



Horizontal Ridge Augmentation with Piezoelectric Hinge-Assisted Ridge Split Technique in the Atrophic Posterior Mandible

Min-Sang Cha, Ji-Hye Lee¹, Sang-Woon Lee², Lee-Ra Cho³, Yoon-Hyuk Huh³, You-Sun Lee⁴

Division of Prosthodontics, Department of Dentistry, Gangneung Asan Hospital, University of Ulsan College of Medicine, ¹Division of Prosthodontics, Department of Dentistry, Uijeongbu St. Mary's Hospital, The Catholic University of Korea College of Medicine, ²Division of Oral and Maxillofacial Surgery, Department of Dentistry, Gangneung Asan Hospital, University of Ulsan College of Medicine, ³Department of Prosthodontics, Research Institute of Oral Science, Gangneung-Wonju National University, ⁴Department of Orthodontics, Section of Dentistry, Seoul National University Bundang Hospital

Abstract

Onlay bone grafting, guided bone regeneration, and alveolar ridge split technique are considered reliable bone augmentation methods on the horizontally atrophic alveolar ridge. Among these techniques, alveolar ridge split procedures are technique-sensitive and difficult to perform in the posterior mandible. This case report describes successful implant placement with the use of piezoelectric hinge-assisted ridge split technique in an atrophic posterior mandible.

Key words: Piezosurgery, Alveolar ridge augmentation, Ridge split

Introduction

Adequate horizontal bone width is important for successful dental implant treatment in edentulous patients. A narrow alveolar bone ridge can cause inappropriate location or direction of dental implant placement. These can affect following prosthetic rehabilitation. Proper horizontal alveolar bone width for the implant placement is at least 5 mm[1]. More than 1 mm width of alveolar bone is needed around the installed dental implant[2].

When the alveolar ridge width is insufficient for the planned implant diameter, horizontal ridge augmentation tech-

niques such as onlay bone grafting, guided bone regeneration (GBR), and alveolar ridge splitting are used for proper implant placement[3]. However, these techniques have some disadvantages in clinical application. With onlay bone grafting, additional surgery is needed for the bone harvesting. In addition, continuous bone resorption is frequent. In the GBR procedures, adequate bone volume does not develop without a barrier membrane. Moreover, infection incidence is increased when the barrier membrane is exposed[4].

The ridge split technique for horizontal bone augmentation was introduced by Simion *et al.*[5] in 1992. The dental

RECEIVED February 14, 2014, REVISED March 8, 2014, ACCEPTED May 8, 2014

Correspondence to Lee-Ra Cho

Department of Prosthodontics, Gangneung-Wonju National University
7 Jukheon-gil, Gangneung 210-702, Korea
Tel: 82-33-640-3182, Fax: 82-33-640-3103, E-mail: lila@gwnu.ac.kr

Copyright © 2014 by The Korean Association of Maxillofacial Plastic and Reconstructive Surgeons. All rights reserved.

© This is an open access article distributed under the terms of the Creative Commons Attribution Non-Commercial License (<http://creativecommons.org/licenses/by-nc/3.0>) which permits unrestricted non-commercial use, distribution, and reproduction in any medium, provided the original work is properly cited.

implant was placed immediately after the ridge split procedure. A non-absorbable membrane covered the gap between buccal and lingual cortical bone with no application of bone graft material. The primary stability of a dental implant comes from the apical 3 to 4 mm intact bone. With this technique, about 1.0 to 1.5 mm expansion of alveolar bone can be obtained in the mandible and 3 to 4 mm in the maxilla. In 1994, Scipioni *et al.*[6] also reported immediate implant placement after a ridge split of maxillary alveolar bone. In this study, membranes and bone graft materials were not applied to reduce the risk of post-operative infection. In earlier studies, ridge split techniques were performed mainly in the maxillary alveolar bone. In the ridge split technique, lateral movement of buccal cortical bone plate was more difficult in the mandible than in the maxilla due to dense cortical bones and external oblique ridge. Thus, the available width of ridge expansion in the mandible is commonly smaller than that of the maxilla[5].

Holtzclaw *et al.*[7] introduced a piezoelectric hinge-assisted ridge split (PHARS) technique in the atrophic posterior mandible. Use of a piezoelectric device, ridge expansion by hinge movement, simultaneous bone graft, and delayed implantation were the main procedures in the PHARS technique. This can overcome the limited expansion width in the posterior mandible. This study achieved successful dental implant treatment with the PHARS technique in the horizontally atrophic posterior mandible.

Case Report

A healthy 67-year-old woman visited the dental clinic with mastication difficulties. Both sides of the posterior mandible needed prosthetic rehabilitation. Dental implant treatments were planned to restore the mandible edentulous regions. The right side of the posterior mandible had adequate vertical and horizontal width of alveolar bone for the dental implants placement. However, the left side of the posterior mandible had a narrow alveolar ridge (Fig. 1A, 2A). Delayed placement of dental implants was planned after horizontal ridge augmentation with the PHARS technique.

After local anesthesia, a full-thickness periosteal flap was

made to expose the alveolar bone. Alveolar bone width was observed to be about 4 to 5 mm at the alveolar crest (Fig. 2B). An initial bone cut was made at the alveolar bone crest, considering the implant position. After crestal osteotomy, lateral vertical osteotomies were performed with a length of around 10 mm, and apical horizontal osteotomy was performed for the hinge movement of the buccal cortical plate. A piezoelectric surgery device (PIEZOSURGERY; Mectron, Carasco, Italy) was used for the bone osteotomy. Guide pins in the crestal osteotomy line were angulated lingually to the axis of premolar teeth (Fig. 2C). A periapical film was placed parallel with the guide pins, and a periapical radiograph was taken to evaluate the position of inferior alveolar canal and mental foramen. The crestal osteotomy was deepened to around 10 mm of vertical depth. Lateral vertical osteotomies were deepened in the lingual direction through the cancellous bone until the cutting tip reached the lingual bone plate. After that, the apical horizontal osteotomy was retraced carefully to avoid complete separation of the buccal bone plate (Fig. 2D). Lateral hinge movement was performed with bone chisels. After 3 to 4 mm lateral movement of buccal bone plate, xenogenic bone (BioCera; Oscotec, Seongnam, Korea) was grafted into the gap between buccal and lingual bone plates. A resorbable collagen membrane (Bio-Gide; Geistlich, Wolhusen, Switzerland) was applied to cover the graft material (Fig. 2E~2G). Primary closure was performed with the use of periosteal releasing incisions (Fig. 1B, 1C).

Four months after the operation, implant placement surgery was performed on the horizontally expanded alveolar bone (Fig. 3A, 3B). Two implants (Implantium; Dentium, Suwon, Korea) of 4.5 mm diameter were inserted into the bone grafted region (Fig. 1D, 3C). A bone biopsy was performed to evaluate histological findings (Fig. 4). A trephine bur (internal diameter 2.3 mm/external diameter 3.0 mm) was used to obtain bone tissues at the planned implant sites. Abutment connection surgery was performed six weeks after the implant placement. Final prostheses were delivered four weeks after the abutment connection surgery (Fig. 1E, 3D).

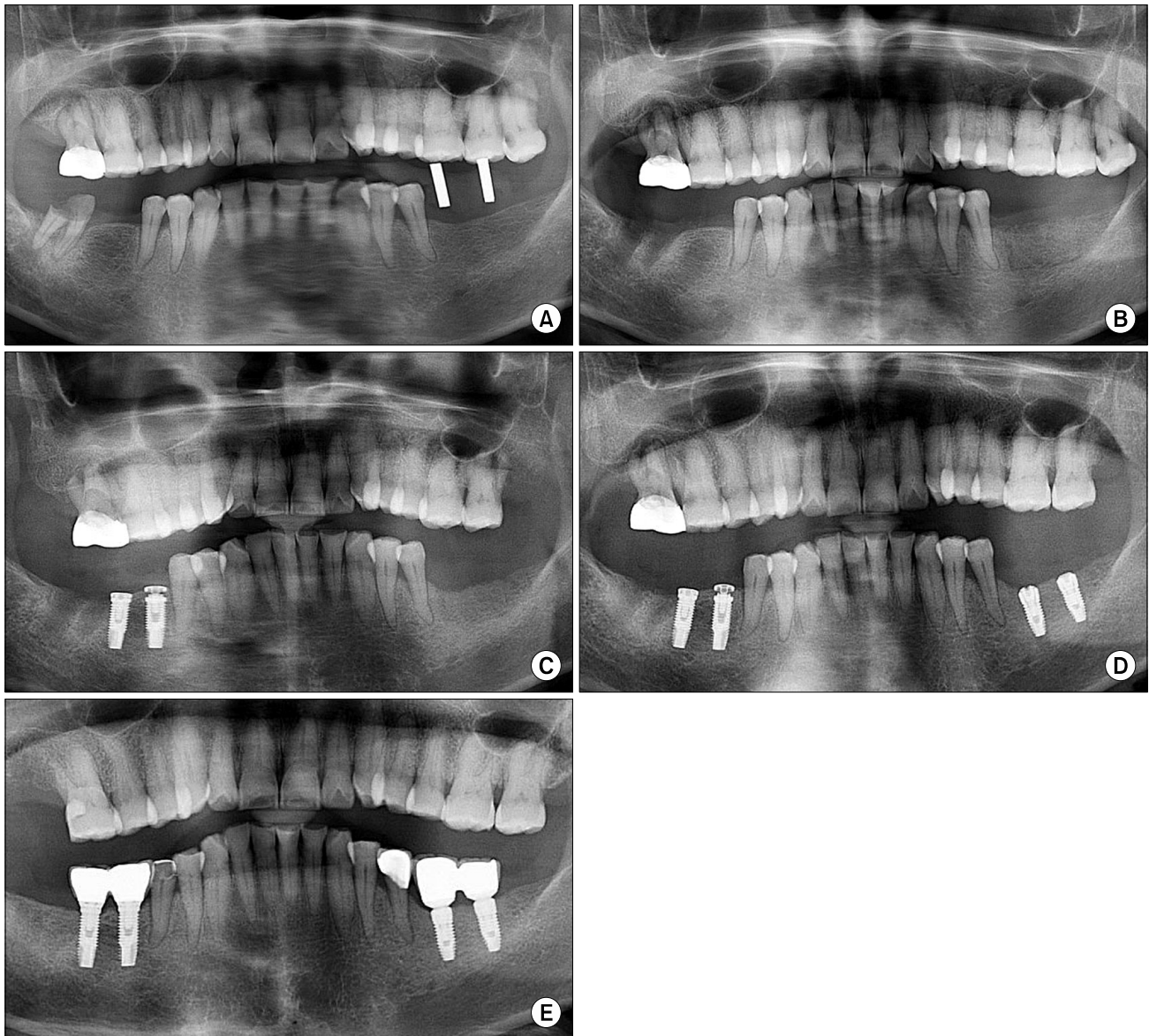


Fig. 1. Radiographic images. (A) Preoperative panoramic radiograph. (B) Panoramic radiograph immediately after piezoelectric hinge-assisted ridge split procedure. (C) Postoperative panoramic radiograph after 3 months. (D) Panoramic radiograph after 4 months and implant installation. (E) Panoramic radiograph at 6 months in function.

Discussion

Splitting is often done with a bone chisel[5,6], diamond disk[8], or microsaw[9]. With the use of bone chisel, it is difficult to make precise cuts in the dense cortical bone of the posterior mandible. It can also cause discomfort for the patient during the operation. A bone saw risks soft tissue trauma. The piezoelectric surgery device used in this study can produce a precise osteotomy, without trauma to the soft tissue, and has a wide range approach in the operative sites[10], so that the accurate apical hori-

zontal osteotomy can be performed successfully and malfracture of dense cortical buccal plate avoided. A few studies[8,9] reported ridge split technique in the posterior mandible when cleaving the buccal cortical plate and installing dental implant immediately. The split crestal bone was adjusted back to its previous position and fixed with a bone screw. In these cases, buccal plate cleavage might be inevitable because a piezoelectric surgery device could not be used.

The ridge split technique can be classified by immediate or delayed ridge splitting in terms of split timing. The

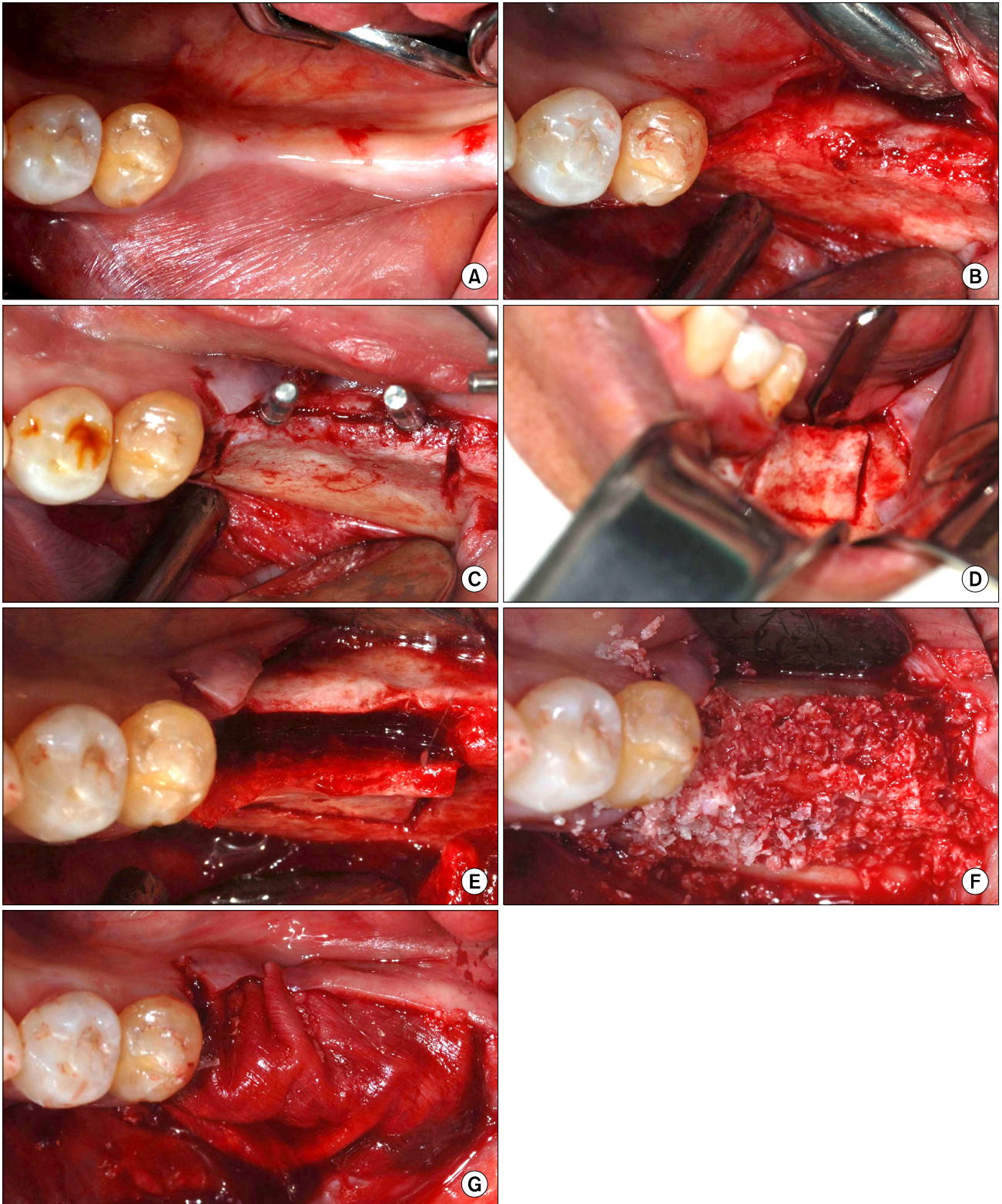


Fig. 2. Piezoelectric hinge-assisted ridge split procedure. (A) Initial clinical view. (B) A full-thickness flap was raised. (C) Two guide pins were placed at the first and second molar. (D) A curved chisel was inserted and gently pushed. (E) Ridge splitting was completed. (F) Xenograft was placed. (G) A resorbable membrane covered the surgical site.

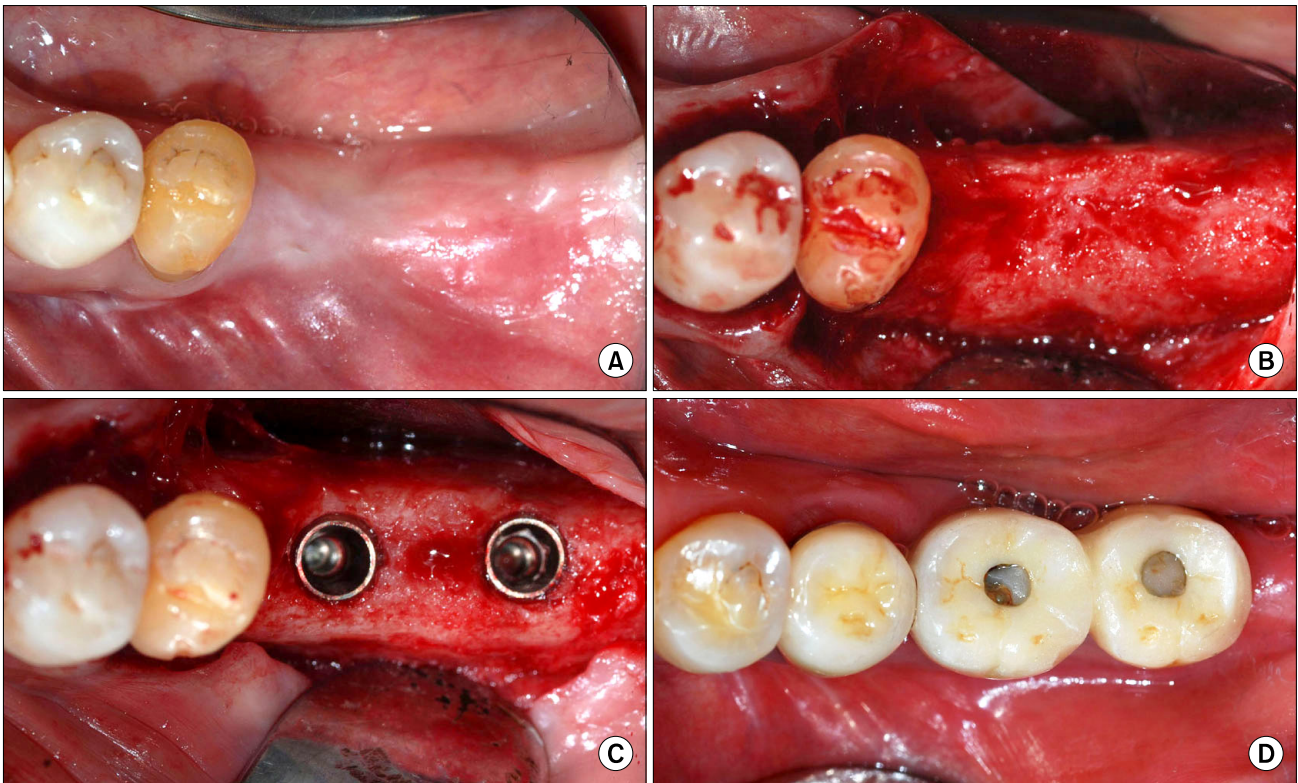


Fig. 3. (A) Clinical view after 4 months of healing. (B) Re-entry for implant installation. (C) Two implants were placed. (D) Final restorations.

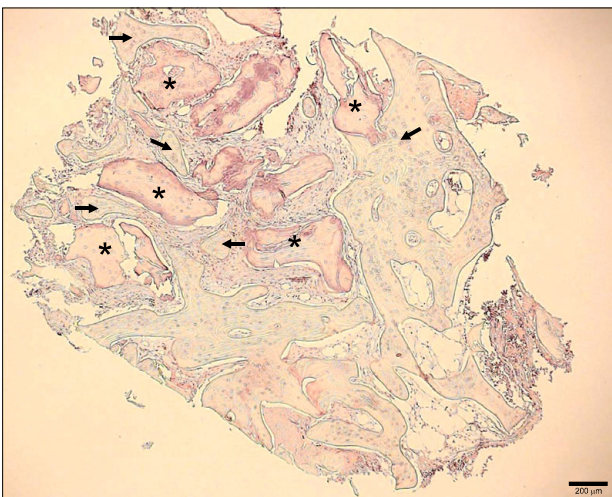


Fig. 4. Biopsy histologic findings. Graft materials (asterisks) were surrounded by newly regenerated bones (arrows) and no foreign body reaction was observed (H&E, $\times 40$).

immediate ridge split procedure with simultaneous implant placement offers favorable bone healing and implant success rates[10-12]. Enislidis *et al.*[13] reported on delayed ridge splitting. The main procedures of this technique were rectangular corticotomy followed by reposition of mucoper-

ioosteal flap with no lateral movement of buccal bone plate. After mucoperiosteal flap healing, fracture and lateral movement of the buccal bone plate with implant placement were performed. In 2010, Sohn *et al.*[14] reported a clinical study comparing immediate and delayed lateral ridge expansion techniques in the posterior mandible. Uneventful lateral movement and predictable alveolar bone augmentation were observed in the delayed lateral ridge expansion, whereas unwanted fracture of buccal cortical plate occurred in five patients among the 23 patients who underwent immediate lateral ridge expansion. The short treatment period was the primary advantage of immediate lateral ridge expansion, although lack of implant stability, unwanted bone fracture, and compromised direction of dental implants were disadvantages.

Immediate ridge splitting was used in this study, although differently from the original techniques in that a minimal depth of apical horizontal osteotomy was used only to guide lateralization. After the ridge split procedure, implant installation was delayed so that pressure during placement of implant or drilling could be avoided. Therefore, malfracture of the buccal bone plate did not occur.

Jensen *et al.*[15] reported the amounts of marginal bone loss after lateral ridge expansion procedures. A bone split of below 3 mm width of the alveolar ridge tends to cause more marginal bone loss than one above 4 mm width. Thus, dental implant placement should be delayed in the severely narrow alveolar ridge. They also demonstrated that elevation of full thickness periosteal flap leads to more marginal bone loss than a partial thickness periosteal flap. In this case, slight crestal bone resorption was observed on the postoperative three months radiographic images, in spite of using the barrier membrane (Fig. 1B, 1C). This might be related to the elevation of a full thickness mucoperiosteal flap to expose alveolar bone. The osteotomy line was still visible on the three month post-surgical radiographic image. However, bone healing of the osteotomy line was evident at four months after the operation (Fig. 1C, 1D). This radiographic finding of bone healing was similar to Basa's study[8].

During the ridge split procedure the distance to vital structures such as the inferior alveolar canal and the mental foramen in the posterior mandible could be directly measured through the periapical radiograph using guide pins. This guide pin measuring procedure might help to avoid inferior alveolar nerve damage. There was no need to preserve at least 3 to 4 mm intact apical bone for primary stability of dental implant because immediate implant installation was not planned in this case. Therefore, sufficiently long vertical corticotomies could be performed. With this procedure it was possible to make a 3 to 4 mm lateral expansion of stiff cortical plate in the posterior mandible and install the implant fixture 4,5 mm in diameter in a direction favorable for prostheses.

A bone biopsy was performed to evaluate the bone formation at the grafted area during implant placement surgery. The histologic result showed the new bones around the graft materials and no inflammatory reactions (Fig. 4). Although the bone formation was incomplete four months after the bone graft, the bone grafted site was considered appropriate for implant placement. The stable level of crestal bone around implants on the panoramic radiograph at six months in function indicated that the bone graft was successful (Fig. 1E).

The PHARS procedure is a delayed implant installation method with immediate ridge splitting. With this method,

the effects of resorption of alveolar crest after ridge splitting are avoidable, and sufficient horizontal augmentation can be achieved predictably in atrophic posterior mandible. Further long-term clinical study is necessary to confirm the success of the augmented sites.

References

1. Misch CM, Misch CE, Resnik RR, Ismail YH. Reconstruction of maxillary alveolar defects with mandibular symphysis grafts for dental implants: a preliminary procedural report. *Int J Oral Maxillofac Implants* 1992;7:360-6.
2. Nedir R, Bischof M, Briaux JM, Beyer S, Szmukler-Moncler S, Bernard JP. A 7-year life table analysis from a prospective study on ITI implants with special emphasis on the use of short implants. Results from a private practice. *Clin Oral Implants Res* 2004;15:150-7.
3. Donos N, Mardas N, Chadha V. Clinical outcomes of implants following lateral bone augmentation: systematic assessment of available options (barrier membranes, bone grafts, split osteotomy). *J Clin Periodontol* 2008;35:S173-202.
4. Chiapasco M, Abati S, Romeo E, Vogel G. Clinical outcome of autogenous bone blocks or guided bone regeneration with e-PTFE membranes for the reconstruction of narrow edentulous ridges. *Clin Oral Implants Res* 1999;10:278-88.
5. Simion M, Baldoni M, Zaffe D. Jawbone enlargement using immediate implant placement associated with a split-crest technique and guided tissue regeneration. *Int J Periodontics Restorative Dent* 1992;12:462-73.
6. Scipioni A, Bruschi GB, Calesini G. The edentulous ridge expansion technique: a five-year study. *Int J Periodontics Restorative Dent* 1994;14:451-9.
7. Holtzclaw DJ, Toscano NJ, Rosen PS. Reconstruction of posterior mandibular alveolar ridge deficiencies with the piezoelectric hinge-assisted ridge split technique: a retrospective observational report. *J Periodontol* 2010;81:1580-6.
8. Basa S, Varol A, Turker N. Alternative bone expansion technique for immediate placement of implants in the edentulous posterior mandibular ridge: a clinical report. *Int J Oral Maxillofac Implants* 2004;19:554-8.
9. Piccinini M. Mandibular bone expansion technique in conjunction with root form implants: a case report. *J Oral Maxillofac Surg* 2009;67:1931-6.
10. Blus C, Szmukler-Moncler S, Vozza I, Rispoli L, Polastri C. Split-crest and immediate implant placement with ultrasonic bone surgery (piezosurgery): 3-year follow-up of 180 treated implant sites. *Quintessence Int* 2010;41:463-9.
11. Blus C, Szmukler-Moncler S. Split-crest and immediate implant placement with ultra-sonic bone surgery: a 3-year life-table analysis with 230 treated sites. *Clin Oral Implants Res* 2006;17:700-7.
12. Danza M, Guidi R, Carinci F. Comparison between implants inserted into piezo split and unsplit alveolar crests. *J Oral Maxillofac Surg* 2009;67:2460-5.
13. Enislidis G, Wittwer G, Ewers R. Preliminary report on a staged ridge splitting technique for implant placement in the

- mandible: a technical note. *Int J Oral Maxillofac Implants* 2006;21:445-9.
14. Sohn DS, Lee HJ, Heo JU, Moon JW, Park IS, Romanos GE. Immediate and delayed lateral ridge expansion technique in the atrophic posterior mandibular ridge. *J Oral Maxillofac Surg* 2010;68:2283-90.
 15. Jensen OT, Cullum DR, Baer D. Marginal bone stability using 3 different flap approaches for alveolar split expansion for dental implants: a 1-year clinical study. *J Oral Maxillofac Surg* 2009;67:1921-30.