

# Is Aggressive Therapy the Answer for All Cases of Emphysematous Pyelonephritis: A Report of Three Cases

Sidharth Kumar, Sushanto Neogi, Kamal K. Gautam

Department of General Surgery, Maulana Azad Medical College and Associated Lok Nayak Hospital, New Delhi, India

## INTRODUCTION

Emphysematous pyelonephritis (EPN) is uncommon, mainly in patients with uncontrolled diabetes or who are immunocompromised. It is a life-threatening emergency, estimates of mortality using current therapy range from 10 to 40%.<sup>[1]</sup> Despite high mortality rates there is a paucity of large series of cases leading to variations in management protocols followed in various institutes. We report three patients with different presentations of EPN who came to our institute with their differing management strategies. One patient was unusual as she had a combination of EPN and pneumoperitoneum, which is very rare and reported only once previously.<sup>[2]</sup>

## CASE REPORTS

### Case 1

A 55-year-old gentleman presented to the surgical emergency with complaints of progressively increasing pain and swelling on the left flank, high grade fever and decreased urine output for the last 15 days. He also had a history of extreme weakness and feeling of being unwell for 1 month. He was a known diabetic on oral hypoglycemic agents. On examination the patient was a thin built, sick looking individual, pale, febrile with

## ABSTRACT

Emphysematous Pyelonephritis (EPN) is a severe, necrotizing, life threatening infection of the renal parenchyma and management is not standardised due to scarcity of literature. We present 3 patients with this rare entity. All 3 patients were of class III on CECT findings based on Huang's classification and had more than two risk factors. Our first patient underwent percutaneous drainage of his condition upon which he recovered. The second and third patients underwent a laparotomy and nephrectomy. The second patient recovered after a stormy post operative period and the third patient died. Management of the first patient was contrary to that recommended in literature, for the other two it was as per recommendations. On successful management of our first patient without surgery and seeing no discernable benefits of surgery for our other two patients, it is possible that percutaneous drainage alone, coupled with antibiotics may be a viable strategy for managing this condition with nephrectomy being considered as a second tier option.

**Key words:** Emphysematous, life threatening, necrotizing, nephrectomy, pyelonephritis

tachycardia of 110/min. He was not icteric and had no lymphadenopathy. Abdominal examination showed a large area of abscess over the left flank and back covering an area of around 15 × 10 cm, which showed inflammatory changes and evidence of tenderness and crepitus on palpation. The investigations showed a markedly deranged blood urea (150 mg/dl) and serum creatinine (4 mg/dl) levels. The blood sugar was 300 mg/dl but there was no evidence of ketonuria at time of admission. An ultrasound (USG) of the abdomen was performed and the left kidney showed evidence of air in the parenchyma, which was extending up to the parietes, suggestive of emphysematous pyelonephritis. Computer tomography (CT) scan was done which showed the left-sided kidney to be enlarged with multiple air lucencies extending up to the skin and subcutaneous tissue [Figures 1 and 2]. Since the inflammatory material had already spread to the parietes, and due to poor general condition of the patient, a decision for incision and drainage was taken under local anesthesia. The wound was left open after draining the gas and the purulent material that were reaching up to the level of the left kidney. The patient was started on broad spectrum antibiotics and the pus sent for both aerobic and anaerobic culture. The anaerobic

### Access this article online

#### Quick Response Code:



#### Website:

www.jstcr.org

#### DOI:

10.4103/2006-8808.110268

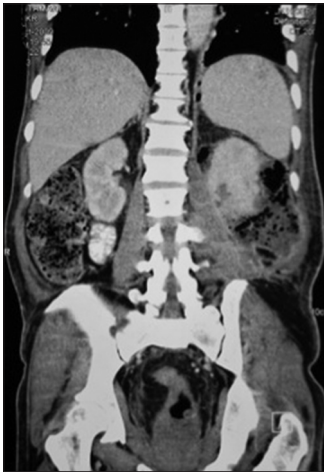**Address for correspondence:** Dr. Sidharth Kumar, Department of General Surgery, Maulana Azad Medical College and Associated Lok Nayak Hospital, E-203, Sagar Sadan Apts, 113, IP Extension, Patparganj, New Delhi, India. E-mail: sidharth@doctors.org.uk

culture was negative. The gram stain showed gram negative cocci. The pus came out positive for Klebsiella, which was sensitive to the antibiotics already being used. The patient was started on human insulin on sliding scale to control the deranged sugar profile. The patient started responding to this treatment within the next 24 h with fever subsiding and there was improvement in the general well being of the patient. The patient's blood urea and creatinine levels progressively decreased to stabilize at urea (60 mg/dl) and creatinine (2 mg/dl). The patient's urine output was adequate at all times during the admission period. The patient was subsequently discharged after a period of 3 weeks with minimal discharge from the surgical site and is doing well after 6 months of follow-up.

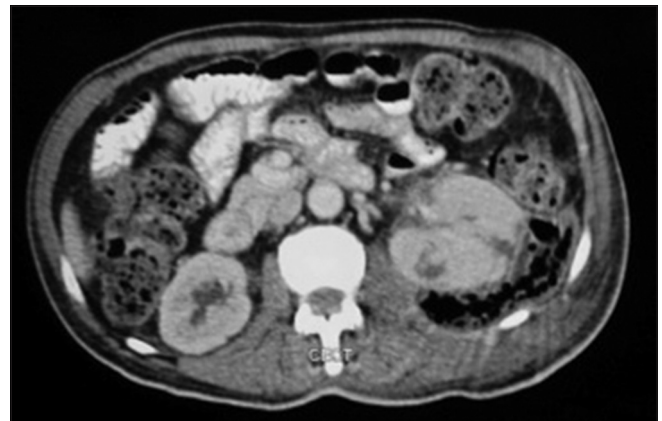### Case 2

A 30-year-old obese lady presented to the surgical emergency with history of pain in the right upper

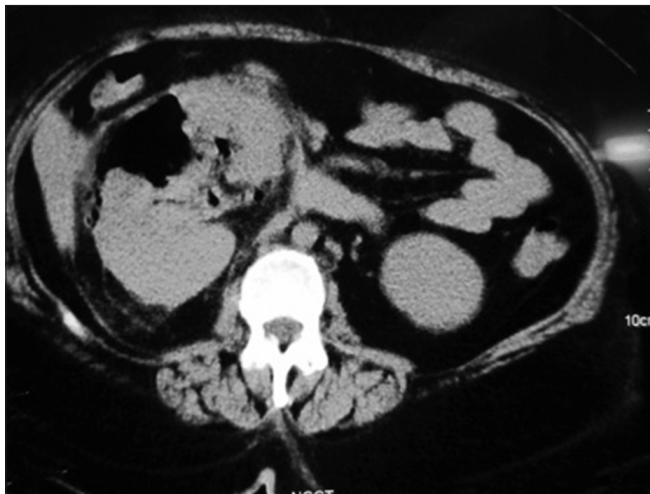abdomen and back, with a history of on and off fever and generalized ill health for the past 2 weeks. She was a known diabetic but was on irregular treatment and poorly controlled according to the records available. Examination showed the patient to be febrile, along with tachycardia of 110/min. The patient was normotensive at admission. The patient was pale but had no other significant finding on general physical examination. Examination showed an ill-defined tender lump occupying the right lumbar and hypochondrium of approximately 10 × 8 cm size. Because of the tenderness and obesity of the patient the characteristics of the lump could not be elicited fully. Hematological investigations showed a hemoglobin of 5 g/dl and total count of 13,000/mm<sup>3</sup>. Biochemical investigations showed a blood sugar of 350 mg/dl with ketonuria, deranged blood urea (100 mg/dl) and serum creatinine (3 mg/dl). X-ray of the abdomen revealed air lucencies along the right psoas muscle, but no free air under diaphragm. Because of suspicion of emphysematous pyelonephritis, a CT scan was ordered and this revealed the right kidney enlarged with multiple air lucencies in the



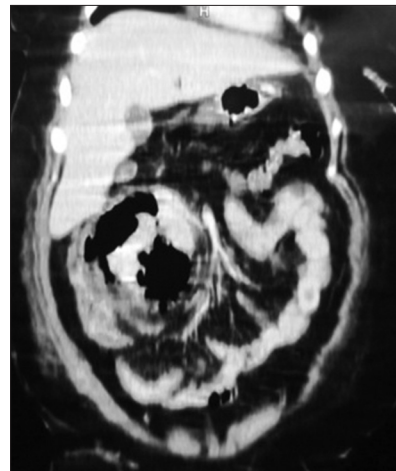
**Figure 1:** CECT with coronal reconstruction showing emphysematous pyelonephritis of left kidney



**Figure 2:** CECT showing emphysematous pyelonephritis of left kidney



**Figure 3:** CECT showing emphysematous pyelonephritis of right kidney



**Figure 4:** CECT with coronal reconstruction showing emphysematous pyelonephritis of right kidney

parenchyma with non-excretion of contrast, suggestive of emphysematous pyelonephritis [Figures 3 and 4]. The patient was explored in the emergency for right nephrectomy. A right nephrectomy with debridement of the surrounding necrotic tissue was done. The pus was sent for culture sensitivity and came out to be positive for *Klebsiella* species and the patient was then started on appropriate antibiotics. The patient had a turbulent postoperative period with persistent hypotension and oliguria for which she was given inotropic support, oliguria. She also had a postoperative high-grade continued fever, which continued for 72 h. With the resolution of sepsis, she became afebrile and could be weaned off inotropic supports. Her recovery was gradual and she was discharged from our care only on the 11<sup>th</sup> day.

### Case 3

A 50-year-old lady presented to the surgical emergency in a condition suggestive of shock. The patient was immediately resuscitated and two large bore cannulas were inserted and ringer lactate solutions were started. Patient was put on oxygen by mask. The pulse at time of admission was 130/min but the blood pressure was un-recordable. After 1 h of resuscitation the systolic blood pressure became 70 mmHg. The patient was then started on inotropic support. During this period the rest of history and examination was conducted. The patient was a known diabetic on oral hypoglycemic agents. The patient developed high-grade fever, nausea, vomiting and right-sided abdominal pain for the past 1 week. The patient was in anuria for the past 3 days. The patient started developing abdominal distension along with constipation for the past 3 days. Examination revealed all the peripheral signs of hypovolemic shock. The patient was dehydrated with sunken eyeballs and dry tongue. The patient was drowsy and responding only to painful stimuli. The patient's abdomen was distended with board like rigidity and tenderness, along with crepitus palpable on the right lumbar region. A clinical diagnosis of perforation peritonitis, septicemia with shock was made. The patient had already got a CT scan from another hospital before coming to our hospital, which showed gas under right dome of diaphragm. The right kidney was replaced with gas lucencies and was markedly enlarged. The patient was diagnosed as emphysematous pyelonephritis with pneumoperitoneum. The patient was taken for emergency exploration but no visceral perforation was found. The pus sent for culture grew *Klebsiella* species. The patient had a turbulent postoperative period and did not survive beyond six hours of surgery.

## DISCUSSION

Emphysematous pyelonephritis is a rare, severe, gas-forming infection of renal parenchyma and its surrounding areas. *E. coli* and *Klebsiella* are the common causative organisms.<sup>[2]</sup> Anaerobic species is only found to the tune of 1% only.<sup>[2]</sup> The disease is encountered primarily in patients with diabetes mellitus or ureteral obstruction associated with perinephric and intrarenal gas.<sup>[2]</sup> An earlier case of pneumoperitoneum has been described which did not reveal any visceral perforation but *Clostridia ramosus* was isolated. Mixed acid fermentation of glucose by Enterobacteriaceae is the major pathway of gas formation.

According to the radiological findings on CT scan, EPN is classified into the following classes:<sup>[3]</sup>

1. Class 1: Gas in the collecting system only
2. Class 2: Gas in the renal parenchyma without extension to extrarenal space
3. Class3:
  - Class A: Extension of gas or abscess to perinephric space
  - Class B: Extension of gas or abscess to pararenal space; and
4. Class 4: Bilateral EPN or solitary kidney with EPN.

Types 1 and 2 are milder forms and are treated with antibiotics and drainage either percutaneous or open technique.

In types 3 and 4 which are extensive forms, but no risk factors like, thrombocytopenia, impaired renal function, deranged consciousness or shock can be managed like the milder forms, but patients with risk factors require nephrectomy as a life-saving measure, but still have high mortality to the tune of 18%.<sup>[3]</sup>

In our cases all the patients belonged to class 3 but one of them was managed with percutaneous drainage unlike what is advocated in literature. The patient was in poor general condition to undergo any major surgery; therefore, drainage of the purulent material which had spread to parietes was done. This alone along with good glycemic control ensured the patients survival. The third patient did not survive laparotomy as the infection had spread to the general peritoneal cavity by the time the patient came to our emergency. This was evident in the form of pneumoperitoneum along with gas in the renal parenchyma on right side.

Plain radiographs are good for depicting air within the renal collecting system, but non-specificity is a problem because

of the superimposition of gas from the bowel. Moreover, gas in the retro-peritoneum and gas within a renal or peri-nephric abscess may mimic EPN. Ultrasonography was a good modality for confirmation of diagnosis but with the advent of CT, use of USG for confirmation has decreased. CT findings are diagnostic of the presence of air within the renal tract, and CT also elegantly depicts the renal and perirenal anatomy and the spread of infection to the perinephric tissues.<sup>[4,5]</sup>

The diagnosis is difficult to arrive at, as clinical picture is similar to acute pyelonephritis and sometimes to patients with obstructive uropathy. With the advent of CT scanning, more powerful antibiotics and better access to life support, an alternative medical approach has emerged but surgical intervention in form of percutaneous drainage or nephrectomy is still required.<sup>[4,5]</sup>

## REFERENCES

1. Chen KW, Huang JJ, Wu MH, Lin XZ, Chen CY, Ruaan MK. Gas in hepatic veins: A rare and critical presentation of emphysematous pyelonephritis. *J Urol* 1994;151:125-6.
2. Langdale LA, Rice CL, Brown N. Emphysematous Pyelonephritis in a xantho-granulomatous kidney. An unusual cause of pneumoperitoneum. *Arch Surg* 1988;123:377-9.
3. Huang JJ, Tseng CC. Emphysematous pyelonephritis: Clinicoradiological classification, management, prognosis, and pathogenesis. *Arch Intern Med* 2000;160:797-805.
4. Grozel F, Berthezene Y, Guerin C, Tran-Minh VA, Croisille M. Bilateral emphysematous pyelonephritis resolving to medical therapy: Demonstration by US and CT. *Eur Radiol* 1997;7:844-6.
5. Craig WD, Wagner BJ, Travis MD. Pyelonephritis: Radiologic-pathologic review. *Radiographics* 2008;28:255-77; quiz 327-8.

**How to cite this article:** Kumar S, Neogi S, Gautam KK. Is Aggressive Therapy the Answer for All Cases of Emphysematous Pyelonephritis: A Report of Three Cases. *J Surg Tech Case Report* 2012;4:106-9.

**Source of Support:** Nil, **Conflict of Interest:** None declared.