


Genomic Alterations In Primary Cardiac Diffuse Large B Cell Lymphoma: A Case Report And Literature Review

This article was published in the following Dove Press journal:
OncoTargets and Therapy

Jinjing Zhang¹
Xuyong Lin¹ 
Yan Li¹
Rui Zhang¹

¹Department of Hematology, The First Affiliated Hospital of China Medical University, Shenyang, Liaoning 110001, People's Republic of China; ²Department of Pathology, The First Affiliated Hospital of China Medical University, Shenyang, Liaoning 110001, People's Republic of China

Abstract: Primary cardiac diffuse large B cell lymphoma (PC-DLBCL) is a rare kind of hematological malignancy, and its clinical and pathologic characteristics, especially in Eastern countries, remain unclear. Moreover, genomic alterations in PC-DLBCL have not been studied previously. We describe a case of a 57-year-old man who presented with exertional dyspnoea due to a heart mass in April 2018 and was diagnosed with PC-DLBCL characterized by immunohistochemical markers of the activated B cell (ABC) subtype and double expression of c-MYC and Bcl-2. Mutations in a total of 11 genes—*TBL1XR1*, *CD79B*, *IGLL5*, *ZMYM3*, *MYD88*, *TMSB4X*, *PIMI1*, *BTK*, *NRXN3*, *CUX1*, and *CSMD1*—were detected via next-generation sequencing (NGS), while 19 copy number variations (CNVs) such as 1q+, 3p+, 3q+(*2), 5p+, 6p-, 6q-, 7q+, +11, 12q-, 15q-, 17q+, 17p-, +18, 19q+, 19p-, 19q-, X q+, and -Y and 4 copy-neutral loss of heterozygosity (CN-LOH) lesions located at 1q21.1q44, 3p26.3q11.2, 3q13.11q29 and 6p22.2p21.32 were identified by single nucleotide polymorphism (SNP) array karyotyping. Some key gene alterations in lymphoma, such as *PRDM1* deletion and *Bcl-2* amplification, were identified using SNP array analysis. The patient received 6 courses of chemotherapy (rituximab, cyclophosphamide, doxorubicin, vincristine, prednisone, R-CHOP regimen) after surgery and is currently in remission. In summary, the present case was diagnosed as PC-DLBCL, ABC subtype by the Hans algorithm and double expression lymphoma, with co-occurrence of the *MYD88*^{L265P} and *CD79B* mutations (MCD) subtype by genetic alteration analysis. This study presents a unique PC-DLBCL case in which complex genomic alterations were revealed by NGS and SNP array analysis, which has never been reported in the literature, and these findings could provide new insight into the genomic characterization of PC-DLBCL.

Keywords: primary cardiac diffuse large B cell lymphoma, NGS, SNP array

Introduction

Primary cardiac lymphoma (PCL) is described as extranodal lymphoma involving only the heart and/or pericardium or presenting with cardiac symptoms particularly accompanied by the development of the main mass of the tumour in the heart or pericardium.¹ PCL is a rare malignant tumour, accounting for 2% of primary heart tumours and approximately 0.3% of lymphomas.^{2,3} Across the broad pathologic spectrum of PCL, diffuse large B cell lymphoma (DLBCL) is the most common histologic subtype, accounting for approximately 63–85% of PCL cases.^{3,4} Recently, genomic aberrations have been regarded to impact the prognosis and outcome of DLBCL;^{5,6} however, the genetic characteristics of primary cardiac diffuse large B cell lymphoma (PC-DLBCL) have rarely been reported.^{6–10} Herein, we report a case of a patient with PC-DLBCL

Correspondence: Rui Zhang
Department of Hematology, The First Affiliated Hospital of China Medical University, Shenyang, Liaoning 110001, People's Republic of China
Tel +86-18240200366
Email zhangruicmlh@163.com

and analyse the genomic alterations via next-generation sequencing (NGS) and single nucleotide polymorphism (SNP) array analysis.

Case Presentation

A 57-year-old male presented with exertional dyspnoea of 1-week duration without fever, night sweats and weight loss. He was admitted to the department of cardiac surgery of the First Affiliated Hospital of China Medical University (CMU) in April 2018 because of the right atrial mass revealed by echocardiography in a local hospital with a negative medical history. Physical examination showed no lymphadenopathy, and the liver and spleen were not palpable. Laboratory tests indicated that routine blood parameters, liver and renal function, and the coagulation index were normal, and the patient was negative for anti-HIV antibodies. The electrocardiogram (ECG) revealed sinus tachycardia and atrial premature beats. The computed tomographic angiography (CTA) of the coronary artery demonstrated a low-density bulk in the right atrium with dimensions of 70 mm X 52 mm infiltrating into both the superior vena cava (SVC) and inferior vena cava (IVC), oppressing the pulmonary vein (Figure 1). Increased uptake of FDP (SUV=25.8) was shown in the cardiac mass by positron emission tomography/computed tomography (PET/CT), and no extracardiac involvement was demonstrated. The patient underwent surgery for cardiac mass resection, which provided pathologic evidence of DLBCL. The cardiac mass

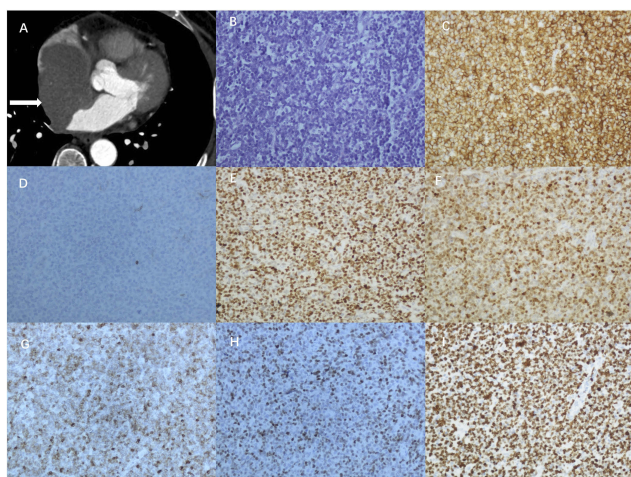


Figure 1 The radiological and pathological examinations of the patient. (A) Computed tomographic angiography (CTA) of the coronary artery revealed a low-density mass (white arrow) in the right atrium. (B) Microscopic examination showed diffuse infiltration by large lymphoid cells with round or oval nuclei and an altered nuclear-cytoplasmic ratio (original magnification x200). (C-I) Immunohistochemical staining of the lymphoid cells (original magnification x200). (C) Positive staining for CD20. (D) Negative staining for CD10. (E) Positive staining for Bcl-6. (F) Positive staining for Mum1. (G) Positive staining for Bcl-2. (H) Positive staining for MYC. (I) The Ki67 staining demonstrating a 80% proliferative rate.

was composed of a diffuse infiltrate of large lymphoid cells with round or oval nuclei and an altered nuclear-cytoplasmic ratio, as observed under microscopic examination. Immunohistochemical staining revealed that the lymphoid cells were positive for CD20, CD45, Pax-5, Bcl-6, Mum1, Bcl-2, and MYC; sporadic positive for CD21 and CD3; and negative for CD10, CK, CyclinD1, CD30, and CD5. The Ki67 index was 80% (Figure 1). Using a NGS platform (HiSeq X Ten, Illumina, San Diego, CA), the whole exome sequencing of 165 hematological tumour-associated genes (Table S1) was performed at Righton Biomedical technology Company Limited (Shanghai, China) using tumour DNA extracted from formalin-fixed paraffin-embedded (FFPE) block. The original data reads obtained from sequencing libraries were collated and evaluated according to the standard protocols, compared with the reference sequence (CRCh37/UCSC hg19), and the sequencing depth and coverage were counted. SNP and InDel mutation information were detected. Functional annotation (GO, Pathway) and conservative prediction and pathogenicity analysis (SIFT, Polyphen-2, GERP) of the mutation genes were performed. In order to get more detailed information, we screened the oncogene/suppressor gene/susceptible gene, analyzed the high-frequency mutation gene, as well as the mutation characteristics and frequency of NMF, and screened the known driving genes. A total of 13 point mutations involving 11 genes were demonstrated by NGS. Seven point mutations in *TBL1XR1*, *CD79B*, *IGLL5*, *ZMYM3*, *MYD88*, *TMSB4X* and *PIMI* had previously been reported in DLBCL, while six point mutations in *PIMI*, *BTK*, *NRXN3*, *CUX1* and *CSMD1* were first reported in lymphoma. Detailed information on the gene mutated is provided in Table 1. DNA copy number variations (CNVs) and regions of homozygosity were identified using whole-genome hybridization at Kingmed Clinical Laboratory (Guangzhou, China), and the genomic locations were retrieved from the National Center for Biotechnology Information (NCBI) build 37 (hg 19) genome. Tumour DNA extracted from FFPE sample using Qiagen QIAamp DNA FFPE Tissue Kit (Qiagen Inc., Valencia, CA) was hybridized with the OncoScan CNV FFPE assay kit (Affymetrix, Santa Clara, CA, USA) according to the manufacturer's protocols. Copy number analysis was estimated utilizing the Chromosome Analysis Suite 3.0 (ChAS 3.0) software, which enabled us to view and summarize chromosomal aberrations across the genome including copy number gain or loss, or loss of heterozygosity. In total, 19 CNVs involving 13 chromosomes (1, 3, 5, 6, 7, 11, 12, 15, 17, 18, 19, X, and Y), including 11 chromosomal gain and eight chromosomal loss CNVs, and four copy-neutral loss of heterozygosity

Table 1 Gene Mutations Revealed By Next-Generation Sequencing (NGS)

Gene	Location Mutation Consequence	VAF	Significance In Lymphoma
<i>TBL1XR1</i>	exon 13 c.A1184G Y395C	82%	Occurred in PCNSL, ABC DLBCL and 18% of OMZL cases; may be involved in the occurrence of lymphoma and associated with resistance to glucocorticoids in B-ALL.
<i>CD79B</i>	exon 5 c.A587C Y196S	38%	Occurred in 25% of ABC DLBCL cases but not in other subtypes of DLBCL or Burkitt lymphoma; BTK, SYK and PKC inhibitors might be effective.
<i>IGLL5</i>	exon 2 c.299_311del; p. G100fs	31%	Occurred in SBP, DLBCL and CLL.
<i>ZMYM3</i>	exon 25 c.G3998A W1333X	80%	An epigenetic regulatory gene and chromatin modification factor; might be correlated with the formation of lymphoma.
<i>MYD88</i>	exon 5 c.T794C L265P	89%	Occurred in LPL and 29% of ABC DLBCL cases but not in other subtypes of DLBCL or Burkitt lymphoma; IRAK1/4 inhibitors might be effective.
<i>TMSB4X</i>	exon 3 c.C118T Q40X	65%	Occurred in relapsed DLBCL and might be associated with poor outcome.
<i>PIM1</i>	exon 4 c.G529A V177M	44%	<i>PIM1</i> mutations reduced ibrutinib sensitivity in ABC-DLBCL through increasing <i>PIM1</i> protein stability.
	exon 1 c.T347C L116P*	38%	
	exon 253 c.G55088C G18363A*	41%	
<i>BTK</i>	exon 4 c.G388A E130K*	42%	Occurred in B-cell lymphomas such as CLL, DLBCL, MCL, and WM. C481S mutation was associated with resistance to ibrutinib.
<i>NRXN3</i>	exon 17 c.C2981A A994D*	32%	<i>NRXN</i> gene mutation occurred in DLBCL.
<i>CUX1</i>	exon 16 c.C1927A Q643K*	74%	Truncation mutation or loss of the <i>CUX1</i> gene was related to poor prognosis.
<i>CSMD1</i>	exon 3 c.C5546T T1849M*	38%	<i>CSMD1</i> gene mutation may be associated with treatment-related AML.

Notes: *The detected point mutation was not reported to be related to haematological malignancy in the COSMIC database or the literature.

Abbreviations: VAF, variant allele frequency; PCNSL, primary central nervous system lymphoma; ABC DLBCL, activated B-cell diffuse large B-cell lymphoma; OMZL, ocular marginal zone lymphoma; B-ALL, B cell acute lymphoblastic leukaemia; BTK, Bruton tyrosine kinase; SYK, spleen tyrosine kinase; PKC, protein kinase C; SBP, solitary bone plasmacytoma; CLL, chronic lymphocytic leukaemia; LPL, diffuse large B-cell lymphoma; IRAK1/4, interleukin 1 receptor-associated kinase 1/4; MCL, mantle cell lymphoma; WM, Waldenström macroglobulinemia; AML, acute myeloid leukaemia.

(CN-LOH) lesions were identified by SNP array karyotyping (Figure 2). Sixteen large chromosomal abnormalities with sizes greater than 5 Mb were observed with multiple chromosome involvement, for example, 1q+, 3p+, 3q+ 5p+, 6p-, 6q-, 7q+, +11, 15q-, 17q+, +18, 19q+, Xq+ and -Y. Four cryptic chromosomal aberrations (≤ 5 Mb), all of which were chromosomal loss, were recognized at 12q24.31, 17p13.1, 19p13.3 and 19q13.42q13.43. It is worth noting that some cancer-associated genes were located in these regions of genomic imbalance, for example, the tumour suppressor genes (TSGs) *PRDM1* (6q21), *TP53* (17p13.1), *HLA-A*, *HLA-B*, and *HLA-C* (6q22.1, 6q22.3, and 6q22.3, respectively) and the oncogenes

Bcl-2 (18q21.3), *Bcl-6* (3q27.3), and *SPIB* (19q33.33) (Table 2). In addition, using *TP53/CSP17* Probe kit (17p13.1/17p11.1-q11) (Jinpujia medical technology Company Limited, Beijing, China), the deletion of 17p13.1 containing *TP53* gene was confirmed by Fluorescence in situ hybridization (FISH) (Figure S1) which was in accordance with SNP array. The patient received 6 courses of chemotherapy (rituximab, cyclophosphamide, doxorubicin, vincristine, prednisone, R-CHOP regimen) after surgery, achieved complete remission as evaluated by PET/CT and showed normal cardiac function by echocardiography. He is currently in remission as of July 2019.




Figure 2 Copy number variations in the present case of primary cardiac diffuse large B cell lymphoma. Four cryptic chromosomal aberrations (≤ 5 Mb), all of which were chromosomal loss, were recognized at 12q24.31, 17p13.1, 19p13.3 and 19q13.42q13.43 and harbored interesting genes.

Discussion And Conclusions

Here, we report a case of DLBCL with a cardiac mass as the initial manifestation. DLBCL is a highly heterogeneous hematological tumour at the clinical, immunohistochemical and genetic levels. DLBCL is divided into germinal center B cell (GCB) and activated B cell (ABC) subtypes according to immunohistochemical markers. In addition, it can be classified into double-hit or double-expression lymphoma based on the rearrangement and expression of MYC and either Bcl-2 or Bcl-6.¹¹ Differentiation between the subtypes is important for clinical procedures because it informs the treatment decisions for and prognostic evaluation of DLBCL.⁵ In addition, the unique location of the tumour as well as the underlying genomic aberrations are highlighted in the 2016 revised WHO classification of lymphoid tumours.¹² Some novel separate entities of DLBCL, such as primary cutaneous DLBCL, leg type and high-grade B-cell lymphoma, are defined according to their distinct prognosis.¹² Therefore,

as PC-DLBCL is an extremely rare subset of extranodal lymphomas, it is worthwhile to investigate the clinical outcome and genomic aberrations of this malignancy.

Since it was defined as a distinct pathological categorization in 1978,¹ PCL has been increasingly addressed either in single case reports or in literature reviews.^{1,4,7-10} However, few studies have investigated both the clinical and pathologic characteristics of PC-DLBCL, especially in Eastern countries. Literatures were searched using “primary cardiac lymphoma” or “cardiac” or “lymphoma” in the databases of “Pubmed”, “China National Knowledge Infrastructure”, “Wanfang” and “Weipu”. Therefore, including the present case, a total of 14 cases of PC-DLBCL diagnosed from 1986 to 2018 in China and analysed with the Hans algorithm were reviewed in this study¹³ (Table 3). Our review showed that cases of PC-DLBCL more frequently occur in older, male patients (median age: 57 years, male: female=1.33:1), accompanied by poor prognostic factors such as cardiac

Table 2 Findings Of Single Nucleotide Polymorphism (SNP) Array Karyotyping Analysis

Chromosome Region	Genomic Coordinates (NCBI Build 37)	Size (Mb)			Interesting Genes
		Gain	Loss	LOH	
1q21.1q44	144,009,053→249,212,878	105.20		105.20	<i>BTG2, IRFZBP2, PCNX2</i>
3p26.3q11.2	63,411→96,922,673	96.86		96.86	<i>ROBO2, FANCD2, IRAK2</i>
3q11.2q13.11	96,922,673→103,136,123	6.21			<i>NFKB12</i>
3q13.11q29	103,136,123→197,852,564	94.72		94.72	<i>BCL6, PIK3CA, KLHL6, TP63</i>
5p15.33p14.3	38,139→20,054,865	20.02			N/A
6p25.3p22.2	204,909→26,205,293		26.00		<i>FOXC1, HIVEP1, ID4*,JARID2*,NOL7*,DUSP22*,CASC15*</i>
6p22.2p21.32	26,205,293→32,202,678			6.00	<i>TRIM27*,MHC class I gene*</i>
6q14.1q27	82,029,109→170,913,051		88.88		<i>HLA-A, HLA-B, HLA-C, BACH2, CASP8AP2, PRDM1, TNFAIP3 (A20), MAP3K5, ARID1B</i>
7q11.23q36.3	75,328,914→156,548,645	81.22			<i>CDK14</i>
11pterqter	1→135,086,622	135.09			<i>FGF4, CCND1, LOC283177</i>
12q24.31	121,738,241→123,989,250		2.25		<i>SETD1B, BCL7A*, CDK2AP1*, SETD8*, SETD1B*, RSRG2*</i>
15q14q21.2	36,120,789→51,472,245		15.35		<i>TP53BP1, B2M,SPRED1</i>
17p13.1	6,567,190→8,354,833		1.79		<i>TP53, XAF1*, MIR497*, BCL6B*, MIR324*, CLDN7*, KCTD11*, TNK1*, FGF11*, SOX15*</i>
17q11.1q12	25,326,941→34,477,480	81.22			N/A
18 pterqter	1→80,373,285	80.37			<i>BCL-2, MALTI</i>
19p13.3	247,232→1,362,613		1.12		<i>TNFSF7(CD70), TNFSF9, STK11*</i>
19q13.33q13.42	49,513,273→56,026,072	6.51			<i>PRMT1, BCL2L12, SPIB</i>
19q13.42q13.43	56,026,072→59,093,239		3.07		<i>ZNF471*, ZNF667*, ZNF671*, ZNF154*, ZNF132*, AIBG-AS1*</i>
Xq28	148,258,148→155,219,364	6.96			N/A
Y pterqter	1→57,227,415		57.23		N/A

Notes: *The interesting genes were not found to be reported related with DLBCL in literatures.

bulk and increased levels of lactate dehydrogenase (LDH), and no bone marrow involvement. The clinical features are consistent with those identified in a previous PC-DLBCL study in Western countries, except that Chinese patients seem to be younger than patients in Western countries.⁴ The tumour cells more frequently originated from the post-germinal center and were characterized by high proliferative activity (a higher Ki67 index and double expression of c-MYC and BCL2/BCL6). Both the ABC subtype and double expression of c-MYC and BCL2/BCL6 have been identified as markers of poor prognosis in DLBCL.^{11,14} There was no uniform recommendation on PC-DLBCL treatment. Surgery, radiotherapy and chemotherapy are the major

therapeutic strategies currently reported. Statistical analysis of treatment efficacy and survival in PC-DLBCL was lacking because of the rarity of this disease.⁴

Genomic aberrations provide clues on the causes underlying the poor outcome of PC-DLBCL; however, these findings have not been reported in previous studies. Due to the limitations of traditional cytogenetic studies (such as G-banding analysis) in biopsy samples, it is difficult to describe the compendium of chromosomal changes in lymphoma. Recently, SNP array analysis has been recommended to identify whole-genome aberrations in lymphoma, including CNVs as well as CN-LOH lesions.^{15,16} This method revealed the complex karyotype in the present case, including

Table 3 The Clinical And Pathological Features Of 14 PC-DLBCLs With Hans Algorithm In China

Parameters	Subgroup	Case Number
Age (years old) at diagnosis	>60	6
	≤60	8
Gender	Male	8
	Female	6
Size of cardiac mass	≥6cm	8
	<6cm	3
	N/A	3
Bone marrow involvement	Yes	0
	No	7
	N/A	7
LDH level>normal	Yes	8
	No	0
	N/A	6
Pathological subtype	GCB	4
	ABC	10
Ki67	≥70%	10
	<70%	1
	N/A	3
c-Myc expression	Positive	4
	Negative	0
	N/A	10
BCL2 expression	Positive	8
	Negative	3
	N/A	3
BCL6 expression	Positive	7
	Negative	5
	N/A	2
Double expression	Yes	4
	No	0
	N/A	10
Surgical resection	Yes	8
	No	4
	Orthotopic heart transplantation	2
Chemotherapy	Yes	11
	No	3

the 1q+, 3q+, 6q-, 7q- and 17p- CNVs, which have been reported in DLBCLs. Cryptic chromosomal losses rather than chromosomal gains were demonstrated by SNP array analysis. The set of affected genes included crucial tumour

suppressor genes (TSGs) in lymphomas, such as *TP53*, *SETD1B*, *TNFSF9* and *TNFSF7 (CD 70)*.^{5,17} Moreover, the analysis revealed unique CNVs that have been mentioned in previous studies but are of interest. For example, amplification of *SP1B* (19q33.33), inactivation of *PRDM1* (6q21), and loss of *HLA-A*, *HLA-B*, and *HLA-C* have been shown to be highly associated with the MCD (based on the co-occurrence of the *MYD88*^{L265P} and *CD79B* mutations) genetic subtype of DLBCL.⁶ Candidate oncogenes and TSGs located in the CNV and LOH regions according to the previous literature are listed in Table 2.^{6,17–20} It is worth noting that this case had copy number gains in *Bcl-6* and *Bcl-2*, which was the underlying mechanism for the dual expression of Bcl-6 and Bcl-2.

In recent years, genomic sequencing studies focusing on DLBCL have been performed, revealing the genetic mechanisms of lymphomagenesis, highlighting the molecular heterogeneity of the subtypes and identifying somatic mutations with therapeutic and prognostic effects, which will likely offer potential precision-medicine strategies in DLBCL.^{5,6,18,19,21,22} Twelve gene mutations contributing to lymphoma transformation and progression were identified in this study. Both the *MYD88* and *CD79B* mutations could be classified into the MCD genetic subtype; 96% of patients with this subtype have ABC subgroup DLBCL⁶ and show a trend of extranodal involvement, such as that in primary central nervous system lymphoma (PCNSL).²³ In addition, mutations in *CD79B*, *MYD88*, and *TBL1XR1* leading to abnormal NF-κB signalling activation may result in the lymphomagenesis of PC-DLBCL and serve as therapeutic targets.⁶ The novel targeted therapy drugs, including inhibitors of BTK, SYK, PKC, IRAK1/4 and PIM, could be replacement selections.^{24–27}

Conclusion

In summary, an integrated genomic evaluation procedure was adopted here to delineate the whole-genome abnormalities in a rare case of PC-DLBCL. The present case was diagnosed as PC-DLBCL, ABC subtype by the Hans algorithm and double expression lymphoma, MCD subtype by genetic alteration analysis. Although the patient acquired complete remission with chemotherapy, further follow-up is needed to reveal the influence of genomic aberrations on long-term survival. To our knowledge, the present case is unique because the use of whole exome sequencing and SNP array analysis to detect the genetic features of PC-DLBCL has not been reported to date. The results of our molecular examination provide new insights into the genomic characterization of PC-DLBCL.

Abbreviations

ABC, activated B-cell; CTA, computed tomographic angiography; CNVs, copy number variations; CN-LOH, copy-neutral loss of heterozygosity; ChAS, Chromosome Analysis Suite; ECG, electrocardiogram; FFPE, formalin-fixed paraffin-embedded; FISH, fluorescence in situ hybridization; GCB, germinal center B cell; IVC, inferior vena cava; LDH, lactate dehydrogenase; MCD, the co-occurrence of the *MYD88^{L265P}* and *CD79B* mutations; NGS, next-generation sequencing; PC-DLBCL, Primary cardiac diffuse large B cell lymphoma; PCL, Primary cardiac lymphoma; PET/CT, positron emission tomography/computed tomography; PCNSL, primary central nervous system lymphoma; R-CHOP, rituximab, cyclophosphamide, doxorubicin, vincristine, prednisone; SNP, single nucleotide polymorphism; SVC, superior vena cava; TSGs, tumour suppressor genes.

Ethical Approval

Written informed consent to have the case details published was obtained from the patient, and the study was approved by Ethics Committee of the First Affiliated Hospital of China Medical University.

Acknowledgement

This work was supported by the National Natural Science Foundation of China (grant number: 81600117).

Disclosure

The authors declare that they have no competing interests in this work.

References

- Petrich A, Cho SI, Billett H. Primary cardiac lymphoma: an analysis of presentation, treatment, and outcome patterns. *Cancer*. 2011;117(3):581–589. doi:10.1002/cncr.25444
- Hudzik B, Miszalski-Jamka K, Glowacki J, et al. Malignant tumors of the heart. *Cancer Epidemiol*. 2015;39(5):665–672. doi:10.1016/j.canep.2015.07.007
- Oliveira GH, Al-Kindi SG, Hoimes C, Park SJ. Characteristics and survival of malignant cardiac tumors: a 40-year analysis of >500 patients. *Circulation*. 2015;132(25):2395–2402. doi:10.1161/CIRCULATIONAHA.115.016418
- Carras S, Berger F, Chalabreysse L, et al. Primary cardiac lymphoma: diagnosis, treatment and outcome in a modern series. *Hematol Oncol*. 2017;35(4):510–519. doi:10.1002/hon.2301
- Chapuy B, Stewart C, Dunford AJ, et al. Molecular subtypes of diffuse large B cell lymphoma are associated with distinct pathogenic mechanisms and outcomes. *Nat Med*. 2018;24(5):679–690. doi:10.1038/s41591-018-0016-8
- Schmitz R, Wright GW, Huang DW, et al. Genetics and pathogenesis of diffuse large B-cell lymphoma. *N Engl J Med*. 2018;378(15):1396–1407. doi:10.1056/NEJMoa1801445
- Perrone MA, Intorcchia A, Morgagni R, et al. Primary cardiac lymphoma: the role of multimodality imaging. *J Cardiovasc Med (Hagerstown)*. 2018;19(8):455–458. doi:10.2459/JCM.0000000000000668
- Pistritto AM, Pavo N, Maurer G, Binder T, Goliasch G. Multimodality imaging of a primary cardiac diffuse large B-cell lymphoma. *Eur Heart J Cardiovasc Imaging*. 2015;16(8):909. doi:10.1093/ehjci/jev099
- Soon G, Ow GW, Chan HL, Ng SB, Wang S. Primary cardiac diffuse large B-cell lymphoma in immunocompetent patients: clinical, histologic, immunophenotypic, and genotypic features of 3 cases. *Ann Diagn Pathol*. 2016;24:40–46. doi:10.1016/j.anndiagpath.2016.05.005
- Wan Y, He D, Ye Y, et al. Primary cardiac diffuse large B-cell lymphoma with concurrent high MYC and BCL2 expression in an immunocompetent Chinese elderly woman. *Cardiovasc Pathol*. 2017;31:54–56. doi:10.1016/j.carpath.2017.07.006
- Menguy S, Frison E, Prochazkova-Carlotti M, et al. Double-hit or dual expression of MYC and BCL2 in primary cutaneous large B-cell lymphomas. *Mod Pathol*. 2018;31(8):1332–1342. doi:10.1038/s41379-018-0041-7
- Swerdlow SH, Campo E, Pileri SA, et al. The 2016 revision of the World Health Organization classification of lymphoid neoplasms. *Blood*. 2016;127(20):2375–2390. doi:10.1182/blood-2016-01-643569
- Zhang JJ, Zhang R, Li Y. Clinical characteristics of 37 cases of primary cardiac diffuse large B-cell lymphoma in China. *Oncol Prog*. 2019;17(18):2167–2171. doi:10.11877/j.issn.1672-1535.2019.17.18.17
- Staiger AM, Ziepert M, Horn H, et al. Clinical impact of the cell-of-origin classification and the MYC/BCL2 dual expresser status in diffuse large B-cell lymphoma treated within prospective clinical trials of the German high-grade non-Hodgkin's lymphoma study group. *J Clin Oncol*. 2017;35(22):2515–2526. doi:10.1200/JCO.2016.70.3660
- Pasqualucci L, Trifonov V, Fabbri G, et al. Analysis of the coding genome of diffuse large B-cell lymphoma. *Nat Genet*. 2011;43(9):830–837. doi:10.1038/ng.892
- Scholtysik R, Kreuz M, Hummel M, et al. Characterization of genomic imbalances in diffuse large B-cell lymphoma by detailed SNP-chip analysis. *Int J Cancer*. 2015;136(5):1033–1042. doi:10.1002/ijc.29072
- Etebari M, Navari M, Piccaluga PP. SNPs array karyotyping in non-Hodgkin lymphoma. *Microarrays (Basel)*. 2015;4(4):551–569. doi:10.3390/microarrays4040551
- Novak AJ, Asmann YW, Maurer MJ, et al. Whole-exome analysis reveals novel somatic genomic alterations associated with outcome in immunochemotherapy-treated diffuse large B-cell lymphoma. *Blood Cancer J*. 2015;5:e346. doi:10.1038/bcj.2015.69
- Mareschal S, Dubois S, Viailly P-J, et al. Whole exome sequencing of relapsed/refractory patients expands the repertoire of somatic mutations in diffuse large B-cell lymphoma. *Genes Chromosomes Cancer*. 2016;55(3):251–267. doi:10.1002/gcc.22328
- Trifonov V, Pasqualucci L, Dalla Favera R, Rabadan R. MutComFocal: an integrative approach to identifying recurrent and focal genomic alterations in tumor samples. *BMC Syst Biol*. 2013;7:25. doi:10.1186/1752-0509-7-25
- de Miranda NFCC, Georgiou K, Chen L, et al. Exome sequencing reveals novel mutation targets in diffuse large B-cell lymphomas derived from Chinese patients. *Blood*. 2014;124(16):2544–2553. doi:10.1182/blood-2013-12-546309
- Dubois S, Viailly P-J, Mareschal S, et al. Next-generation sequencing in diffuse large B-cell lymphoma highlights molecular divergence and therapeutic opportunities: a LYSA study. *Clin Cancer Res*. 2016;22(12):2919–2928. doi:10.1158/1078-0432.CCR-15-2305

23. Grommes C, Pastore A, Palaskas N, et al. Ibrutinib unmasks critical role of bruton tyrosine kinase in primary CNS lymphoma. *Cancer Discov.* 2017;7(9):1018–1029. doi:10.1158/2159-8290.CD-17-0613
24. Scott JS, Degorce SL, Anjum R, et al. Discovery and optimization of pyrrolopyrimidine inhibitors of interleukin-1 receptor associated kinase 4 (IRAK4) for the treatment of mutant MYD88L265P diffuse large B-cell lymphoma. *J Med Chem.* 2017;60(24):10071–10091. doi:10.1021/acs.jmedchem.7b01290
25. Lionakis MS, Dunleavy K, Roschewski M, et al. Inhibition of B cell receptor signaling by ibrutinib in primary CNS lymphoma. *Cancer Cell.* 2017;31(6):833–843.e5. doi:10.1016/j.ccell.2017.04.012
26. Kuo H-P, Ezell SA, Hsieh S, et al. The role of PIM1 in the ibrutinib-resistant ABC subtype of diffuse large B-cell lymphoma. *Am J Cancer Res.* 2016;6(11):2489–2501.
27. Younes A, Ansell S, Fowler N, et al. The landscape of new drugs in lymphoma. *Nat Rev Clin Oncol.* 2017;14(6):335–346. doi:10.1038/nrclinonc.2016.205

OncoTargets and Therapy

Dovepress

Publish your work in this journal

OncoTargets and Therapy is an international, peer-reviewed, open access journal focusing on the pathological basis of all cancers, potential targets for therapy and treatment protocols employed to improve the management of cancer patients. The journal also focuses on the impact of management programs and new therapeutic

agents and protocols on patient perspectives such as quality of life, adherence and satisfaction. The manuscript management system is completely online and includes a very quick and fair peer-review system, which is all easy to use. Visit <http://www.dovepress.com/testimonials.php> to read real quotes from published authors.

Submit your manuscript here: <https://www.dovepress.com/oncotargets-and-therapy-journal>