



Case report

Streptococcus pluranimalium infective endocarditis and brain abscessParikshit Duriseti^{a,*}, Jorge Fleisher^b^a Department of Medicine - St. Elizabeth's Medical Center, 736 Cambridge Street, Brighton, MA 02134, USA^b Division of Infectious Diseases, Department of Medicine - St. Elizabeth's Medical Center, 736 Cambridge Street, Brighton, Massachusetts, MA 02134, USA

ARTICLE INFO

Article history:

Received 31 May 2019

Received in revised form 30 June 2019

Accepted 1 July 2019

ABSTRACT

Infective endocarditis is an infection of the endocardium of the heart typically seen in individuals with underlying risk factors. We report a rare case of *Streptococcus pluranimalium* bacteremia causing infective endocarditis and brain abscess. Only 3 cases were reported in the literature on infective endocarditis in patients secondary to *S. pluranimalium*.

© 2019 The Authors. Published by Elsevier Ltd. This is an open access article under the CC BY-NC-ND license (<http://creativecommons.org/licenses/by-nc-nd/4.0/>).

Introduction

Streptococcus pluranimalium was first described by Devriese et al. in 1999 isolated from genital tract and tonsils of cattle, tonsils of a goat and a cat and the excreta and respiratory tract of canaries [1]. *S. pluranimalium* primarily causes infections in bovine and avian species. Clinicians should be aware of an increasing incidence of non-hemolytic Streptococcal infections causing hematogenous abscesses and endocarditis.

We describe a case of a 51-year-old non-IV drug user admitted to the medical service with *S. pluranimalium* bacteremia and subacute bacterial endocarditis.

Case presentation

A 51-year-old male non-IV drug user with a past medical history significant for mitral valve prolapse with severe mitral regurgitation presented to the emergency department with a 3-month history of dyspnea on exertion and intermittent fevers (up to 102 Fahrenheit) associated with chills. Review of systems was notable for night sweats, headache, nausea, vomiting, 15 lbs weight loss, fatigue, myalgias, and arthralgias for the past 3 months.

He presented to his primary care physician twice with symptoms and was prescribed 7-day course of levofloxacin each time. Both times after completing the course of the antibiotic, his symptoms briefly improved but subsequently relapsed.

Vitals on initial presentation included temp 102.1F, BP 124/66 mm Hg, RR 22, SaO₂ 98% on room air. Physical examination

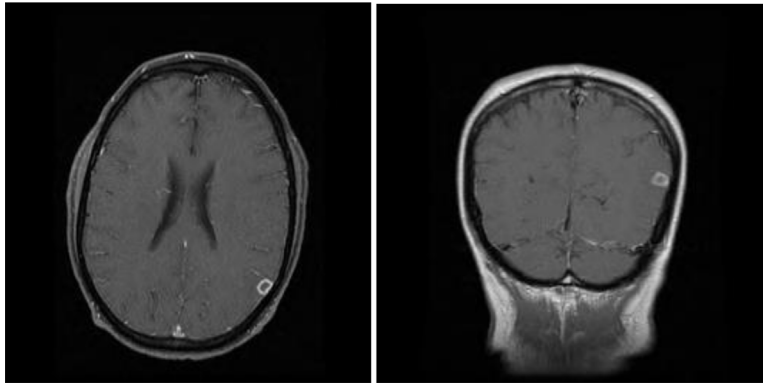
revealed poor dental hygiene with infection of the right upper molar; tender, erythematous nodules over the left little finger and right hypothenar eminence concerning for Osler's nodes; and grade 3/6 holosystolic murmur at the cardiac apex.

Laboratory evaluation was notable for a hemoglobin of 11.5 g/dl, white count of 10.2×10^3 /microL, ESR of 47 mm/hr, and CRP of 6.23 mg/dl. He had persistent bacteremia with blood cultures growing gram-positive cocci in chains identified as *Streptococcus pluranimalium* (which was confirmed by a reference lab). The organism was sensitive to ceftriaxone, ampicillin, benzylpenicillin, vancomycin and levofloxacin. He underwent a transesophageal echocardiogram (TEE) which showed an ejection fraction of 51% with severe mitral regurgitation and severe prolapse of the posterior leaflet of the mitral valve without any evidence of vegetations on mitral, aortic, tricuspid or pulmonary valves. MRI brain was performed showing a $9 \times 8.8 \times 7$ mm ring-enhancing lesion in the left parietal lobe and microhemorrhages in the right inferior cerebellum consistent with embolic phenomena. Diagnosis of definite infective endocarditis was made using the Modified Duke's Criteria with the patient meeting 5 minor criteria. Patient was started on IV ceftriaxone 2 gm daily for treatment. Neurosurgery consultation was obtained with concern raised for an abscess on brain MRI and conservative medical therapy was recommended.

After initiation of antibiotics, patients' symptoms improved with resolution of headache, fevers and myalgias though he continued to have mild arthralgias. He was treated with a 4-week course of IV ceftriaxone with clearance of bacteremia and resolution of his symptoms. He was discharged home with close follow-up. His surveillance blood cultures remained negative on follow-up with infectious disease. At 6 month and 1 year visits post-discharge, he remained asymptomatic without any recurrence of his symptoms.

* Corresponding author.

E-mail address: parikshit.duriseti@steward.org (P. Duriseti).



MRI brain with ring enhancing lesion within the left parietal region at the cortical surface of the brain measuring $9 \times 8.8 \times 7$ mm with associated edema and sulcal effacement

Discussion

Infective endocarditis is a potentially lethal infection of the endocardium of the heart most commonly seen in individuals with an underlying predisposing condition. In a prospective cohort study of adults with definite infective endocarditis, the most common predisposing conditions were related to valvular heart disease with degenerative valve disease being the most frequent native valve factor [2]. Other risk factors include illicit intravenous drug use, congenital and structural heart disease, and poor dental hygiene/dental infections.

Our patient had underlying mitral valve prolapse with severe mitral regurgitation placing him at risk for endocarditis. In a population-based study on the predictors of infective endocarditis, the incidence of endocarditis in patients with echocardiographic mitral valve prolapse was approximately 87 cases per 100,000 person-years, which represents approximately 8 times the risk in the general population. Patients with moderate to severe mitral regurgitation were at a notably higher risk of endocarditis compared to patients without mitral regurgitation [3].

Organisms most commonly implicated in endocarditis include *Staphylococcus aureus* and viridans group *Streptococci* [2]. Other pathogens associated with endocarditis include *Enterococci*, coagulase-negative *Staphylococci*, *Streptococcus galloyticus* (formerly *Streptococcus bovis*), other *Streptococci*, gram negative bacilli (*Pseudomonas*), HACEK group (*Haemophilus aphrophilus*, *Actinobacillus actinomycetemcomitans*, *Cardiobacterium hominis*, *Eikenella corrodens* and *Kingella kingae*) and pathogenic fungi. *S. aureus* is frequently associated with right-sided endocarditis (particularly involving the tricuspid valve) in patients with intravenous drug abuse. In addition, *S. aureus* commonly causes acute endocarditis in individuals with normal heart valves. On the other hand, viridans group *Streptococci* (which are part of the normal human flora in the oral cavity, gastrointestinal tract, skin and genital tract in females) are frequently associated with subacute bacterial endocarditis which commonly occurs following transient bacteremia in individuals with prosthetic heart valves or damaged heart valves secondary to structural or valvular heart disease. Rare causes of endocarditis include *Brucella*, *Coxiella burnetii*, *Lactobacillus* and *Corynebacterium*. Culture negative endocarditis is seen in about 2–9% of cases. There has been an increasing recognition of several non-hemolytic *Streptococci* species in human infections and their propensity to cause hematogenous abscesses and endovascular infections such as endocarditis.

Streptococcus pluranimalium was first described by Devriese et al. in 1999 isolated from genital tract and tonsils of cattle, tonsils of a goat and a cat and the excreta and respiratory tract of canaries [1]. *S. pluranimalium* is classified under unusual streptococcus species which includes streptococci which are not beta hemolytic and not part of the viridans group [4]. The organism has been associated with diseases in animals (primarily in bovine and avian species) causing septicaemia and valvular endocarditis in adult broiler parents [5], subclinical mastitis in cows [1] and purulent meningoventriculitis in a calf [6].

There are case reports in the literature linking *S. pluranimalium* to human infections. Paolucci et al describe *S. pluranimalium* being isolated in a patient with neutropenic fever (clinical history was not provided) [7]. Jacob et al describe a case of a 53-year-old female who presented with septic arthritis and septic shock eventually causing death with *S. pluranimalium* identified in blood and joint aspirate cultures [8]. Aryasinghe et al report a case of a 17-year-old male who presented with headache and was found to have subdural empyema with pus growing the organism [9]. Few case reports have described brain abscess secondary to the novel pathogen [10,11].

Only 3 cases have been reported in literature till date of endocarditis secondary to *S. pluranimalium*. Fotoglidis et al describe a case of left-sided endocarditis due to *S. pluranimalium* in a 37-year-old intravenous drug user with multiple peripheral arterial embolic events resulting in a fatal outcome despite antibiotic and surgical management [12]. Second case report published by Muñoz Ortiz et al describes a 25-year-old male with down syndrome and severe mental retardation in contact with various farm animals diagnosed with *S. pluranimalium* endocarditis associated with immune mediated glomerulonephritis. Patient survived with antibiotic therapy and surgery [13]. A third case reports aortic ring abscess caused by the organism in a non-IV drug user who was successfully treated with antibiotic therapy. The patient was reported to have contact with chickens [14].

The exact mechanism of infection by *S. pluranimalium* remains unknown. Our patient worked in an auto repair shop, had an indoor cat and had no exposure to farm animals. Dhotre S et al report *S. pluranimalium* being isolated from subgingival dental plaque of a patient with periodontitis following tooth extraction [15]. An extensive literature review revealed that the bacterium was isolated from a blood culture in a patient after dental piezocision procedure following transient bacteremia (with negative blood culture before the procedure) [16]. It is unclear if *S. pluranimalium* could potentially be a part of the normal oral flora functioning as a commensal causing transient bacteremia secondary to poor dentition and/or dental procedures. Bacteremia following dental procedures has been well documented which forms the basis for antibiotic prophylaxis in high risk patients

undergoing dental procedures [17]. Cumulative bacteremia secondary to poor dental hygiene and periodontal/gingival infections in the absence of dental procedures has been associated with the risk of infective endocarditis [18,19]. Cumulative bacteremia in such cases occurs following trivial activities such as tooth brushing, flossing or chewing in the setting of increased plaque burden due to poor dentition or dental infections.

The diagnosis of infective endocarditis is frequently established with Modified Duke's criteria. The criteria are a helpful diagnostic tool which has to be used in conjunction with clinical judgement to make a diagnosis. Our patient had 0 major criteria and 5 minor criteria meeting the diagnosis of definite infective endocarditis. It is crucial to remember that the absence of a vegetation (or other echocardiographic findings described in the major criterion) does not rule out infective endocarditis or eliminate the possibility of systemic embolism. A thorough physical examination helped in making a diagnosis of endocarditis in our patient.

This case aims to remind physicians of novel pathogens emerging as a cause of endocarditis and to have a high clinical suspicion of endocarditis in patients with predisposing risk factors.

Author statement

We report a rare case of endocarditis causing by *Streptococcus pluranimalium*. We have performed an extensive literature review on human infections secondary to this unusual streptococcus to attempt to elucidate novel pathogens emerging as cause of endocarditis.

References

- [1] Devriese LA, Vandamme P, Collins MD, Alvarez N, Pot B, Hommez J. *Streptococcus pluranimalium* sp. nov.: from cattle and other animals. *Int J Syst Bacteriol* 1999;49(3):1221–6.
- [2] Murdoch DR, Corey GR, Hoen B, Miró JM, Fowler [47_TD\$DIFF]r VG, Bayer AS, et al. Clinical presentation, etiology, and outcome of infective endocarditis in the 21st century: the International Collaboration on Endocarditis-Prospective Cohort Study. *Arch Intern Med* 2009;169:463–73.
- [3] Katan Ognjen, Michelena Hector I, Avierinos Jean-Francois, Mahoney Douglas W, DeSimone Daniel C, Baddour Larry M, et al. Incidence and predictors of infective endocarditis in mitral valve prolapse: a population-based study. *Mayo Clin Proc* 2016;91(March (3)):336–42.
- [4] Facklam Richard. What happened to the streptococci: overview of taxonomic and nomenclature changes. *Clin Microbiol Rev* 2002;15 (October (4)):613–30.
- [5] Hedegaard LI, Christensen H, Chadfield MS, Christensen JP, Bisgaard M. Association of *Streptococcus pluranimalium* with valvular endocarditis and septicemia in adult broiler parents. *Avian Pathol* 2009;38(April (2)):155–60.
- [6] Seimiya YM, Takahashi M, Kudo T, Sasaki K. Meningoventriculitis caused by *Streptococcus pluranimalium* in a neonatal calf of premature birth. *J Vet Med Sci* 2007;69(6):657–60.
- [7] Paolucci M, Stanzani M, Melchionda F. Routine use of a real-time polymerase chain reaction method for detection of bloodstream infections in neutropenic patients. *Diagn Microbiol Infect Dis* 2013;75:130–4.
- [8] Jacob E, Kiran S, Jithendranath A, et al. *Streptococcus pluranimalium*-close encounter of a new kind internet. [Accessed 3 Jan 2015]. Available at: http://www.japi.org/oral_Feb_2014/poster_Infectious_Diseases.html.
- [9] Aryasinghe L, Sabbar S, Kazim Y. *Streptococcus pluranimalium*: a novel human pathogen? *Int J Surg Case Rep* 2015;5:1242–6.
- [10] Maher G, Beniwal M, Bahubali V, Biswas S, Bevinahalli N, Srinivas D, et al. *Streptococcus pluranimalium*: emerging animal streptococcal species as causative agent of human brain abscess. *World Neurosurg* 2018;115(July)208–12. doi:<http://dx.doi.org/10.1016/j.wneu.2018.04.099> Epub 2018 Apr 22.
- [11] Ahmed A, Zaman G, Gardezi A, Satti L, Sabir N, Haleem A. Cerebral abscess caused by novel species: *streptococcus pluranimalium*. *J Coll Phys Surg Pak* 2018;28(September (9)):S181–3. doi:<http://dx.doi.org/10.29271/jcpsp.2018.09.S181>.
- [12] Photoglidis A, Pagourelis E, Kyriakou P. Endocarditis caused by unusual *Streptococcus* species (*Streptococcus pluranimalium*). *Hippokratia* 2015;19:182–5.
- [13] Muñoz Ortiz E, Ramírez Urrea JH, Atehortúa Muñoz S, Arévalo Guerrero EF. Infective endocarditis by *Streptococcus pluranimalium*: case report [Article in Spanish]. *Arch Cardiol Mex* 2016;86(October–December (4)):383–4.
- [14] Kindo Anupma Jyoti, Tharmalingam Divya, Sekar Uma, Nagarjuna G, Muralidharan TR, Thanikachalam S. Aortic ring abscess caused by *Streptococcus pluranimalium*: a case report. *J Acad Clin Microbiol [serial online]* 2015;17:127–9 [cited 2019 May 31].
- [15] Dhotre S, Suryawanshi N, Nagoba B, Selkar S. Rare and unusual isolates of viridans streptococci from the human oral cavity. *Indian J Pathol Microbiol* 2016;59(January–March (1)):47–9.
- [16] Ileri Z, Akin M, Erdur EA, Dagi HT, Findik D. Bacteremia after piezocision. *Am J Orthod Dentofacial Orthop* 2014;146(October (4)):430–6.
- [17] Parahitiyawa NB, Jin LJ, Leung WK, Yam WC, Samaranyake LP. Microbiology of odontogenic bacteremia: beyond endocarditis. *Clin Microbiol Rev* 2009;22 (January (1)):46–64.
- [18] Lockhart Peter B, Brennan Michael T, Thornhill Martin, Michalowicz Bryan S, Noll Jenene, Bahrani-Mougeot Farah K, et al. Poor oral hygiene as a risk factor for infective endocarditis-related bacteremia. *J Am Dent Assoc* 2009;140 (October (10)):1238–44.
- [19] Lockhart PB, Brennan MT, Sasser HC, Fox PC, Paster BJ, Bahrani-Mougeot FK. Bacteremia associated with toothbrushing and dental extraction. *Circulation* 2008;117(June (24)):3118–25.