

PEDIATRIC UROLOGY
ORIGINAL ARTICLE

Influence of postnatal hydroureter in determining the need for voiding cystourethrogram in children with high-grade hydronephrosis

Amr Hodhod^{a,b,*}, John-Paul Capolicchio^a, Roman Jednak^a, Eid El-Sherif^b,
Abd El-Alim El-Doray^b, Mohamed El-Sherbiny^a

^a Departments of Surgery and Pediatric Surgery, Montreal Children's Hospital, McGill University, Montreal, Quebec, Canada

^b Department of Urology, Faculty of Medicine, Menoufia University, Al Minufya, Egypt

Received 29 September 2017, Received in revised form 26 October 2017, Accepted 7 November 2017

Available online 13 December 2017

KEYWORDS

Voiding cystourethrography;
Congenital hydronephrosis;
Vesico-ureteric reflux;
Pelvi-ureteric junction obstruction

ABBREVIATIONS

APD, antero-posterior diameter;
CI, confidence interval;
fUTI, febrile UTI;
OR, odds ratio;
PH, postnatal hydro-

Abstract Objective: To evaluate the utility of hydroureter (HU) to identify high-grade vesico-ureteric reflux (VUR) in patients with high-grade postnatal hydronephrosis (PH).

Patients and methods: We retrospectively reviewed patients' charts that had antenatal hydronephrosis from 2008 to 2014. Patients were excluded if they presented with febrile urinary tract infection (fUTI), neurogenic bladder, posterior urethral valve, multi-cystic dysplastic kidney, and multiple congenital malformations. We reviewed postnatal ultrasonography images and patients with Society of Fetal Urology (SFU) Grades 3 and 4 hydronephrosis with a renal pelvic antero-posterior diameter of ≥ 10 mm were included. The ureter was assessed and considered dilated if the ureteric diameter was ≥ 4 mm. The voiding cystourethrogram (VCUG) studies, fUTI incidence, and surgical reports were reviewed.

Results: Of the 654 patients reviewed, we included 148 patients (164 renal units) of whom 113 (76.4%) were male and 35 (23.6%) female. SFU Grade 3 PH was identified in 49% of the renal units, with the remaining 51% being SFU Grade 4. HU was found in 50/164 renal units and was not detected in the remaining 114 units. VUR was diagnosed in four units (3.5%) without HU (low-grade VUR); whilst it

* Corresponding author at: Departments of Surgery and Pediatric Surgery, McGill University, The Montreal Children's Hospital, Room B04.2916.1 GLEN, 1001 Boulevard Décarie, Montréal, QC H4A 3J1, Canada.

E-mail address: amr.hodhod@mail.mcgill.ca (A. Hodhod).

Peer review under responsibility of Arab Association of Urology.



Production and hosting by Elsevier

nephrosis;
 NU, normal ureter;
 HU, hydroureter;
 HGH, high-grade
 postnatal hydrone-
 phrosis;
 (N)(P)PV, (negative)
 (positive) predictive
 value;
 SFU, Society for Fetal
 Urology;
 PUJO, PUJ obstruc-
 tion;
 US, ultrasonography;
 VCUg, voiding cysto-
 urethrogram

was detected in 19 units (38%) with HU (72.7% were high-grade VUR) ($P < 0.001$). VUR was diagnosed on the contralateral side in four/105 patients with PH without HU and diagnosed in 10/43 patients with PH with HU ($P < 0.001$). During a median follow-up of 25.9 months, none of the renal units that had VUR without HU developed UTI or had surgeries.

Conclusion: Low-grade uncomplicated VUR was diagnosed in 3.5% of renal units without HU. Our results support limiting the use of VCUg to renal units with PH if associated with HU.

© 2017 Production and hosting by Elsevier B.V. on behalf of Arab Association of Urology. This is an open access article under the CC BY-NC-ND license (<http://creativecommons.org/licenses/by-nc-nd/4.0/>).

Introduction

Antenatal hydronephrosis is one of the most common congenital anomalies being diagnosed in 1–5% of all pregnancies [1]. PUJ obstruction (PUJO) has been found to be the most common cause of high-grade postnatal hydronephrosis (HGH) [2]. When primary PUJO is associated with VUR, low-grade reflux predominates [3]. On the other hand, high-grade VUR associated with secondary PUJO is more often associated with dilated tortuous ureter [3,4].

Most available protocols for the management of HGH recommend a voiding cystourethrogram (VCUG) for all patients [1,5]. However, when VUR coexists with HGH without hydroureter (HU), it is of low-grade and tends to resolve spontaneously after surgery [3]. Hence, for better utilisation of resources, the re-evaluation of the role of VCUg in the evaluation of HGH is warranted.

Our hypothesis was that in HGH, the absence of HU on ultrasonography (US) excludes high-grade VUR in the vast majority of cases, thus precluding the need for VCUg in the primary assessment of these patients. Therefore, in the present study, we evaluated patients with HGH and correlated the findings of VCUg with the presence or absence of HU.

Patient and methods

Review of patients' charts was initiated after receiving the approval of the Local Review Board. We retrospectively reviewed all patients' data presented to our tertiary care institution with antenatal hydronephrosis from January 2008 to June 2014. We included only patients who had presented in the first year of life. Renal units with single renal system were only included. We excluded patients who presented initially with febrile UTI (fUTI), neurogenic bladder, posterior urethral

valve, multi-cystic dysplastic kidney, and patients with multiple congenital malformations.

We collected patients' demographic data, side of hydronephrosis, and laterality. Postnatal renal US images were reviewed by a single investigator (A.H). All investigations were blindly reviewed in relation to the outcome. All abdominal US sessions within the first year of life were reviewed. Ureteric diameter and renal pelvic antero-posterior diameter (APD) were measured in every US. Findings with the highest values were recorded. We only included patients with Society of Fetal Urology (SFU) Grade 3 and 4 postnatal hydronephrosis (PH) with a renal pelvic antero-posterior diameter (APD) of ≥ 10 mm. Renal units with a renal pelvic APD of ≥ 10 mm were recruited, as the Society for Pediatric Urology (SPU) consensus considered postnatal renal pelvis dilatation of > 10 mm to be more suggestive of PUJ pathology [6]. The renal pelvic APD was measured in the transverse plane of the kidney. SFU Grade 3 was defined as diffuse calyceal dilatation without parenchymal thinning and SFU Grade 4 was considered when calyceal dilatation was associated with parenchymal thinning [7]. Moreover, the status of the retro-vesical ureter was evaluated. The ureter was measured, if it could be visualised in any of the reviewed US images, in the transverse plane. When the ureter was not visualised, we considered its diameter to be 0 mm. The mean ureteric diameter up to the age of 3 years usually does not exceed 4 mm [8,9]. Hence, if the ureteric diameter was ≥ 4 mm with a full bladder, we considered it to be HU.

Cyclic VCUg was carried out in all patients, aiming to detect occult VUR that might not appear in standard VCUg [10]. Cyclic VCUg was performed with two consecutive fillings of contrast according to bladder capacity according to age. VUR was looked for during the filling and voiding phases then, if present, the grade of VUR was recorded. We graded VUR according to the International classification of VUR [11]. Surgical

reports were also reviewed regarding the type of operation. Moreover, the clinical diagnosis was collected and follow up period was calculated.

Those with HGH without a dilated ureter were considered as isolated PH. PUJO was only considered if patient underwent pyeloplasty.

Finally, the incidence of fUTI was recorded and was defined as a fever $> 39^{\circ}\text{C}$ associated with pyuria and urine culture identified a single pathogen of $> 50\,000$ colony-forming units/mL. Urine samples for culture were obtained through catheterisation. The incidence of UTI was obtained from patients' charts and urine culture reports.

Our primary measure was to evaluate the absence of HU associated with a renal pelvic APD of ≥ 10 mm as a predictor of the absence of ipsilateral high-grade VUR. Our secondary analysis was to report the incidence of surgical interventions and fUTI occurrence of HGH with HU and those with normal ureter (NU).

Patients with VUR had antibiotic prophylaxis if high grade (Grade 4 or 5), complicated with fUTI. All patients with suspected PUJO and associated with VUR received antibiotic prophylaxis.

Statistical analysis was done using the Statistical Package for the Social Sciences (SPSS®, version 20; SPSS Inc., IBM Corp., Armonk, NY, USA). The VCUG results, type of surgical intervention, and the incidence of fUTI were correlated to the presence or absence of HU. Categorical data were evaluated using the chi-squared test and continuous data were evaluated with the Mann–Whitney *U*-test. Logistic regression was used to calculate the odds ratio (OR) to evaluate the likelihood of VUR in the presence of HU. Moreover, the ability of ipsilateral HU on US to predict VUR in HGH was evaluated for the sensitivity, specificity, positive (PPV) and negative (NPV) predictive values. A $P \leq 0.05$ was considered statistically significant.

Results

Of the 654 patients reviewed, 148 patients (164 renal units) were included (Fig. 1). We excluded patients with initial fUTI (15 patients), neurogenic bladder (seven), posterior urethral valve (four), multi-cystic dysplastic kidney (five), and genetic or multiple congenital malformations (14).

Patients' demographics

We included 113/148 (76.4) males and 35/148 (23.6) females. In all, 70% of the included renal units were on the right side (115/164) and 30% were on the left (49/164). The median (range) age at presentation was 14 (1–350) days. In all, 81 renal units (49%) were SFU Grade 3 and the remaining 83 (51%) were SFU Grade 4. In all, 51% (76/148) of the patients had unilateral

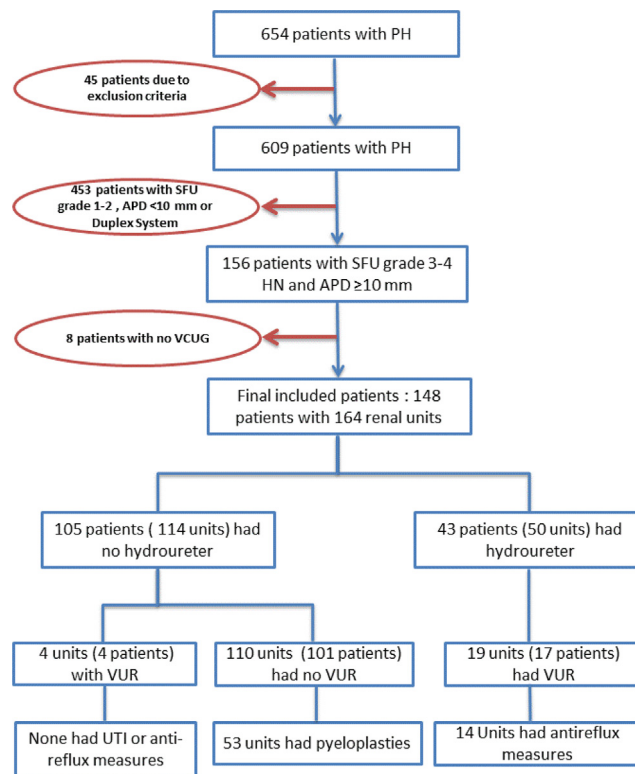


Fig. 1 Flowchart of study design.

PH and 49% (72/148) had bilateral PH. Of the patients with bilateral PH, only 16/72 patients (32 units) had bilateral SFU Grade 3 or 4 PH and the rest (56/72) had only SFU Grade 3 or 4 PH on one side and a lesser degree of PH on the other side.

The median (range) renal pelvic APD was 15 (10–48) mm. HU was detected by US in 50/164 renal units in 44 patients (30.5%) with a median (range) ureteric diameter of 9 (4.8–18) mm.

VUR

Of 21 patients who were diagnosed with VUR, two had bilateral VUR. VUR was diagnosed in 13/113 males (11.5%) and eight/35 females (22.9%) ($P = 0.09$).

For patients with NU, VUR was detected in only four/114 renal units (3.5%); whilst in the presence of HU, VUR was detected in 19/50 renal units (38%) ($P < 0.001$). The median (range) ureteric diameter for refluxing HU units was 10 (4.8–18) mm (Fig. 2), and 74% (14/19) of refluxing renal units were high grade. Notably, all units with VUR detected without HU were low grade (Table 1); and refluxing ureters were neither dilated nor tortuous on VCUG.

Moreover, VUR was diagnosed on the contralateral side in four/105 (3.85%) patients with NU and in 10/43 (23.2%) with HU ($P < 0.001$). Clinical diagnoses, with ureteric diameters, were identified and tabulated (Table 2).

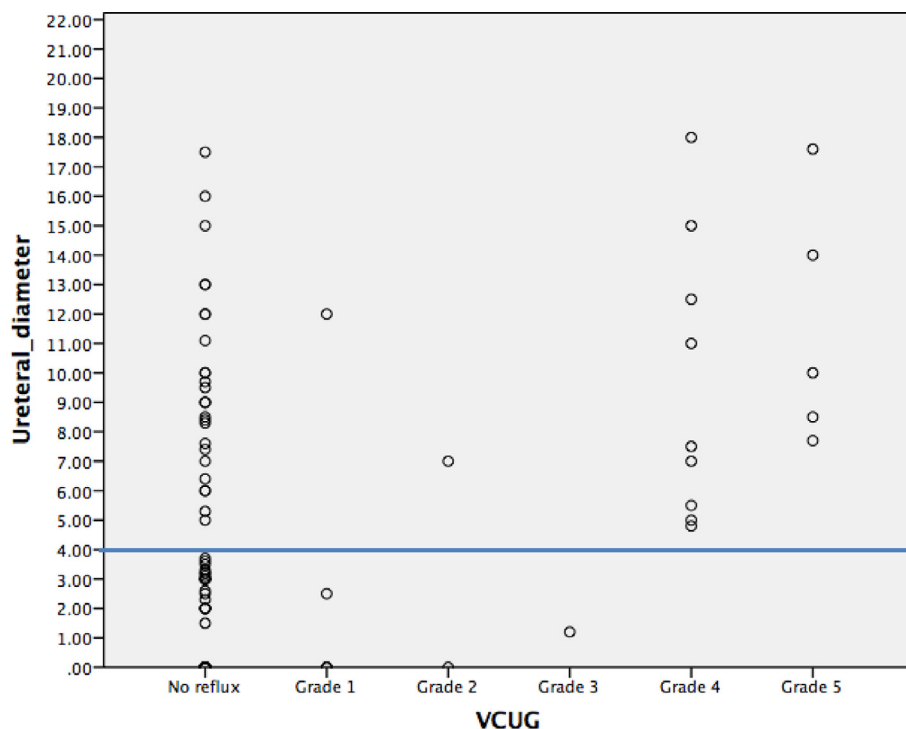


Fig. 2 Scatterplot of the grade of VUR in relation to ureteric diameter. A line is drawn at 4 mm diameter, i.e. limit of NU size.

Table 1 Grades of VUR (per renal unit) in relation to dilated ureter and SFU grading.

VCUG	PH with HU			PH with NU		
	SFU Grade 3	SFU Grade 4	Total	SFU Grade 3	SFU Grade 4	Total
No reflux	16	15	31	53	57	110
Grade 1	0	2	2	2	0	2
Grade 2	1	0	1	1	0	1
Grade 3	2	0	2	1	0	1
Grade 4	4	5	9	0	0	0
Grade 5	1	4	5	0	0	0
Total renal units	24	26	50	57	57	114
Refluxing units	8	11	19	4	0	4

Table 2 Clinical diagnoses with ureteric diameters after initial investigations (renal units).

Diagnosis	HU		NU		Total, n (%)
	N (%)	Ureteric diameter, mm, median (range)	N (%)	Ureteric diameter, mm, median (range)	
PUJO or isolated PH*	5 (10)	7.85 (5–10)	110 (96.5)	0 (0–3.7)	115(70.1)
VUR	13 (26)	7.7 (4.8–17.6)	0 (0)	–	13 (7.9)
Non-refluxing megaureter	27 (54)	8.5 (7–17.5)	0 (0)	–	27 (16.5)
Concomitant VUR and PUJO	2 (4)	15 (12–18)	4 (3.5)	0 (0–0)	6 (3.7)
Ureterocele	3(6)	9 (8.5–10)	0 (0)	–	3 (1.8)
Total	50 (100)		114 (100)		164 (100)

* 56 patients (53 NU and 3 HU) were confirmed to have PUJO.

Two HU renal units were diagnosed as concomitant PUJO and VUR and had ureteric diameters of 12 and 16 mm. Conversely, ureteric diameters for NU units with the same diagnosis were 0 mm.

Using logistic regression analysis, NU units were less likely to have VUR (OR 0.125, 95% CI 0.046–0.339). Low-grade VUR was likely to be associated with a dilated ureter if associated with HGH (OR 0.026, 95% CI 0.002–0.341).

Sensitivity of US in VUR prediction in patients with HU was 82.6% (95% CI 61.2–95.1%), whilst the specificity was 78% (95% CI 70.3–84.6%), the PPV was 38% and the NPV was 96.5%. However, US had 100% sensitivity (95% CI 85–100%) and 88% specificity (95% CI 80.4–93.1%) for detection of high-grade VUR in patients with HU, with a PPV of 66.7% and NPV of 100%.

Antibiotic prophylaxis

In all, 74% of patients with HU (32/43) received antibiotic prophylaxis in comparison to 45% (47/105) of those with NU ($P = 0.001$). Notably, all patients with VUR, either associated with HU or NU, had antibiotic prophylaxis. Patients with HU who had VUR had a median (range) antibiotic prophylaxis duration of 13 (5–48) months. Of patients with NU and VUR, three units (in three patients) had surgical interventions (pyeloplasties) and received a median (range) duration of antibiotic prophylaxis of 6 (5–12) months.

fUTI

The median (range) follow-up period was 25.9 (11.2–83.4) months. fUTI was reported in 12/104 NU patients (11.5%) and 16/44 HU patients (36.4%) during follow-up ($P < 0.001$). Notably, all patients with NU with VUR did not have UTIs during follow-up. Three of 12 patients with NU and six of 16 patients with HU (38%) who had UTIs were on antibiotic prophylaxis.

Surgical outcome (Table 3)

In all, 46% (76/164) of the renal units were treated surgically. Surgical intervention was necessary in 44% (22/50) of renal units with HU and in 47.4% (54/114) of NU renal units ($P = 0.707$). It was noted that bilateral HGH with NU had a higher incidence of surgical intervention ($P = 0.03$). Pyeloplasty was the most commonly performed surgery (98.1%) for renal units with NU (53/54 units). Anti-reflux measures were performed in 14/22 renal units associated HU (63.6%) and not reported for renal units with NU. The remaining HU units that did not undergo surgical management (28/50 units) were managed conservatively. Of these remaining units, six of 28 units (21.5%) had fUTI during follow-

Table 3 Type of surgery in relation to presence or absence of HU.

Surgery	HGH with HU, n (%)	HGH with NU, n (%)	Total, n (%)
Anti-reflux measures	14 (63.6)	0	14 (18.4)
Pyeloplasty	3 (13.65)	53 (98.1)	56 (73.7)
Nephrectomy	2 (9.1)	1 (1.9)	3 (3.95)
Ureterocele incision	3 (13.65)	0	3 (3.95)
Total, n (%)	22 (100)	54 (100)	76 (100)

up. Prophylactic antibiotics were prescribed for five of these six units. We noted that NU units with VUR, either on the ipsilateral or the contralateral side, did not receive any type of surgical intervention. For HU units with concomitant PUJO and VUR (two units), one unit had pyeloplasty and the other underwent re-implantation.

Discussion

Despite VUR generally being more prevalent than PUJO, PUJO or isolated hydronephrosis is the most common pathology in moderate and severe hydronephrosis [2]. Many published reports have shown the association between PUJO and VUR, and all endorse the futility of VCUG if PUJO is associated with NU. However, none reported the importance of VCUG in HGH globally, not only PUJO, in respect of the presence of a dilated ureter [3,12,13]. In the present study, we evaluated the value of ureteric dilatation for excluding VUR in renal units with HGH.

Ureteric diameter is usually < 4 mm in the first 3 years of life [8,9]. Fernbach et al. [7] proposed a grading system for HU and defined the lowest grade as a diameter of < 7 mm. However, after a literature review, we found no data that this classification was further evaluated or used. Leroy et al. [4] considered HU when visualised retrovesically. In the present study, we considered HU if the retrovesical ureter exceeded the mean diameter.

The importance of HU detection with US had been presented in the literature [4,14–16]. Leroy et al. [4] concluded that high-grade VUR was found to be associated with dilated ureters with 73% sensitivity and 88% specificity. Furthermore, another study stated that 63% of patients could avoid VCUG using the criteria of HU, renal duplication, and dysmorphia [17]. HU was evaluated in a paediatric population with UTI and was identified as being a helpful tool in VUR detection [15]. Moreover, Logvinenko et al. [16] found that ureteric dilatation had a predictive value for VUR Grade > 2 in children with UTI. In our present study, HGH, renal pelvic APD of > 10 mm, and NU had 96.5% NPV for VUR and 100% NPV for high-grade VUR.

In the present study, despite 76% of included patients being male, females had twice the chance of getting VUR than males. Chand et al. [18] reported the same percentage of VUR incidence.

Lee et al. [17] reported that HU, in association with any grade of pH, was an independent predictor of VUR. Moreover, of the patients who underwent pyeloplasty, three patients had concomitant low-grade VUR. Interestingly, none of these patients had a UTI after pyeloplasty. None of our patients who underwent pyeloplasty and had associated VUR had UTIs during follow-up.

Concomitant PUJO and VUR are uncommon, with 8–11% of patients diagnosed initially as PUJO [3,19]. In our present study, concomitant PUJO and VUR represented 3.65% of HGH. All our patients who had suspected PUJO and VUR received antibiotic prophylaxis, as refluxing could result in pyonephrosis.

The association of PUJO and VUR can be classified into three groups: Group 1, includes primary PUJO that is associated with low-grade reflux; Group 2, contains PUJO secondary VUR; and patients with VUR associated with pseudo PUJO (non-obstructive renogram) constitute Group 3 [20]. VUR and PUJO are independent in Group 1 and mostly resolve spontaneously [20]. VUR Grades ≥ 3 are associated with a dilated pelvicalyceal system and ureter [4,21]. Despite undocumented VUR resolution, our present results showed that all patients with PUJO who had NU with VUR did not develop any complications during the 30.1 months of follow-up.

Kim et al. [3] stated that low-grade VUR coexisting with PUJO usually disappears after pyeloplasty. Furthermore, they reported that low-grade VUR was not detected with US, whilst US easily detected high-grade VUR [3]. Our present results showed that the ureter could not be visualised in all renal units with low-grade VUR. Moreover, 14/19 (73.4%) HU units with VUR were either Grade 4 or 5.

The importance of VCUg in the assessment of pH is still debatable. Some still recommend VCUg for screening of pH [22,23]. Others favour limiting the use of VCUg due to low clinical significance [24,25]. Complications of VCUg are numerous and unavoidable despite precautions [26] and include: ascending infection, urethral or bladder injury, radiation exposure, and renal pain in addition to sedation side-effects [27].

A previous study at our institute found that VCUg is of limited use in terms of VUR screening for low-grade PH [24]. The present study showed that the criteria of NU with a renal pelvic APD of ≥ 10 mm had a high NPV for the presence of VUR. Therefore, carrying out VCUg had limited usefulness in assessment of HGH with NU and also may be hazardous for the patient and wasteful of medical resources.

The present study had some limitations. First, the nature of the study is retrospective. The follow-up period is relatively short. Thus, long-term studies are warranted to evaluate the incidence of UTI in the absence of HU.

Conclusion

Renal units with HGH, NU and renal pelvic APD of > 10 mm on US have a high NPV for the presence of VUR, suggesting the diagnosis of isolated PH. Hence, in the absence of HU, VCUg is of limited value in the assessment of HGH.

Conflict of interest

None.

References

- [1] Lee RS, Cendron M, Kinnamon DD, Nguyen HT. Antenatal hydronephrosis as a predictor of postnatal outcome: a meta-analysis. *Pediatrics* 2006;**118**:586–93.
- [2] Passerotti CC, Kalish LA, Chow J, Passerotti AM, Recabal P, Cendron M, et al. The predictive value of the first postnatal ultrasound in children with antenatal hydronephrosis. *J Pediatr Urol* 2011;**7**:128–36.
- [3] Kim YS, Do SH, Hong CH, Kim MJ, Choi SK, Han SW. Does every patient with ureteropelvic junction obstruction need voiding cystourethrography? *J Urol* 2001;**165**:2305–7.
- [4] Leroy S, Vantalou S, Larakeb A, Ducou-Le-Pointe H, Bensman A. Vesicoureteral reflux in children with urinary tract infection: comparison of diagnostic accuracy of renal US criteria. *Radiology* 2010;**255**:890–8.
- [5] Psooy K, Pike J. Investigation and management of antenatally detected hydronephrosis. *Can Urol Assoc J* 2009;**3**:69–72.
- [6] Nguyen HT, Benson CB, Bromley B, Campbell JB, Chow J, Coleman B, et al. Multidisciplinary consensus on the classification of prenatal and postnatal urinary tract dilation (UTD classification system). *J Pediatr Urol* 2014;**10**:982–98.
- [7] Fernbach SK, Maizels M, Conway JJ. Ultrasound grading of hydronephrosis: introduction to the system used by the Society for Fetal Urology. *Pediatr Radiol* 1993;**23**:478–80.
- [8] Hellström M, Hjälmås K, Jacobsson B, Jodal U, Odén A. Normal ureteral diameter in infancy and childhood. *Acta Radiol Diagn (Stockh)* 1985;**26**:433–9.
- [9] Cussen LJ. Dimensions of the normal ureter in infancy and childhood. *Invest Urol* 1967;**5**:164–78.
- [10] Papadopoulou F, Efremidis SC, Oiconomou A, Badouraki M, Panteleli M, Papachristou F, et al. Cyclic voiding cystourethrography: is vesicoureteral reflux missed with standard voiding cystourethrography? *Eur Radiol* 2002;**12**:666–70.
- [11] Lebowitz RL, Olbing H, Parkkulainen KV, Smellie JM, Tamminen-Möbius TE. International system of radiographic grading of vesicoureteric reflux. International Reflux Study in Children. *Pediatr Radiol* 1985;**15**:105–9.
- [12] Hubertus J, Plieninger S, Martinovic V, Heinrich M, Schuster T, Bürst M, et al. Children and adolescents with ureteropelvic junction obstruction: is an additional voiding cystourethrogram necessary? Results of a multicenter study. *World J Urol* 2013;**31**:683–7.
- [13] ElSheemy MS, Ghoneima W, Abdelwahhab M, Aboulela W, Daw K, Shouman AM, et al. The role of voiding cystourethrog-

- raphy in asymptomatic unilateral isolated ureteropelvic junction obstruction: a retrospective study. *J Pediatr Urol* 2017;**13**(206):e1–7.
- [14] Oliveira EA, Diniz JS, Rabelo EA, Silva JM, Pereira AK, Filgueiras MT, et al. Primary megaureter detected by prenatal ultrasonography: conservative management and prolonged follow-up. *Int Urol Nephrol* 2000;**32**:13–8.
- [15] Park YW, Kim MJ, Han SW, Kim DW, Lee MJ. Meaning of ureter dilatation during ultrasonography in infants for evaluating vesicoureteral reflux. *Eur J Radiol* 2015;**84**:307–11.
- [16] Logvinenko T, Chow JS, Nelson CP. Predictive value of specific ultrasound findings when used as a screening test for abnormalities on VCUG. *J Pediatr Urol* 2015;**11**(176):e1–7.
- [17] Lee NG, Rushton HG, Peters CA, Groves DS1, Pohl HG. Evaluation of prenatal hydronephrosis: novel criteria for predicting vesicoureteral reflux on ultrasonography. *J Urol* 2014;**192**:914–8.
- [18] Chand DH, Rhoades T, Poe SA, Kraus S, Strife CF. Incidence and severity of vesicoureteral reflux in children related to age, gender, race and diagnosis. *J Urol* 2003;**170**:1548–50.
- [19] Karnak I, Woo LL, Shah SN, Sirajuddin A, Kay R, Ross JH. Prenatally detected ureteropelvic junction obstruction: clinical features and associated urologic abnormalities. *Pediatr Surg Int* 2008;**24**:395–402.
- [20] Hollowell JG, Altman HG, Snyder 3rd HM, Duckett JW. Coexisting ureteropelvic junction obstruction and vesicoureteral reflux: diagnostic and therapeutic implications. *J Urol* 1989;**142**(2 Pt 2):490–3 [discussion 501].
- [21] Kenney IJ, Negus AS, Miller FN. Is sonographically demonstrated mild distal ureteric dilatation predictive of vesicoureteric reflux as seen on micturating cystourethrography? *Pediatr Radiol* 2002;**32**:175–8.
- [22] Estrada CR, Peters CA, Retik AB, Nguyen HT. Vesicoureteral reflux and urinary tract infection in children with a history of prenatal hydronephrosis—should voiding cystourethrography be performed in cases of postnatally persistent grade II hydronephrosis? *J Urol* 2009;**181**:801–7.
- [23] Brophy MM, Austin PF, Yan Y, Coplen DE. Vesicoureteral reflux and clinical outcomes in infants with prenatally detected hydronephrosis. *J Urol* 2002;**168**:1716–9.
- [24] Szymanski KM, Al-Said AN, Pippi Salle JL, Capolicchio JP. Do infants with mild prenatal hydronephrosis benefit from screening for vesicoureteral reflux? *J Urol* 2012;**188**:576–81.
- [25] Mears AL, Raza SA, Sinha AK, Misra D. Micturating cystourethrograms are not necessary for all cases of antenatally diagnosed hydronephrosis. *J Pediatr Urol* 2007;**3**:264–7.
- [26] Rachmiel M, Aladjem M, Starinsky R, Strauss S, Villa Y, Goldman M. Symptomatic urinary tract infections following voiding cystourethrography. *Pediatr Nephrol* 2005;**20**:1449–52.
- [27] McAlister WH, Cacciarelli A, Shackelford GD. Complications associated with cystography in children. *Radiology* 1974;**111**:167–72.