

ORIGINAL ARTICLE

Spinal phantom comparability study of Cobb angle measurement of scoliosis using digital radiographic imaging

Ni Chung, Yi-Hong Cheng, Hiu-Lam Po, Wai-Kit Ng, Kam-Ching Cheung, Ho-Yin Yung, Yau-Ming Lai*

Department of Health Technology and Informatics, The Hong Kong Polytechnic University, Hong Kong, China

Received 28 June 2018; received in revised form 18 September 2018; accepted 26 September 2018
Available online 26 October 2018

KEYWORDS

Cobb angle;
Comparison study;
Imaging evaluation;
Scoliosis;
Spine phantom

Summary *Background:* Computed radiography (CR), digital radiography (DR) and biplanar radiography (EOS™ imaging system) are common imaging tools for radiographic evaluation of adolescent idiopathic scoliosis (AIS). The effect of imaging methods in relation to later-on Cobb angle measurements on radiographs is not yet quantified. The study aimed to examine the compatibility between CR, DR and EOS for scoliotic quantification by evaluating the reliability, agreement of different imaging methods, and assessing the prediction performance for EOS measurement from that of CR and DR.

Method: A flexible spine phantom was used to simulate 32 different scoliotic curves ranging from 10° to 60°. Each curvature was imaged using DR, CR and EOS systems accordingly. Each of the six observers independently measured Cobb angle twice on each image at a two-week interval. Intraclass correlation coefficient (model 2 and 3), Bland-Altman plot and linear regression analysis were completed to evaluate the reliability, agreement, and the prediction of Cobb angle measurement, respectively.

Results: Reliability analysis showed excellent intra-observer reliability (Intraclass correlation coefficient >0.9) for each observer and good inter-observer reliability (Intraclass correlation coefficient = 0.84 for EOS; 0.739 for CR; 0.877 for DR) for each method. Bland-Altman plots demonstrated good agreement between imaging methods without fixed or proportional bias. Excellent coefficient of determination was achieved, with 0.980 for CR versus EOS measurements, and 0.973 for DR versus EOS measurements.

Conclusions: Radiographs produced by all of the three methods can provide reliable and accurate Cobb angle measurements for scoliosis assessments. None of the methods systemically underestimates or overestimates the Cobb angle measurement. Additionally, all of the evaluated methods are satisfactory in obtaining images for Cobb angle measurement in AIS. However, the 3D post-processing techniques offered by EOS should also be taken into consideration as it

* Corresponding author. Department of Health Technology and Informatics, The Hong Kong Polytechnic University, Hong Kong, China.
E-mail address: htpymlai@gmail.com (Y.-M. Lai).

takes a vital role in treatment and monitoring of 3D deformity in the case of scoliosis.

The translational potential of this article: In view of the limited availability of biplanar radiography (EOS™ imaging system), computed radiography and digital radiography are demonstrated to be reliable alternatives in scoliosis monitoring as evident in the reliability, agreement and prediction of Cobb angle measurement.

© 2018 The Authors. Published by Elsevier (Singapore) Pte Ltd on behalf of Chinese Speaking Orthopaedic Society. This is an open access article under the CC BY-NC-ND license (<http://creativecommons.org/licenses/by-nc-nd/4.0/>).

Introduction

Scoliosis is a three-dimensional (3D) spinal deformity that is defined by lateral deviation of the vertebral column of more than 10° with vertebrate rotation. It can be classified into four main categories—congenital, idiopathic, neuromuscular, and syndromic. Among them, adolescent idiopathic scoliosis (AIS) is the one most commonly encountered by physicians, orthopaedists, and surgeons. It is a developmental deformity of the spine and body trunk evident in an otherwise healthy adolescent, consisting of structural lateral spinal curvature in a coronal plane, axial vertebral rotation in a transverse plane, and physiological spinal curvature disruption in a sagittal plane [1]. Epidemiological studies showed that 2–4% of teenagers aged between 10 and 16 years will develop some degree of scoliosis [2]. In Hong Kong, its prevalence is about 3% [3].

Regardless of the enormous advances in medical imaging over decades, scoliosis radiography remains the mainstay to diagnose and evaluate AIS. Full-length posteroanterior (PA)/anteroposterior and lateral spinal radiographs are taken to assess the degree of curvature. Patients are imaged in the standing position to evaluate the influence of gravity on the deformity, giving more reliable radiographic measurements for estimating the magnitude of scoliosis and ultimately in clinical decision-making [4]. The radiographs can be obtained with the use of various imaging methods, including computed radiography (CR), digital radiography (DR), and biplanar linear radiography (EOS™ imaging system). Although the EOS system is proved to offer the most accurate assessment of whole-body imaging without clinical significant difference compared with computed tomography scanogram [5], its availability is limited. Most clinical centres still use DR or CR systems for scoliosis examinations. However, DR and CR systems are associated with differential magnification due to the parallax effect. The extent of magnification is related to the object size, source–detector distance, beam centring, and beam divergence. The parallax phenomenon may distort the full-length spinal images, leading to error on radiographic measurements [5,6].

On the PA/anteroposterior radiograph, the degree of the scoliotic curve is determined with the Cobb's method. It is obtained by measuring the angle between the superior end plate of the superior end vertebra and the inferior end plate of the inferior end vertebra involved in the curve [2,4]. To decide which management method should be chosen, the maturity of patients and severity of scoliosis should be considered and that younger children with larger

curve magnitude have greater risk of curve progression [2]. Progressive scoliosis could lead to worsening of deformity such as truncal shift, asymmetry in the shoulder height, rib prominences and development of chest wall abnormality [2]. For mild scoliosis of 10°–25°, observation at regular intervals is suggested. Bracing is recommended for moderate scoliotic patients angled from 26° to 40°. Spinal curvature with Cobb angle greater than 40° is regarded as severe scoliosis, and multilevel spinal fusion surgery is usually performed for these patients. Because a few degrees of difference can significantly affect the treatment decisions, it is important for an AIS patient to have follow-up radiographs regularly to see if there is any progression. When comparing two radiographs of the same patient, a difference of 5° in the measured Cobb angle represents a 95% confidence of a true difference [7]. In AIS, an increase of 5° at a 12-month interval indicates a significant curve progression [4].

Accurate and reliable radiographic measurements in scoliosis are important for clinical decision-making, especially for Cobb angle measurement. The Cobb angle measured should be accurate enough to represent the real condition of the patient [8,9]. Also, it should be reliable for monitoring of curve progression and management of the treatment process [9]. However, error exists in Cobb measurement owing to changes in radiographic production and/or measurement error. Vrtovec et al. [10] further explained that the positioning procedure, radiographic method used, end vertebrae selection, inaccurate protractors, and bias of observers were the major causes of variations in the Cobb angle measurement. A total error of 2°–7° had been reported in the assessment of Cobb angle [7]. In the study of Goldberg et al. [11], subtle variations in imaging acquisition, such as changes in the patient posture and position, caused an error of 2°. The study also reported an interobserver error of 2.5° and an intraobserver error of 1.9°. Although the imaging method has been recognized to be one of the potential factors causing error in the Cobb angle measurement, few research studies investigated its effect. *In vivo* investigations on individuals comparing CR, DR, and EOS difference in scoliosis measurement have not been conducted to the best knowledge of the researchers, probably due to the ethical concern of unnecessary high radiation exposure.

In the light of the aforementioned review, we aimed to examine the compatibility between the three radiographic imaging methods, CR, DR, and EOS, for scoliotic quantification by using a flexible spine phantom. The specific objectives of our study include, first, reviewing the reliability

of CR, DR, and EOS for Cobb angle measurement, second, assessing the agreement between different imaging methods, and third, evaluating the prediction performance for EOS measurement from that of CR and DR.

Materials and methods

Phantom description and experimental setup

A highly bendable spine model with soft intervertebral discs (1008545, 3B Scientific, Hamburg, Germany) was selected in this study (Figure 1). The spine phantom was fully flexible such that it could mimic scoliosis with a wide range of clinical significant extent of deformation. The spine phantom was flexed into different degrees of lateral curvatures in the coronal plane with the natural kyphosis and lordosis maintained. Individuals were refrained from the study because multiple X-ray exposures for single individual were involved in this study, which would pose additional radiation risks to humans without clinical justification. To better imitate the

real clinical situation, the adjustment of curves followed the major curve characteristics of AIS. A total of 32 C-shaped thoracic dextroscoliotic curves (a single curvature with thoracic spine convex to the right) between 10° and 60° were simulated. The range of angles covered the scope at which decisions for observation, bracing, and surgery for AIS would be made. The study started with 10° based on the definition of scoliosis. A few degrees of measurement difference within the range affect the management decisions significantly. Vice versa, measurement variations for curves clearly below 20° or above 60° are unlikely to alter the treatment option [12]. Because the accuracy of Cobb angle measurement could be affected by positioning errors, which could reach up to 20°–30° theoretically [13], the spine phantom was fixed in its position rigidly within an immobilizer frame for minimisation of these extraneous variables. The frame ensured that there was no axial rotation of the spine phantom during transfer between different examination rooms and that the same object–detector distance was maintained in every image acquisition.

Scoliosis imaging

Image collection was started by first bending the spine phantom to shape a single right thoracic curve. Before any image acquisition, a digital photo was taken for documentation of the curvature. For each curve, it underwent three image acquisitions involving DR, CR, and EOS systems, in order. For all methods, the positioning parameters followed the local protocols of the Duchess of Kent Children's Hospital. The central point (eighth thoracic vertebra) and proximal and distal margin (occiput and pelvis) of the spine phantom were marked on the frame for consistent centring and collimation.

Image acquisition began with the use of the DR unit (Discovery XR650, GE Healthcare, Chicago, United States). The phantom was placed in PA position, with the source-to-image receptor distance being 180 cm (Figure 2A). The exposure parameters were adjusted to 63 kVp and 16 mAs. By setting the start and end level with the use of the scoliosis series protocol, three consecutive radiographs were obtained with a craniocaudal angulation of the central beam. The three images would be automatically stitched to a single whole spine image (Figure 2A). The Cobb angle would be measured once at the workstation to ensure the adjusted curvature was within the desired range before performing the remaining acquisitions.

Full-length radiographs were then performed using the CR system (CR75 5612/110, Agfa Healthcare, Bonn, Germany). Two 35 cm × 43 cm imaging plates would be placed inside the designated imaging plate holder with slight overlapping behind the Bucky grid. Same as in DR acquisition, the phantom was in PA position but the source-to-image receptor distance was changed to 150 cm (Figure 2B). The exposure factors remained the same as in DR setting. The entire spine was imaged with single X-ray exposure by centring according to the predefined reference marking. The CR images were stitched together semi-automatically with the use of background gridlines at the computer workstation (Figure 2B).

Scanning was performed after CR and DR acquisitions using a biplanar linear radiography system (EOS™, EOS

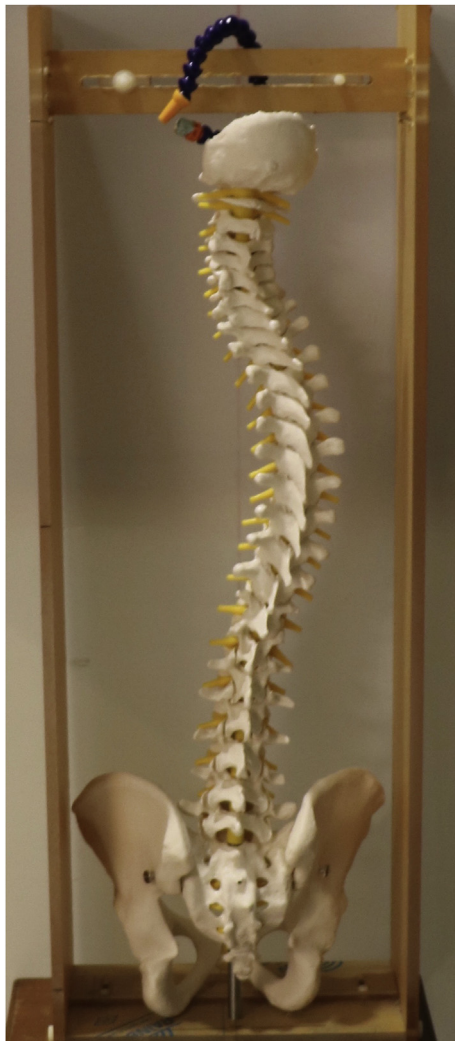

Figure 1 Illustration of the spine phantom. The spine phantom was manipulated with a right-sided thoracic scoliosis fixed in an immobilizer frame.

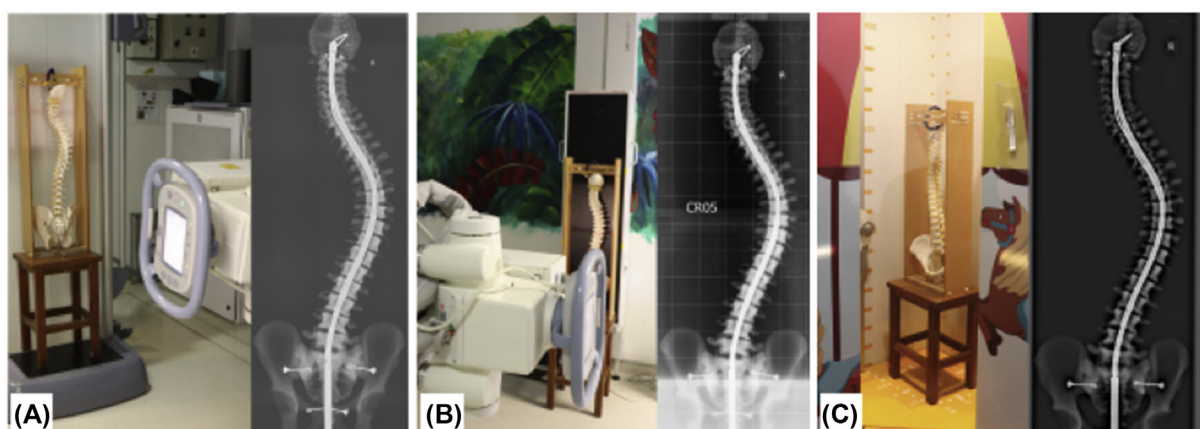


Figure 2 Experimental set-up and the corresponding radiographs for different imaging methods. The phantom was placed on the chair in true anteroposterior/posteroanterior position with consistent centring and collimation (A) in DR setting, (B) in CR setting, and (C) in EOS setting.

CR = computed radiography; DR = digital radiography; EOS™ imaging system.

Imaging, Paris, France). The spine phantom was positioned anteroposteriorly at the centre of the scanning field (Figure 2C). All parameter values were remained as preset except the exposure parameters that were changed to 63 kVp and 160 mA. The start and end level were located using the external laser beam. Because lateral images and 3D reformation were not necessary in this study, the biplanar mode was not used.

After all image acquisitions by the three aforesaid imaging methods, another curvature was then remanipulated to start a new set of image collection. The acquisition process was repeated until a total of 32 sets of data including 96 radiographs were acquired. All images were eventually sent to the local server of the hospital and wrote into a CD-ROM.

Scoliosis measurement

Six trained radiography practitioners were recruited as observers in the study. Computer-aided Cobb angle measurements were performed on the Philips DICOM viewer (PMS DICOM R3.0 SP3; Philips Healthcare, Eindhoven, the Netherlands). Once the observers determined the superior and inferior end vertebrae location by placing two lines crossing the end plates, the Cobb angle would be automatically calculated by using the software. Consensus and training on the measurement technique was made among the observers beforehand to familiarize them with the software program and minimise measurement bias. Observers were allowed to adjust the image contrast, brightness and magnification to assist in the measurements. Each radiograph was evaluated two times by each observer at an interval of 2 weeks. The end vertebrae were determined and recorded by every observer for each radiograph at their first trial so that same end vertebrae were used for their later-on trial. They were not allowed to access their measurement results and others' results until all data collection was finished.

Data analysis

The software SPSS (SPSS Statistics 23; IBM, Chicago, USA) was used for statistical analysis. Descriptive statistics

including the mean, standard deviation, and range of measurement were reported. Interobserver and intra-observer reliability of measurements for each imaging method was assessed by the intraclass correlation coefficient (ICC) models 2 and 3, respectively. Reliability was regarded as poor for less than 0.24, low for 0.25–0.49, moderate for 0.5–0.69, good for 0.70–0.89, and excellent for greater than 0.9 [14]. A statistically significant difference was present between two values of comparison when their 95% confidence intervals were not overlapped. A Bland–Altman plot was also performed to distinguish whether the variation between radiographic techniques would lead to significant difference on clinical performance. CR, DR, and EOS were compared with each other using the Bland–Altman plot. For each comparison, 95% limit of agreement was used. Linear regression analysis was performed for prediction of the Cobb angle measurement by EOS using CR or DR. Statistical significance was defined by p -value < 0.05 for all tests.

Results

Descriptive statistics

The mean, standard deviation, and the range of the measured Cobb angle for the 32 radiographs obtained from each of the three imaging methods were recorded. Each imaging method was reported independently for every observer (Table 1). The overall mean Cobb angle for CR imaging was 32.035°, 33.70° for DR imaging and 33.9° for EOS imaging method. The range of measured Cobb angle were from 9.40° to 59.3° for the three imaging methods among the observers.

Reliability

The intraobserver reliability of Cobb angle measurements using the three imaging methods for each observer was analysed. The data are presented as intraclass correlation coefficient (ICC) with 95% confidence intervals (Table 2).

Table 1 Descriptive statistics between measurements of Cobb angle.

Cobb angle	Observer 1			Observer 2			Observer 3		
	CR	DR	EOS	CR	DR	EOS	CR	DR	EOS
Mean (°)	30.87	32.90	33.00	35.96	37.10	37.91	35.07	34.65	33.95
Standard deviation	8.34	9.64	9.81	9.40	10.00	10.10	9.94	10.16	10.45
Range (°)	12.20 –49.75	14.90 –51.75	15.65 –51.55	18.05 –56.00	18.50 –55.80	18.70 –56.85	17.20 –55.00	12.65 –53.30	13.45 –51.05
Cobb angle	Observer 4			Observer 5			Observer 6		
	CR	DR	EOS	CR	DR	EOS	CR	DR	EOS
Mean (°)	30.08	30.05	29.70	24.95	32.23	31.34	35.28	35.85	37.52
Standard deviation	9.01	9.12	8.97	11.80	9.22	8.74	10.01	9.97	10.01
Range (°)	14.90 –48.05	14.10 –48.35	14.30 –48.10	9.40 –48.55	16.20 –50.75	16.30 –50.65	15.30 –51.25	17.45 –52.60	20.60 –59.30

All values were corrected to two digits after decimal point.

CR = computed radiography; DR = digital radiography; EOS™ imaging system.

Table 2 Intraobserver reliability of Cobb angle measurements using three imaging methods.

Imaging modality	Observer 1	Observer 2	Observer 3	Observer 4	Observer 5	Observer 6
EOS	0.970 (0.939 –0.985)	0.994 (0.988 –0.997)	0.977 (0.953 –0.988)	0.978 (0.956 –0.989)	0.928 (0.858 –0.964)	0.992 (0.983 –0.996)
CR	0.960 (0.920 –0.980)	0.987 (0.969 –0.994)	0.967 (0.926 –0.985)	0.960 (0.843 –0.985)	0.968 (0.935 –0.984)	0.987 (0.973 –0.994)
DR	0.962 (0.834 –0.986)	0.989 (0.978 –0.995)	0.980 (0.960 –0.990)	0.981 (0.958 –0.991)	0.955 (0.911 –0.978)	0.990 (0.980 –0.995)

CR = computed radiography; DR = digital radiography; EOS™ imaging system; ICC = intraclass correlation coefficient.

Two-way mixed ICC model 3 with absolute agreement for single measures was used. For all estimates, test value = 0.9.

Excellent reliability was found between the repeated measurements for all observers with the single-measure ICC values higher than 0.9, regardless of the type of radiographic methods used. Half of all observers (observers 1, 2, and 6) expressed highest ICC values in EOS measurements, whereas most of the observers (observers 1, 2, 3, 4, and 6) expressed the lowest ICC estimates in CR measurements compared with those of EOS and DR. Observers 2 and 6 demonstrated relatively higher ICC results for all imaging methods compared with other observers. Statistically significant differences in ICC values were present between four observer pairs in EOS measurements (observer 1 and 2, observer 2 and 3, observer 2 and 5, and observer 5 and 6) and two observer pairs in DR measurements (observer 2 and 5 and observer 5 and 6).

The interobserver reliability of Cobb angle measurement was determined using a two-way random model with absolute agreement. The interobserver ICC values (colour bars) with upper and lower bound of 95% confidence intervals (error bars) are demonstrated (Figure 3). The interobserver reliability estimates were lower than the corresponding intraobserver reliability estimates, with ICC values ranged from moderate to excellent for EOS (0.636–0.926), poor to good for CR (0.499–0.869), and moderate to excellent for DR (0.739–0.941). The p -value

was larger than 0.05 in all values for each method with a testing value of 0.9. The ICC value of CR was slightly lower than that of DR and EOS, but no significant difference was detected among the three methods. The interobserver variability was relatively high for all methods with reference to a wide range of the 95% confidence intervals. CR measurements showed highest variability with a range of 0.37 ICC.

Agreement

Comparisons of Cobb angle measurements between pairs of imaging methods were categorized by the extent of agreement with the use of Bland–Altman method of difference (Figure 4). With an unknown true Cobb angle value, the mean of the two measurements was regarded as the best estimate. The resulted Bland–Altman plots of all demonstrated low mean difference of measured Cobb angle between modalities (d CR v. DR = 0.0344°; d CR v. EOS = 0.3891°; and d DR v. EOS = 0.3547°) which were not significant from zero ($p > 0.05$), meaning that there was no fixed or constant bias between methods. No demonstrable departure from zero was detected in slopes of the regression of difference on means for the three plots ($R^2 = 0.01$

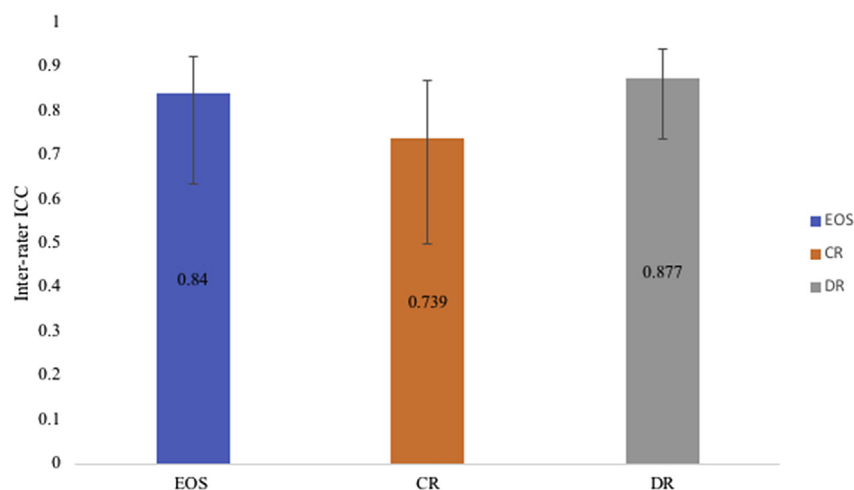


Figure 3 Interobserver reliability of Cobb angle measurements within imaging methods. Two-way random ICC model 2 with absolute agreement for single measure was used. For all estimates, test value = 0.9. ICC, intraclass correlation coefficient; CR = computed radiography; DR = digital radiography; EOS™ imaging system.

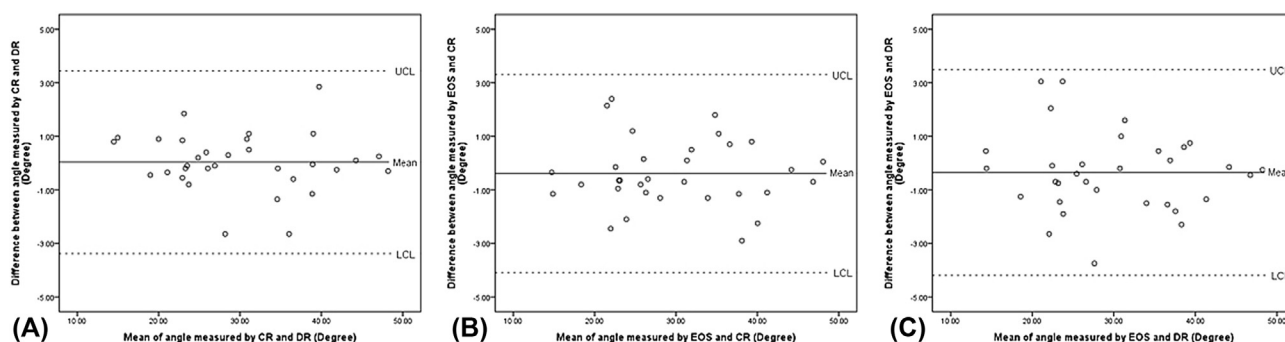


Figure 4 Bland-Altman plots of observer 4 between the Cobb angle measurements of different imaging methods. (A) CR versus DR. (B) CR versus EOS. (C) DR versus EOS.

CR = computed radiography; DR = digital radiography; EOS™ imaging system.

for CR v. DR; 0.00476 for CR v. EOS; and 0.02 for DR v. EOS), indicating no proportional bias between methods. All differences were within the limits of agreement mean + 1.96SD and mean − 1.96SD. The range of CR and DR differences, CR and EOS differences, and DR and EOS differences were from −2.65° to 2.85°, from −2.40° to 2.90°, and from −3.05° to 3.75°, respectively. The results of the Bland–Altman plots indicate that the difference between EOS and CR/DR measurements was not clinically important.

Prediction

Linear regression analysis was performed for studying the relationship between the Cobb angles measured using EOS and using CR/DR (Figure 5). The coefficient of determination, R^2 , represents the percentage of the variance in the dependent variable (Cobb angle measured by EOS) that is predictable from the independent variables (Cobb angle measured by CR/DR). The results demonstrated significant linear regression between the Cobb angle measured using CR and EOS ($R^2 = 0.980$; $p < 0.001$) and between DR and EOS ($R^2 = 0.973$; $p < 0.001$). The significant p -value

indicated that changes in the predictor (Cobb angle measured by CR/DR) were related to changes in the response (Cobb angle measured by EOS). The Cobb angle measured from CR images was found to be slightly better than that from DR images for prediction of EOS measurement. However, their difference in R^2 was very small and was clinically insignificant. All observed Y points lied closely to the predicted Y points of the regression equation in both regression variation plots without any outliers. This accounted for the low standard error of the estimate of 1.281 and 1.502 for CR and DR measurements, respectively.

Discussion

This was the first local study to compare the performance of CR, DR, and EOS in scoliosis imaging with Cobb angle measurements. In the study, the reliability of individual imaging methods and the agreement between different imaging methods were assessed, and prediction was made to see if the three methods could be used interchangeably. The main findings included, first, excellent intraobserver reliability for each observer in each of the three imaging

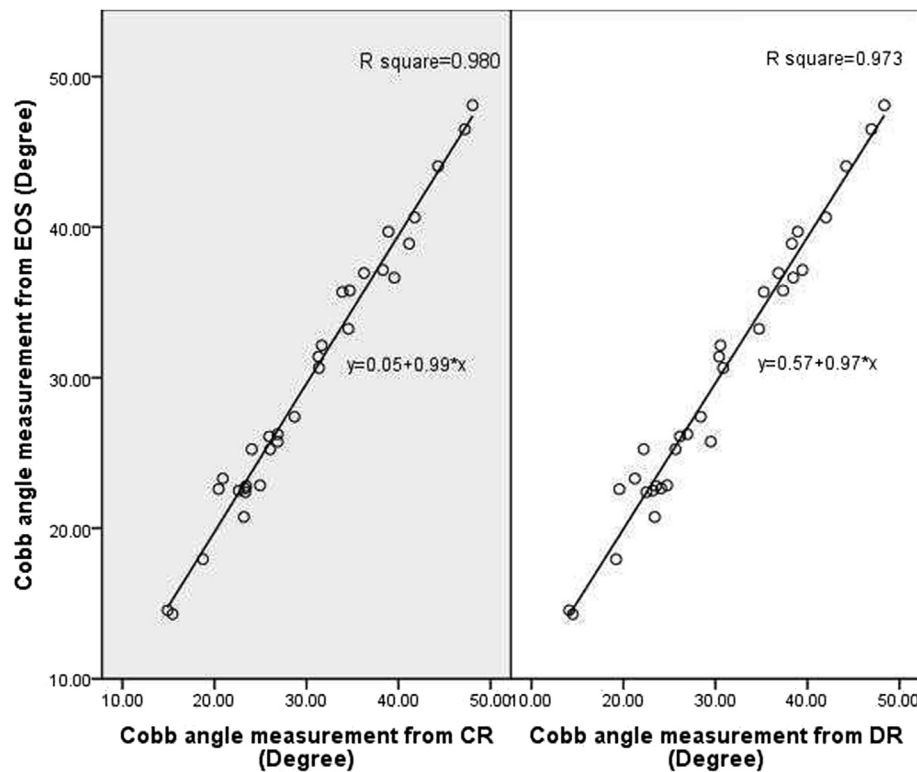


Figure 5 Regression variation plot of observer 4 between Cobb angle measured using CR/DR and EOS. Estimated Cobb angle value in EOS is predicted with known value of Cobb angle in CR/DR measurement. CR = computed radiography; DR = digital radiography; EOS™ imaging system.

methods, second, lower interobserver reliability than the corresponding intraobserver reliability for each imaging method, third, good agreement between pairs of methods and last, high linear regression between EOS and CR/DR measurements.

Reliability is essential in the radiographic evaluation of scoliosis by minimising observer error so that more uniform recommendations regarding treatment and surgical planning can be achieved. It represents the non-systematic error of measurements with regard to the intraobserver and interobserver variability. This applies to the imaging method used to produce the radiographs for angle measurement. By testing the commonly used methods for scoliosis radiography, CR, DR, and EOS all showed the ability to produce reliable Cobb angle measurement results in repeated measures in the present study. They were reported to have excellent intraobserver reliability and moderate-to-good interobserver reliability in general. It verifies that the same observer measuring a curve is more similar to their own measurements than those of other observers [15,16].

These results are in agreement with previous literature values for the high intraobserver ICCs and lower corresponding interobserver ICCs of the Cobb angle [15]. Wills [15] documented ICCs of 0.91–0.99 for intraobserver reliability and 0.89 to 0.99 for interobserver reliability of the Cobb angle. Compared with his study, the present study showed similar intraobserver ICCs (0.928–0.994) but lower interobserver ICCs (0.739–0.837). The difference between the results could be explained by the preselection of the

end vertebrae before measurements in the study by Wills. In the present study, because the end vertebrae of scoliotic curves were not defined before angle measurement, observers may select different end vertebrae for their measurement, resulting in higher interobserver variability. As suggested by Dimar [17], only poor-to-moderate level of inter-rater reliability would be reported on coronal measurements when the end vertebrae of scoliotic curves were not preselected and agreed on by observers. The lack of preselection of end vertebrae posed a potential source of error, resulting in greater measurement variation [12,18].

Small difference was found in the interobserver variability of Cobb angle measurement using various imaging methods. This could be related to the variation in the radiographic image quality between imaging methods. The end plates should be clearly defined and viewed as a single clear line so that observers can accurately draw the lines adjacent to the end plates of the upper and lower vertebrae using marking tools for Cobb angle calculation. As suggested by Deschênes et al. [19], biplanar slot scanners provide images of better resolution than that of standard CR images with 46.7% global image quality and 32.4% structure visibility improvements. On CR radiographs, the vertebral end plates far from the source often partially overlap and appear fusiform, which cannot be reduced to a single clear line and defined by observers [16,19]. Improper drawing of lines across the end plates of the vertebrae causes inaccurate estimation of slopes of the end vertebrae, resulting in Cobb angle degree variation [20]. This explains our finding that CR was of higher interobserver

variability in Cobb angle measurement than that of DR and EOS. Another study also pointed out that the performance of CR measurement is even worse in the condition of combined deformities such as lordoscoliosis or kyphoscoliosis, as the determination of end plates for true Cobb angle measurement is nearly impossible with CR [21].

The measurement of Cobb angle in serial follow-up should be accurate to reflect the scoliotic severity and curve progression in patients. Thus, it is important to see if different imaging methods are in agreement with one another so that the Cobb angle measured from the radiographs are comparable. When comparing two radiographs, a 5° difference in the Cobb angle measurement represents a 95% chance of a true difference, which may be enough to influence the clinicians' evaluation on likelihood of curve progression and suggestions for treatment intervention [11]. Thus, a value of 5° has been accepted as the upper limit of measurement variations between measurements. Because all differences of Cobb angle measurements by using various imaging methods randomly fell within 5° difference in the study with a maximum range of the measured Cobb angle differences between methods from -3.05° to 3.75° (Figure 4), it could be concluded that there was no significant difference in the Cobb angle measurement with the use of different imaging methods. Similar to our results, Schmid et al. [22] also found a 3° error for Cobb angle measurements between different modalities (CR, EOS, and CT) at the neutral plane. Good agreement was found between any two of the examined imaging methods, meaning that they could be used interchangeably with one another, and clinical comparison on Cobb angle could be made with radiographs produced either by CR, DR, or EOS.

Previous studies have compared the performance of EOS with CT in the measurement of scoliotic curves, and most studies reported an excellent agreement between EOS and CT in measuring Cobb angle and confirmed EOS to be a reliable and accurate imaging acquisition method for scoliosis examination [22,23]. It is suggested that the biplanar X-ray sources and detectors of EOS system translate simultaneously along superoinferior direction; thus, the images produced do not have geometrical magnification, contrary to conventional projection imaging systems [24]. However, no studies have actually examined the agreement between EOS and standard X-ray systems. In contrast to Hull's suggestion [24], the results of the present study proved that the effect of geometrical magnification on Cobb angle measurement is insignificant. The difference in the Cobb angle measurement between imaging methods could be regarded as measurement variability rather than real error. None of the methods systemically underestimated or overestimated the Cobb angle measurement in our study. All the three methods are satisfactory for assessing the Cobb angle in AIS.

With EOS being suggested to be an accurate method and recommended to be a standard in scoliosis radiography, it should be used extensively in scoliotic centre for follow-up examinations. However, the availability of this newly developed system is limited and CR and/or DR is still in use in most of the scoliosis centres, it is indicative to document the performance of CR and DR versus that of EOS to see if their measurements on Cobb angle are correlated. The findings showed that the CR and DR measurements were

highly correlated with the EOS measurement, with coefficient of determination (R-square value) of both CR and DR close to 1 (Figure 5). It is confident to tell from the study that the measurements of Cobb angle by EOS could be effectively predicted using CR/DR, with a high accuracy of predictions. In other words, CR and DR could give accurate Cobb angle measurement results comparable to those of EOS, so they could be continuously used in the future without an urgent need to be replaced by EOS for assessment of scoliosis.

Still, the slot-scanning system has key advantages over standard X-ray systems in terms of its microdose protocol and 3D reconstruction ability, which has not been assessed in the study. During spine radiograph acquisitions, radio-sensitive organs including the breasts and thyroid are exposed to radiation [25]. Previous studies documented an estimated cumulative radiation exposure of 15 mSv due to periodic radiographic follow-ups, leading to notably increased cancer risk in AIS patients [26,27]. With the use of microdose EOS, a 58% dose reduction with the effective dose reduced from 233 mSv to 98.7 mSv could be achieved [28,29]. Another study also confirmed a 6- to 9-fold of average skin dose reduction in the thoracoabdominal region, with the use of slot-scanning imaging instead of CR [19]. Moreover, a complex 3D structure of curve deformity has been reported to be difficult to assess from 2D radiographic measurement [30,31]. The Scoliosis Research Society has highlighted the clinical relevance and impacts of 3D analysis of scoliosis using EOS [32]. The 3D spine images created can be tilted and rotated, permitting accurate evaluation of the axial plane and visualisation of true sagittal alignment. The extensive and complete description of scoliotic spine assists the orthopaedists in classification of scoliosis and assessment of posture [28].

The clinical relevance of the present study may lie in several aspects. Differences in the image acquisition techniques contribute to errors of Cobb angle measurement in addition to patient factors [4,33]. First, the present study design using the spinal phantom allows separate evaluation of influences of the state-of-art digital imaging systems on the reliability of the Cobb angle determination, which is an important imaging biomarker for scoliosis management [34,35]. It may substantiate further comparison studies on clinical evaluation of the three current digital radiographic imaging methods in the measurement accuracy of Cobb angle. Understanding of such influences allows optimized use of these imaging systems for spinal imaging of scoliosis. Second, the results demonstrated that both CR and DR systems are as reliable and accurate as EOS system for Cobb angle measurement in the coronal plane. Thus, both the CR and DR imaging system can be an alternative to EOS in view of the limited availability in clinical practice. Third, the newly developed EOS system enables improvement in the image quality; the present study was evident that it further reduced the intraobserver variability in the measurement of Cobb angle, which is important in the longitudinal monitoring of AIS for spinal curve progression.

The present study design was not without limitation. A spine phantom in place of clinical radiographs was used for comparison. Nonetheless, this is necessary as performing additional radiographic examinations for patients without health benefits to them is unethical. The absence of soft

tissue and neighbouring anatomy in the model made it impossible to take into account the effect of soft tissue scattering and anatomical superimposition on clinical radiographs. Also, because measurements in the present study were made under ideal conditions with the use of phantom, the total error may be underestimated owing to patient factors such as positioning and movement during image acquisition. The phantom enables bending and rotation via a metallic spring rod inserted in the vertebral canal. However, the radio-opaque metallic rod and the Perspex fixation frame around the phantom would obscure the radiographic image landmarks such as the pedicles, spinous process and vertebral end plate, which are the essential reference points for the quantitative evaluation of the Cobb angle in the sagittal plane and vertebral axial rotation using the methods by Cobb, Nash-Moe, Perdriolle and Stokes [36,37]. Thus, quantitative evaluation of the sagittal curvature and vertebra axial rotation had not been attempted in the present study.

In summary, the existing data suggested that CR, DR, and EOS radiographs were all highly reliable for Cobb angle measurements. Excellent agreement was shown between each of the three imaging methods with no significant difference in their measurements. As a result, any of the evaluated methods is an acceptable means to obtain images for Cobb angle measurement in AIS. A further direction of the study is to assess the effect of imaging methods on other clinical measurement parameters of scoliosis so as to assess their interchangeability.

Conflicts of interest

The authors have no conflicts of interest to declare regarding this study.

Acknowledgements

The authors would like to thank the Department of Diagnostic Radiology, The Duchess of Kent Children's Hospital at Sandy Bay, for their help and support. We are grateful that research funding support is offered by the Department of Health Technology and Informatics, The Hong Kong Polytechnic University

References

- [1] Kotwicki T. Evaluation of scoliosis today: examination, X-rays and beyond. *Disabil Rehabil* 2008;30(10):742–51.
- [2] Altaf F, Gibson A, Dannawi Z, Noordeen H. Adolescent idiopathic scoliosis. *Br Med J* 2013;346:f2508.
- [3] Cheung CWJ. Development of 3D ultrasound system for assessing adolescent idiopathic scoliosis. PhD thesis. Hong Kong: The Hong Kong Polytechnic University; 2013.
- [4] Malfair D, Flemming AK, Dvorak MF, Munk PL, Vertinsky AT, Heran MK, et al. Radiographic evaluation of scoliosis: review. *Am J Roentgenol* 2010;194(3 Suppl):S8–22.
- [5] Escott BG, Ravi B, Weathermon AC, Acharya J, Gordon CL, Babyn PS, et al. EOS low-dose radiography: a reliable and accurate upright assessment of lower-limb lengths. *J Bone Jt Surg Am* 2013;95(23):e1831–7.
- [6] Green WT, Wyatt GM, Anderson M. Orthoroentgenography as a method of measuring the bones of the lower extremities. *Clin Orthop Relat Res* 1968;61:10–5.
- [7] Pruijs JE, Hageman MA, Keessen W, Van Der Meer R, Van Wieringen JC. Variation in Cobb angle measurements in scoliosis. *Skeletal Radiol* 1994;23(7):517–20.
- [8] Allen S, Parent E, Khorasani M, Hill DL, Lou E, Raso JV. Validity and reliability of active shape models for the estimation of cobb angle in patients with adolescent idiopathic scoliosis. *J Digit Imaging* 2008;21(2):208–18.
- [9] Langensiepen S, Semler O, Sobottke R, Fricke O, Franklin J, Schonau E, et al. Measuring procedures to determine the Cobb angle in idiopathic scoliosis: a systematic review. *Eur Spine J* 2013;22(11):2360–71.
- [10] Vrtovec T, Pernus F, Likar B. A review of methods for quantitative evaluation of spinal curvature. *Eur Spine J* 2009;18(5):593–607.
- [11] Goldberg MS, Poitras B, Mayo NE, Labelle H, Bourassa R, Cloutier R. Observer variation in assessing spinal curvature and skeletal development in adolescent idiopathic scoliosis. *Spine* 1988;13(12):1371–7.
- [12] Morrissey RT, Goldsmith GS, Hall EC, Kehl D, Cowie GH. Measurement of the cobb angle on radiographs of patients who have scoliosis. Evaluation of intrinsic error. *J Bone Jt Surg Am* 1990;72(3):320–7.
- [13] Carman DL, Browne RH, Birch JG. Measurement of scoliosis and kyphosis radiographs. Intraobserver and interobserver variation. *J Bone Jt Surg Am* 1990;72(3):328–33.
- [14] Munro BH. Statistical methods for health care research. Lipincott Williams & Wilkins; 2005.
- [15] Wills BP, Auerbach JD, Zhu X, Caird MS, Horn BD, Flynn JM, et al. Comparison of Cobb angle measurement of scoliosis radiographs with preselected end vertebrae: traditional versus digital acquisition. *Spine* 2007;32(1):98–105.
- [16] Gstoettner M, Sekyra K, Walochnik N, Winter P, Wachter R, Bach CM. Inter- and intraobserver reliability assessment of the Cobb angle: manual versus digital measurement tools. *Eur Spine J* 2007;16(10):1587–92.
- [17] Dimar II JR, Carreon LY, Labelle H, Djurasovic M, Weidenbaum M, Brown C, et al. Intra- and inter-observer reliability of determining radiographic sagittal parameters of the spine and pelvis using a manual and a computer-assisted methods. *Eur Spine J* 2008;17(10):1373–9.
- [18] Oda M, Rauh S, Gregory PB, Silverman FN, Bleck EE. The significance of roentgenographic measurement in scoliosis. *J Pediatr Orthop* 1982;2(4):378–82.
- [19] Deschênes S, Charron G, Beaudoin G, Labelle H, Dubois J, Miron M-C, et al. Diagnostic imaging of spinal deformities: reducing patients radiation dose with a new slot-scanning X-ray imager. *Spine* 2010;35(9):989–94.
- [20] Kundu R, Chakrabarti A, Lenka PK. Cobb angle measurement of scoliosis with reduced variability. 2012. arXiv preprint arXiv:1211.5355.
- [21] Villemure I, Aubin CE, Grimard G, Dansereau J, Labelle H. Progression of vertebral and spinal three-dimensional deformities in adolescent idiopathic scoliosis: a longitudinal study. *Spine* 2001;26(20):2244–50.
- [22] Schmid SL, Buck FM, Böni T, Farshad M. Radiographic measurement error of the scoliotic curve angle depending on positioning of the patient and the side of scoliotic curve. *Eur Spine J* 2016;25(2):379–84.
- [23] Lechner R, Putzer D, Dammerer D, Liebensteiner M, Bach C, Thaler M. Comparison of two- and three-dimensional measurement of the Cobb angle in scoliosis. *Int Orthop* 2017;41(5):957–62.
- [24] Hull NC, Binkovitz LA, Schueler BA, Kolbe AB, Larson AN. Upright biplanar slot scanning in pediatric orthopedics: applications, advantages, and artifacts. *Am J Roentgenol* 2015;205(1):W124–32.

- [25] Levy AR, Goldberg MS, Mayo NE, Hanley JA, Poitras B. Reducing the lifetime risk of cancer from spinal radiographs among people with adolescent idiopathic scoliosis. *Spine* 1996;21(13):1540–7. discussion 1548.
- [26] Law M, Ma WK, Lau D, Chan E, Yip L, Lam W. Cumulative radiation exposure and associated cancer risk estimates for scoliosis patients: impact of repetitive full spine radiography. *Eur J Radiol* 2016;85(3):625–8.
- [27] Ronckers CM, Land CE, Miller JS, Stovall M, Lonstein JE, Doody MM. Cancer mortality among women frequently exposed to radiographic examinations for spinal disorders. *Radiat Res* 2010;174(1):83–90.
- [28] Blumer SL, Dinan D, Grissom LE. Benefits and unexpected artifacts of biplanar digital slot-scanning imaging in children. *Pediatr Radiol* 2014;44(7):871–82.
- [29] Dietrich TJ, Pfirrmann CW, Schwab A, Pankalla K, Buck FM. Comparison of radiation dose, workflow, patient comfort and financial break-even of standard digital radiography and a novel biplanar low-dose X-ray system for upright full-length lower limb and whole spine radiography. *Skeletal Radiol* 2013;42(7):959–67.
- [30] Cheung J, Wever DJ, Veldhuizen AG, Klein JP, Verdonck B, Nijlunsing R, et al. The reliability of quantitative analysis on digital images of the scoliotic spine. *Eur Spine J* 2002;11(6):535–42.
- [31] Newton PO, Farnsworth CL, Parvaresh KC. Imaging and three-dimensional analysis of adolescent idiopathic scoliosis. *Semin Spine Surg* 2015;27(1):21–6.
- [32] Ilharreborde B, Sebag G, Skalli W, Mazda K. Adolescent idiopathic scoliosis treated with posteromedial translation: radiologic evaluation with a 3D low-dose system. *Eur Spine J* 2013;22(11):2382–91.
- [33] Kim H, Kim HS, Moon ES, Yoon CS, Chung TS, Song HT, et al. Scoliosis imaging: what radiologists should know. *Radiographics* 2010;30(7):1823–42.
- [34] Negrini S, Minozzi S, Bettany-Saltikov J, Zaina F, Chockalingam N, Grivas TB, et al. Braces for idiopathic scoliosis in adolescents. *Spine* 2010;35(13):1285–93.
- [35] Romano M, Minozzi S, Bettany-Saltikov J, Zaina F, Chockalingam N, Kotwicki T, et al. Exercises for adolescent idiopathic scoliosis. *Cochrane Database Syst Rev* 2012;(8):CD007837.
- [36] Lam GC, Hill DL, Le LH, Raso JV, Lou EH. Vertebral rotation measurement: a summary and comparison of common radiographic and CT methods. *Scoliosis* 2008;3:16.
- [37] Vrtovec T, Pernus F, Likar B. A review of methods for quantitative evaluation of axial vertebral rotation. *Eur Spine J* 2009;18(8):1079–90.