

# Green urine sign after laparoscopic chromopertubation as an effect of severe contrast intravasation: a report of three cases

Journal of International Medical Research

48(8) 1–7

© The Author(s) 2020

Article reuse guidelines:

[sagepub.com/journals-permissions](https://sagepub.com/journals-permissions)

DOI: 10.1177/0300060520942083

[journals.sagepub.com/home/imr](https://journals.sagepub.com/home/imr)

Piotr Szkodziak<sup>1</sup> , Andrzej Woźniak<sup>1</sup>,  
Filip Szkodziak<sup>1</sup>, Grzegorz Buszewicz<sup>2</sup>,  
Piotr Czuczwar<sup>1</sup> and Sławomir Woźniak<sup>1</sup>

## Abstract

Tubal diseases are responsible for 25% to 35% of female infertility. Laparoscopic chromopertubation is the gold standard for assessing tubal patency when female infertility is suspected. Intravasation is a complication of intrauterine procedures involving the passage of fluid filling the uterine cavity into the bloodstream through endometrial vessels (from the myometrial veins to the uterine venous plexuses). This complication has been described during hysterosalpingography and sonohysterosalpingography. We herein present a report of three cases in which severe intravasation occurred during laparoscopic chromopertubation using methylene blue as a contrast agent. The intravasation manifested as green urine (i.e., the “green urine sign”). The presence of methylene blue in the urine and blood was confirmed by laboratory tests. All three patients had risk factors for intravasation as described in the literature (unilateral or bilateral tubal obstruction, endometriosis, and previous intrauterine procedures for Mullerian duct anomalies and Asherman’s syndrome). The green urine sign appeared a few hours after laparoscopic chromopertubation and spontaneously resolved after 24 hours. Cystoscopy was performed to rule out bladder injury. All three patients required only clinical observation.

<sup>1</sup>Third Chair and Department of Gynecology, Medical University of Lublin, Lublin, Poland

<sup>2</sup>Laboratory of Forensic Toxicology, Chair and Department of Forensic Medicine, Medical University of Lublin, Lublin, Poland

## Corresponding author:

Piotr Szkodziak, Third Chair and Department of Gynecology, Medical University of Lublin, Teaching Hospital No. 4, Jaczewskiego 8, Lublin 20-954, Poland.  
Email: [piotr.szkodziak@gmail.com](mailto:piotr.szkodziak@gmail.com)



## Keywords

Green urine sign, chromopertubation, infertility diagnosis, intravasation, methylene blue, tubal patency

Date received: 31 March 2020; accepted: 23 June 2020

## Introduction

Tubal diseases are responsible for 25% to 35% of female infertility. The disease process may involve the proximal, distal, or entire tube. Numerous diagnostic techniques for tubal infertility are available, including salpingoscopy, hysterosalpingography (HSG), and sonohysterosalpingography.<sup>1</sup> However, laparoscopic chromopertubation is still the gold standard for assessment of tubal patency when female infertility is suspected. During laparoscopic chromopertubation, methylene blue solution is introduced into the uterine cavity. This solution should flow through the fallopian tubes into the abdominal cavity and thus become visible during laparoscopy. In the case of proximal occlusion, no externally visible passage of solution is present beyond the isthmus of the fallopian tube. In contrast, distal occlusion can be identified when the solution passes at least into the ampullary segment of the tube but not beyond the fimbria.<sup>2</sup>

Chromopertubation seems to be the most appropriate assessment method for diagnosis of gynaecological problems such as endometriosis, adhesions, or fallopian tube occlusion. Furthermore, slight adhesions inside the fallopian tube can be resolved by the flow of the solution during chromopertubation.<sup>2</sup>

We herein present three cases of severe contrast intravasation as a previously unpublished complication of laparoscopic chromopertubation. This complication manifested as green urine, and we have thus termed this phenomenon the “green urine sign.” Cases of the green urine sign

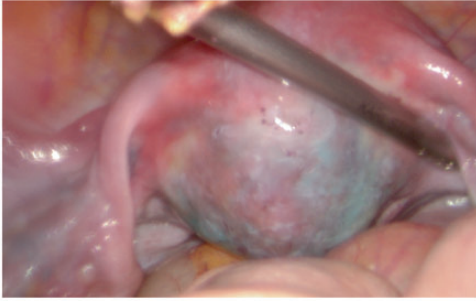
of different aetiologies have been reported in the literature, but none were associated with laparoscopic chromopertubation.<sup>3–5</sup>

## Case reports

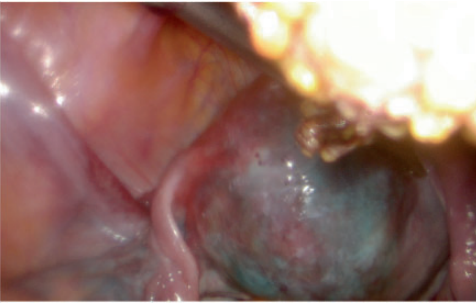
The green urine sign was observed in 3 of 168 patients undergoing laparoscopic chromopertubation procedures (complication rate of 1.8%) in our centre from 2012 to 2019.

### Case 1

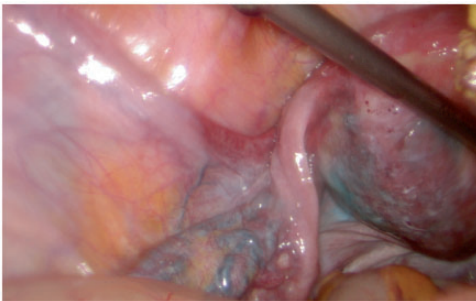
A 29-year-old woman with eumenorrhoea and a body mass index (BMI) of 22.3 kg/m<sup>2</sup> was incapable of becoming pregnant for 5 years. She was not pregnant upon presentation and denied having undergone any gynaecological procedures. The patient's only complaint was severe pain before menstruation. Because endometriosis was suspected, patient underwent diagnostic laparoscopy with chromopertubation during the middle of her follicular period. The laparoscopic examination revealed single spots of endometriosis and isolated adhesions in the pouch of Douglas. The endometriosis was diagnosed as grade 1 according to the American Society for Reproductive Medicine (ASRM) classification. After filling the uterine cavity with methylene blue, flow was observed in only one fallopian tube; the second fallopian tube appeared to be occluded. Contrast produced by methylene blue solution was observed in the uterine wall and perimetrium vessels (Figures 1–3). After a few hours, the patient's urine turned green (Figure 4).



**Figure 1.** Methylene blue solution in uterine wall vessels (initial phase of intravasation).



**Figure 2.** Methylene blue solution in uterine wall vessels (alternating phase of intravasation).



**Figure 3.** Methylene blue solution in perimetrium vessels (uterine venous plexus).

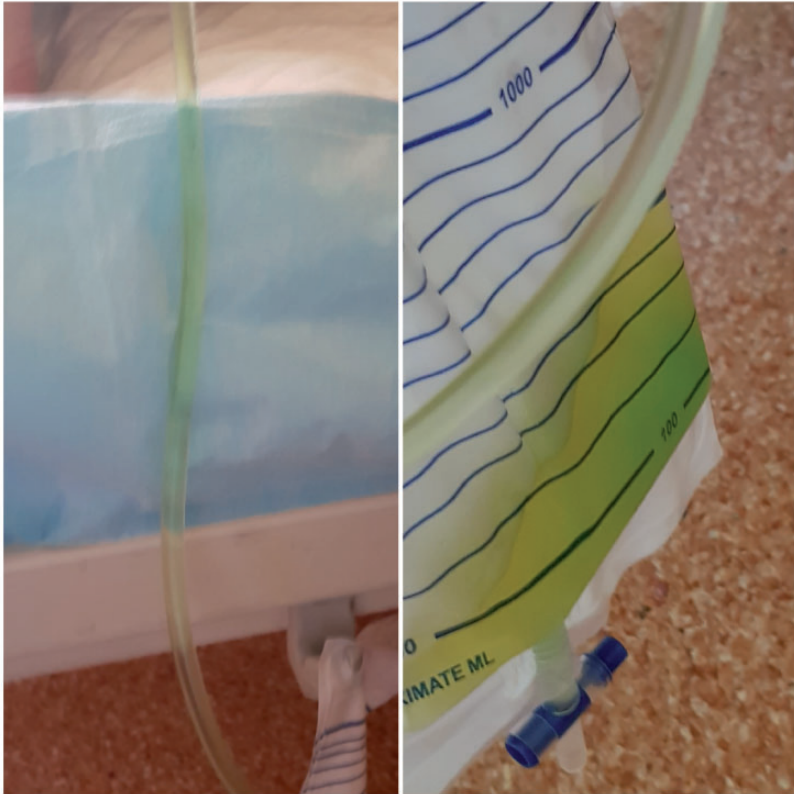
### Case 2

A 32-year-old woman with secondary amenorrhoea and a BMI of  $23.8 \text{ kg/m}^2$  was incapable of becoming pregnant. She had

undergone caesarean section 5 years previously and hysteroscopic resection of intrauterine adhesions secondary to Asherman's syndrome 4 months previously. According to the surgical protocol, the uterine cavity was released to the area of the uterine ostium of the fallopian tubes. The patient underwent laparoscopy with chromopertubation to assess the patency of the fallopian tubes during the middle of her follicular period. The laparoscopic procedure revealed adhesion of the major omentum with the abdominal wall. The adhesion was released, and the uterus with adnexa was visualised. After filling the uterine cavity with methylene blue, no contrast or flow through either fallopian tube was observed. Contrast produced by methylene blue solution was observed in the uterine wall and perimetrium vessels. After a few hours, the patient's urine turned green.

### Case 3

A 34-year-old woman with eumenorrhoea and a BMI of  $24.1 \text{ kg/m}^2$  had been incapable of becoming pregnant for 3 years. She had undergone appendectomy at the age of 15 years and hysteroscopic resection of the intrauterine partial septum (class Vb according to the ASRM classification) 3 months before presentation. According to the surgical protocol, the intrauterine septum was completely released. Because intra-abdominal adhesions were suspected, the patient underwent diagnostic laparoscopy with chromopertubation during the middle of her follicular period. The laparoscopic examination revealed grade 2 endometriosis according to the ASRM classification and solid adhesions between the adnexa and anterior wall of the abdomen. After filling the uterine cavity with methylene blue, partial contrast and no flow through both fallopian tubes was observed. Contrast produced by methylene blue solution was observed in the uterine wall and



**Figure 4.** Green urine (sign) was observed a couple of hours after chromopertubation.

perimetrium vessels. After a few hours, the patient's urine turned green.

Urine and blood samples were obtained from all patients, and postoperative cystoscopy was performed to rule out bladder injury. Bladder wall damage was not observed.

Laboratory tests confirmed the presence of methylene blue in the blood and urine. Twenty-four hours after the procedure, the urine had returned to its standard colour without the presence of blue dye solution. The patients' general condition was normal. The green urine sign had no negative impact on the patients' health.

### Laboratory tests

Methylene blue was detected in the blood and urine samples using ultra-high-performance liquid chromatography coupled with time-of-flight mass spectrometry. Chromatographic analysis was performed using ultra-high-performance liquid chromatography (Agilent 1290; Agilent Technologies, Santa Clara, CA, USA). Differentiation was performed on Poroshell column (120 EC-C18,  $3.0 \times 100$  mm,  $2.7 \mu\text{m}$ ; Agilent Technologies) at a temperature of  $40^\circ\text{C}$ . The tested compound was detected with hybrid use of a quadrupole mass

analyser and time-of-flight mass spectrometry system (Q-TOF-MS 6540; Agilent Technologies) in mass spectrometry mode. The spectrometer was equipped with electrospray ionization Jet Stream source.

## Discussion

After analysing the above phenomenon, a question was asked: Why does the methylene blue appear in the patient's urine and what are the consequences?

Initially, we assumed that the appearance of green-coloured urine was the result of bladder damage. During cystoscopy, however, we confirmed the absence of such damage. Therefore, we hypothesised that because of the high pressure resulting from filling the uterine cavity with the methylene blue solution, the contrast penetrated the superficial endometrial capillaries. The veins of the muscular layer then transported the solution into the uterine venous plexus, after which it was transported through the uterine veins into the internal iliac veins, the ovarian veins, and finally the renal veins. From there it travelled to the kidneys, where it was filtered and excreted in the urine. The green colour of the urine was the result of the blue dye of the methylene solution mixing with the yellow dye of urobilinogen.

The literature reports a similar mechanism of the above-described phenomenon during HSG. This phenomenon was called intravasation, which the authors described as a complication and potential pitfall of HSG and analogous procedures, including hysteroscopy. The estimated frequency of intravasation during HSG ranges from 0.4% to 6.9%.<sup>6-8</sup>

Dusak et al.<sup>7</sup> established the following four-level intravasation severity classification: level 0 (no intravasation), level 1 (mild intravasation with minimal invasion limited to the myometrium), level 2 (moderate intravasation involving the venous

uterine plexus and occurring slowly), and level 3 (severe intravasation involving the venous uterine plexus and appearing immediately).

Factors predisposing to the occurrence of intravasation during HSG have been identified in many reports. The most frequently mentioned are performance of the procedure during the early postmenstrual and late preovulatory periods; the presence of Mullerian duct anomalies; pelvic discomfort and unusual lingering pain during HSG; menometrorrhagia; polycystic ovary syndrome; endometriosis; uterine malformations related to secondary infertility, recurrent miscarriages, endometrial injury, complicated delivery, and Asherman's syndrome; and subclinical urinary infections.<sup>6,7</sup>

No consensus has been reached regarding the role of high pressure in the uterine cavity during HSG. Our hypothesis assumes that a main cause of the green urine sign following intravasation is the short-lasting increase in pressure in the uterine cavity during chromopertubation. This has been confirmed by many studies.<sup>8-10</sup> However, Dusak et al.<sup>7</sup> proved that the phenomenon of intravasation with the use of hydrosoluble contrast media during HSG does not depend on the increase in contrast pressure in the uterine cavity: at 70 mmHg of pressure, the authors observed this phenomenon at level 1 intravasation severity.

Our hypothesis requires further studies to determine the significance of the pressure increase, which may impact the risk of hyperhydration during long-lasting intra-uterine procedures with low-viscosity media (e.g., hysteroscopy).<sup>11</sup>

Previous reports have also described the intravasation phenomenon with the HSG procedure during the performance of hysterosalpingo-foam sonography (HyFoSy) and transvaginal four-dimensional hysterosalpingo-contrast sonography with SonoVue (TV 4D HyCoSy).<sup>12-14</sup> Ludwin et al.<sup>12</sup>



presented a case report of mild intravasation during HyFoSy using air/saline as a contrast agent. The risk factor for intravasation specified in the cited publication was unilateral occlusion of the fallopian tube. According to the authors, this caused a complication in the form of nonthrombocytopenic palpable purpura associated with moderate leg pain as a symptom of cutaneous small-vessel vasculitis in response to the contrast agent. The authors suggested that information on this type of rare complication should be attached to the patient's informed consent form.<sup>12</sup>

He et al.<sup>13</sup> reported that the occurrence of intravasation during TV 4D HyCoSy significantly affected the diagnostic image quality, which decreased as the level of this complication increased. Shi et al.<sup>14</sup> identified risk factors for intravasation during 4D HyCoSy TV. The most important were conditions associated with secondary infertility, tubal patency, and endometrial thickness of <5.45 mm.<sup>14</sup>

Notably, the estimated frequency of intravasation during HyCoSy ranges from 26.3% to 27.9%.<sup>13,14</sup> This is almost four times higher than the frequency during HSG.<sup>6-8</sup> The following question thus arises: What is the difference in the frequency of occurrence of intravasation in otherwise similar procedures?

Some authors have stated that the probable cause of the higher incidence of intravasation during HyCoSy is the low viscosity and particle size of the contrast agent as well as the use of another catheter for the procedure. The use of a Foley catheter during HyCoSy might cause higher contrast pressure and vessel damage in the uterine cavity compared with the Leech-Wilkinson catheter used during HSG.<sup>13,14</sup>

Analysing the discussions in the above-mentioned reports reveal that the cited authors point to the same mechanism and similar risk factors for intravasation. By eliminating predisposing factors, it is possible to minimise or prevent

intravasation and reduce its potential consequences.<sup>6-9,12-14</sup> Therefore, we treat the green urine sign as a complication of laparoscopic chromopertubation.

This is in line with the definition of a complication as a deviation from the desired course of the medical procedure; it does not always indicate a violation of the standard of care, medical neglect, or medical malpractice.<sup>15</sup> Clinical observation revealed no health consequences for our three patients with the green urine sign. These cases also raise the question of whether the green urine sign is an indication for cystoscopy in all cases. Teeluckdharry et al.<sup>16</sup> suggested that cystoscopy should be performed in all cases in which bladder injury is suspected.

## Conclusion

The green urine sign appeared as a consequence of severe intravasation and disappeared after 24 hours. The patients' vital parameters and renal function were monitored. Additionally, cystoscopy was performed to rule out bladder damage. All patients had risk factors for intravasation.

Intravasation should be kept in mind during all intrauterine procedures because the possibly increased risk of hyperhydration and its life-threatening consequences. Gynaecologists should be familiar with the risk factors for intravasation to reduce or eliminate the occurrence of this phenomenon and related complications.

## Declaration of conflicting interest

The authors declare that there is no conflict of interest.

## Ethics

This study was approved by the Local Bioethics Committee (KE-0254/287/2019). All patients described in this report provided written informed consent.

## Funding

This research received no specific grant from any funding agency in the public, commercial, or not-for-profit sectors.

## ORCID iD

Piotr Szkodziak  <https://orcid.org/0000-0002-3582-067X>

## References

1. Kodaman PH, Arici A and Seli E. Evidence-based diagnosis and management of tubal factor infertility. *Curr Opin Obstet Gynecol* 2004; 16: 221–229.
2. Ott J, Hager M, Nouri K, et al. Assessment of tubal patency: a prospective comparison of diagnostic hysteroscopy and laparoscopic chromopertubation. *J Minim Invasive Gynecol*. Epub ahead of print 2019.
3. Lepenies J, Toubekis E, Frei U, et al. Green urine after motorcycle accident. *Nephrol Dial Transplant* 2000; 15: 725–726.
4. Leclercq P, Loly C, Delanaye P, et al. Green urine. *Lancet* 2009; 373: 1462.
5. Urushidani S and Kuriyama A. Green urine. *QJM* 2015; 108: 675–675.
6. Bhoil R, Sood D, Sharma T, et al. Contrast intravasation during hysterosalpingography. *Polish J Radiol* 2016; 81: 236–239.
7. Dusak A, Ekinci F, Görük N, et al. Venous intravasation as a complication and potential pitfall during hysterosalpingography: re-emerging study with a novel classification. *J Clin Imaging Sci* 2014; 3: 67.
8. Chang M and Shim JJ. Venous intravasation: a potential pitfall of confirmatory hysterosalpingogram following essure hysteroscopic sterilization. *J Radiol Case Rep* 2012; 6: 18.
9. Nunley WC, Bateman BG, Kitchin JD, et al. Intravasation during hysterosalpingography using oil-base contrast medium - a second look. *Obstet Gynecol* 1987; 70: 309–312.
10. Bradley LD. Complications in hysteroscopy: prevention, treatment and legal risk. *Curr Opin Obstet Gynecol* 2002; 14: 409–415.
11. Darwish AM and Zareh Hassan ZEA. Haemodynamic, biochemical and haematological changes during hysteroscopic myomectomy. *Gynaecol Endosc* 2002; 11: 349–355.
12. Ludwin A, Ludwin I, Szczeklik W, et al. Cutaneous small-vessel vasculitis after hysterosalpingo-foam sonography (HyFoSy). *Ultrasound Obstet Gynecol*. Epub ahead of print 20 June 2019.
13. He Y, Wu H, Xiong R, et al. Intravasation affects the diagnostic image quality of transvaginal 4-dimensional hysterosalpingo-contrast sonography with SonoVue. *J Ultrasound Med* 2019; 38: 2169–2180.
14. Shi J, Li S, Wu H, et al. The influencing factors of venous intravasation during transvaginal four-dimensional hysterosalpingo-contrast sonography with SonoVue. *Ultrasound Med Biol*. Epub ahead of print June 2019.
15. Jacobs JP, Jacobs ML, Mavroudis C, et al. What is operative morbidity? Defining complications in a surgical registry database. *Ann Thorac Surg* 2007; 84: 1416–1421.
16. Teeluckdharry B, Gilmour D and Flowerdew G. Urinary tract injury at benign gynecologic surgery and the role of cystoscopy. *Obstet Gynecol* 2015; 126: 1161–1169.