



2020

Chylothorax after coronary artery bypass surgery. Report of a case and review of the literature

Follow this and additional works at: <https://www.j-saudi-heart.com/jsha>



Part of the [Cardiology Commons](#)



This work is licensed under a [Creative Commons Attribution-Noncommercial-No Derivative Works 4.0 License](#).

Recommended Citation

Khan, Imran; Khan, Zahid M.; El Refy, Abdelbasset; El Badry, Ahmad Mahmood; and Babiker, Tarig Faisal (2020) "Chylothorax after coronary artery bypass surgery. Report of a case and review of the literature," *Journal of the Saudi Heart Association*: Vol. 32 : Iss. 2 , Article 4.

Available at: <https://doi.org/10.37616/2212-5043.1031>

This Case Report is brought to you for free and open access by Journal of the Saudi Heart Association. It has been accepted for inclusion in Journal of the Saudi Heart Association by an authorized editor of Journal of the Saudi Heart Association.

Chylothorax after coronary artery bypass surgery. Report of a case and review of the literature

Imran Khan*, Zahid M. Khan, Abdelbasset El Refy, Ahmad Mahmood El Badry, Tarig Faisal Babiker

Department of Cardiothoracic Surgery, Al Mana General Hospital, Al Khobar, Saudi Arabia

Abstract

Chylothorax after coronary artery bypass grafting is a rare complication and leads to increased mortality and morbidity. Because of the rarity of this complication, its management is debatable. We present the case of a 41 years old male patient who had a left sided chylothorax after coronary artery bypass grafting. The patient was managed conservatively with low fat diet and drainage of the chylothorax. A thorough search of the literature published on the subject was done and treatment strategies employed by various authors were studied. Various treatment options are conservative management with chest tube drainage, octreotide and low-fat diet or diet containing medium chain triglycerides. Invasive options are video assisted thoracoscopy and thoracotomy with or without ligation of thoracic duct. An account of the management strategies employed by various authors is presented in this report.

Keywords: Chylothorax, Coronary artery bypass grafting, Management

1. Introduction

Chylothorax is the presence of lymphatic fluid, or chyle, in the thoracic cavity. The incidence of chylothorax is 0.4–4% in esophageal procedures to 2.5%–4.7% in congenital cardiac procedures [1,2]. But chylothorax after coronary artery bypass grafting has been described very rarely. This is probably because lymphatics are valved and normally these valves are competent. Also the anatomy of the thoracic duct keeps it safe in surgical revascularization. In most cases the thoracic duct traverses up the chest on the right side of the aorta and at the level of T4-T5 travels to the left side ascending in the chest and then projects for a short while into the neck. It ends by entering the junction of subclavian vein and internal jugular vein by curving down. But this ‘normal’ course is found in

only 50–60% of the population and in 12–15% cases, there is anomalous course and aberrant tributaries of the duct [3]. The left anterior mediastinal lymph node chain crosses the left internal mammary artery (LIMA) anteriorly near its origin. It joins the thoracic duct or in some cases, enters the venous confluence directly. This chain is vulnerable to injury during harvesting of LIMA, especially if the mammary vein is divided proximally [4]. Injury to anomalous peri-thymic lymphatics and use of electrocautery in lymphatic rich area rather than suturing for hemostasis are some of the mechanisms [5]. Because of the rarity of chylothorax after CABG, there is no consensus on the management strategy. This report describes the case of chylothorax after CABG and sheds light on the previously reported cases and management strategies.

Received 9 April 2020; revised 13 April 2020; accepted 14 April 2020.
Available online 8 May 2020

* Corresponding author at: Al Mana General Hospital, Department of Cardiothoracic Surgery, Prince Talal Street, Al Khobar city, PO 311, Eastern Province, Saudi Arabia.
E-mail addresses: cardiac.imran@gmail.com (I. Khan), Zahidkhan2000@hotmail.com (Z.M. Khan), aelfrey@hotmail.com (A. El Refy), Badorry_451@yahoo.com (A.M. El Badry), tfbabiker@hotmail.com (T.F. Babiker).



2. Case report

A 41 years old gentleman, known diabetic and hypertensive, presented with chest pain, palpitations and diaphoresis. He was diagnosed to have non-ST elevation myocardial infarction and a subsequent coronary angiography showed multivessel coronary artery disease. The patient was scheduled for elective coronary artery bypass grafting. The CABG included a pedicled LIMA to left anterior descending (LAD) artery, great saphenous vein to right coronary artery (RCA), obtuse marginal (OM) and diagonal coronary arteries. Left pleura was widely opened during harvesting of the LIMA and thymus was dissected with electrocautery. The patient had an uneventful postoperative course and discharged on the 10th day.

Just 3 days after discharge, the patient presented with shortness of breath and tiredness. On examination, breath sounds were greatly diminished on left side of the chest. A postero-anterior chest X-Ray was done that showed large left sided pleural effusion [Fig. 1](#).

Chest drain was inserted that drained 2400 ml milk colored fluid.

The patient rapidly improved symptomatically with drainage of the effusion. A Gram staining and Ziel Nelson staining of the pleural fluid did not show any organism. But the initial biochemical analysis showed triglyceride of 1575 mg/dl (normal <110 mg/dl) and cholesterol less than 50 mg/dl. Chylothorax was diagnosed and the patient was rendered nil by mouth and total parenteral nutrition was started. The chest tube drainage dropped to 1000 ml on the second day, 600 ml on the third and 300 ml on fourth day. A low-fat diet was then started. The drainage

decreased further and the tube was removed on day seventh. The patient was then discharged with clear both lung fields and in a normal and stable condition. One month later, the patient was asymptomatic and chest X-Ray showed no pleural effusion ([Fig. 2](#)).

3. Discussion

Chylothorax after coronary artery bypass grafting poses a unique problem. If it doesn't respond to conservative management, invasive management must be adopted. This complication can lead to deleterious consequences like immunosuppression, dehydration, malnutrition and respiratory dysfunction in a patient who is already recovering from a major open-heart surgery [6]. But luckily, the incidence is rare [1]. A thorough search of the available English language literature identified less than 50 cases. Various strategies have been used to manage this complication including a conservative approach with chest tube drainage and dietary changes, pharmacologic management with the use of somatostatin and its analogues and invasive management that involves thoracotomy or thoracoscopy to control the chyle leakage.

3.1. Conservative management

Conservative management involves nil per os (NPO), total parenteral nutrition, chest tube drainage of the chyle, and later when the drainage has decreased significantly, starting a low-fat diet or

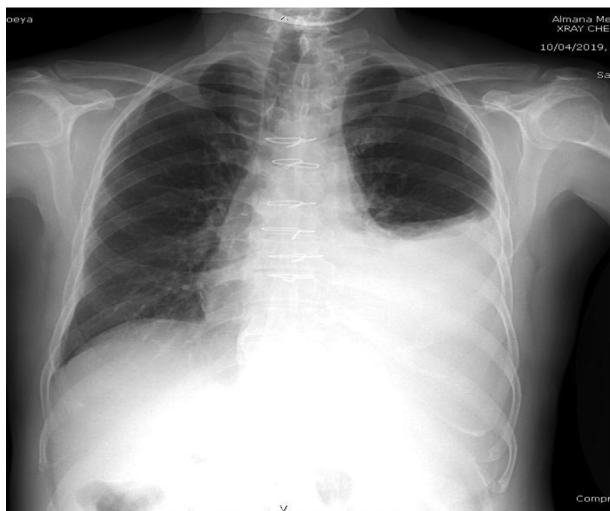

Fig. 1. Chest X-Ray showing left sided pleural effusion.

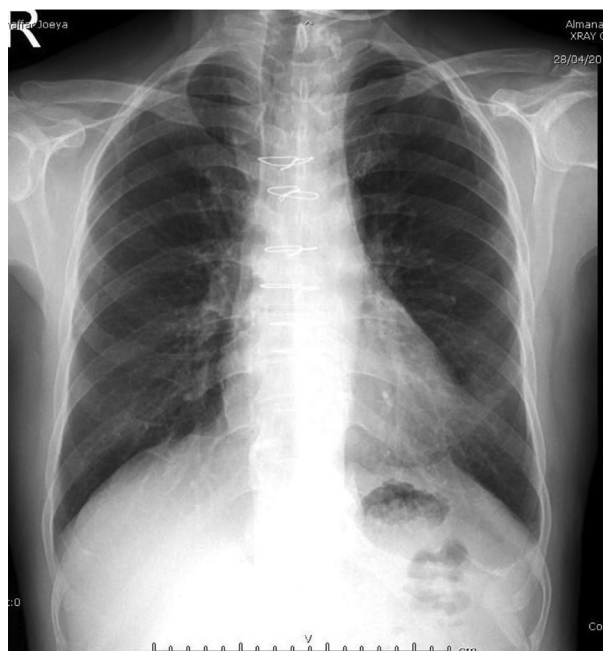


Fig. 2. Chest X-Ray on follow up.

a diet rich in medium chain triglycerides (MCTG). Most of the authors seem to have employed this regimen (Table 1). Excluding long chain triglycerides from the diet ensures a decreased chylomicron transportation to the intestinal lymphatic ducts. It has been suggested that a 10–14 days trial of conservative management is plausible. In case the drainage persists beyond this, invasive strategy should be followed [7]. Some of the disadvantages of conservative management are deterioration in nutritional status and vulnerability to infections because of depletion of lymphocytes.

3.2. Octreotide

Octreotide is a synthetic analogue of somatostatin which inhibits growth hormones, glucagon and insulin, more potently than somatostatin. It has been used with success in GI fistulae. The use of Octreotide for post CABG chylothorax seems to have increased recently [24]. Most authors have used a dose of 50–100 µg subcutaneously for 10–14 days. If somatostatin is used, it must be used intravenously because of its short half-life [6]. Side

effects such as hypoglycemia and hypotension should be looked for when treating patients with octreotide. The exact mechanism of action is not known but receptors having high affinity for somatostatin have been described on human lymphatics [25]. Table 2 presents a summary of the published cases where octreotide was used.

3.3. Invasive management

Invasive options are VATS, thoracotomy, median sternotomy. Most authors agree suggest that surgery should not be delayed for more than 1–2 weeks or the output remains more than 1000 ml/day [7,27]. Historically, lymphangiography and high fat content food has been administered before the invasive procedure to localize the leaking site. But high fat content food has been shown to be preferable because the ducts damaged mostly in CABG are small in size [33]. Various strategies during invasive management are duct ligation, pleural flap cover, biological sealants and suturing of the leaking area [7]. If a delayed diagnosis is made, lavage and pleurodesis should be done through VATS because

Table 1. Summary of the reported cases of conservative management of chylothorax after coronary artery bypass grafting.

Author	Procedure	Age/ Gender	LIMA/ RIMA	Site	Surgery to diagnosis duration (days)	Management
Weber et al., 1981 [8]	CABG	55 y/M	LIMA	L & M	2	Chest tube drainage, MCTG, drain removed on 12th POD, discharged home on 14th POD
Zakhour et al., 1981 [9]	CABG	73 y/M	LIMA	L	90	Chest tube drainage, MCTG, drainage resolved on 21st day
Zakhour et al., 1981 [9]	CABG	59 y/M	N	L & M	2	Chest tube drainage, MCTG, resolved after 5 days
Kshetry et al., 1982 [10]	CABG	51 y/M	N	L	60	Chest tube drainage, resolved after 4 days
Teba et al., 1985 [11]	CABG + MVR	51 y/F	N	L	7	Chest tube drainage, resolved after 17 days
Davies et al., 1994 [12]	CABG	48 y/M	LIMA	L	21	Chest tube drainage, MCTG, resolved after 4 weeks
Smith et al., 1994 [13]	CABG	60 y/M	LIMA	L	14	Chest tube drainage, MCTG, resolved after 15 days
Smith et al., 1994 [13]	CABG	47 y/M	LIMA	L	7	Chest tube drainage, MCTG, resolved after 14 days
Zaidenstein et al., 1996 [5]	CABG	70 y/F	LIMA	L	42	Chest tube drainage, low fat diet, resolved after 16 days
Mohanty et al., 1998 [14]	CABG	56 y/M	LIMA	L	8	Chest tube drainage, MCTG, resolved after 22 days, the sternum was rewired at day 9
Sharpe et al., 1999 [15]	CABG	63 y/F	N	L & M	11	Chest tube drainage, TPN, Pigtail drainage initially and then pericardial window later-on for chylopericardium initially, resolved after 14 days
Priebe et al., 1999 [16]	CABG	75 y/F	LIMA	L & M	30	Chest tube drainage, discharged after 3 days as the chest X-Ray was clear, readmitted 2 weeks later with relapse of chylothorax, low fat diet, pleurodesis through chest tube, resolved after 2 months
Brancaccio et al., 2001 [17]	CABG	64 y/M	LIMA	L	6	Chest tube drainage, resolved after 11 days
Fahimi et al., 2001 [18]	CABG	51 y/M	LIMA	L	UK	Chest tube drainage, MCTG
Abid et al., 2003 [19]	CABG	58 y/M	LIMA	L	3	Chest tube drainage, MCTG, Talc pleurodesis after 8 days, resolved after one week
Halldorsson et al., 2006 [20]	CABG	47 y/F	N	R	10	Chest tube drainage, resolved after 10 days
karimi et al., 2010 [21]	CABG	53 y/M	LIMA	L	2	Chest tube drainage, low fat diet, resolved after 27 days
Mandak et al., 2011 [22]	CABG	76 y/F	LIMA	L	9	Chest tube drainage, NPO, TPN, resolved after 16 days
Sabzi et al., 2017 [23]	CABG	43 y/M	LIMA	L	0	Chest tube drainage, low fat diet, resolved after 10 days

Table 2. A summary of the published cases of chylothorax after coronary artery bypass grafting where octreotide was used in the management.

Author	Procedure	Age/ Gender	LIMA/ RIMA	Site	Surgery to diagnosis duration (days)	Management and Use of Octreotide/Somatostatin
Perez et al., 1999 [26]	CABG + AVR	68 y/M	UK	L & M	10	Chest tube drainage, TPN, MCTG, Octreotide, resolved after 10 days
Kelly et al., 2000 [27]	CABG	77 y/M	L	L	18	Chest tube drainage, NPO, TPN, Octreotide (50 µg SC TID for 14 days), resolved after 14 days
Gabbieri et al., 2004 [28]	CABG	67 y/F	LIMA	L	10	Chest tube drainage, TPN, NPO, Octreotide (100 µg SC TID), resolved after 28 days
Kilic et al., 2005 [29]	CABG	66 y/F	LIMA	L	12	Chest tube drainage, MCTG, Octreotide (100 µg SC TID), resolved after 10 days
Barbetakis et al., 2006 [30]	CABG	78 y/M	LIMA	L	27	Chest tube drainage, MCTG, Octreotide
Altun et al., 2015 [6]	CABG	60 y/M	LIMA	UK	2	Chest tube drainage, NPO, TPN, Somatostatin infusion @ 3.5 µg/kg/Hr, increased to 7 µg/Kg/Hr, resolved after 13 days
Altun et al., 2015 [6]	CABG	46 y/M	LIMA	UK	3	Chest tube drainage, NPO, TPN, Somatostatin infusion, resolved after 7 days
Owais et al., 2015 [31]	CABG	76 y/F	LIMA	L	15	Chest tube drainage, MCTG, Octreotide (100 µg SC 8 hourly), resolved after 7 days
Waikar et al., 2018 [24]	CABG	52 y/M	LIMA	L	6	Chest tube drainage, NPO, TPN, later on MCTG, Octreotide (100 µg SC 8 hourly), pleurodesis done with 7.5% povidone iodine on POD 11th, resolved after 14 days
Mukherjee et al., 2016 [32]	CABG	56 y/M	LIMA	L	3	Chest tube drainage, Octreotide, Tal pleurodesis after 30 days of conservative management, lung expanded after two days of pleurodesis
Mukherjee et al., 2016 [32]	CABG	50 y/M	LIMA	L	14	Chest tube drainage, Octreotide, Tal pleurodesis after 29 days of conservative management

Table 3. A summary of the reported cases of invasive management of chylothorax after coronary artery bypass grafting.

Author	Procedure	Age/ Gender	LIMA/ RIMA	Site	Surgery to diagnosis duration (days)	Management
Dilello et al., 1987 [36]	CABG	53 y/M	LIMA	L	9	Chest tube on POD 13th, supraclavicular approach to thoracic duct, multiple entries of TD to the vein were noticed, leakage ligated, drainage did not decrease so a left thoracotomy was done on POD 31, a diffuse leak from adhesion in the junctional area of mammary pedicle, subclavian vein and artery was noted, pleural flap was raised and the area sprayed with biological glue, the flap closed over the area, chyle drainage resolved after POD 7
Czarnecki et al., 1988 [37]	CABG	61 y/F	LIMA and RIMA	R	42	Conservative management failed after 10 days, right thoracotomy and ligation of the duct at diaphragm
Chaiyaroji et al., 1991 [38]	CABG	69 y/F	LIMA	L	6	Conservative management failed after 18 days, left thoracotomy and clipping at the leakage site
Inderbitzi et al., 1992 [39]	Redo- CABG	69 y/M	UK	L	2	Left VATS, fibrin glue spray
Bogers et al., 1993 [7]	CABG	41 y/M	LIMA	L	1	Conservative management failed after 35 days, left thoracotomy and ligation at injury site
Wood et al., 1994 [40]	CABG	69 y/M	LIMA	L	3	Conservative failed after 7 days, left VATS ligation at injury site (proximal LIMA)
Janssen et al., 1994 [41]	CABG	58 y/M	LIMAL	L	35	Conservative failed after 2 weeks, left VATS and clipping of thoracic duct behind the aortic arch
Yamaguchi et al., 1996 [42]	CABG	64 y/M	LIMA	L	2	Conservative management failed after 3 weeks, left thoracotomy

(continued on next page)

Table 3. (continued)

Author	Procedure	Age/ Gender	LIMA/ RIMA	Site	Surgery to diagnosis duration (days)	Management
Felz et al., 1997 [43]	CABG	50 y/F	LIMA	L	56	Left VATS ligation at injury site
Pego-Fernandez et al., 1997 [34]	CABG	38 y/M	LIMA	L	90	VATS for cleaning and lavage of thorax only
Venturini et al., 1999 [44]	CABG	67 y/M	LIMA	L	70	Left thoracotomy, ligation of the duct
Fahimi et al., 2001 [18]	CABG	49 y/M	LIMA	L	UK	Left VATS, fibrin glue
Riquet et al., 2004 [45]	CABG	59 y/F	LIMA	L	UK	Left thoracotomy, ligation at injury site (left anterior mediastinal lymph node chain)
Falode et al., 2005 [46]	CABG + ASD repair	68 y/F	LIMA	L	3	Left VATS, Talc pleurodesis
Choong et al., 2006 [4]	CABG	63 y/M	LIMA	L	2	Conservative management failed after 35 days, right thoracotomy and ligation at injury site (severed duct identified in thymic area)
Paul et al., 2009 [35]	CABG	65 y/M	UK	UK	UK	Conservative failed after 14 days, right thoracotomy and duct ligation at diaphragm
Deguchi et al., 2015 [47]	CABG	78 y/F	LIMA and RIMA	R	3	Conservative failed after 10 days, median sternotomy and ligation at injury site (injured lymphatic on right side of innominate vein)
Waliany et al., 2018 [48]	CABG	62 y/M	LIMA	L	13	Chest tube drainage, MCTG followed by TPN, thoracoscopic Talc pleurodesis on POD 33 but drainage remained high, so Doxycycline pleurodesis through chest tube on POD 40, course complicated by Yellow Nail Syndrome, resolved ultimately

adhesions in the area of thoracic duct following surgery will make dissection in this area very difficult and dangerous [34]. Most authors have preferred a left thoracotomy or VATS and clipping or ligation of the leakage area but a right thoracotomy and mass ligation of the duct at the diaphragm has also been done [35]. **Table 3.**

4. Conclusion

Chylothorax is a rare complication after coronary artery bypass grafting. Patients with a pedicled harvesting of left internal mammary artery harvesting are more prone to this complication. It appears from the published reports that most of the patients can be managed with a conservative management. In case of failure of conservative management, early invasive strategy should be resorted to avoid complications.

Funding

This research received no specific grant from any funding agency in the public, commercial, or not-for-profit sectors.

Conflicts of Interest

The authors have no conflicts of interest relevant to this article.

References

- [1] Miao L, Zhang Y, Hu H, et al. Incidence and management of chylothorax after esophagectomy. *Thorac Cancer* 2015;6(3): 354–8. <https://doi.org/10.1111/1759-7714.12240>.
- [2] Akbari Asbagh P, Navabi Shirazi MA, Soleimani A, et al. Incidence and aetiology of chylothorax after congenital heart surgery in children. *J Tehran Heart Cent* 2014;9(2):59–63.
- [3] Medina JE. Neck dissection. In: Bailey BJ, Johnson JT, editors. *Head and neck surgery: otolaryngology*. 4th ed., vol. 2. Philadelphia, Pa: Lippincott Williams and Wilkins; 2006. p. 1585–609 [Chapter 113].
- [4] Choong CK, Martinez C, Barner HB. Chylothorax after internal thoracic artery harvest. *Ann Thorac Surg* 2006;81: 1507–9.
- [5] Zaidenstein R, Cohen N, Dishi V, Alon I, Golik A, Modai D. Chylothorax following median sternotomy. *Clin Cardiol* 1996 Nov;19(11):910–2.
- [6] Altun G, Pulathan Z, Kutanis D, Hemsinli D, Erturk E, Civelek A. Conservative management of chylothorax after coronary artery bypass grafting. *Tex Heart Inst J* 2015 Apr; 42(2):148–51. <https://doi.org/10.14503/THIJ-13-3532>.
- [7] Bogers AJ, Pardijs WH, Van Herwerden LA, Bos E. Chylothorax as a complication of harvesting the left internal thoracic artery in coronary artery bypass surgery. *Eur J Cardio Thorac Surg* 1993;7(10):555–6.
- [8] Weber DO, Del Mastro P, Yarnoz MD. Chylothorax after myocardial revascularization with internal mammary graft. *Ann Thorac Surg* 1981;32(5):499–502.
- [9] Zakhour B, Drucker M, Franco A. Chylothorax as a complication of aortocoronary bypass. Two case reports and a review of the literature. *Scand J Thorac Cardiovasc Surg* 1988; 22(1):93–5.
- [10] Kshetry V, Rebello R. Chylothorax after coronary artery bypass grafting. *Thorax* 1982;37:954.
- [11] Teba L, Dedhia HV, Bowen R, Alexander JC. Chylothorax review. *Crit Care Med* 1985;13(1):49–52.

- [12] Davies MJ, Spyt TJ. Chylothorax and wound lymphocele formation as a complication of myocardial revascularization with the internal thoracic artery. *J Thorac Cardiovasc Surg* 1994;108(6):1155–6.
- [13] Smith JA, Goldstein J, Oyer PE. Chylothorax complicating coronary artery by-pass grafting. *J Cardiovasc Surg* 1994; 35(4):307–9.
- [14] Mohanty B, Craddock D, Stubberfield J. Chylothorax: an unusual complication following coronary artery bypass grafting using the left internal mammary artery. *Asia Pacific Hear J* 1998;7(3):220–2.
- [15] Sharpe DA, Pullen MD, McGoldrick JP. A minimally invasive approach to chylopericardium after coronary artery surgery. *Ann Thorac Surg* 1999;68(3):1062–3.
- [16] Priebe L, Deutsch HJ, Erdmann E. Chylothorax as a post-operative complication of aortic coronary bypass operation. *Dtsch Med Wochenschr* 1999;124:855–88.
- [17] Brancaccio G, Prifti E, Cricco AM, Totaro M, Antonazzo A, Miraldi F. Chylothorax: a complication after internal thoracic artery harvesting. *Ital Heart J* 2001;2(7):559–62.
- [18] Fahimi H, Casselman FP, Mariani MA, et al. Current management of postoperative chylothorax. *Ann Thorac Surg* 2001;71(2):448–50.
- [19] Abid Q, Millner RW. Chylothorax following coronary bypass grafting: treatment by talc pleurodesis. *Asian Cardiovasc Thorac Ann* 2003;11(4):355–6.
- [20] Halldorsson A. Chylothorax after coronary artery bypass grafting. *Int Surg* 2009;94(2):119–29.
- [21] Karimi A, Salehiomran A, Yazdanifard P. Chylothorax after coronary artery bypass and internal mammary artery harvesting: a case report. *East Mediterr Health J* 2010;16(10): 1103–4.
- [22] Mand'ák J, Habal P, Stětina M, Harrer J. Chylothorax—a rare complication after cardiac surgery (a case report). *Acta Med* 2011;54(1):37–9.
- [23] Sabzi F, Faraji R. Early chylothorax after coronary artery bypass grafting. *Zahedan J Res Med Sci* 2017;19(8):e9067. <https://doi.org/10.5812/zjrms.9067>.
- [24] Waikar HD, Kamalaneson P, Mohamad Zamri MS, Jayakrishnan AG. Chylothorax after off-pump coronary artery bypass graft surgery: management strategy. *Ann Card Anaesth* 2018;21:300–3.
- [25] Sreedharan SP, Kodama KT, Peterson KE, Goetzl EJ. Distinct subsets of somatostatin receptors on cultured human lymphocytes. *J Biol Chem* 1989;264:949–52.
- [26] Pérez J, Casal J, Rodríguez W. Always remember chylothorax. *South Med J* 1999;92(8):833–5.
- [27] Kelly RF, Shumway SJ. Conservative management of post-operative chylothorax using somatostatin. *Ann Thorac Surg* 2000;69(6):1944–5.
- [28] Gabbieri D, Bavutti L, Zaca F, Turinetto B, Ghidoni I. Conservative treatment of postoperative chylothorax with octreotide. *Ital Heart J* 2004;5(6):479–82.
- [29] Kilic D, Sahin E, Gulcan O, Bolat B, Turkoz R, Hatipoglu A. Octreotide for treating chylothorax after cardiac surgery. *Tex Heart Inst J* 2005;32(3):437–9.
- [30] Barbetakis N, Xenikakis T, Efstathiou A, Fessatidis I. Successful octreotide treatment of chylothorax following coronary artery bypass grafting procedure. A case report and review of the literature. *Hellenic J Cardiol* 2006;47(2): 118–22.
- [31] Owais T, Back D, Girdauskas E, Kuntze T. Postoperative Chylothorax: is octreotide a valid therapy? *J Case Reports Stud* 2015;3(3).
- [32] Mukherjee K, Chakrabarty U, Dasbakshi K, Roymukherjee S, Saha E, Mukherjee P. Management of chylothorax after coronary artery bypass grafting: two case reports and review of literature. *Indian J Chest Dis Allied Sci* 2016 Apr-Jun;58(2): 131–4.
- [33] Cerfolio RJ, Allen MS, Deschamps C, Trastek VF, Pairolero PC. Postoperative chylothorax. *J Thorac Cardiovasc Surg* 1996;112:1361–6.
- [34] Pêgo-Fernandes PM, Ebaid GX, Nouer GH, Munhoz RT, Jatene FB, Jatene AD. Chylothorax after myocardial revascularization with the left internal thoracic artery. *Arq Bras Cardiol* 1999;73(4):383–90.
- [35] Paul S, Altorkl NK, Port JL, Stiles BM, Lee PC. Surgical management of chylothorax. *Thorac Cardiovasc Surg* 2009; 57(4):226–8.
- [36] Di Lello F, Werner PH, Kleinman LH, Mullen DC, Flemma RJ. Life-threatening Chylothorax after left internal mammary artery dissection: therapeutic considerations. *Ann Thorac Surg* 1987;44(6):660–1.
- [37] Czarnecki DJ, Kehoe ME, Tector AJ. Lymphangiographic evaluation of chylothorax after myocardial revascularization. *Am J Roentgenol* 1988;151(5):1054–5.
- [38] Chaiyaraj S, Mullerworth MH, Tatoulis J. Surgery in the management of chylothorax after coronary artery bypass with left internal mammary artery. *J Thorac Cardiovasc Surg* 1993;106(4):754–6.
- [39] Inderbitzi RG, Krebs T, Stirneman T, Ulrich A. Treatment of postoperative chylothorax by fibrin glue application under thoracoscopic view with use of local anesthesia. *J Thorac Cardiovasc Surg* 1992;104(1):209–10.
- [40] Wood MK, Ullyot DJ. Chylothorax. *J Thorac Cardiovasc Surg*. 1994;108(6):1156.
- [41] Janssen JP, Joosten HJM, Postmus PE. Thoracoscopic treatment of postoperative chylothorax after coronary bypass surgery. *Thorax* 1994;49(12):1273.
- [42] Yamaguchi T, Watanabe G, Kotoh K, Yamashita A, Sugiyama S, Misaki T. The changes in lymphocytes subpopulations of a patient with postoperative chylothorax. *Kyobu Geka* 1996;49:1085–7.
- [43] Felz MW, Neely J. Beware the left-sided effusion. *J Fam Pract* 1997;45(6):519–22.
- [44] E1 Venturini, Piccoli M, Francardelli L, Ballestra AM. [Chylothorax following myocardial revascularization with the internal mammary artery]. *G Ital Cardiol* 1999 Nov;29(11): 1334–6.
- [45] Riquet M, Assouad J, D'Attellis N, Gandjbakhch I. Chylothorax and re-expansion pulmonary edema following myocardial re-vascularization: role of lymph vessel insufficiency. *Interact Cardiovasc Thorac Surg* 2004;3(3):423–5.
- [46] Falode O, Hunt I, Young CP. Chylothorax after coronary artery bypass surgery. *J R Soc Med* 2005;98(7):314–5.
- [47] Deguchi K, Yamauchi T, Maeda S, Takeuchi M, Kin K, Takano H. Chylothorax after coronary artery bypass grafting using the right internal thoracic artery. *Gen Thorac Cardiovasc Surg* 2015;63(7):416–21.
- [48] Waliyany S, Chandler J, Hovsepian D, et al. Yellow nail syndrome with chylothorax after coronary artery bypass grafting. *J Cardiothorac Surg* 2018;13:93. <https://doi.org/10.1186/s13019-018-0784-8>.