

Incessant narrow-QRS tachycardia mediated by ventriculo-fascicular accessory pathway



Massimo Tritto, MD, Giammarco Spadacini, MD, Paolo Moretti, MD, Domenico Zagari, MD, Elvira Renzullo, MD, Aurora Sanniti, MD

From the Electrophysiology and Cardiac Pacing Unit, Humanitas Mater Domini Hospital, Castellanza, Italy.

Introduction

Accessory pathway (AP) variants¹ including nodofascicular or nodoventricular fibers are uncommonly reported but may have significant clinical implications and present difficulties in electrophysiological evaluation and treatment.²⁻⁷

We report an unusual case of incessant orthodromic atrioventricular (AV) reentrant tachycardia mediated by a ventriculo-fascicular (VF) AP resulting in severe left ventricular dysfunction and successfully treated with catheter ablation.

Case report

A 34-year-old man was referred to our institution for incessant, narrow-QRS tachycardia and congestive heart failure symptoms due to severe left ventricular dysfunction (ejection fraction: 25%). Intermittent episodes of the same tachycardia had been reported since several years before admission and they were not prevented by antiarrhythmic drugs, including verapamil, flecainide, propafenone, and sotalol. Adenosine was ineffective in terminating the tachycardia. At surface 12-lead electrocardiogram (ECG), tachycardia had a rate of 200 beats/min, AV dissociation, and its onset—following a few normally conducted sinus beats—was associated with subtle changes in the QRS morphology, suggesting a right-to-left interventricular septal activation (Figure 1A).

An electrophysiological study was performed introducing multipolar catheters in the coronary sinus, His bundle (HB) region, right ventricular septum (RVS), and right ventricular apex (RVA). In particular, HB and RVS electrodes were deployed to display the whole HB activation. Baseline intervals in sinus rhythm were normal (AH: 65 ms, HV 55 ms); tachycardia initiated with an activation pattern resembling a 1:2

KEY TEACHING POINTS

- Unidirectional ventriculo-fascicular accessory pathways may be responsible for incessant atrioventricular orthodromic reentrant tachycardias and tachycardiomyopathy occurrence.
- Detailed His bundle activation analysis through multielectrode catheters during either sinus rhythm or ongoing tachycardia, and multisite pacing maneuvers, may provide the correct diagnosis of the tachycardia mechanism and accessory pathway insertion.
- Cryoablation confirms to be safe and effective in para-Hisian arrhythmogenic substrates.

AV response (ie, dual HB activation following a single atrial beat), tachycardia cycle length (CL) duration measured 310 ms, and HB electrograms always preceded the QRS complexes (HV: 50 ms) (Figure 1B). HB activation was proximal-to-distal in sinus rhythm, while distal and proximal HB electrodes were simultaneously activated during tachycardia. Finally, atrial activation was dissociated from ventricular activation, and it never interfered with ongoing tachycardia during sinus rhythm, overdrive atrial pacing, or atrial fibrillation (Supplemental Figure 1). Being incessant, the role of atrial or ventricular stimulation in tachycardia initiation could not be tested. Conversely, tachycardia was repeatedly terminated by premature ventricular beats (PVBs) or overdrive ventricular pacing.

To allow differential diagnosis with other narrow-QRS tachycardias with ventriculoatrial (VA) dissociation, single PVBs were delivered from the distal RVS or RVA during ongoing tachycardia. Late coupled PVBs, delivered at a time when the HB was refractory, advanced the next HB electrogram and reset the tachycardia (Figure 2). This finding indicated the presence of an AP and excluded AV nodal reentrant tachycardia (AVNRT) with conduction block in the upper common pathway, junctional ectopic tachycardia (JET), and intra-Hisian reentrant tachycardia (IHRT). Moreover, shortening of PVB coupling intervals resulted in tachycardia reset with

KEYWORDS Accessory pathway; Cryoablation; Mahaim fiber; Orthodromic reentry; Nodoventricular bypass tract; Para-Hisian pacing; Tachycardiomyopathy

(Heart Rhythm Case Reports 2020;6:558–563)

This research did not receive any specific grant from funding agencies in the public, commercial, or not-for-profit sectors. All authors state that they have no conflicts of interest. **Address reprint requests and correspondence:** Dr Massimo Tritto, Electrophysiology and Cardiac Pacing Unit, Humanitas Mater Domini Hospital, Via Gerenzano, 2, 21053 Castellanza (VA) – Italy. E-mail address: m.tritto@libero.it.

progressive fusion at surface ECG (Figure 2). This feature demonstrated that the ventricle was involved in the reentry and ruled out a nodofascicular bypass tract. Tachycardia reset curve, obtained by plotting PVB coupling intervals vs V2-H2 time intervals, showed a wide excitable gap in the reentry circuit (>80 ms) and an increasing pattern (Figure 2D). Overdrive pacing from RVA also resulted in tachycardia entrainment with progressive fusion at surface ECG and postpacing intervals always exceeding the tachycardia CL by less than 115 ms, thus confirming the previous findings. Finally, programmed stimulation was performed also from the anterosuperior aspect of the RVS. During this maneuver, premature beats delivered from the para-Hisian area captured the HB and reset the tachycardia with a QRS morphology similar to that observed during sinus rhythm (Figure 3A and Supplemental Figure 2). Conversely, PVBs delivered slightly more distally and very late coupled (after the right bundle branch activation) also reset the tachycardia with concealed fusion at surface ECG (Figure 3B and Supplemental Figure 2). Thus, based on the HB activation sequence and the response to pacing maneuvers, this region was deemed as the proximal insertion of the AP and tachycardia was diagnosed as orthodromic reentry occurring through a VF bypass tract (Figure 1C and Supplemental Figure 3).

Catheter ablation was performed using a 4-mm-tip cryoenergy catheter (Freezor; CryoCath Technologies Inc, Montreal, Canada) targeting the earliest HB activation. During the first cryoapplication the tachycardia was interrupted (at -50°C) but resumed (with functional right bundle branch block) after catheter defrosting. After repositioning the catheter at a slightly more proximal position, another cryoapplication resulted in stable tachycardia termination (at -30°C, Figure 3C). Accordingly, catheter tip temperature was lowered to -75°C and cryoenergy delivery prolonged for 240 seconds while checking for AV conduction integrity with overdrive atrial pacing. The postablation electrophysiological study revealed normal anterograde AV conduction parameters and absence of VA conduction. Tachycardia was no longer observed spontaneously or inducible with programmed electrical stimulation performed in baseline condition and during intravenous isoprenaline administration.

After hospital discharge the patient remained asymptomatic without arrhythmia recurrences or AV conduction abnormalities at repeated Holter monitoring. Full recovery of the left ventricular function was observed at 3-month 2D echocardiogram.

Discussion

Narrow-QRS tachycardias with stable or intermittent VA conduction block are rare, but they might have significant clinical implications, including incessant pattern and tachycardiomyopathy occurrence.^{4,6,7} Differential diagnosis includes AVNRT with conduction block in the upper common pathway, JET, IHRT, and orthodromic reentry through nodofascicular or nodoventricular AP.¹ In this respect, ventricular stimulation performed during ongoing tachycardia provides key insights in distinguishing among

tachycardia mechanisms. In particular, His-synchronous PVBs advancing the next HB activation and resetting the tachycardia unequivocally demonstrate the presence of an AP. Furthermore, either tachycardia reset or entrainment occurring with progressive fusion at surface ECG proves the involvement of the ventricle in the reentry circuit.¹ These features allowed us to rule out all tachycardias whose substrate is confined to the conduction system (ie, AVNRT, JET, IHRT) as well as to establish that, in the present case, the distal insertion of the AP was at the ventricular level. In fact, if the AP had been attached to one fascicle, the antidromically propagating paced wavefront had to fully penetrate the conduction system to reset or entrain the tachycardia, thus making overt fusion impossible to occur. Moreover, careful HB activation mapping with multielectrode catheters and the response to pacing maneuvers performed from the anterosuperior aspect of the RVS allowed us to prove that the AP had a proximal insertion at the fascicular level (penetrating AV bundle or proximal right bundle branch). In fact, the simultaneous activation of the proximal and distal HB electrodes during tachycardia is not consistent with an AV nodal insertion of the AP (Figure 1C and Supplemental Figure 3) since, in that case, HB activation would have been proximal-to-distal (as during sinus rhythm). Similarly, this activation pattern cannot even support a 1:2 AV conduction at tachycardia onset, as proposed in other reported cases.^{2,6} Conversely, unidirectional anterograde conduction block and slow retrograde activation through the VF AP may allow reentrant propagation from the normally conducted sinus beat as well as the incessant pattern of the tachycardia. This hypothesis is confirmed by para-Hisian reset maneuvers. In fact, proximal HB pacing resulted in QRS morphology nearly matching that of sinus rhythm (antidromic impulse propagation), while very late coupled PVBs promptly reset tachycardia with concealed fusion, indicating that the paced area was very close to the AP attachment (Figure 3, and Supplemental Figures 2 and 3). Notably, also the QRS morphology changes observed at tachycardia onset—indicating a right-to-left interventricular septal activation—support a fascicular insertion of the AP, possibly in correspondence of predestined fibers directed toward the right bundle.^{8,9} Finally, this tachycardia shares some 12-lead ECG and intracardiac activation features with the “upper septal” variant of idiopathic left ventricular tachycardia.¹⁰ However, in this case, the HB is retrogradely activated with an HV interval much shorter than during sinus rhythm and it is not actively involved in the reentry circuit. Accordingly, pacing from the anterosuperior aspect of the basal RVS should not result in tachycardia reset/entrainment with concealed fusion and postpacing intervals equal to tachycardia CL, as occurred in our case.

Fibers connecting the AV bundle with the ventricular septal crest (namely fasciculo-ventricular AP) have been described in anatomical studies, and they usually account for a distinctive form of ventricular pre-excitation.^{1,8} Conversely, the active involvement of a VF AP in reentrant tachycardias, as demonstrated in our case, has been rarely

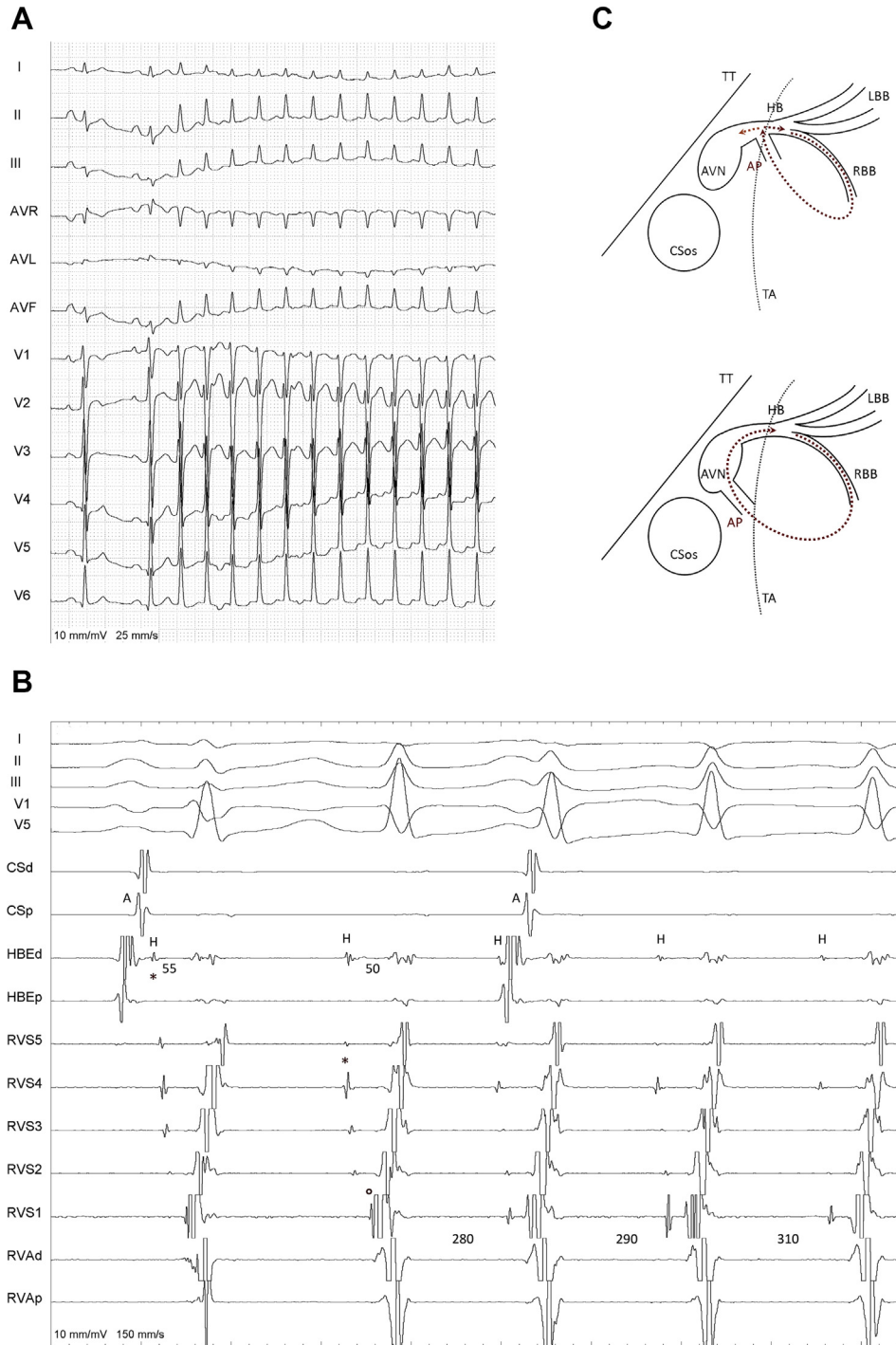


Figure 1 Tachycardia 12-lead electrocardiogram, intracardiac recordings, and reentry circuit diagram. **A:** After 2 normally conducted sinus beats a narrow QRS tachycardia with atrioventricular (AV) dissociation starts. Compared to sinus rhythm, tachycardia QRS complexes show lower R-wave amplitude in lead V₁, Q-wave disappearance in leads V₅–V₆, and slight downward shift of the QRS axis. These findings are consistent with a right-to-left interventricular septal activation. **B:** From top to bottom, electrograms recorded from catheters placed in the coronary sinus (CS), His bundle region (HB), right ventricular septum (RVS), and right ventricular apex (RVA) are shown. P and 5 indicate the proximal recordings; d and l the distal ones; A, atrial electrogram; and H, HB electrogram. All measures are in ms and refer to consecutive deflections when not otherwise indicated. During sinus rhythm (first beat) HB activation is proximal-to-distal (H_{HBEd}–H_{RVS4}: 15 ms; asterisk indicates the earliest HB recording). Spontaneous tachycardia initiation (second beat) is associated with a change in the HB activation sequence (H_{HBEd}–H_{RVS4}: 0 ms), indicating a retrograde impulse propagation occurring along the proximal HB but not in the distal His-Purkinje system. This activation pattern also excludes that these electrograms result from retrograde conduction along an accessory pathway (AP). Compared to sinus rhythm, the HV interval is slightly shorter (50 ms) and the earliest ventricular activation is recorded at the right bundle branch (open circle). Ventriculoatrial dissociation is present. **C:** Based on intracardiac activation sequence and the response to pacing maneuvers (see also [Figures 2 and 3](#) and [Supplemental Figures 2 and 3](#)), the tachycardia mechanism is consistent with an orthodromic reentry occurring through an AP inserting distally into the right ventricle and proximally into the AV penetrating bundle, respectively (dotted red arrows in the upper panel). Dotted orange arrow indicates retrograde impulse penetration within the proximal HB. The lower panel depicts how the reentrant activation would have been (dotted red arrow) whether AP was attached to the AV node (slow AV nodal pathway area). In this case HB activation should occur proximal-to-distal (as during sinus rhythm). AVN = AV node; LBB = left bundle branch; RBB = right bundle branch; TA = tricuspid annulus; TT = tendon of Todaro.

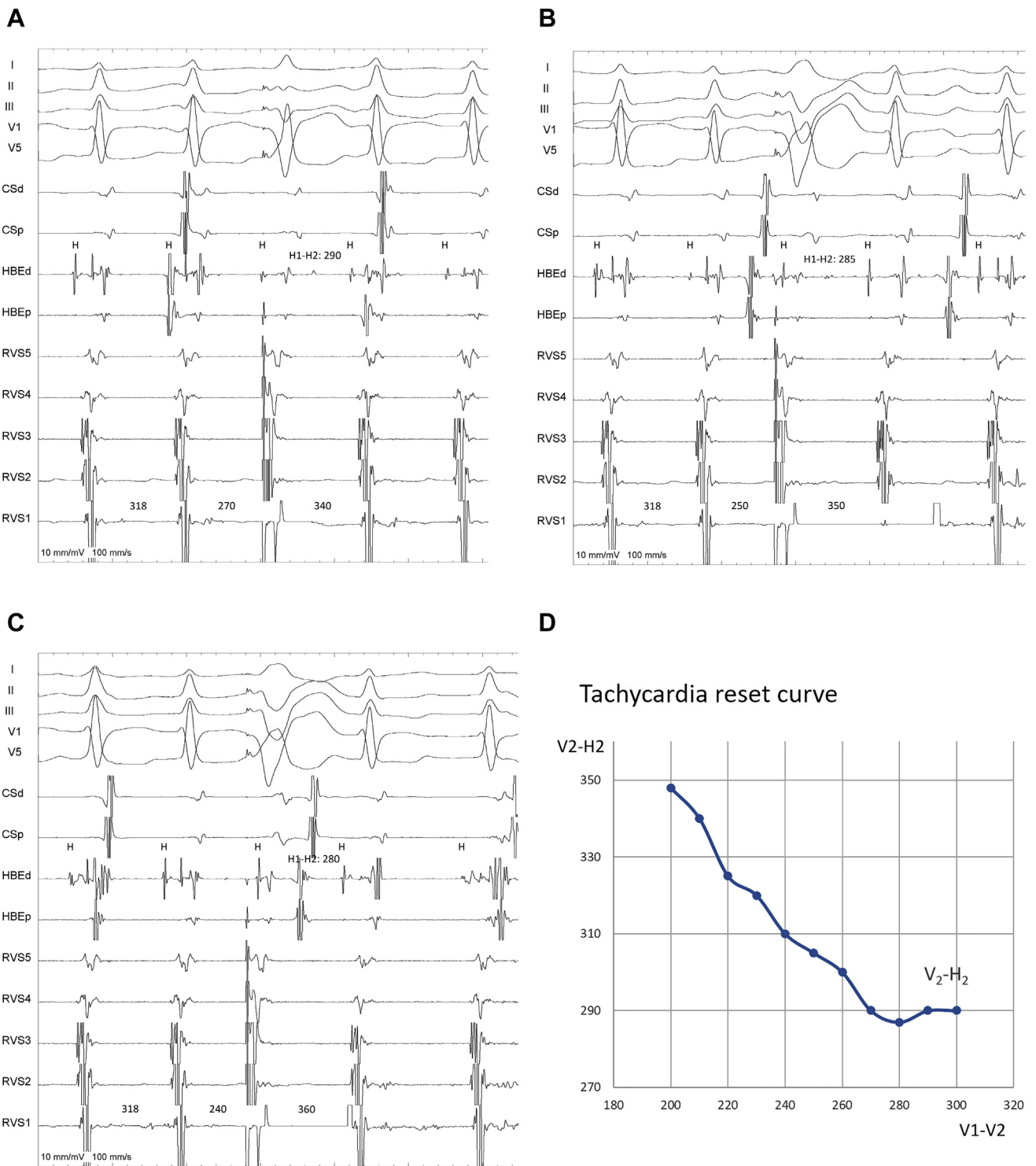


Figure 2 Premature ventricular stimulation from the right ventricular apex and tachycardia reset curve. In panels A to C intracardiac recordings are arranged as in Figure 1. **A:** A premature ventricular beat (PVB) synchronous with the His bundle (HB) activation advances the next HB electrogram (to 290 ms) and resets the tachycardia. PVBs introduced with progressively shorter coupling intervals reset the tachycardia with varying degree of fusion at surface electrocardiogram (**A–C**). These findings prove the involvement of an accessory pathway with a distal attachment at the ventricular level in the tachycardia reentry circuit. **D:** PVBs with a coupling interval ≤ 280 ms reset the tachycardia. Progressive shortening of PVB coupling intervals (V1-V2) up to ventricular refractoriness (200 ms) is associated with increasing V2-H2 intervals, indicating slow conduction in the retrograde arm of the reentry circuit.

reported so far.⁷ Moreover, the electrophysiological properties of these APs are not well known^{1,8}; slow conduction seems relatively intuitive (prolonged VH interval during

reentrant tachycardia), but the coexistence of decremental conduction is less clear. The increasing pattern of tachycardia reset curve obtained in our case strongly suggests

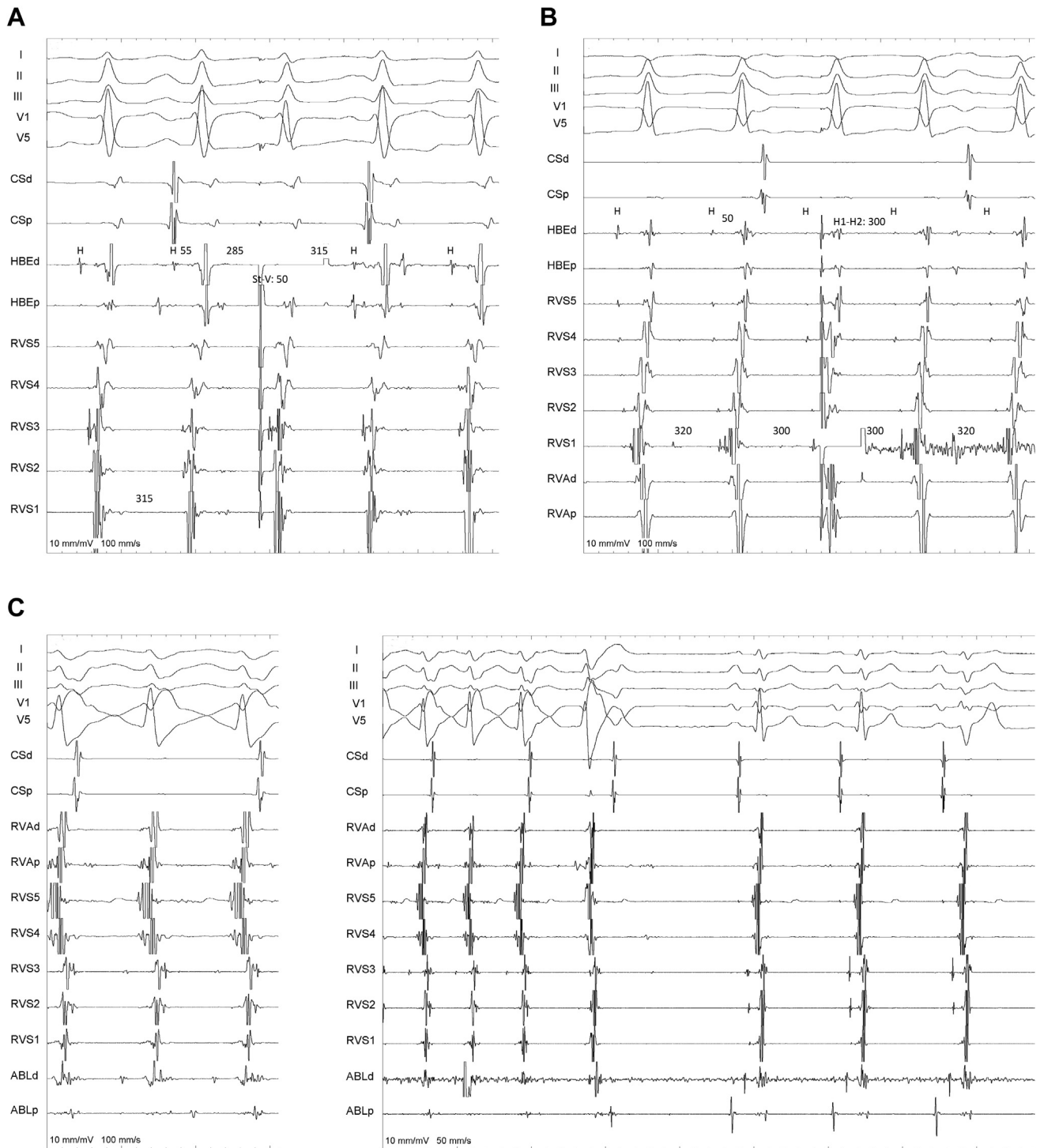


Figure 3 Tachycardia reset from the para-Hisian area and catheter cryoablation. In all panels intracardiac recordings are arranged as in Figure 1. **A:** A premature beat delivered from the His bundle (HB) catheter with a 285 ms coupling interval (H1-H2) directly captures the HB, advances the QRS complex, and reset the tachycardia. The ST-V interval is similar to the tachycardia HV interval, and the postpacing interval (ST-H) matches the tachycardia cycle length duration (315 ms). The subtle changes in the morphology of the advanced QRS (small S wave in lead I, small Q wave in lead V₅) are consistent with possible antidromic capture of the proximal HB. **B:** A very late coupled premature beat (V1-V2: 300 ms), delivered slightly more distally (RVS1) after the right bundle branch activation, locally captures the ventricle without producing QRS fusion at surface electrocardiogram, but it still advances the next HB electrogram and resets the tachycardia. These findings also support the reentry circuit depicted in Figure 1C. RVS = right ventricular septum. **C:** An HB potential is present on the mapping catheter (ABLd) at the ablation site. **D:** During cryoenergy delivery (at -30°C) tachycardia terminates. Note the disappearance of the functional right bundle branch block and the HB deflection still visible on the ablation catheter recordings.

decremental conduction along the bypass tract (Figure 2D). Nonetheless, whether this behavior is related to unique structural features of the AP (ie, nodal-like cell types, asymmetrical architecture with nonuniform anisotropic conduction properties) or to functional changes in refractoriness owing to rate is unknown.^{1,8} Finally, catheter ablation of VF AP is challenging, since the exact localization of the proximal insertion of the bypass tract cannot be established according to reliable electrophysiological markers, especially when the retrograde atrial activation is missing. Hence, the correct diagnosis of the AP type through careful HB activation mapping and pacing maneuvers is key to establishing the proper target for catheter ablation. In this respect, the misdiagnosis of nodoventricular AP could explain some failures that occurred when ablation was attempted in the slow AV nodal pathway area.^{2,3,5,6} Recently, Chung and colleagues⁷ described a similar reversed HB activation pattern occurring in 3 of 7 cases with ventricular-Hisian or ventricular-nodal APs, and in 2 of them catheter ablation was successfully attempted from the right coronary cusp. Although we did not map the left para-Hisian area, in our case the electrophysiological data as well as the response to catheter ablation were strongly consistent with a right-sided insertion on the AP.

Catheter ablation was performed using cryoenergy owing to the good safety profile and the partial lesion reversibility demonstrated on other septal substrates.¹¹ Moreover, catheter adherence also provides the opportunity to test the integrity of the AV conduction system by atrial pacing performed during energy delivery.

Conclusions

Unidirectional, slowly and decrementally conducting VF AP may result in incessant orthodromic reentrant tachycardia and severe left ventricular dysfunction. Careful mapping with multielectrode catheters and pacing maneuvers allows to correctly diagnose the tachycardia mechanism and, in

particular, to identify the proper ablation target. Finally, catheter cryoablation was confirmed to be safe and effective in para-Hisian arrhythmogenic substrates.

Appendix Supplementary data

Supplementary data associated with this article can be found in the online version at <https://doi.org/10.1016/j.hrcre.2020.05.015>.

References

1. Hoffmayer KS, Han FT, Singh D, Scheinman MM. Variants of accessory pathways. *Pacing Clin Electrophysiol* 2020;43:21–29.
2. Haissaguerre M, Campos J, Marcus FI, Papoin G, Clementy J. Involvement of a nodofascicular connection in supraventricular tachycardia with VA dissociation. *J Cardiovasc Electrophysiol* 1994;5:854–862.
3. Hamdan MH, Kalman JM, Lesh MD, et al. Narrow complex tachycardia with VA block: diagnostic and therapeutic implications. *Pacing Clin Electrophysiol* 1998; 21:1196–1206.
4. Quinn RF, Mitchell LB, Mardell AP, Disler D, Veenhuyzen GD. Entrainment mapping of a concealed nodoventricular accessory pathway in a man with complete heart block and tachycardia-induced cardiomyopathy. *J Cardiovasc Electrophysiol* 2008;19:90–94.
5. Roberts-Thomson KC, Seiler J, Raymond JM, Stevenson WG. Exercise induced tachycardia with atrioventricular dissociation: what is the mechanism? *Heart Rhythm* 2009;6: 426–228.
6. Han FT, Riles EM, Badhwar N, Scheinman MM. Clinical features and sites of ablation for patients with supraventricular tachycardias from concealed nodofascicular and nodoventricular tachycardias. *JACC Clin Electrophysiol* 2017; 3:1547–1556.
7. Chung R, Wazni O, Dersing T, et al. Clinical presentation of ventricular-Hisian and ventricular-nodal accessory pathways. *Heart Rhythm* 2019;16:369–377.
8. Anderson RH, Sanchez-Quintana D, Mori S, et al. Unusual variants of pre-excitation: from anatomy to ablation: part I – understanding the anatomy of the variants of ventricular pre-excitation. *J Cardiovasc Electrophysiol* 2019; 30:2170–2180.
9. Narula OS. Longitudinal dissociation in the His bundle. Bundle branch block due to asynchronous conduction within the His bundle in man. *Circulation* 1978; 57:996–1006.
10. Nogami A. Purkinje-related arrhythmias part I: monomorphic ventricular tachycardias. *Pacing Clin Electrophysiol* 2011;34:624–650.
11. Bravo L, Atenza F, Eidelman G, et al. Safety and efficacy of cryoablation vs. radiofrequency ablation of septal accessory pathways: systematic review of the literature and meta-analysis. *Europace* 2018;20:1334–1342.