

STITCHLESS Percutaneous Endoscopic Cervical Discectomy Are We Moving Towards Day Care Discectomy Procedure?

Abstract

Background: STITCHLESS percutaneous endoscopic cervical discectomy s[PECD] is safe, precise, targeted, and a complete endoscopic procedure to treat soft cervical disc herniation with unilateral radiculopathy. It allows direct visualization of herniated fragment and its removal, inspection of decompressed nerve root in an awake and aware patient. It reduces the risk related to general anesthesia and to the neurological structures. However, all the patients treated with PECD can be candidates for anterior cervical discectomy and fusion (ACDF). ACDF requires a longer period of stay, expense, and more risk to neurological structures and ultimately loss of the disc space by fusion. **Materials and Methods:** Twenty consecutively treated patients by sPECD over a period of 2 years with soft cervical disc herniation and unilateral radiculopathy were included in the study. PECD enables removal of offending fragment under vision and irrigation and ablation of inflammation with few complications. All patients were followed for minimum of 6 months with visual analog score (VAS) and neck disability index (NDI). **Results:** All treated patients had a good outcome in terms of pain relief (VAS) and functional recovery (NDI). One patient had episodes of cough lying in the supine position and another patient had transient hoarseness of voice, (both recovered). **Conclusion:** Potential benefits of sPECD include safety as it is done under local anesthesia, smaller incision, short hospitalization, fewer complications, avoidance of fusion, preservation of segmental motion, preventing the adjacent segment degeneration, and avoidance of the risk related to the hardware (nonunion and pseudarthrosis). sPECD is an effective treatment modality for soft cervical disc herniation.

Keywords: Cervical radiculopathy, decompression, minimally invasive spine surgery, soft disc herniation, STITCHLESS percutaneous endoscopic cervical discectomy

MeSH terms: Radiculopathy, cervical vertebrae, decompression, minimal access surgical procedure

**Sunil M Nadkarni,
Pavankumar Kohli,
Bhupesh Patel¹,
Satishchandra
Gore,
Bhagyashree S
Kulkarni¹**

*Departments of Orthopedics and
¹Spine Surgery, Shree Vithalrao
Joshi Charities Trust's B.K.L.
Walawalkar Hospital and Rural
Medical College, Dervan,
Ratnagiri, Maharashtra, India*

Introduction

Anterior cervical approach, popularized by Smith Robinson, Cloward, Bailey and Badgley is a well-established approach for cervical disc disease¹ and is safe, less traumatic because of tissue dissection along anatomical plane.¹⁻⁴

Stookey first described clinical symptoms and anatomical location of cervical disc herniation.⁵ Cervical disc herniation presents in the form of headache, neck pain, unilateral or bilateral arm pain (radiculopathy), or motor and sensory deficit.⁶ Symptomatology of cervical disc herniation is a result of mechanical compression and chemical irritation of nerve roots.⁶⁻⁸ Mechanical compression (herniated fragment) can be diagnosed by imaging study (magnetic resonance imaging [MRI] or computed tomography [CT] scan) and chemical irritation by clinical examination by locating

dermatomal distribution of pain.^{6,9} Majority of patients respond well with conservative treatment; however, where natural resolution of inflammation fails, we need intervention.⁶ Neck and upper limb pain incidence shows a dramatic increase with the use of computers, smartphones and tablets, office-based jobs, and long hours of sitting in wrong postures. Percutaneous endoscopic cervical discectomy (PECD) may prove to be a boon in the long run, especially for such young patients.

Cervical disc herniation may be soft disc herniation or hard disc herniation. Hard herniation is due to collagenization and subsequent osteophyte formation.^{6,8} Current treatment options are anterior cervical discectomy (ACD) only and anterior cervical discectomy with fusion (ACDF).^{6-8,10}

Current trend in evolution of spine surgery is minimally invasive approach which

Address for correspondence:

*Dr. Sunil M Nadkarni,
Ankur, 12 Shanta Sahakari
Society, 394/B, Kusalkar Road,
Pune - 411 016, Maharashtra,
India.
E-mail: sunilnadkarni@gmail.
com*

Access this article online

Website: www.ijoonline.com

DOI:
10.4103/ortho.IJOrtho_283_16

Quick Response Code:



How to cite this article: Nadkarni SM, Kohli P, Patel B, Gore S, Kulkarni BS. STITCHLESS percutaneous endoscopic cervical discectomy: Are we moving towards day care discectomy procedure?. Indian J Orthop 2017;51:653-7.

This is an open access article distributed under the terms of the Creative Commons Attribution-NonCommercial-ShareAlike 3.0 License, which allows others to remix, tweak, and build upon the work non-commercially, as long as the author is credited and the new creations are licensed under the identical terms.

For reprints contact: reprints@medknow.com

involves less tissue dissection, less blood loss, reduction in hospital stay, early functional recovery, and better cosmesis which may be important in cervical region.¹¹⁻¹³ Introduction of stitchless endoscopic procedure has reduced tissue trauma further. It aims at removing offending herniated disc fragment responsible for radicular symptoms. It is also called targeted fragmentectomy.^{1,9,11-14}

We can avoid the risk of general anesthesia and need of neuro monitoring by doing surgery under local anesthesia. Soft disc herniation can be tackled by stitchless percutaneous endoscopic surgery under local anesthesia.^{1,7,9,12,13}

This study presents the outcome measures of stitchless percutaneous endoscopic surgery in patients with soft cervical disc herniation with unilateral radicular pain.^{12,13}

Materials and Methods

Twenty patients of cervical disc herniation operated at our hospital by single surgeon between July 2013 and December 2015 were analysed in this retrospective study. Out of twenty patients, 70% ($n = 14$) were males and 30% ($n = 6$) were females, age ranged between 25 and 63 years. The inclusion criteria were unilateral radicular pain extending below the elbow with or without motor or sensory deficit, no clinical improvement after fair trial of conservative treatment, and soft disc herniation on MRI matching with clinical picture. Patients with hard disc herniation, foraminal osteophyte, spinal canal stenosis, cervical myelopathy, bilateral symptoms, cervical kyphosis, gross disc height reduction, degenerative listhesis, and clinical symptoms not matching with images were excluded from the study. Outcome was measured by visual analogue score (VAS) and neck disability index (NDI). For statistical analysis, we used Wilcoxon's signed rank test which is a nonparametric alternative to paired t -test as the sample size is <30 . To draw the conclusion, we used R software output.^{1,9,11-13,15}

Operative procedure

All surgical procedures were performed under local infiltration anesthesia with or without a superficial and deep cervical block based on the anesthetist's preference.

Patient was placed in a supine position with neck extended by placing a pillow under shoulders and soft silicon ring to prevent rotation of head. Shoulders were pulled down by applying adhesive tape to visualize lower cervical spine. Local part prepared with povidone-iodine solution and draped with sterile sheets [Figure 1].

Under C-arm guidance, the needle was inserted medial to the anterior border of sternocleidomastoid between carotid sheath and midline viscera from the opposite side of the herniation. With the use of sustained pressure using the three middle fingers of one hand, the space between the carotid sheath and midline viscera was opened by pushing visceral axis to feel the cervical vertebra with the middle finger. After infiltration with local anesthetic (1:1 mix of 0.5% lignocaine and 0.5% bupivacaine, total of about 10 ml), the needle was inserted into the center of desired disc space under C-arm guidance. A guidewire was then passed, over which dilators were inserted. Working sheath of desired shape was then passed over dilator and position was confirmed under C-arm. Dilator was then removed once the position of dilator, and working sheath was appropriate (with respect to the fragment) under the C-arm [Figure 2].

Endoscope (Karl Storz) with working channel of 2.5 mm was then inserted and fragment was identified. Fragmentectomy was done with different types of graspers; hook, and suction cannula was used to tease the fragment and release it with grasper. Hook was also used to mobilize the nerve root and confirmed the complete removal of offending fragments. Fresh epidural bleeding, visualization of nerve root, and subsidence of pain were used as signs of complete removal of the fragment [Figure 3]. We used to inject Depo-Medrol (methylprednisolone) 80 mg at the end of surgery, but now we use the platelet-rich fibrin plug (Dervan Plug) as it is showing promising results by reducing the postoperative inflammation and pain more rapidly and also based on *in vitro* evidence is expected to enhance annular healing.¹⁶⁻¹⁹ Soft cervical collar is applied after a light dressing.

Patient was mobilized after 2 hours and discharged from the hospital on coming morning just to complete

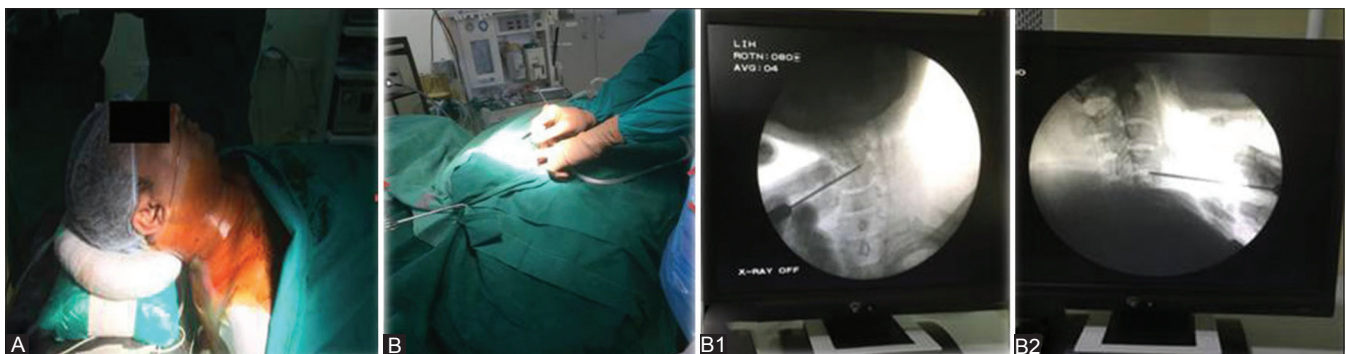


Figure 1: Surgical procedure. A: Patient in supine position, B: Needle insertion, B1: Anteroposterior view under the guidance of C-arm, B2: Lateral view under the guidance of C-arm

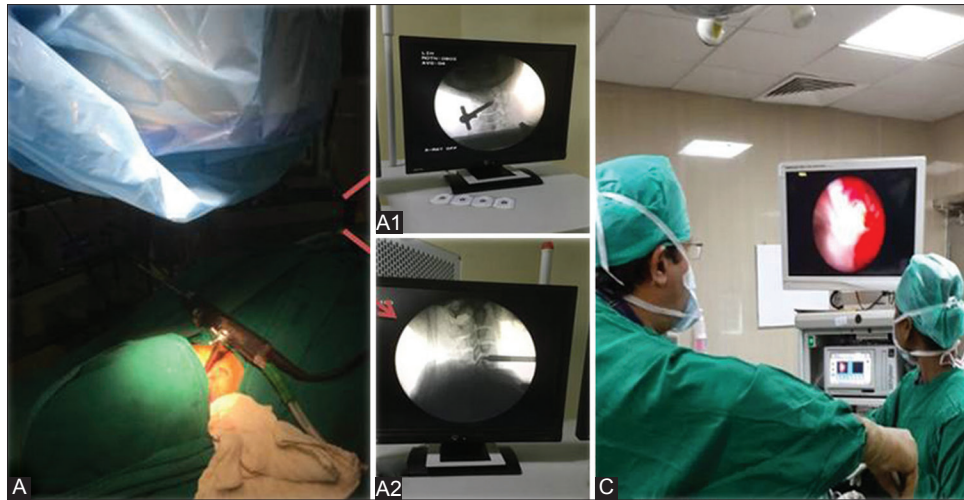


Figure 2: A: Dilator followed by sheath insertion. A1: anteroposterior view under the guidance of C-arm. A2: Lateral view under the guidance of C-arm. C: Identification of fragment by introducing endoscope through sheath with working channel of 2.5 mm

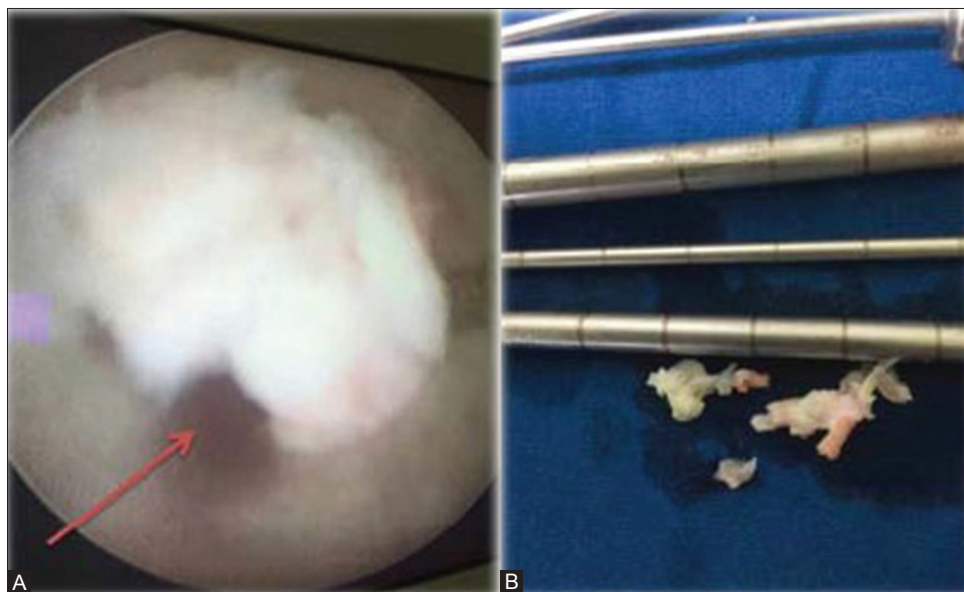


Figure 3: Surgical procedure. A: Endoscopic view of the herniated fragment to be removed. B: Removed herniated intervertebral disc tissue

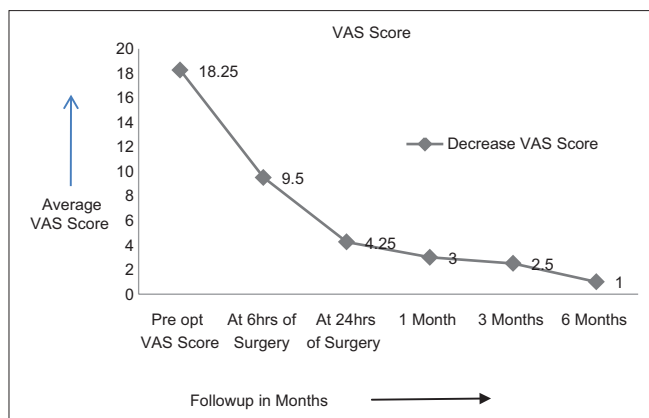
total three doses of intravenous (IV) antibiotic (injection cefuroxime 1.5 g before surgery and 750 mg two doses after surgery).

Results

We have followed all twenty patients to the assessment of surgical outcome for a postsurgical period of 6 months. VAS for pain was followed for next 6 months after the sPECD at the interval of 6 hrs immediately after surgery, 24 hrs after the surgery, after the 1 month, 3 months, and 6 months of postsurgical period. The postsurgical pain intensity (VAS) showed an average of 94.52% [Graph 1] of decrease from the preoperative pain intensity data ($P = 0.00045$). To assess the functional ability to manage in day-to-day activity, NDI was chosen as a best index for surgical outcome. All patients

were followed for the postsurgical period of 1 month, 3 months, and 6 months to assess neck disability by NDI after sPECD. The average preoperative NDI compared with postsurgical NDI [Graph 2] showed a significant improvement at postsurgical period of 1 month ($P = 0.00049$), 3 months ($P = 0.00043$), and 6 months ($P = 0.00045$). The average followup was of 6 months might serve as a limitation of the present study, so further comparative study with long followup period and increase sample size needs to be done. Results were considered statistically significant if P value for continuous variable was 0.05.

Overall observation and statistical data of the sPECD under local anesthesia in terms of patient's satisfaction were the receipt of success, but to present a tall conclusion further long term study needs to be done.



Graph 1: Outcome of surgery by visual analog score (VAS) showing the average decrease in the visual analog score after postsurgical period of 6 h, 24 h, 1 month, 3 months, and 6 months

On analyzing the surgical outcome, no adverse effects have seen, postoperative VAS score showed statistically significant improvements on followup as compared to the preoperative values ($P < 0.05$). NDI also showed statistically significant improvement between preoperative and postoperative values ($P < 0.05$).

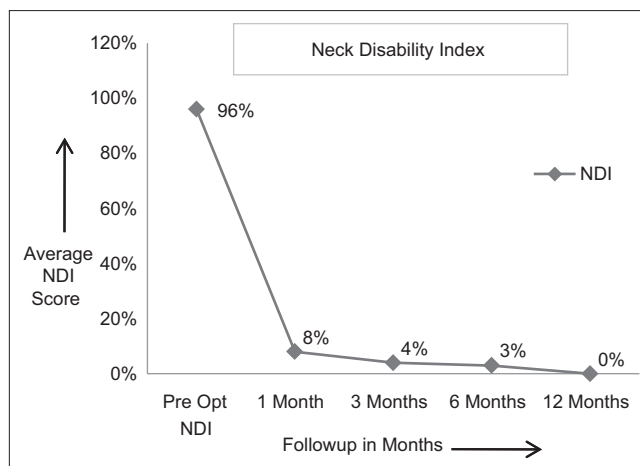
Although the short term postsurgical followup of 6 months might be a limitation of the study, the safety of sPECD showed that it can be the precise, targeted, and a complete endoscopic procedure to treat soft cervical disc herniation with unilateral radiculopathy.

Discussion

Cervical disc herniation causes radicular pain in upper extremities, neck pain, and headache.^{6,8} Long standing hard disc herniation may cause myelopathy.^{6,8,10} Mechanism of disc herniation-induced symptoms is due to mechanical compression over nerve roots and spinal cord and chemical changes induced by the herniated fragment.^{1,6,8} As the herniated fragment of nucleus pulposus was unknown to immune system, and its exposure to immune system due to annular tear induces inflammatory cascade and irritates the dorsal root ganglia which is akin to peripheral brain for sensory system and causes radicular pain.^{6,8} Mechanical compression over cord and nerve root may cause motor and sensory deficit.^{6,8}

Traditional treatment of the cervical disc herniation is divided into conservative and operative. Surgical treatment is becoming more precise as we have better and superfine anatomical analysis by MRI scans, and in sPECD, we can correlate the symptoms with visualized pathology which adds to our learning.

Operative treatment traditionally includes open cervical discectomy with or without fusion mainly by anterior approach^{1-5,10,11} based only on image analysis of changes in disc outline. It requires general anesthesia and the need to fuse that segment depending on surgeon's choice and clinical need. Some patients who have comorbidities may



Graph 2: Outcome of surgery by neck disability index (NDI) showing the average decrease in the neck disability after postsurgical period of 1 month, 3 months, 6 months, and 12 months

be at high risk of complications from general anesthesia. Since endoscopic discectomy is performed under local anesthesia, it would be particularly safe for such patients. With better imaging and clinical analysis, we should be targeting the offending disc fragment that is only possible with sPECD. As only the offending fragment is removed with good preservation of disc material function in that segment would be preserved to a large extent.^{1,7,12,13}

The hard disc herniation is difficult to tackle by our technique as the strength and size of instruments is a limiting factor. However, it can be tackled by the modification of the technique using high speed burr, trephine, and laser to break the osteophytes and the hard disc fragment. However, cervical myelopathy from ossification of posterior longitudinal ligament and hard disc herniation will have to be with open anterior or posterior decompression with or without fusion.^{2-4,10} Another concern is regarding damage to healthy annulus during access to the herniated disc. Radiation exposure during needle access is also high, especially during initial training periods but reduces with subsequent experience.

The advantage of our technique is that it is done under local anesthesia as day care procedure with only stab incision (5–6 mm) which does not require any stitch. Patient can walk on the same day and can be discharged from hospital on the same or next day. It avoids all risk related to general anesthesia. Since it is performed in an awake state, there is natural continuous neuromonitoring and feedback which adds greatly to patients' confidence.

There have been no serious complications or neurological deficits in our series. In one patient, however, there were bouts of coughing while in a supine position which lasted for 3 months and another patient had transient hoarseness of voice. We did not have any instability of the operated segment after surgery. All our treated patients have statistically significant improvement in the VAS and the NDI score, so our technique is safe and effective with good outcome.^{1,6,12,13}

Complications specific to ACD, ACDF, and ACDF with instrumentation include hardware and graft failures, neurologic injury, and neck-related complications. Hardware complications involve failures related to instrumentation.^{20,21} Reported incidence rates are from 1% to 20%; can include screw back out (2%–10%), plate fracture (2%), screw breakage (1%–7%), and plate migration (1%–3%). Graft fusion failures have also been described with an incidence that ranges from 3% to 9%. Interestingly, plate length, increasing age, use of allograft, and a reoperative procedure have been linked to a higher incidence of plate failure. Neurologic complications can also occur with cervical procedures including dural tears leading to cerebrospinal fluid leaks, spinal cord injuries, and nerve root injuries resulting in weakness (1%–5%) Dysphagia due to esophageal retraction and intubation has been reported to range from 4% to 16%. Postoperative neck hematoma causing airway obstruction has been reported. Esophageal perforations can also occur, especially during the opening approach to the vertebral body. These complications are totally avoided with sPECD.²²

The access related annular weakening is proposed to be dealt with the use of platelet-rich fibrin, and work is underway to study the growth of nucleus and annulus under the effect of platelet-related growth factors. It is already reported for lumbar spine.²³

The limitation of our study is that it is retrospective, nonrandomized study having only 6 months of followup and we have not compared the outcome with open surgery.

However, more studies are needed to firmly establish its effectiveness and for the procedure to be acceptable as a standard treatment modality for soft cervical disc herniation.

Conclusion

Results of our study indicate that the stitchless percutaneous anterior endoscopic cervical surgery under local anesthesia can become an effective treatment for soft cervical disc herniation.

Declaration of patient consent

The authors certify that they have obtained all appropriate patient consent forms. In the form the patient(s) has/have given his/her/their consent for his/her/their images and other clinical information to be reported in the journal. The patients understand that their names and initials will not be published and due efforts will be made to conceal their identity, but anonymity cannot be guaranteed.

Financial support and sponsorship

Nil.

Conflicts of interest

There are no conflicts of interest.

References

1. Tzaan WC. Anterior percutaneous endoscopic cervical discectomy for cervical intervertebral disc herniation: Outcome, complications, and technique. *J Spinal Disord Tech* 2011;24:421-31.
2. Robinson RA, Smith GW. Anterolateral cervical disc removal and interbody fusion for cervical disc system. *Bull Johns Hopkins Hosp* 1955;96:223-4.
3. Cloward RB. The anterior approach for removal of ruptured cervical disks. *J Neurosurg* 1958;15:602-17.
4. Bailey RW, Badgley CE. Stabilization of the cervical spine by anterior fusion. *J Bone Joint Surg Am* 1960;42-A:565-94.
5. Stookey B. Compression of the spinal cord due to ventral extradural cervical chondromas. *Arch Neur Psych* 1928;20:275-8.
6. Bono CM, Gary G, Gilbert TJ, Kreiner DS, Reitman C, Summers J, *et al.* Diagnosis and Treatment of Cervical Radiculopathy from Degenerative Disorders. NASS Clinical Guideline; 2010.
7. Sugawara T. Anterior cervical spine surgery for degenerative disease: A Review. *Neurol Med Chir (Tokyo)* 2015;55:540-6.
8. Urban JP, Roberts S. Degeneration of the intervertebral disc. *Arthritis Res Ther* 2003;5:120-30.
9. Lee JH, Lee SH. Clinical and radiographic changes after percutaneous endoscopic cervical discectomy: A long term followup. *Photomed Laser Surg* 2014;32:663-8.
10. Minamide A, Yoshida M, Yamada H, Nakagawa Y, Maio K, Kawai M, *et al.* Clinical outcomes of microendoscopic decompression surgery for cervical myelopathy. *Eur Spine J* 2010;19(3):487-93.
11. Maroon JC. Current concepts in minimally invasive discectomy. *Neurosurgery* 2002;51 5 Suppl:S137-45.
12. Yue JJ, Long W. Full endoscopic spinal surgery techniques: Advancements, indications, and outcomes. *Int J Spine Surg* 2015;9:17.
13. Kim Ch, Shin KH, Chung CK, Park SB, Kim JH. Changes in cervical sagittal alignment after single-level posterior percutaneous endoscopic cervical discectomy. *Global Spine J* 2015;5:31-8.
14. Fontanella A. Endoscopic microsurgery in herniated cervical discs. *Neurol Res* 1999;21:31-8.
15. Jwon HC, Kim CS, Kim SC, Kim TH, Jang JW, Choi KY *et al.* Posterior cervical microscopic foraminotomy and discectomy with laser for unilateral radiculopathy. *Chonnam Med J* 2015;51(3):129-34.
16. Tsai CH, Hsu HC, Chen YJ, Lin MJ, Chen HT. Using the growth factors-enriched platelet glue in spinal fusion and its efficiency. *J Spinal Disord Tech* 2009;22:246-50.
17. Kuffler DP. Platelet-rich plasma and the elimination of neuropathic pain. *Mol Neurobiol* 2013;48:315-32.
18. Bron JL, Helder MN, Meisel HJ, Van Royen BJ, Smit TH. Repair, regenerative and supportive therapies of the annulus fibrosus: Achievements and challenges. *Eur Spine J* 2009;18:301-13.
19. Khiste SV, Tari RN. Platelet-Rich Fibrin as a Biofuel for Tissue Regeneration, *ISRN Biomaterials* (2013), Article ID 627367, 6 pages.
20. Bose B. Anterior cervical fusion using Caspar plating: Analysis of results and review of the literature. *Surg Neurol* 1998;49:25-31.
21. Zaveri GR, Ford M. Cervical spondylosis: The role of anterior instrumentation after decompression and fusion. *J Spinal Disord* 2001;14:10-6.
22. Nadkarni SM, Kohli PK, Gore S, Kulkarni B, Patel B. Percutaneous endoscopic cervical discectomy with insertion of platelet rich fibrin (Derwan) plug. *J Trauma and Orthopaedic Surgery* 2016;11:19-23.
23. Nadkarni S, Kohli P, Gore S, Patel B. Use of biological solutions for annular healing: Dervan platelet fibrin plug in transforaminal disc surgery. *IOSR-JDMS* 2016;15:52-7.