

## Missing Disc Fragment: A Rare Surgical Experience

### Abstract

About 35%–72% of lumbar disc herniations are associated with fragment migration. However, the posterior epidural migration is rare. We present a strange situation encountered during surgical decompression of the posterior migrated fragment. A 72-year-old male presented with a history of pain radiating to the left lower limb and Grade 3 power of the extensor hallucis longus. Magnetic resonance imaging revealed a prolapsed intervertebral disc and a possible posterior epidural migration of disc fragment. Routine surgical steps for microdiscectomy were followed after confirmation of level using fluoroscopy. However, the extruded disc fragment was not seen, and both exiting and traversing roots were free with adequate mobility. After extensively searching for a disc in the spinal canal, suction fluid was filtered through a surgical mop used as a sieve. Material collected was sent for histopathological study. Biopsy report confirmed material filtered was indeed the intervertebral disc. Thus, accidental suction of disc material in case of the posterior epidural migrated disc is a possibility, and we should be vigilant about this scenario to avoid disaster.

**Keywords:** Lumbar disc herniation, migrated disc fragment, suction

### Introduction

Lumbar disc herniation is the most commonly encountered reason for spine surgery across the adult population worldwide. About 35%–72% of all lumbar disc herniation are associated with fragment migration.<sup>[1]</sup> Herniated disc fragments tend to migrate in all directions in the spinal canal with caudal and paracentral displacements being the most common patterns. Posterior epidural migration is relatively rare. Reasons why disc fragments migrate posteriorly are not well understood.<sup>[2-4]</sup> Inability to locate sequestered disc fragment which is obviously evident on magnetic resonance imaging (MRI) during routine surgical decompression is a nightmare for the surgeon. Retained fragments pose a potential threat to patients in terms of neurological manifestations, risk of re-exploration, and subsequent financial as well as medico-legal consequences.

Although the posterior epidural migration of disc fragments is well described in the literature (75 case reports),<sup>[5]</sup> we present a strange situation encountered during surgical decompression of the posterior migrated fragment. To the best of authors'

knowledge, such an occurrence is first of its kind to be reported.

### Case Report

72-year-old male patient presented with a history of the left buttock pain radiating to the left lower limb for the past 6 months, which aggravated over the past 2 days (visual analog scale 9/10). On examination, the patient had no nerve root tension signs, and bilateral straight leg raising test was negative. Extensor hallucis longus (EHL) and plantar flexion were Grade 3 power by Medical Research Council (MRC) grading on the left side. The patient also reported sensory deficit to both crude and fine touch over L5 and S1 dermatome in the left lower limb. There were no bowel or bladder symptoms. The patient was evaluated by MRI examination that revealed total six lumbar vertebrae and a prolapsed intervertebral disc between L5 and L6 vertebra with left side lateral recess and foraminal stenosis and a possible posterior epidural migration of the disc fragment [Figures 1 and 2]. Patient was advised urgent surgical decompression by L5 and L6 laminotomy and microdiscectomy in view of neurological deterioration. Routine surgical steps for

**Abhinandan Reddy Mallepally, Amrit Gantaguru, Nandan Marathe, Sanjay Kumar Meena, Vikas Tandon**

*Department of Spine Services, Indian Spinal Injuries Centre, New Delhi, India*

#### Address for correspondence:

*Dr. Abhinandan Reddy Mallepally, Department of Spine Services, Indian Spinal Injuries Centre, Vasant Kunj, Sector C, New Delhi - 110 070, India. E-mail: mabhi28@gmail.com*

#### Access this article online

**Website:** www.asianjns.org

**DOI:** 10.4103/ajns.AJNS\_79\_20

#### Quick Response Code:



This is an open access journal, and articles are distributed under the terms of the Creative Commons Attribution-NonCommercial-ShareAlike 4.0 License, which allows others to remix, tweak, and build upon the work non-commercially, as long as appropriate credit is given and the new creations are licensed under the identical terms.

For reprints contact: WKHLRPMedknow\_reprints@wolterskluwer.com

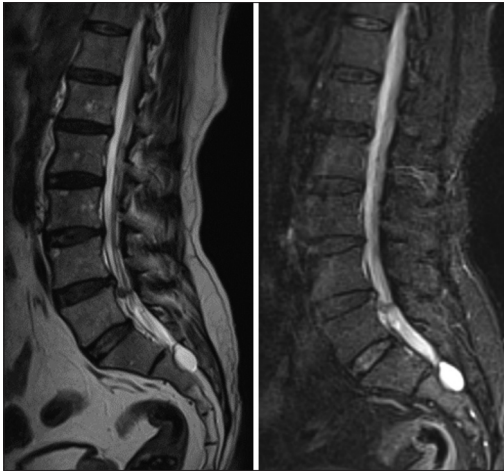**How to cite this article:** Mallepally AR, Gantaguru A, Marathe N, Meena SK, Tandon V. Missing disc fragment: A rare surgical experience. Asian J Neurosurg 2020;15:674-7.

**Submitted:** 03-May-2020

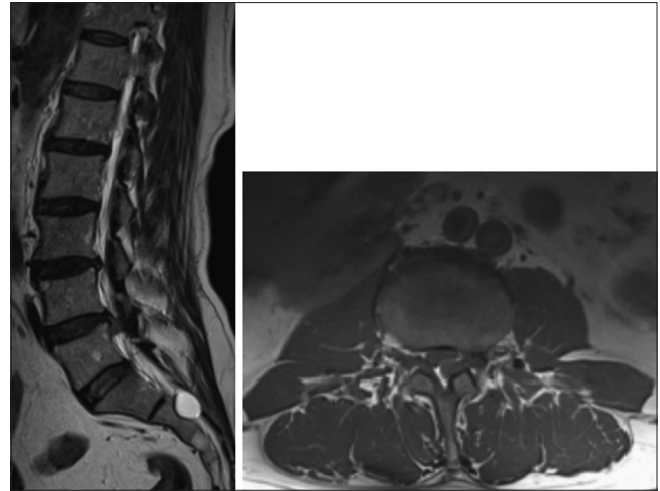
**Revised:** 23-Apr-2020

**Accepted:** 22-May-2020

**Published:** 28-Aug-2020



**Figure 1:** Sagittal magnetic resonance images (T2 weighted and Fat saturation) of the lumbar spine showing intervertebral disc herniation at L5–6 level with probable posterior migration of disc fragment



**Figure 2:** Sagittal and axial cross-sections of magnetic resonance images showing disc herniation at L5–6 level with posterior epidural migration

microdiscectomy were followed after confirmation of the level. L5 laminotomy was performed. The disc space was explored after securing shoulder of exiting nerve root. To our surprise, the extruded disc fragment was not seen, and both the exiting and traversing nerve roots were absolutely free of any compression/tension with adequate mobility. We looked both at the level as well as above and below the L5–L6 disc level to find out the missing disc material. MRI was repeatedly checked and compared with X-ray images to ascertain the level of discectomy. Intraoperative C-arm images were taken to reconfirm the level of discectomy. After extensively searching for the disc as well as going through the radiology images repeatedly, it was contemplated that the disc material might have got sucked through the suction tip. The suction fluid was filtered through a surgical mop used as a sieve, and the material collected was sent for histopathological study [Figure 3]. The roots and epidural space anteriorly were checked again with sweeping movements using Watson Cheyne retractor and nerve hook retractor under direct vision. After repeated confirmation, the incision was closed in layers. Postoperatively, the patient had relief from radicular pain (postoperative VAS for back and leg pain 3/10), and the motor power was improved (Grade 4/5 MRC). The biopsy report confirmed the material filtered was intervertebral disc material [Figure 4].

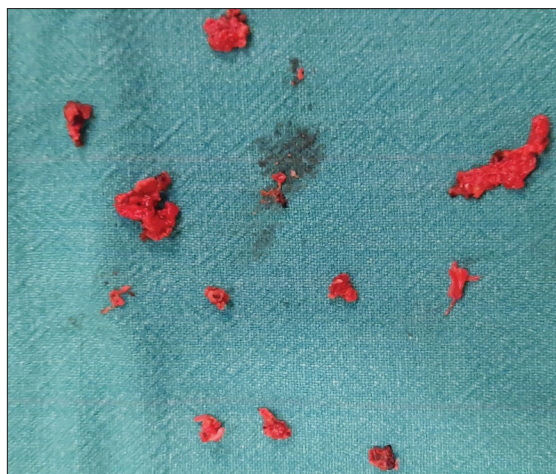
## Discussion

Disc fragment migration within the spinal canal is a usual phenomenon, although it commonly occurs within the anterior epidural space. Posterior migration of fragments of the extruded disc in the epidural space is a rare condition, but when it does occur, it requires prompt diagnosis and decompression surgery depending on the patient's symptomatology. Usually, posterior migration of disc fragments is prevented by anatomic structures such as the midline septum, peridural membrane, nerve roots,

and Hoffman ligaments.<sup>[6,7]</sup> The midline septum extends from the vertebral body to the posterior longitudinal ligament (PLL) and prevents the lateral migration of disc fragments. The peridural membrane spans the width of the vertebral body. Hoffman ligaments are bilateral (right and left) fine attachments between the dura mater and deep layer of the PLL, at each level. However, the true role of these structures in preventing disc fragment migration remains unclear.

In the present case, there was a posterior epidural migration of the herniated disc material in L5–6 level. There was significant extruded disc material resulting in excruciating leg pain, which was sudden in onset for 2 days. However, to our surprise, there were no root tension signs, which are a common finding in disc herniation with nerve root compression. The patient was able to perform well leg raise and affected leg raise to 90° without root tension signs despite a decrease in the motor power of EHL and plantar flexion to Grade 3. There were no bowel and bladder involvement. Sudden-onset excruciating pain with large fragments and decrease in motor power necessitated emergent decompressive surgery. In most cases, posterior epidural disc herniation manifests as an emergency, it should be diagnosed quickly, and emergency surgery may be performed.

The peculiarity of the present case report is a practical issue of missing disc during the decompressive procedure, which might happen in the posterior epidural migrated fragments. The fragment lies immediately beneath the lamina, lying on the dura making it immediately accessible after laminotomy without the need to identify the traversing nerve root and dural sac. This close proximity to the site of laminotomy might have led to suctioning of the disc fragments by the suction cannula and might have led the surgeon to confusion, as there was no disc material to be found on searching for the extruded fragments.



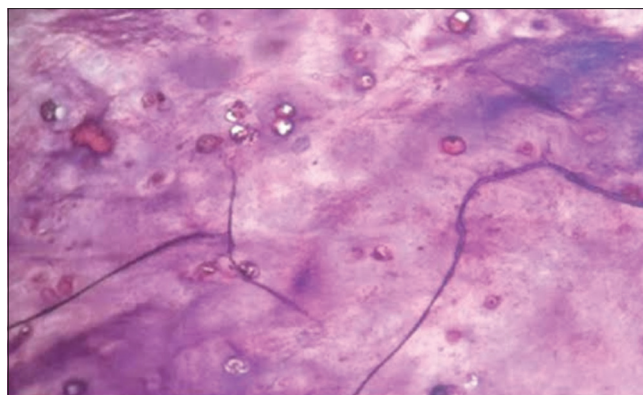
**Figure 3: Retrieved disc fragments from the suction container after using the surgical mop as a sieve**

A missing fragment intraoperatively, which was evident on MRI, makes the intraoperative scenario stressful and critical. Retained fragments cause undue physical, emotional, and financial/legal consequences to patients and treating doctors. Momentary human flaws can result in disastrous results for the patients and the surgical team along with hospital management.

Our case report suggests that search for the missing fragment in a step-wise manner at the suspected locations improves the chance of detecting the missing disc material. It is the responsibility of the primary surgeon to inform the assistant and scrub nurse regarding the retrieval of disc material and its immediate recovery from the surgical site postexecution of the planned step in the procedure. The nursing staff along with primary surgeon and assistant surgeon should be vigilant of the proceedings to prevent such events. Smaller the size of the fragment, extra care needs to be taken during the procedure as smaller fragments, especially when in the posterior epidural space is easily sucked into the suction apparatus while performing the routine surgical procedure or during sudden excessive bleeding while trying to clear the surgical field.

One possible reason behind not able to find the pathological disc is wrong level surgery. In the spine, wrong-site surgery occurs when a procedure is performed on an unintended vertebral level. Several national protocols have been developed to decrease the incidence of wrong-site surgery, such as “The Universal Protocol for Preventing Wrong Site, Wrong Procedure, and Wrong Person Surgery” from the Joint Commission and the “Sign, Mark, and X-ray” program from the North American Spine Society.<sup>[8,9]</sup>

Using palpable and visible anatomic landmarks alone to identify the desired vertebral level during spine surgery is not entirely reliable. Hence, intraoperative radiography is a critical step in identifying the correct surgical level.<sup>[10-12]</sup> Counting from bony landmarks is only appropriate if the



**Figure 4: Histopathology slides of the extruded disc material. Photomicrograph: Degenerative disc material with invading polymorphonuclear cells with granulation tissue in the periphery of the disc material**

patient has conventional numbering or if unconventional segmentation is clearly identified before surgery. Our patient had six lumbar vertebrae, and the disc herniation was seen in L5–6 level. Missing the pathological level also might be a reason to not find the intended extruded disc material. If a patient has unusual vertebral column anatomy that is not recognized before surgery, then intraoperative counting can be problematic and may lead to surgery on the wrong level. We had to count the vertebral level using intraoperative fluoroscopy and match it to the MRIs repeatedly to reassure that we were at correct level.

The surgical exploration plan to find such missing fragments should guarantee maximal exposure of the pathologic process, avoid incidental durotomy, enable the approach to the nerve root, and disc spaces without traction on neural structures and minimize overlap syndrome and instability. As we could not retrieve any disc material after the thorough inspection of epidural space and neural foramina, we suspected that disc material might have been accidentally sucked into the suction apparatus. We got the suction apparatus checked and using the surgical mop as a sieve, checked for the missing fragment and found it to be in there. Histopathological examination confirmed it to be the disc fragment.

This report is a first of its kind in the literature that describes the accidental suction of disc material intraoperatively and later recovery of the same. This report provides an important learning point that a posteriorly migrated free fragment might be lost if we are not vigilant during the surgical routine. It also encourages the surgeon to order routine histopathology also along with visual confirmation, to prove the authenticity of the index surgery.

#### **Financial support and sponsorship**

Nil.

#### **Conflicts of interest**

There are no conflicts of interest.

## References

1. Turan Y, Yilmaz T, Goomez C, Ozevren H, Kemaloglu S, Teke M, *et al.* Posterior epidural migration of a sequestered lumbar intervertebral disc fragment. *Turk Neurosurg* 2017;27:85-94.
2. Daghighi MH, Pouriesia M, Maleki M, Fouladi DF, Pezeshki MZ, Mazaheri Khameneh R, *et al.* Migration patterns of herniated disc fragments: A study on 1,020 patients with extruded lumbar disc herniation. *Spine J* 2014;14:1970-7.
3. Mobbs RJ, Steel TR. Migration of lumbar disc herniation: An unusual case. *J Clin Neurosci* 2007;14:581-4.
4. Tamburrelli FC, Perna A, Oliva MS, Giannelli I, Genitiempo M. Unusual posterior epidural migration of intervertebral herniated disc: A report of two cases. *Malays Orthop J* 2018;12:47-9.
5. Deora H, Prabhuraj AR, Pruthi N. Posterior epidural migration of lumbar disc: Will the real „disc“ please stand up? *Surg Neurol Int* 2017;8:302.
6. Dösoğlu M, Is M, Gezen F, Ziyal MI. Posterior epidural migration of a lumbar disc fragment causing cauda equina syndrome: Case report and review of the relevant literature. *Eur Spine J* 2001;10:348-51.
7. Lakshmanan P, Ahuja S, Lyons K, Howes J, Davies PR. Sequestered lumbar intervertebral disc in the posterior epidural space: A report on two cases and review of the literature. *Spine J* 2006;6:583-6.
8. Joint Commission on Accreditation of Healthcare Organizations. Universal protocol for preventing wrong site, wrong procedure, wrong person surgery. URL; 2004. Available from: [http://www.jcaho.org/accredited+organizations/patient+safety/universal+protocol/wss\\_universal+protocol.htm](http://www.jcaho.org/accredited+organizations/patient+safety/universal+protocol/wss_universal+protocol.htm). [Last accessed on 2020 Apr 04].
9. Sign, Mark and X-Ray” (SMaX). Available from: <https://www.spine.org/Portals/0/Assets/Downloads/ResearchClinicalCare/SMAX2014Revision.pdf>. [Last accessed on 2020 Apr 04].
10. Ebraheim NA, Inzerillo C, Xu R. Are anatomic landmarks reliable in determination of fusion level in posterolateral lumbar fusion? *Spine (Phila Pa 1976)* 1999;24:973-4.
11. Ammerman JM, Ammerman MD. Wrong-sided surgery. *J Neurosurg Spine* 2008;9:105-6.
12. Ammerman JM, Ammerman MD, Dambrosia J, Ammerman BJ. A prospective evaluation of the role for intraoperative x-ray in lumbar discectomy. Predictors of incorrect level exposure. *Surg Neurol* 2006;66:470-3.