



Received: 2016.06.14
Accepted: 2016.08.12
Published: 2017.04.19

Authors' Contribution:

- A** Study Design
- B** Data Collection
- C** Statistical Analysis
- D** Data Interpretation
- E** Manuscript Preparation
- F** Literature Search
- G** Funds Collection

Diagnostic Imaging of Pregnant Women – The Role of Magnetic Resonance Imaging

Monika Bekiesińska-Figatowska^{1ABCDEF}, Anna Romaniuk-Doroszewska^{1BCD},
Sylvia Szkudlińska-Pawlak^{1BCD}, Agnieszka Duczkowska^{1BCD}, Jarosław Mądzik^{1BCD},
Martyna Szopa-Krupińska^{2B}, Tomasz M. Maciejewski^{2B}

¹ Department of Diagnostic Imaging, Institute of Mother and Child, Warsaw, Poland

² Clinic of Obstetrics and Gynecology, Institute of Mother and Child, Warsaw, Poland

Author's address: Monika Bekiesińska-Figatowska, Department of Diagnostic Imaging, Institute of Mother and Child, Warsaw, Poland, e-mail: zaklad.rtg@imid.med.pl

Background:

Presentation of magnetic resonance imaging (MRI) findings in pregnant women in the Department of Diagnostic Imaging, Institute of Mother and Child, Warsaw, Poland.

Material/Methods:

Forty-three symptomatic pregnant women underwent MRI between 9 and 33 weeks of gestation (mean of 23 weeks). Moreover, we included 2 pregnant women who underwent fetal MRI and had incidental abnormalities.

Results:

In 9 cases, we excluded the suspected brain abnormalities. In 4 cases, we found unremarkable changes in the brain without clinical significance. One patient was diagnosed with multiple sclerosis, one with cortical dysplasia, one with pineal hemorrhage and one with a brain tumor. On abdominal MRI, 2 patients had normal findings, one patient had colon cancer with a hepatic metastasis, one patient had a hepatic angioma, one patient had an extraadrenal pheochromocytoma, one patient had an abscess in the iliopsoas muscle, 9 patients had myomas, two patients had ovarian simple cysts, two endometrial cysts, three dermoid cysts, one patient had sacrococcygeal teratoma, one patient had a cystadenofibroma (partial borderline tumor), one patient had an androgenic ovarian tumor and two patients had hyperreactio luteinalis. One patient was diagnosed with transient osteoporosis of the hip and one with a stress fracture of the sacral bone.

Conclusions:

Magnetic resonance imaging is the best imaging modality for pregnant women. Although ultrasonography is the method of choice, doubtful cases as well as structures that cannot be examined with ultrasonography can be non-invasively evaluated with MRI.

MeSH Keywords:

Diagnostic Imaging • Magnetic Resonance Imaging • Pregnant Women

PDF file:

<http://www.polradiol.com/abstract/index/idArt/900071>

Background

Pregnancy is a special time in the life of a woman, and it requires a special approach to imaging. In principle, ionizing radiation should be avoided as it can have a negative influence on the fetus, especially during the period of organogenesis (i.e. in the first trimester). Although it has been shown that the dose of radiation would have to be very high in order to cause fetal damage (more than that used in computed tomography of the abdomen), x-ray-based studies are not used routinely in pregnant women,

with one exception in the case of suspected pulmonary embolism.

Because of that, during pregnancy the two most commonly used imaging modalities are ultrasonography (US) and magnetic resonance imaging (MRI). As in our previous studies [1], we wanted to show our experience from the Department of Diagnostics Imaging, Institute of Mother and Child, Warsaw – a leading center in Poland as regards imaging of the fetus, pregnant women and newborns.

Table 1. Area imaged by MRI in individual patients.

Area	Patient number	Percentage (%)
Brain	17	37.8
Abdomen	4	8.9
Pelvis	16	35.6
Abdomen and pelvis	6	13.3
Bone pelvis	2	4.4
Total	45	100.0

Material and Methods

We included 43 symptomatic pregnant women between 9 and 33 weeks of gestation (mean of 23 weeks) who required an imaging work-up. MRI was performed when ultrasonography could not help with diagnosis or when it was necessary to obtain more detailed information on the structures that cannot be easily evaluated with ultrasonography.

Table 2. Diseases diagnosed on MRI.

Diagnosis	Patient number	Percentage (%)
Normal brain, exclusion of suspected abnormality	9	19.6
Non-specific brain abnormalities without clinical significance	4	8.7
Multiple sclerosis	1	2.2
Cortical dysplasia	1	2.2
Pineal cysts with signs of hemorrhage	1	2.2
Brain tumor	1	2.2
Normal abdomen	2	4.3
Hepatic metastasis and colon cancer	1	2.2
Hemangioma*	1	2.2
Pheochromocytoma	1	2.2
Abscess in the iliopsoas muscle	1	2.2
Uterine myomas	9	19.6
Simple ovarian cyst	2	4.3
Endometrial cyst	2	4.3
Dermoid cyst*	3	6.5
Sacroccygeal teratoma	1	2.2
Ovarian cystadenofibroma/borderline tumor	1	2.2
Sex-cord stromal tumor	1	2.2
Hyperreactio luteinalis	2	4.3
Transient hip osteoporosis	1	2.2
Stress fracture of the sacral bone	1	2.2
Total	46	102.2

* This patient was diagnosed with hepatic adenoma and ovarian dermoid cyst and therefore there are 46 patients in total (in reality 45 patients) corresponding to the given total percentage.

Moreover, we included 2 pregnant women who underwent fetal MRI and had incidental abnormalities. In total, we included 45 patients. We excluded patients with myomas smaller than 3 cm, without degeneration or location that could not interfere with delivery. We also excluded patients with unilateral or bilateral dilation of the renal pelvis or calyces, which is a frequent incidental finding in pregnant women. We present the studied patients in Table 1.

We used the GE Signa Hdxt magnetic resonance scanner (1.5 Tesla) with appropriate protocols for respective body parts and suspected abnormalities.

Results

Diagnoses made based on MRI studies are presented in Table 2.

Discussion

Proper diagnosis is very important for pregnant women as it can influence the choice of treatment – either conservative

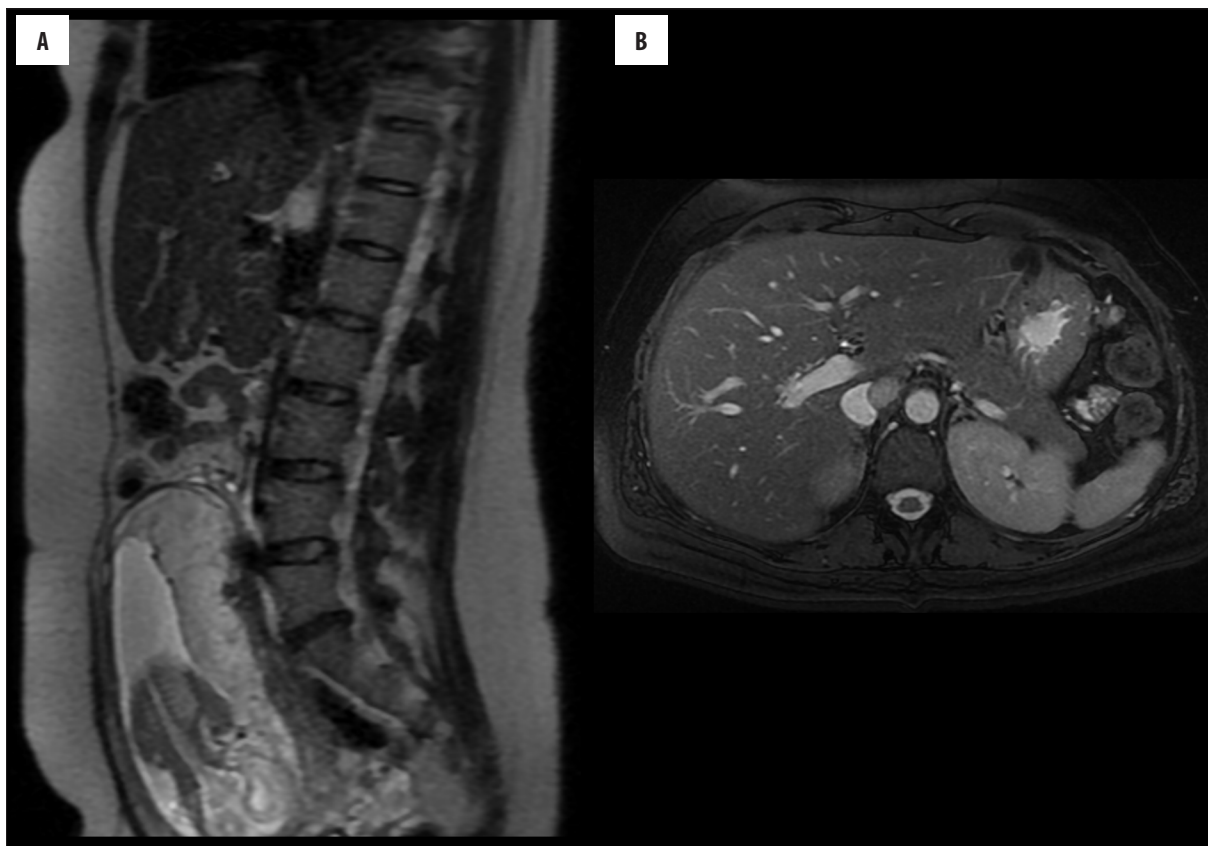


Figure 1. Pheochromocytoma with high-intensity signal in T2-weighted images in the periaortal area in a pregnant patient (week 19 of gestation) (A). Axial view, the inferior vena cava is modeled by the tumor (B). The patient underwent surgery during pregnancy.

or surgical. It decides whether to operate during pregnancy or to postpone the surgery after delivery or to terminate pregnancy in order to save the mother. Therefore, it is very important to use appropriate imaging methods in an institution with extensive experience. Ultrasonography should be used always in the case of structures that can be well assessed with it, and the remaining structures are evaluated with MRI independent of the week of gestation. In 2007, the American College of Radiology reported that, provided the risk-benefit ratio is favorable, MRI can be performed at all stages of pregnancy [2]. The choice of imaging center is very important, because it is crucial to use short protocols without the use of contrast agents, when possible. Although gadolinium has not been shown to negatively affect the fetus, it crosses the placental barrier and therefore its use is not recommended in pregnant women [3]. However, when it is necessary, gadolinium should be used at the discretion of an experienced radiologist [4]. On the other hand, as a number of sequences can be used in MRI, it is not often required to administer contrast agents. Imaging studies in pregnant women should not be performed via tele-radiology as during the study an experienced radiologist should always be present and direct the study as there are no routine protocols that can be used in all pregnant women. However, the experience in Poland is limited, and apart from our center, only two others have published case reports [5,6].

As already mentioned, in MRI a number of different sequences can be used in order to look for characteristic

abnormalities. Such abnormalities include pheochromocytomas that are diagnosed based on biochemical studies and subsequent MRI (however ultrasonography should also be performed), which expedites treatment [7]. Although there is controversy if T2 and STIR sequences could be very characteristic for pheochromocytomas [8], it is possible to find a tumor with such characteristics in the periaortal area in patients genetically predisposed and previously operated on because of this tumor in the adrenals, as was done in one of our patients (Figure 1). This enables further surgical treatment.

Similar considerations regard abscesses in the iliopsoas muscle, where in DWI sequence the signal is very hyperintense corresponding to low apparent diffusion coefficient in ADC map. This shows restricted diffusion in abscesses as opposed to cysts without the need to use contrast agents in pregnant women (Figure 2) [9].

A major part of our patients (over a half, 26 patients, 57.8%) was evaluated because of incidental findings found on ultrasonography in routine examinations or because of abdominal symptoms (including uterine symptoms). In a large part of these patients (in 20 patients, 76.9% of the 26 patients, and 44.4% of all patients) MRI showed specific abnormalities of the genital system. The usefulness of MRI in diagnosing such abnormalities is well-known and well-described [10–12] and is also appreciated during pregnancy [13]. The limitations of ultrasonography are also well-known – small field of view, difficulties in imaging because

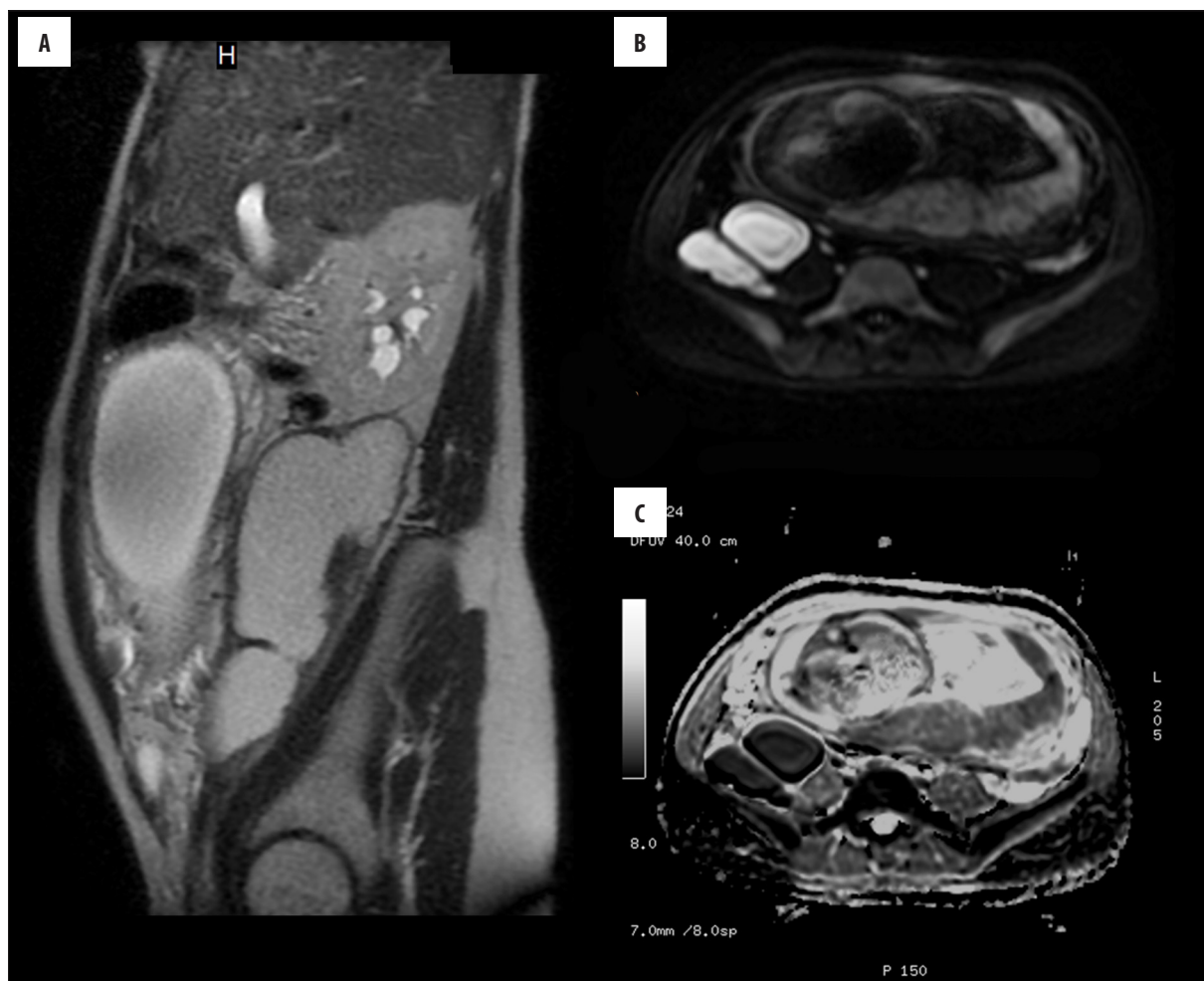


Figure 2. Abscess in the right iliopsoas muscle in a pregnant patient (week 33 of gestation). In a standard T2 sequence, it is seen as a fluid collection (A) with a high signal in DWI (B) and a black signal in ADC (C), which supports the diagnosis of an abscess.

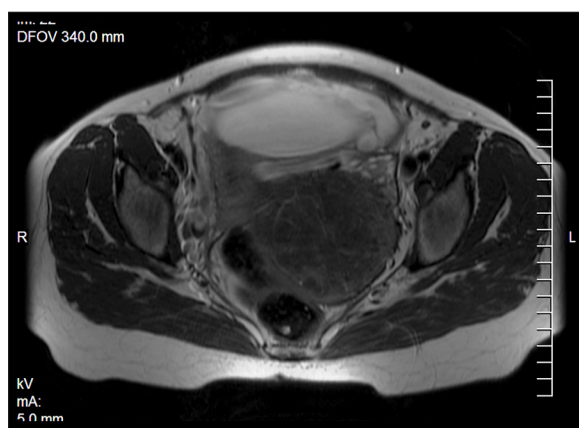

Figure 3. Pedunculated myoma in a pregnant patient (week 22 of gestation) displacing the rectum/sigmoid to the right and neighboring the left ovary. On ultrasound, it was not possible to differentiate between myoma and ovarian tumor.

of the enlarged uterus, difficulties in obese patients etc. These problems are not associated with MRI and therefore we were able to make or strongly suggest diagnosis in the

majority of patients. For instance, in two patients we confirmed myomas that based on ultrasonography had been earlier described as ovarian tumors. Pedunculated myomas can especially mimic ovarian tumors and MRI is very helpful (Figure 3) [14].

Other characteristic abnormalities of the genital system include the endometrial and dermoid cysts of the ovaries. When T2, T1 and T1-fat-saturated sequences are used, they can be differentiated from one another without using contrast agents [15]. We show two such cases (Figure 4). In another case, we confirmed a fetal hepatic angioma and found another hepatic angioma in the mother together with a dermoid cyst of the ovary.

Cysts and cystadenofibromas of the ovary with smooth and thin walls, containing fluid collections as well as borderline tumors with characteristic sizes, fluid contents and characteristic solid parts can be differentiated by the radiologist [15–17], as was seen in our patients (Figure 5).

There is also a growing need to perform MRI in pregnant women because of acute reasons including appendicitis, active Crohn’s disease, torsion of the ovary or an ovarian

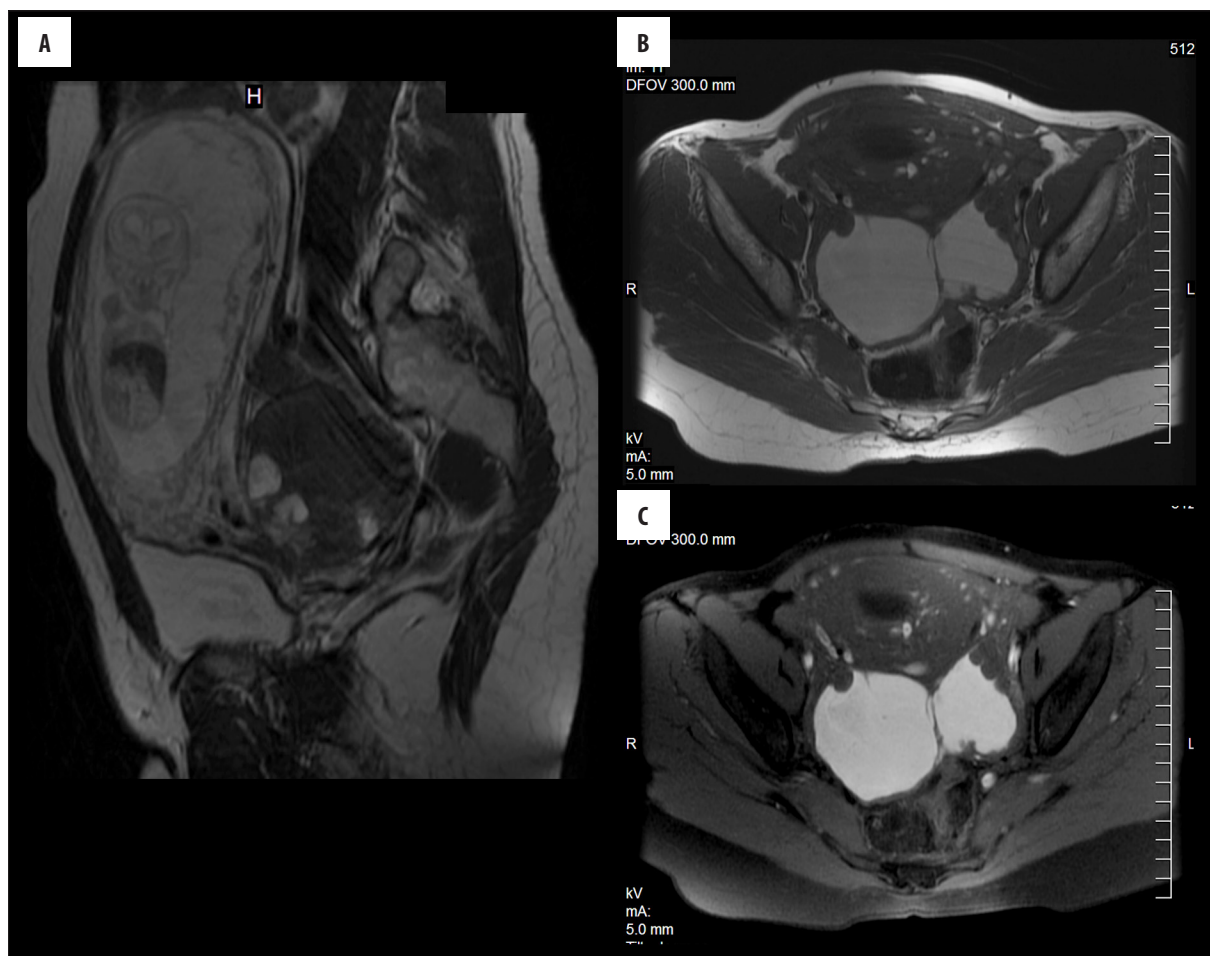
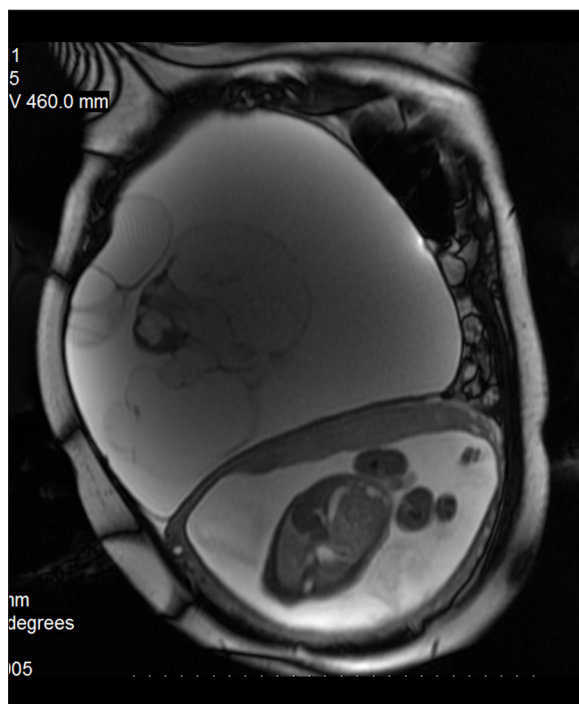

Figure 4. Endometrial ovarian cysts in a pregnant patient (week 16 of gestation) (A). In T1-weighted images, there is a strong signal similar to subcutaneous fat (B). After fat saturation, subcutaneous fat is suppressed and the signal of blood in the cysts remains strong (C). The patient was operated during pregnancy (week 16 of gestation).



cyst, and torsion of a pedunculated myoma [18]. We had two patients (4.4%) evaluated for acute pancreatitis.

Proper diagnosis cannot be made in all cases and a cooperation between radiologists and clinicians is crucial. One of our patients is an example of a lack of such cooperation. This patient had a large tumor that could not be separated from the uterus and which was accompanied by enlarged veins. Because clinicians did not provide any additional information, the patient was diagnosed with the most probable disease – i.e. myoma. Further information on hormonal disturbances prompted us to include ovarian tumors in the differential diagnosis. On the other hand radiologists should also actively seek clinical information. Had a radiologist seen the patient (her obesity, hirsutism), an androgenic tumor would have been included in the differential diagnosis.

Figure 5. Cystadenofibroma of the ovary/partial borderline tumor in a pregnant patient (week 22 of gestation) with a typical morphology for a borderline tumor on MRI. The patient was operated during pregnancy (week 24 of gestation).

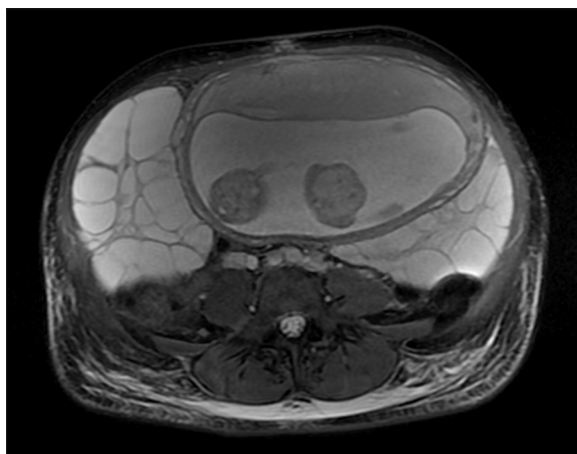


Figure 6. Hyperreactio luteinalis in a twin, monochorionic, monoamniotic pregnancy (week 18 of gestation).

It is also crucial to exclude suspected diseases. For instance, even when clinical and laboratory information indicate acute pancreatitis, a normal MRI study excludes the necessity for surgery, which was the case with our two patients. In another 2 patients with hyperreactio luteinalis, we excluded ovarian tumors. One of these patients was in week 22 of gestation (spontaneous twin pregnancy) and the other patient was in week 28 of gestation (monochorionic, monoamniotic twins after *in vitro* fertilization). On MRI, there were characteristic multilocular cystic masses with numerous septae in the ovaries (Figure 6) [19]. In one of these patients, cancer was additionally excluded (hydatoid mole, choriocarcinoma).

Exclusion of suspected disease was most common in neurological patients. In 9 of 17 patients (52.9%), brain MRI was normal. In four patients we found clinically insignificant changes, usually small focal abnormalities. In total, we excluded suspected diseases in 14 patients (76.% of patients with brain MRI, 18.9% of all patients), which included cerebral venous sinus thrombosis, arteriovenous malformation, multiple sclerosis relapse and brain tumor. These diseases should be taken into account in patients with acute headaches, neurological signs suggesting multifocal brain damage and first epileptic seizures. MRI is the best study to exclude such conditions [20,21]. When brain MRI containing all necessary sequences is normal in pregnant women, there is no need to administer contrast agents. However, it can be difficult to exclude cerebral venous sinus thrombosis in sequences without contrast. If cerebral sinuses have normal signal intensity and MRI-angiography (no contrast) is also normal, there is no need to extend the study.

In some patients who underwent brain MRI, we found clinically significant abnormalities (4/17=23.5%). One patient with first epileptic seizure was diagnosed with a brain tumor. One patient with a history of epilepsy who had an exacerbation of the disease during pregnancy was diagnosed with cortical dysplasia (Figure 7). A patient with a severe headache had features of pineal gland hemorrhage.

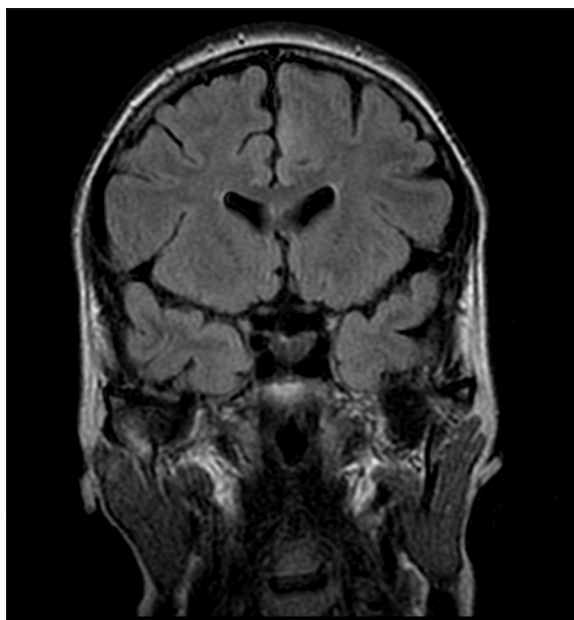


Figure 7. Cortical dysplasia in the left frontal lobe in a pregnant woman (week 28 of gestation) with a history of epileptic seizures who had not undergone MRI before. The seizures were exacerbated during pregnancy. The direct reason for MRI was a grand-mal seizure.

In another patient with multifocal neurological signs we found multiple white matter lesions that could suggest multiple sclerosis. These proportions are similar to those found in the literature [22].

Bone studies are another field of interest. We evaluated two patients because of bone pain (4.6%). Progressive hip pain in a pregnant woman in the third trimester should suggest transient osteoporosis – a rare disease found in pregnant women that causes pain (in contrast to osteoporosis). Plain radiography, not routinely performed in pregnant women, is not helpful as the changes are seen only in the second stage of the disease after 2–3 months. Therefore, MRI is the study of choice both in pregnant women and other patients with transient osteoporosis as it can show characteristic bone marrow edema in the femoral head and neck as early as 3 days since the onset of symptoms. These changes can be accompanied by edema of the surrounding tissues and joint effusions [23]. Early detection is important in order to prevent fractures. One of our patients was diagnosed with transient hip osteoporosis and another patient with a stress fracture of the lateral mass of the sacral bone. In the latter case, a fracture fissure was seen in addition to bone marrow edema.

Conclusions

Magnetic resonance imaging is the best imaging modality for pregnant women. Although ultrasonography is the method of choice, doubtful cases as well as structures that cannot not be examined with ultrasonography can be non-invasively evaluated with MRI.

References:

1. Bekiesińska-Figatowska M, Furmanek MI, Walecki J et al: MR imaging of benign and malignant neoplasms co-existing with pregnancy. *Pol J Radiol*, 2004; 69(2): 64–68
2. Kanal E, Barkovich AJ, Bell C et al: ACR guidance document for safe MR practices: 2007. *Am J Roentgenol*, 2007; 188(6): 1447–74
3. Chen MM, Coakley FV, Kaimal A et al: Guidelines for computed tomography and magnetic resonance imaging use during pregnancy and lactation. *Obstet Gynecol*, 2008; 112(2 Pt 1): 333–40
4. Patenaude Y, Pugash D, Lim K et al: The use of magnetic resonance imaging in the obstetric patient. *J Obstet Gynaecol Can*, 2014; 36(4): 349–63
5. Bińkowska M, Dębska M, Mazurek M et al: Embolization of renal angiomyolipoma in pregnancy: Case report. *Ginekol Pol*, 2009; 80: 449–52
6. Pęksa M, Boćkowski K, Preis K: Solitary fibrous tumor of the retroperitoneum in pregnancy: Case report. *Ginekol Pol*, 2011; 82: 382–85
7. Wyskida M, Wyskida K, Maruniak-Chudek I et al: [Pheochromocytoma in pregnancy]. *Postepy Hig Med Dosw (Online)*, 2014; 68: 749–53 [in Polish]
8. Havekes B, King K, Lai EW et al: New imaging approaches to pheochromocytomas and paragangliomas. *Clin Endocrinol (Oxf)*, 2010; 72(2): 137–45
9. Neubauer H, Platzer I, Mueller VR et al: Diffusion-weighted MRI of abscess formations in children and young adults. *World J Pediatr*, 2012; 8(3): 229–34
10. Sala E: Magnetic resonance imaging of the female pelvis. *Semin Roentgenol*, 2008; 43(4): 290–302
11. Namimoto T, Awai K, Nakaura T et al: Role of diffusion-weighted imaging in the diagnosis of gynecological diseases. *Eur Radiol*, 2009; 19(3): 745–60
12. Chassang M, Novellas S, Baudin G et al: [Contribution of new MRI sequences in the exploration of the pelvic gynaecological disease]. *J Gynecol Obstet Biol Reprod (Paris)*, 2011; 40(5): 399–406 [in French]
13. Leyendecker JR, Gorengaut V, Brown JJ. MR imaging of maternal diseases of the abdomen and pelvis during pregnancy and the immediate postpartum period. *Radiographics* 2004, 24(5), 1301-1316.
14. Bekiesińska-Figatowska M, Wagił K, Walecki J et al: MR imaging of lesions mimicking ovarian tumors. *Pol J Radiol*, 2006; 71(1): 53–58
15. Bekiesińska-Figatowska M, Jurkiewicz E, Iwanowska B et al: Magnetic resonance imaging as a diagnostic tool for ovarian masses in girls and young women. *Med Sci Monit*, 2007; 13(Suppl. 1): 116–20
16. Casanova J, Maciel R, Ferreira V et al: Borderline ovarian tumor during pregnancy: A case report. *Case Rep Obstet Gynecol*, 2013; 2013: 160319
17. Bent CL, Sahdev A, Rockall AG et al: MRI appearances of borderline ovarian tumours. *Clin Radiol*, 2009; 64(4): 430–38
18. Birchard KR, Brown MA, Hyslop WB et al: MRI of acute abdominal and pelvic pain in pregnant patients. *Am J Roentgenol*, 2005; 184: 452–58
19. Takeuchi M, Matsuzaki K: Magnetic resonance manifestations of hyperreactio luteinalis. *J Comput Assist Tomogr*, 2011; 35(3): 343–46
20. Edlow JA, Caplan LR, O'Brien K et al: Diagnosis of acute neurological emergencies in pregnant and post-partum women. *Lancet Neurol*, 2013; 12(2): 175–85
21. Lebrun C, Le Page E, Kantarci O et al: Radiologically Isolated Syndrome Consortium (RISC) group. Impact of pregnancy on conversion to clinically isolated syndrome in a radiologically isolated syndrome cohort. *Mult Scler*, 2012; 18(9): 1297–302
22. Semere LG, McElrath TF, Klein AM. Neuroimaging in pregnancy: A review of clinical indications and obstetric outcomes. *J Matern Fetal Neonatal Med*, 2013; 26(14): 1371–79
23. Pai W-Ch, Lin Ch-Y, Kao M-J et al: Transient osteoporosis of the hip during pregnancy: A case report. *Tw J Phys Med Rehabil*, 2009, 37(2): 131–37