

Received: 2019.02.08
Accepted: 2019.04.23
Published: 2019.05.14

Comparison of the Effects of Indobufen and Warfarin in a Rat Model of Adenine-Induced Chronic Kidney Disease

Authors' Contribution:
Study Design A
Data Collection B
Statistical Analysis C
Data Interpretation D
Manuscript Preparation E
Literature Search F
Funds Collection G

ABCDEF 1,2,3 Xiaowei Lou
ABCDFG 1,2,3 Juan Jin
BCD 1,2,3 Jianguang Gong
BCD 1,2,3 Li Zhao
AEFG 1,2,3 Yiwen Li*
AEFG 1,2,3 Qiang He*

1 Department of Nephrology, Zhejiang Provincial Peoples' Hospital, Hangzhou, Zhejiang, P.R. China
2 Peoples' Hospital of Hangzhou Medical College, Hangzhou, Zhejiang, P.R. China
3 Chinese Medical Nephrology Key Laboratory of Zhejiang Province, Hangzhou, Zhejiang, P.R. China

Corresponding Authors: Qiang He, e-mail: qianghe1973@126.com, Yiwen Li, e-mail: yiwen1962@163.com

Source of support: This work was supported by grants from the Natural Science Foundation of Zhejiang Province (Grant Numbers: LZ17H050001, LY16H050005, and Y18H050024), the Project of Province and the Ministry (Grant Number: WKJ-ZJ-1915), the Major Projects of Science and Technology Department of Zhejiang Province (Grant Number: 2014C03047-2), the General Project of the Medical and Health of Zhejiang Province (Grant Numbers: 2015KYA015, 2015KYA015, and 2015KYB035), the Project of the Scientific Research Foundation of Chinese Medicine (Grant Numbers: 2017ZA010, and 2016ZQ007)

Background: Worldwide, the treatment of patients with chronic kidney disease (CKD) remains a challenge as warfarin treatment can be associated with severe adverse events related to bleeding. Alternative anticoagulants that can be used in CKD remain to be identified. This study aimed to compare the effects of indobufen, a new antiplatelet agent, with warfarin in a rat model of adenine-induced CKD.





Material/Methods: Forty-eight male Wistar rats were treated with intragastric adenine to create the rat model of CKD and were divided into four groups: an untreated control group (N=12), a group treated with dimethyl sulfoxide (DMSO) (N=12), a group treated with indobufen, (N=12) and a group treated with warfarin (N=12). Treatment was given for 4 weeks and 8 weeks. Kidney histology was performed, and the degree of fibrosis was quantified using Masson trichrome staining.

Results: In the rat model of adenine-induced CKD, Masson trichrome staining showed that the degree of kidney fibrosis in the indobufen group (26%) was significantly reduced ($p < 0.05$) when compared the DMSO group (58%) and the warfarin group (49%). Kidney fibrosis was associated with upregulation of 6-keto-PGI₂/TXB₂ in the rat kidney tissue.

Conclusions: In a rat model of adenine-induced CKD, preliminary findings showed that indobufen was associated with reduced kidney fibrosis when compared with warfarin.

MeSH Keywords: **Fibrosis • Platelet Aggregation Inhibitors • Renal Insufficiency, Chronic**

Full-text PDF: <https://www.medscimonit.com/abstract/index/idArt/915590>

 2282  1  5  19



Background

Worldwide, chronic kidney disease (CKD) is an increasing public health problem that is associated with chronic kidney failure [1]. Dialysis or kidney transplantation are the only treatment options for CKD, both of which place a burden on healthcare services [2]. Therefore, further studies are needed to improve the prevention of CKD and to improve clinical management. CKD is often associated with changes in coagulation and fibrinolysis that result in hypercoagulability, bleeding, and abnormal coagulation factors [3]. Hypercoagulability is a main cause of the pathological changes that occur in the kidney in CKD leading to a decline in renal function. Anticoagulant treatments that reduce hypercoagulability in CKD have the potential to prevent or delay the onset of end-stage renal disease.

Warfarin is an anticoagulant that is commonly used to inhibit vitamin K-dependent coagulation [4,5]. Warfarin is used to prevent and treat venous thrombosis and pulmonary embolisms and is used to prevent thromboembolic stroke in patients with atrial fibrillation [4,5]. Warfarin is also commonly used to prevent and treat hypercoagulation in patients with CKD [6,7]. However, warfarin has complications due to bleeding that range from mild epistaxis, gingival bleeding, and hematuria, to hemorrhage from increased uterine bleeding, and from peptic ulcers [8,9]. Therefore, for patients with CKD who require anticoagulation, new treatments are required.

Indobufen is a new antithrombotic agent that inhibits platelet activation, adhesion, and aggregation [10]. Although this may be a useful antiplatelet therapy for patients with CKD, there is no safety and efficacy data on its use in this patient population from randomized controlled clinical trials. Therefore, this preliminary study aimed to compare the effects of indobufen, a new antiplatelet agent, with warfarin in a rat model of adenine-induced CKD.

Material and Methods

The rat model of adenine-induced chronic kidney disease (CKD)

This study was granted an animal license by the local Institutional Animal Research Committee and conformed to the animal care guidelines of the American Physiological Society. Chronic kidney disease (CKD) was induced in 48 male Wistar rats (Shanghai SLAC Laboratory Animal Co., Ltd.) (Certification Number: SCXK2012-0002) using intragastric administration of adenine (Batch No. WXBB0585V) (Sigma-Aldrich, St. Louis MO, USA), as previously described [11]. One week after the establishment of the model, all 48 rats survived and were included in the study.

Treatment of the rat model of CKD with dimethyl sulfoxide (DMSO), indobufen, or warfarin

Rats in the model of CKD (N=48) were divided into four groups, with different feeding patterns, as follows: the control group (N=12) were given standard rat fodder; the DMSO group (N=12) were given standard rat fodder and DMSO; the indobufen group (N=12) were given standard rat fodder plus indobufen in DMSO (20 mg/kg/day); and the warfarin group (N=12) were given standard rat fodder plus warfarin sodium in DMSO (0.5 mg/kg/day). Rats were weighed each week. After 4 weeks, half of the rats in each group (N=6) were euthanized. The remaining rats in each group (N=6) continued the regimen for a further eight weeks and were euthanized at week 12.

Measurement of coagulation factors and blood biochemistry

Blood was obtained from the carotid artery of the rats and the samples were divided. The first set of samples were added to a heparin sodium solution and centrifuged at 3000 rpm for 10 min, followed by the measurement of serum blood urea nitrogen (BUN), creatinine, and uric acid levels using biochemical kits. Sodium citrate solution was added to the second blood sample, which was centrifuged at 3000 rpm for 10 min followed by tests for coagulation function including levels of activated partial thromboplastin time (APTT) and prothrombin time (PT).

Measurement of 6-keto-prostaglandin I₂ (PGI₂), and thromboxane B₂ (TXB₂) in the kidney tissue

The levels of 6-keto-PGI₂ and TXB₂ were measured using an enzyme-linked immunosorbent assay (ELISA) kit (CEB396Ge, CEA727Ge) (Wuhan USCN Co., Wuhan, China), according to the manufacturer's instructions. Measurements were performed at an absorbance at 450 nm.

Western blot of the rat serum

Western blot was performed on blood samples. Blood samples were incubated with primary rabbit polyclonal antibodies and mouse monoclonal antibodies, anti-cyclooxygenase 1 (COX-1) (ab109025) (Abcam, Cambridge, MA, USA), anti-TGF beta 1 (ab2486) (Abcam, Cambridge, MA, USA), anti-Smad3 (ab40854) (Abcam, Cambridge, MA, USA), and anti-cyclooxygenase 2 (COX-2) (Cat. No. 12282S) (Cell Signaling Technology, Danvers, MA, USA). Secondary antibodies included goat anti-rabbit IgG (1: 5000) (Multisciences, Hangzhou, China), and goat anti-mouse IgG (1: 5000) (Multiscience, Hangzhou, China). Immunostains were visualized using electrochemiluminescence (ECL) and Western blot (Beyotime Biotechnology Co. Ltd., Shanghai), and quantified using the ChemiDoc XRS⁺ imaging system (Bio-Rad Labs, Hercules, CA, USA).

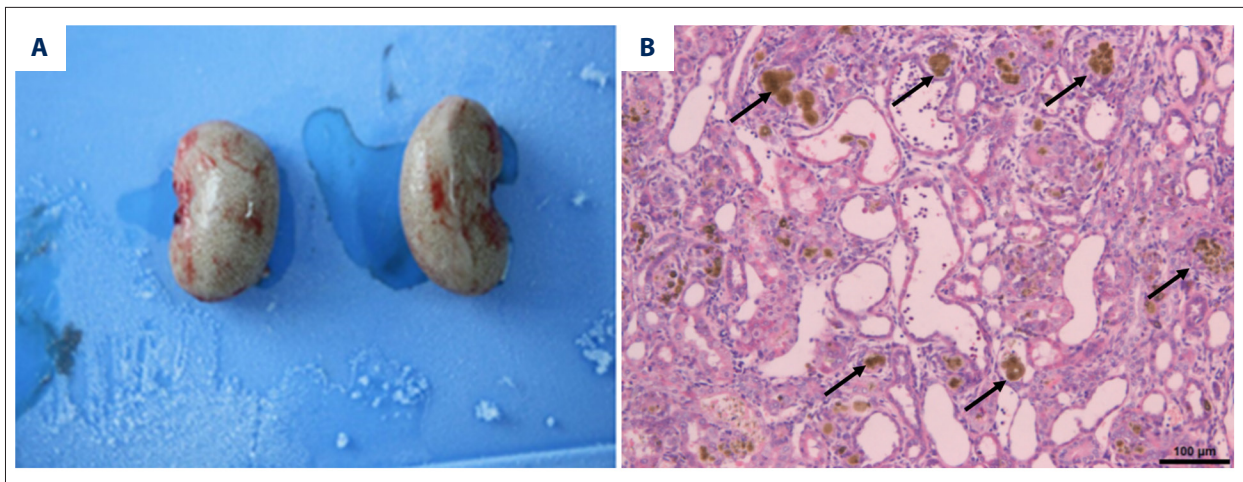


Figure 1. Macroscopic appearance of a kidney and a representative photomicrograph of a kidney tissue section from the rat model of adenine-induced chronic kidney disease (CKD). **(A)** The macroscopic appearance of the kidney from the rat model of adenine-induced chronic kidney disease (CKD) shows an enlarged kidney with a pale gray appearance. **(B)** Photomicrograph of the histology of the kidney from the rat model of adenine-induced CKD. The number of nephrons are decreased, the renal tubules are dilated, and inflammatory cell infiltrates are present. A proportion of the tubular epithelial cells have undergone squamous metaplasia, as shown by the arrow where there is a yellow-brown deposit of adenine. Hematoxylin and eosin (H&E). Bar, 100 μ m.

Histological analysis

After blood was sampled, the rats were euthanized and the kidneys were removed. The kidneys were transversely cut into two halves and fixed in 10% formalin and embedded in paraffin wax. Tissue sections were cut at 4 μ m and were stained for light microscopy using hematoxylin and eosin (H&E) and with Masson trichrome for collagen. Quantitative assessments were made of the cell size, cell population, and area of fibrosis [15] using ImageJ software (National Institutes of Health, Bethesda, MD, USA).

Statistical analysis

Data were shown as the mean \pm standard deviation (SD). Evaluation of the therapeutic effect of the treatments was performed using one-way analysis of variance (ANOVA). The figures and tables were created using GraphPad Prism version 6.0 software (GraphPad Software, San Diego, CA, USA). A P-value <0.05 was considered to be statistically significant.

Results

The rat model of adenine-induced chronic kidney disease (CKD)

None of the rats died in the model of adenine-induced chronic kidney disease (CKD), and the success rate of the CKD model was 100%. All the rats in the CKD model developed dry hair,

had poor mental state, developed polydipsia and polyuria, some of the rats salivated, and their weights plateaued or decreased. The kidneys of the rats became enlarged and were pale and gray (Figure 1A). Histology of the kidneys showed that the number of nephrons decreased, renal tubules were dilated, and inflammatory cell infiltrates were observed. A proportion of the tubular epithelial cells underwent squamous metaplasia, and others became necrotic, as shown in Figure 1B. Measurement of the serum indicators of renal function showed that rats in the CKD model had increased levels of serum blood urea nitrogen (BUN), creatinine, and uric acid, which confirmed the development of renal failure and the success of the development of the rat model of CKD [11].

The rat model of CKD

All rats were maintained in good condition before treatment. In the warfarin sodium treated group, ecchymosis of the paws, testicles, and skin was observed, and the abdominal organs were congested. None of the rats in the control group, dimethyl sulfoxide (DMSO) group, and indobufen group showed these symptoms. The rats in each group were weighed once a week, and there was no statistical difference in weight change between the groups (Figure 2).

Kidney histology and treatment with DMSO, indobufen, and warfarin

Histology of the kidney showed that the number of nephrons decreased, the renal tubules were dilated, and inflammatory

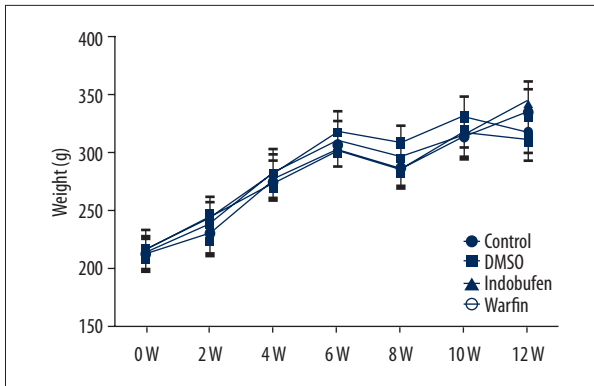


Figure 2. Average body weight curves over 12 weeks in the rat model of adenine-induced chronic kidney disease (CKD) in the control group and rats treated with dimethyl sulfoxide (DMSO), indobufen, and warfarin. 0W represents one week after modeling, or day 1 of the experiments.

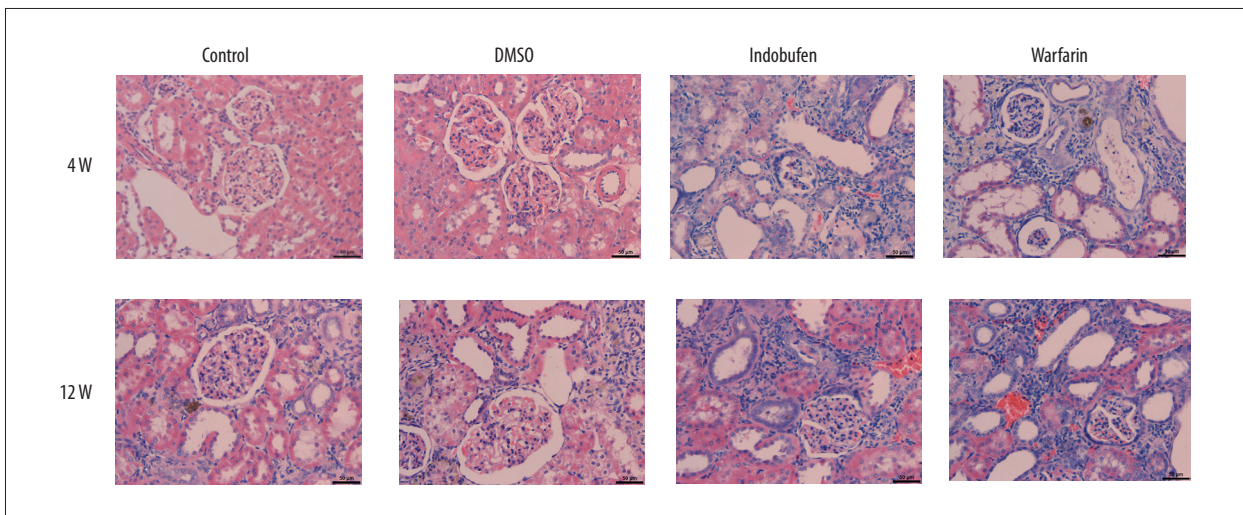


Figure 3. Photomicrographs of the histology of the kidneys in the rat model of adenine-induced chronic kidney disease (CKD) in the control group and rats treated with dimethyl sulfoxide (DMSO), indobufen, and warfarin. Hematoxylin and eosin (H&E) staining of the kidney tissue. (Magnification, $\times 400$).

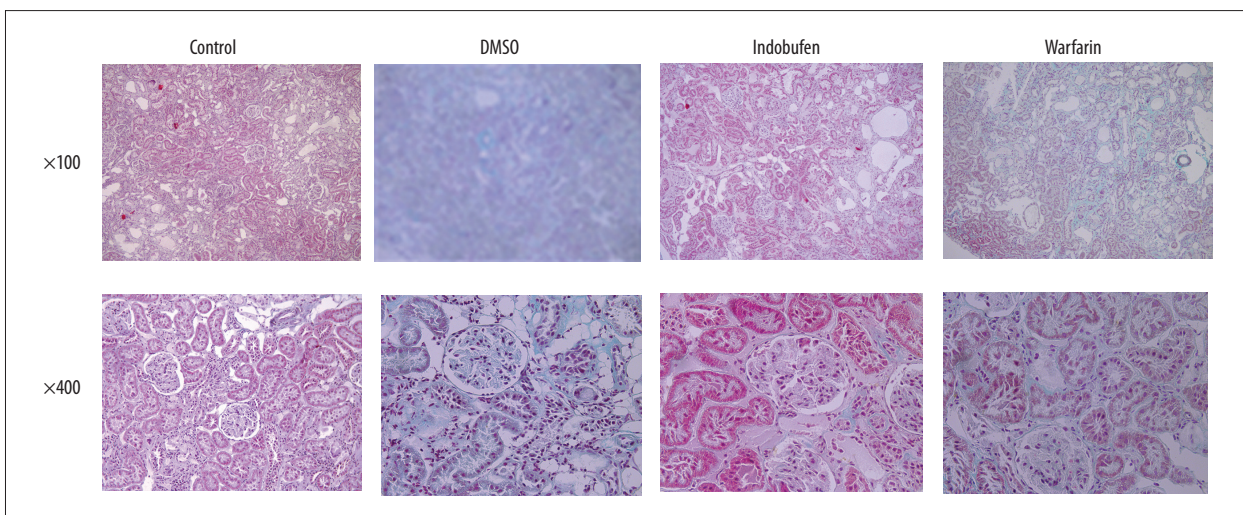


Figure 4. Photomicrographs of the histology of the kidneys in the rat model of adenine-induced chronic kidney disease (CKD) in the control group and rats treated with dimethyl sulfoxide (DMSO), indobufen, and warfarin. Masson trichrome and hematoxylin and eosin (H&E). Magnification: $\times 100$, and $\times 400$.

Table 1. The proportion of the kidney tissue showing staining with Masson trichrome for fibrosis in the rat model of adenine-induced chronic kidney disease (CKD) in the control group and rats treated with dimethyl sulfoxide (DMSO), indobufen, and warfarin.

Treatment group	Control	DMSO	Indobufen	Warfarin
Area stained with Masson trichrome	0%	58%	26%	49%

For each group, three random fields were chosen and the percentage of the stained area in the total field was measured using ImageJ software. The results represent the average percentage.

cell infiltrates were observed in all treatment groups. Some tubular epithelial cells underwent squamous metaplasia, and there were necrotic cells (Figure 3). Masson trichrome staining showed the degree of tissue fibrosis (Figure 4). The average area of kidney fibrosis was measured (Table 1), and compared with the DMSO and warfarin groups, the degree of fibrosis in the indobufen group was significantly reduced but was greater than that of the controls.

Platelet counts and serum coagulation factors and treatment with DMSO, indobufen, and warfarin

Figure 5 shows the platelet counts of the four groups at week 4 and week 12 after treatment (Figure 5A.i, 5A.ii). The four groups did not differ significantly at week 4 and week 12. Serum levels of cyclooxygenase 1 (COX-1), COX-2, transforming growth factor- β (TGF- β) and Smad3 were determined by Western blot. Serum levels of prostaglandin I₂ (PGI₂) (or prostacyclin) and thromboxane A₂ (TXA₂) were determined by enzyme-linked immunoassay (ELISA).

Renal function tests and treatment with DMSO, indobufen, and warfarin

Figure 5 shows the levels of creatinine (Figure 5B.i, 5B.ii) and blood urea nitrogen (BUN) (Figure 5C.i, 5C.ii) of the four treatment groups at week 4 and week 12 after treatment. The rats in the control group had significantly lower levels than those in the other three treatment groups at week 4 and week 12 ($P < 0.05$). There was no significant difference in the levels between the treatment groups.

Coagulation factors and treatment with DMSO, indobufen, and warfarin

Figure 5 shows the prothrombin time (PT) (Figure 5D.i, 5D.ii) and activated partial thromboplastin time (APTT) (Figure 5E.i, 5E.ii) in the four treatment groups at week 4 and week 12 after treatment. The APTT and PT were significantly increased in the warfarin group compared with the other three groups at week 4 and week 12 (all, $P < 0.05$).

Expression of COX-1 and treatment with DMSO, indobufen, and warfarin

As shown in Figure 5E, at week 4 and week 12, the level of COX-1 (Figure 5F.i, 5F.ii) was significantly lower in the indobufen group than the DMSO and warfarin groups ($P < 0.05$), which were similar to the levels found in the control group. The levels of COX-2 (Figure 5G.i, 5G.ii) did not significantly differ between the indobufen and the warfarin group.

Expression of TGF- β and Smad3 and treatment with DMSO, indobufen, and warfarin

As shown in Figure 5, the levels of TGF- β and Smad3 [12] were significantly lower in the indobufen group than in the DMSO group and the warfarin group ($P < 0.05$) at week 4 and week 12. However, TGF- β and Smad3 levels were significantly higher than in the control group ($P < 0.05$).

Expression of 6-keto-prostaglandin I₂ (PGI₂), and thromboxane B₂ (TXB₂) and treatment with DMSO, indobufen, and warfarin

As shown in Figure 5I.i, at week 4, the level of 6-keto-prostaglandin I₂ (PGI₂), and thromboxane B₂ (TXB₂) in the indobufen treated group was significantly higher than in the DMSO and warfarin groups ($P < 0.05$), with a similar finding at week 12 (Figure 5I.ii).

Discussion

Warfarin has good antiplatelet effects and is widely used clinically for anticoagulant therapy in combination with heparin, particularly in patients with chronic kidney disease (CKD) [13]. However, there are several side effects, including bleeding complications, such as gastrointestinal bleeding, subcutaneous hemorrhage, and cerebral hemorrhage, which restricts its use [8,9]. Previous studies have confirmed that indobufen is an effective antiplatelet drug [14]. Therefore, this study aimed to compare indobufen and warfarin in the rat model of adenine-induced CKD. The findings showed that the degree of inflammatory infiltration and fibrosis of the renal tissue of the rats in the group treated with indobufen was significantly lower than

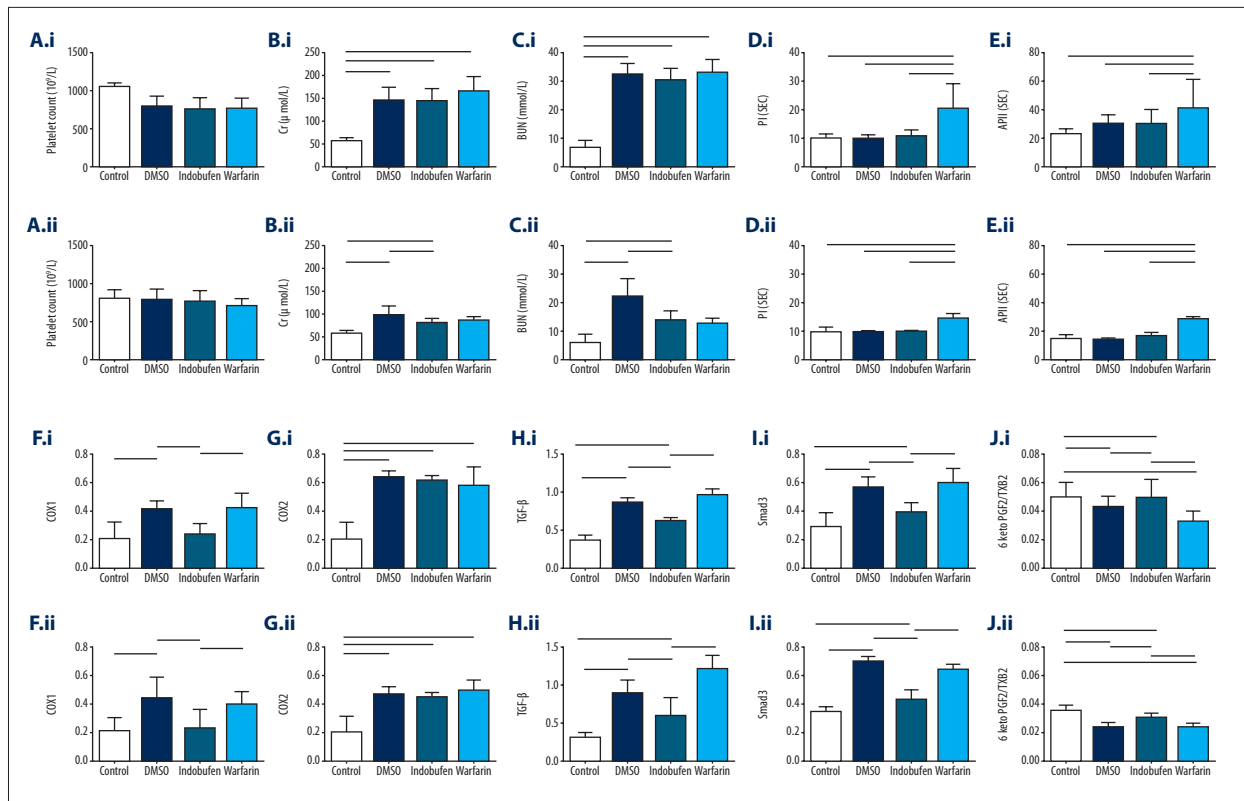


Figure 5. (A–J) Effects of indobufen and warfarin on biochemical indices in the rat model of adenine-induced chronic kidney disease (CKD) in the control group and rats treated with dimethyl sulfoxide (DMSO), indobufen, and warfarin at 4 week and 12 weeks. Levels of cyclooxygenase 1 (COX-1) and COX-2 were determined Western blot. Prostacyclin (PGI₂) and thromboxane A₂ (TXA₂) levels in the rat serum were measured by enzyme-linked immunoassay (ELISA). Concentrations of transforming growth factor- β (TGF- β) and Smad3 were measured by Western blot. Data are expressed as the mean \pm standard deviation (SD) for each group (N=6). The horizontal lines indicate P<0.05 of the groups.

that of the groups treated with dimethyl sulfoxide (DMSO) and warfarin. The ratio of 6-keto-prostaglandin I₂ (PGI₂) to thromboxane B₂ (TXB₂) in this group treated with indobufen was also significantly greater than that in the other three groups. Cyclooxygenase-1 (COX-1) and Smad3 levels were higher than in the warfarin group. The rats in the indobufen group had significantly lower prothrombin time (PT) and activated partial thromboplastin time (APTT) levels, but COX-2 levels were not significantly different between the groups.

The COX-2 measurements in this study supported the antiplatelet effects of indobufen. Indobufen had little effect on the coagulation factors in the rat model of CKD and did not affect the production and consumption of platelets or reduce the number of platelets. Because indobufen did not affect the coagulation function of the rats, this finding suggests that the risk of bleeding after the use of indobufen may be reduced. However, this finding requires validation with further preclinical and clinical studies.

Also, in the present study, histology of the kidney tissue in the rat model of CKD treated with indobufen showed a lower degree of fibrosis [15] and inflammation when compared with the group treated with warfarin. This finding suggests that indobufen had a protective effect on the kidney. Furthermore, the activity of COX-1 was significantly inhibited in the kidney tissue of the indobufen group, and the ratio of 6-keto-PGI₂ to TXB₂ [16–18] was increased. Previous studies have suggested that a higher ratio of 6-keto-PGI₂ to TXB₂ can reduce renal fibrosis [19]. Therefore, it is possible that indobufen reduced renal fibrosis in the rat model of CKD by upregulating the ratio of 6-keto-PGI₂ to TXB₂. In this preliminary study, further pathway analysis of the effects of indobufen were performed, and conclusions regarding its effects on chronic changes in the kidney, including fibrosis, cannot be made.

In this study, there was no significant difference in the reduction in urea and creatinine levels between the three treatment groups of DMSO, indobufen, and warfarin. Histology of the rat kidney tissue supported an association with reduced renal damage in the group treated with indobufen. In this

study, the treatment period was short, and the study sample size was small, and these factors might explain the discrepancy between the serum and kidney tissue findings. To the best of our knowledge, this study was one of the first to investigate the effects of the new antiplatelet drug, indobufen, on CKD. By treating the CKD rat model with indobufen, warfarin, and two controls, the finding that indobufen was associated with significantly reduced kidney fibrosis than warfarin might encourage further studies on the safety and efficacy of this antiplatelet drug. Future studies using the rat model of CKD should be undertaken to investigate the mechanism of the effects of indobufen and will require an increased study sample size and a longer treatment period.

References:

- Eckardt KU, Coresh J, Devuyst O et al: Evolving importance of kidney disease: From subspecialty to global health burden. *Lancet*, 2013; 382(9887): 158–69
- Woo KT, Choong HL, Wong KS et al: The contribution of chronic kidney disease to the global burden of major noncommunicable diseases. *Kidney Int*, 2012; 81(10): 1044–45
- Irish AB, Green FR: Factor VII coagulant activity (VIIc) and hypercoagulability in chronic renal disease and dialysis: Relationship with dyslipidaemia, inflammation, and factor VII genotype. *Nephrol Dial Transplant*, 1998; 13(3): 679–84
- Zivelin A, Rao LV, Rapaport SI: Mechanism of the anticoagulant effect of warfarin as evaluated in rabbits by selective depression of individual procoagulant vitamin K-dependent clotting factors. *J Clin Invest*, 1993; 92(5): 2131–40
- Goodstadt L, Ponting CP: Vitamin K epoxide reductase: Homology, active site and catalytic mechanism. *Trends Biochem Sci*, 2004; 29(6): 289–92
- Hu DY: [The efficacy and safety of antithrombotic therapy with warfarin in nonrheumatic atrial fibrillation.] *Zhonghua Nei Ke Za Zhi*, 2006; 45(10): 800–3 [in Chinese]
- You JH, Chan FW, Wong RS, Cheng G: Is INR between 2.0 and 3.0 the optimal level for Chinese patients on warfarin therapy for moderate-intensity anticoagulation? *Br J Clin Pharmacol*, 2005; 59(5): 582–87
- Robertson L, Yeoh SE, Ramli A: Secondary prevention of recurrent venous thromboembolism after initial oral anticoagulation therapy in patients with unprovoked venous thromboembolism. *Cochrane Database Syst Rev*, 2017; 12: CD011088
- Weber J, Olyaei A, Shatzel J: The efficacy and safety of direct oral anticoagulants in patients with chronic renal insufficiency: A review of the literature. *Eur J Haematol*, 2019; 102(4): 312–18
- Lee JY, Sung KC, Choi HI: Comparison of aspirin and indobufen in healthy volunteers. *Platelets*, 2016; 27(2): 105–9
- Yokozawa T, Zheng PD, Oura H, Koizumi F: Animal model of adenine-induced chronic renal failure in rats. *Nephron* 1986; 44(3): 230–34
- Yang J, Dai C, Liu Y: Hepatocyte growth factor suppresses renal interstitial myofibroblast activation and intercepts Smad signal transduction. *Am J Pathol*, 2003; 163(2): 621–32
- Hirsh J, Fuster V, Ansell J, Halperin JL: American Heart Association/American College of Cardiology foundation guide to warfarin therapy. *J Am Coll Cardiol*, 2003; 41(9): 1633–52
- Vinazzer H, Fuccella LM: Clinical pharmacology studies with indobufen (K 3920): Inhibitor of platelet aggregation. *Clin Pharmacol*, 1980; 20(5–6): 316–25
- Liu Y: Renal fibrosis: New insights into the pathogenesis and therapeutics. *Kidney Int*, 2006; 69(2): 213–17
- Pan X, Lu J, Cheng W et al: Independent factors related to preoperative acute lung injury in 130 adults undergoing Stanford type-A acute aortic dissection surgery: A single-center cross-sectional clinical study. *J Thorac Dis*, 2018; 10(7): 4413–23
- Papanikolaou N, Peros G, Morphake P et al: Does gentamicin induce acute renal failure by increasing renal TXA2 synthesis in rats? *Prostaglandins Leukot Essent Fatty Acids*, 1992; 45(2): 131–36
- Benedetto C, Barbero M, Rey L et al: Production of prostacyclin (PGI2) and thromboxane A2 (TXA2) by vessels draining and not-draining benign and malignant tumours of the breast. *Prostaglandins Leukot Med*, 1985; 17(1): 31–42
- Eddy AA: Molecular basis of renal fibrosis. *Pediatr Nephrol*, 2000; 15(3–4): 290–301

Conclusions

This study aimed to compare the effects of indobufen, a new antiplatelet agent, with warfarin in a rat model of adenine-induced chronic kidney disease (CKD). The preliminary findings showed that indobufen was associated with reduced kidney fibrosis when compared with warfarin, and both warfarin and indobufen had a similar antithrombotic effect.

Conflict of interest

None.