

Ross procedure

H.H. Sievers

Department of Cardiac Surgery, Universitätsklinikum Schleswig-Holstein, Lübeck, Germany

HSR Proceedings in Intensive Care and Cardiovascular Anesthesia 2012; 4(2): 119-123

ABSTRACT

Introduction: In 1967 Donald Ross introduced the subcoronary Ross procedure consisting of transplantation of the autologous pulmonary valve into aortic position. We describe our 15-year experience in Ross procedures.

Methods: 576 subcoronary operations have been performed (436 male and 140 female patients); the mean age was 45 ± 11.9 years. (range, 13 to 70 years). The mean follow-up was 7 ± 4.2 years (range, 0 to 16 years). There were 4597 patient years at follow-up with a clinical completeness of 95% and echo completeness of 91%.

Results: There were two operative deaths (0.3%) and 31 patients with reoperation. The survival is similar to that of the normal population and the freedom from allo- and autograft reoperation is 87% at 15 years. Autograft regurgitation at last examination was grade 0 in 40%, trace in 54%, grade I in 19%, grade II in 4% and grade III in 0.4%; the pressure gradient was smaller than 5 mmHg in 57% and between 5 and 10 mmHg in 24%. Only 6% had a transvalvular pressure gradient of more than 10 mmHg.

Discussion: After 15 years of experience it can be concluded that the subcoronary technique provides near normal survival in adult patients, with excellent hemodynamics and acceptable rate of reoperations.

Keywords: aortic valve replacement, Ross procedure, autograft, survival.

Presented at the 2nd Expert Forum of the Roland Hetzer International Cardiothoracic and Vascular Surgery Society, 11 February 2012, Freiburg, Germany

INTRODUCTION

The replacement of the diseased aortic valve still remains a major problem, especially for young patients. Mechanical valves are durable but confer the risk of thromboembolism and bleeding as well as lifelong anticoagulation.

Bioprostheses as an alternative have a considerable rate of failure which is pronounced in young patients (1).

In 1967 Donald Ross introduced the so called Ross procedure consisting of trans-

plantation of the autologous pulmonary valve into aortic position.

The gap in the right ventricular outflow tract is filled with a homograft. There are three different operative techniques (*Figure 1*): the full root aortic root replacement, the subcoronary original technique and the inclusion technique. The full root technique is most frequently used. *Figure 2* presents an intraoperative photo of a subcoronary implantation after completion of the operation. The operative technique as used in the University of Luebeck is summarized in *Figure 3*. The most important points are annulus side by side traction U-stitches and reinforcement and reduction of the annulus which is most important to prevent later recurrence of insufficiency.

Corresponding author:

Prof. Dr. Med. Hans-Hinrich Sievers
 Department of Cardiac Surgery
 Universitätsklinikum Schleswig-Holstein
 Lübeck, Germany
 e-mail: sievers@medinf.mu-luebeck.de

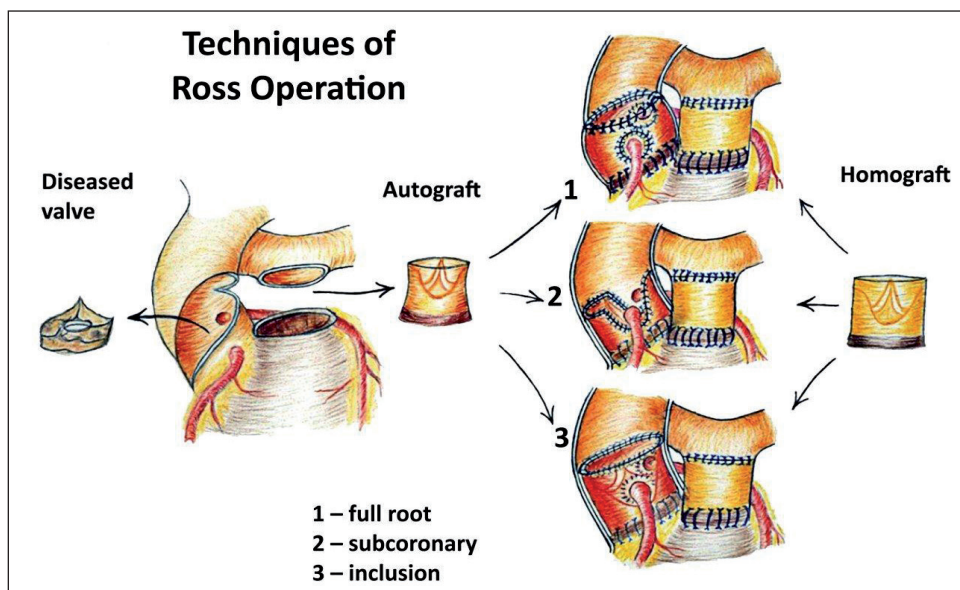


Figure 1
Techniques of Ross Operation.

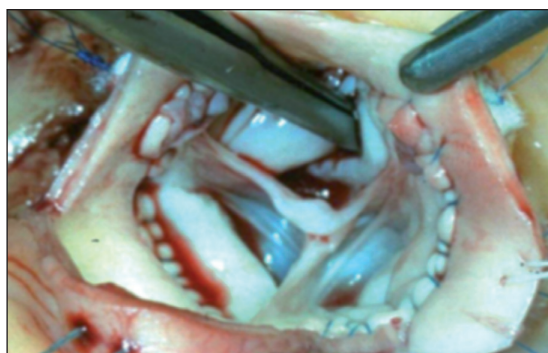

Figure 2 - *Ross operation - subcoronary technique.*

METHODS

In the University of Luebeck 576 subcoronary operations have been performed (436 male and 140 female patients); the mean age was 45 ± 11.9 years. (range, 13 to 70 years). The mean follow-up was 7 ± 4.2 years (range, 0 to 16 years). There were 4597 patient years at follow-up with a clinical completeness of 95% and echo completeness of 91%. In addition to the subcoronary technique 15 root procedures have been performed. The local ethics committee approved the present study.

RESULTS

There were two operative deaths (0.3%) and 31 reoperations as indicated in figure 4. The survival is similar to that of the normal population and the freedom from allo- and autograft reoperation is 87% at 15 years (*Figures 5 and 6*).

Autograft function at last examination was insufficiency grade 0 in 40% of patients, insufficiency trace in 54%, insufficiency grade I in 19%, insufficiency grade II in 4% and insufficiency grade III in 0.4%; the pressure gradient was smaller than 5 mmHg in 57%, between 5 and 10 mmHg in 24% and higher than 10 mmHg in 6% of the patients.

The homograft function at last examination was regurgitation grade 0, trace, I, II, III, IV: 36%, 25%, 21%, 5%, 1%, respectively. The mean pressure gradient was smaller than 5 mmHg in 14% of the patients, 5-10 mmHg in 44%, 11-15 mmHg in 16%, 16-20 mmHg in 4%, 21-25 mmHg in 3% and higher than 25 mmHg in 2% of the patients. In two patients there was tricuspid insufficiency grade III.

Operative technique (subcoronar, Lübeck)

1. Annulus side by side, intraannular, no inversion
2. Traction U-stiches alternatively to single over and over stitches
3. Commissures hitched-up
4. Annulus and sinu-tubular junction matched roughly to autograft dimensions, target size 25-28mm (reduction and reinforcement)



5. Sinus suture 5/0 Prolene continous with additional commissural U-stiches with pledgets on the inside and outside

Figure 3
Technical details.

DISCUSSION

Although there has been tremendous progress in cardiovascular medicine, especially in cardiac surgery, the choice of the ideal

prosthesis for aortic valve replacement is still problematic and challenging, especially for young patients. The Ross procedure provides the advantage of autologous tissue which is living and most likely has the ca-

Patient Data (June 1994 – Jan 2012)
Subcoronary Technique Luebeck

Ross-Operation: Clinical Outcome

- **hospital mortality:** n = 2 (0.3%)
- **late mortality:** n = 38
- *cardiac:* n = 13
- *non cardiac:* n = 25

- **reoperations in n = 31 Pts. (5.4%) no letality**

autograft procedures
repair (n=2) or replacement (n=18)

homograft procedures
repair (n=4) replacement (n=16)

(incl. autograft and homograft in n=6 patients)

Figure 4
Clinical outcome.

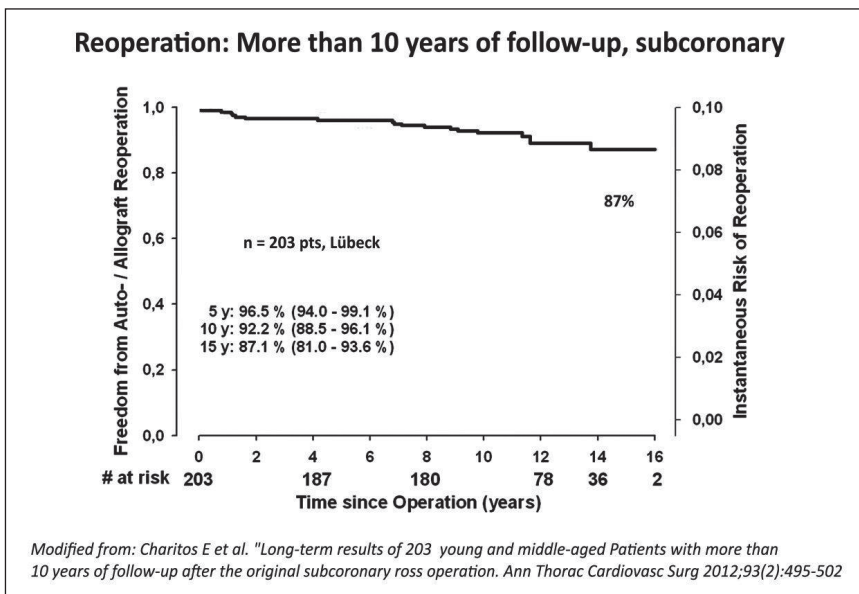


Figure 5
Reoperation.

capacity of regenerative processes. From this point of view the Ross operation should provide a lifelong solution for aortic valve replacement; however the gap in the right ventricular outflow tract is closed by a homograft, which is a risk factor for reoperation. The great advantage of the Ross operation is the expectation of normal survival.

This could be the consequence of selecting patients but there were also patients with a preoperatively reduced left ventricular ejection fraction, so the survival advantage may be real. On the other hand it is conceivable that the excellent hemodynamics, with an almost normal pressure gradient across the autograft, have some influence

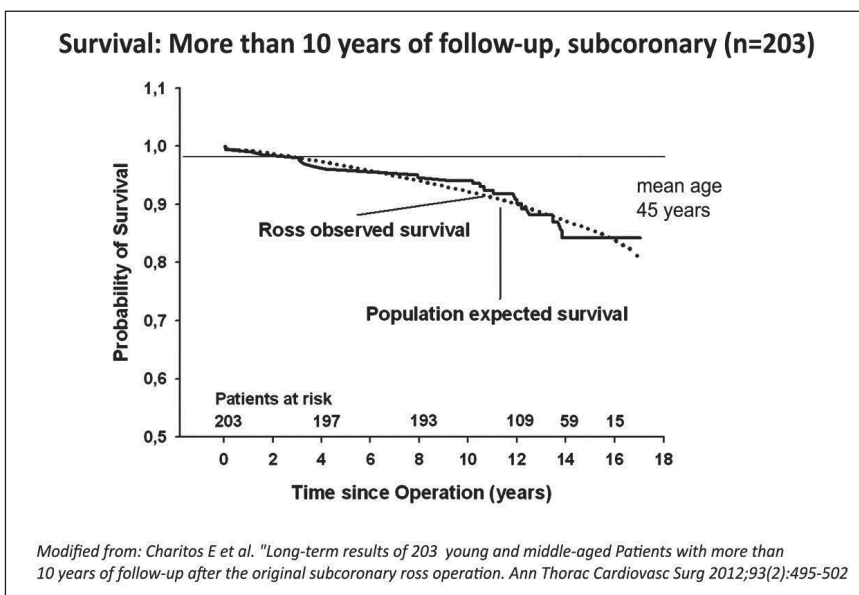


Figure 6
Survival.

on survival of the patients, because the left ventricle has less hemodynamic burden than with alternative substitutes such as mechanical prostheses and bioprostheses, with pressure gradients rising to more than 20 and 30 mmHg during exercise. The limitation of the Ross procedure is the risk of reoperation: two valves are at risk. In some centers (2) the reoperation rate is high, starting at 7 years after the operation. In this series mostly full root replacements were performed. In our study the reoperation rate is lower and the freedom from reoperation after 15 years is 87% which is higher than for the reported series of full root replacement.

Nevertheless, if full root replacement is accompanied by reduction and reinforcement of the annulus, also excellent results can be obtained regarding reoperation (3). After these 15 years of experience it can be concluded that the subcoronary technique provides near normal survival in adult patients, the risk for bleeding and thromboembolism

is low and the risk for reoperation is acceptable after 15 years. The bicuspid valve and aortic insufficiency are not contraindication for the Ross operation. Nevertheless, there is room for improvement of this ingenious concept: the reduction and reinforcement of the annulus and sinutubular junction, prophylaxis for endocarditis and blood pressure control are especially important. Furthermore, new developments of pulmonary valve substitutes, especially decellularized homografts, may have the potential for an even more greatly reduced reoperation rate.

REFERENCES

1. Chan V, Malas T, Lapierre H, et al. Reoperation of left heart valve bioprostheses according to age at implantation. *Circulation* 2011; 124: 75-80.
2. Kouchoukos NT, Davila-Roman VG, Spray TL, et al. Replacement of the aortic root with a pulmonary autograft in children and young adults with aortic valve disease. *N Eng J Med* 1994; 330: 1-6.
3. Charitos EI, Hanke T, Stierle U, et al. German-Dutch Ross Registry. Autograft reinforcement to preserve autograft function after the Ross procedure: a report from the German-Dutch Ross registry. *Circulation* 2009; 120: 146-54.

Cite this article as: Sievers HH. Ross procedure. *HSR Proceedings in Intensive Care and Cardiovascular Anesthesia* 2012; 4 (2): 119-123

Source of Support: Nil. **Conflict of interest:** None declared.

Acknowledgements: We thank Anne Gale for carefully copy-editing the manuscript.