

Nodular fasciitis of the oro-facial region

PRIYA SUBRAMANIAM, RAMDAS BALAKRISHNA¹, MAHENDRA P.¹, GILHOTRA K.

Abstract

Nodular fasciitis is a benign proliferative spindle-cell lesion that presents as a rapidly growing mass frequently being mistaken for a sarcoma. A rare presentation and treatment of nodular fasciitis in the cheek of an 8-year-old boy is described here. He came with a chief complaint of swelling in the left cheek since 1 month which rapidly increased to the size of a marble, over a period of 1 month. Surgical excision of the lesion was planned under general anesthesia following which the surgical site was closed with resorbable sutures. Based on the history, clinical picture, and histopathological examination, the lesion was diagnosed as nodular fasciitis. Although infrequent in both children and the oral mucosa, nodular fasciitis should be considered in the differential diagnosis of facial tumors in infants and young children.

Keywords: Benign, nodular fasciitis, swelling, tumor

Introduction

Nodular fasciitis is defined by the World Health Organization as a benign and reactive fibroblastic growth extending from the superficial fascia into the subcutaneous tissue or muscle.^[1] The tumors are equally distributed between genders and are more common in the third to fifth decades of life.^[2] Lesions are small, solitary, and are commonly located on extremities occasionally on the trunk and infrequently on the head and neck. Oro-facial lesions involve the skin of the face, parotid gland, buccal mucosa, labial mucosa, and tongue.^[3] Nodular fasciitis is rarely diagnosed in childhood but appears in the head and neck region more commonly in children than in adults.^[4]

The etiology of nodular fasciitis is unknown. The role of trauma in initiating the lesion is doubtful.^[5] Prior to its recognition as a distinct entity, nodular fasciitis was often classified as some form of sarcoma usually liposarcoma, fibrosarcoma, or rhabdomyosarcoma. In 1955, Konwaler and associates published the first formal description of nodular

fasciitis, naming it as subcutaneous pseudosarcomatous fibromatosis.^[6]

Case Report

A 9-year-old male patient with no significant medical history reported to the Department of Pedodontics and Preventive Dentistry with a chief complaint of swelling in the left cheek since 1 month. The onset of swelling was associated with fever. It was initially of pea size and rapidly increased to the size of a marble, over a period of 1 month. It was not associated with pain or discomfort.

On extra-oral examination, the mass measured 3 × 3 cm and was located at the junction of middle and lower third of the face, 2 cm lateral to the angle of the mouth. The mass was freely movable and no ulceration was observed on the overlying skin. Intra-orally the swelling involved the buccal mucosa at the occlusal plane and extended from the distal aspect of first primary maxillary molar to the distal aspect of permanent maxillary first molar. Bi-digital examination revealed that the swelling was firm in consistency, mobile, and appeared to infiltrate the surrounding soft tissue. The mucosa overlying the swelling was intact. Intraoral examination also revealed dental caries in relation to mandibular left primary second molar.

Aspiration of the swelling did not show any contents. A radiograph of the intra-oral swelling, taken by placing an intra-oral film between the buccal mucosa and the posterior buccal surfaces did not show any radiopacity. Intra-oral periapical radiograph in relation to mandibular left primary second molar revealed deep dental caries involving the pulp. Ultrasonography of the left cheek was carried out. This showed a well demarcated solitary isolated tumor involving the buccal mucosa.

Surgical excision of the lesion was planned under general anesthesia. Prior to surgery routine blood investigations were carried out. After achieving general anesthesia with

Departments of Pedodontics and ¹Oral & Maxillofacial Surgery, The Oxford Dental College, Hospital and Research Centre, Bommanahalli, Hosur Road, Bangalore, Karnataka, India.

Correspondence: Dr. Priya Subramaniam, Department of Pedodontics, The Oxford Dental College, Hospital and Research Centre, Bommanahalli, Hosur Road, Bangalore – 560 068, Karnataka, India. E-mail: drpriyapedo@yahoo.com

Access this article online	
Quick Response Code:	Website: www.contempclindent.org
	DOI: 10.4103/0976-237X.95096

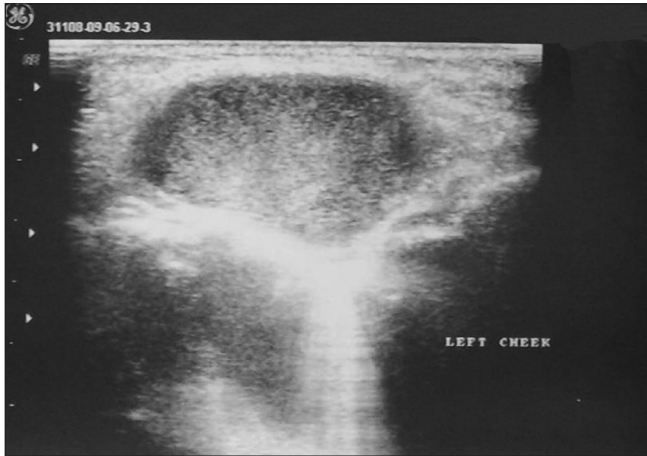

Figure 1: Ultrasonography of the left cheek showing a well demarcated solitary isolated tumor involving the buccal mucosa

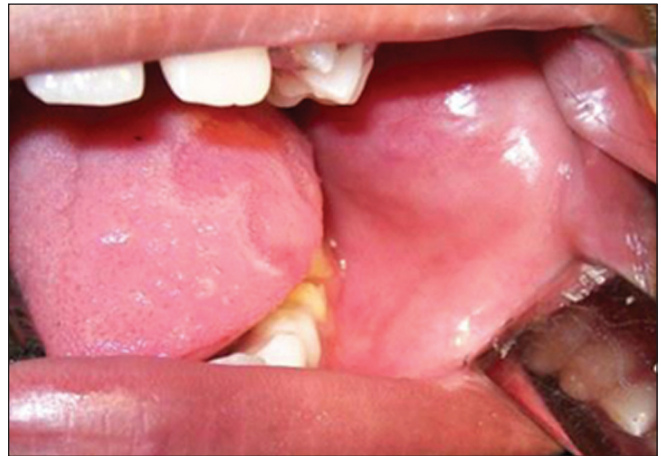

Figure 2: Intra oral swelling i.r.t buccal mucosa

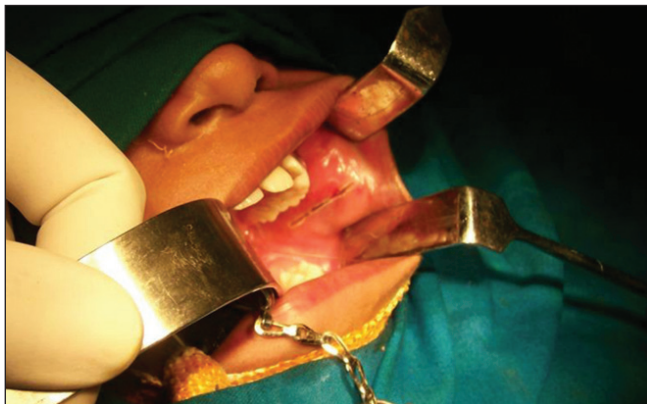

Figure 3: Intra oral horizontal incision made antero-posteriorly using electrocautery along the buccal mucosa and over the most prominent part of the swelling

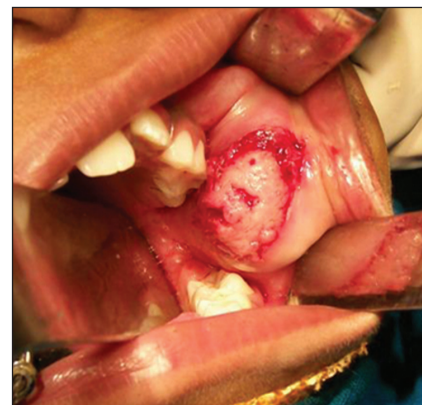

Figure 4: Surgical exposure of swelling

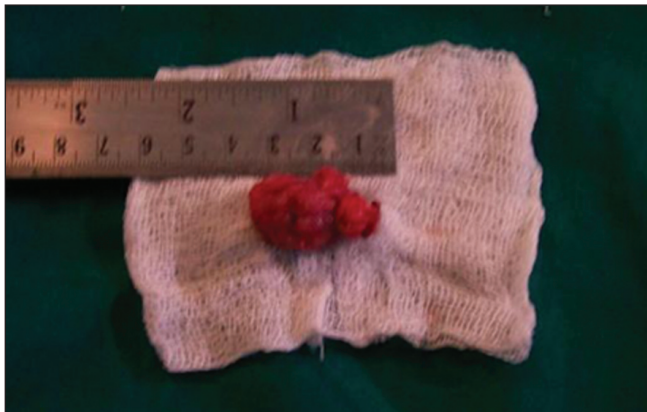

Figure 5: The excised mass was a pinkish white, nodular and nonencapsulated

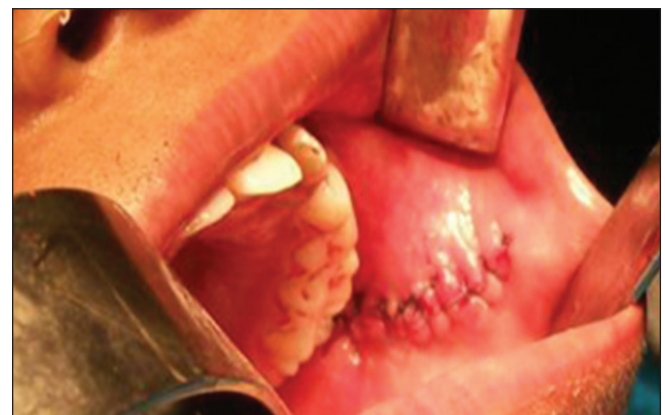

Figure 6: Haemostasis was achieved and the surgical site was sutured with resorbable sutures

oral intubation, infiltration was given over and around the swelling with local anesthetic containing 2% adrenaline. A horizontal incision was made anteroposteriorly using electrocautery along the buccal mucosa and over the most prominent part of the swelling. The swelling was relieved all

around from its mucosal attachment including the buccal pad of fat. The lesion was removed in toto using allieps forceps. The excised mass was a pinkish white, nodular, nonencapsulated and measured 2 × 2.5 cm. Hemostasis was achieved and the surgical site was closed with resorbable sutures. Post-operative instructions regarding the diet and oral hygiene practice were given.

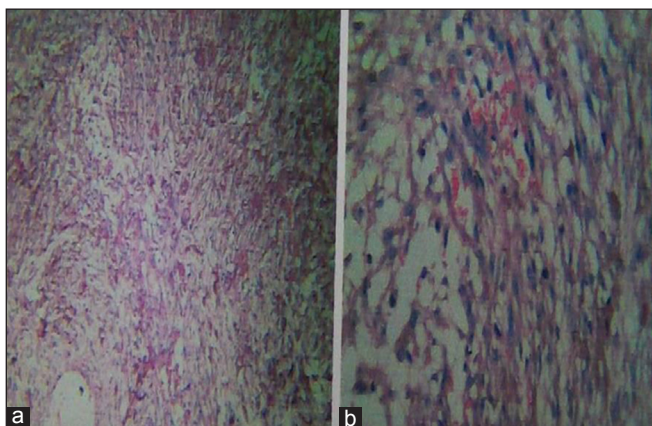


Figure 7: Histopathological examination showed predominately spindle cells arranged in a nodular contour and appearing whorled is (a) $\times 10$ and (b) $\times 40$

Histopathological examination showed predominately spindle cells arranged in a nodular contour and appearing whorled. Individual cells showed vesicular nuclei with mild degree of pleomorphism and occasional mitotic figures. Also seen were diffusely scattered lymphocytes, polymorphs, and good number of congested blood vessels with plenty of extravasated red blood cells [Figures 1-7].

Based on the history, clinical picture, and histopathological examination, the lesion was diagnosed as nodular fasciitis.

Dental treatment included oral prophylaxis, sealant application, and root canal treatment in relation to mandibular left primary second molar, followed by restoration with a stainless steel crown.

Discussion

Benign fibrous tumors represent a group of clinical entities that are often difficult to diagnose. Nodular fasciitis is one such benign fibroblastic proliferation whose rapid growth and rich cellularity frequently cause the lesion to be misdiagnosed as fibroma, lipoma or sarcoma.^[2,7-9] Thus, when presented with a rapidly growing soft tissue tumor in a child, uncommon diagnoses need to be considered. Nodular fasciitis can be distinguished from these based on histopathological examination, molecular biology, and immunohistochemistry.^[10]

The absence of fat globules, areolar tissue and collagen strands differentiated it from lipoma. Also in fibroma there are bundles of interlacing collagenous fibers interspersed with varying number of fibroblasts or fibrocytes and small blood vessels.^[11] Nodular fasciitis is believed to occur as an unusual proliferation of myofibroblasts triggered by local injury or inflammatory processes. The myofibroblast is thought to be the cell of origin.^[5] Nodular fasciitis accounts for 0.025% of all pathologic diagnosis, with less than 4% of those cases occurring in children aged 0–9 years of age.^[6,12]

Treatment of choice is complete resection, which may not always be possible. Partial excision is acceptable as any residual lesion may resolve spontaneously.^[13] Recurrence is rare with a low recurrence rate of 0.4% to 1%.^[8] Any recurrence could indicate an error in initial diagnosis. In the present case, on the 4th day following surgical excision, a diffuse inflammatory type of swelling was observed over the operated site. Pus was drained intraorally and its culture showed moderate growth of *Klebsiella* species. The patient was prescribed augmentine 375 mg twice daily for 5 days, following which the swelling subsided. Ten days later there was resorption of the sutures and the operated site had healed uneventfully. The patient continues to be under observation and has shown no signs of recurrence.

Conclusion

This case demonstrates that although infrequent in children, nodular fasciitis should be considered in the differential diagnosis of facial tumors for an accurate diagnosis and timely treatment.

References

- Robertson B, Roche WC, Shabb B. Nodular fasciitis: A case report. *J Oral Maxillofac Surg* 1986;44:236-9.
- Han W, Hu Q, Yang X, Wang Z, Huang X. Nodular fasciitis in the orofacial region. *Int J Oral Maxillofac Surg* 2006;35:924-7.
- Dayan D, Nasrallah V, Vered M. Clinico-pathologic correlations of myofibroblastic tumors of the oral cavity: 1. Nodular fasciitis. *J Oral Pathol Med* 2005;34:426-35.
- Handa Y, Asai T, Tomita Y. Nodular fasciitis of the forehead in a pediatric patient. *Dermatol Surg* 2003;29:867-8.
- Graham BS, Barrett TL, Goltz RW. Nodular fasciitis: Response to intralesional corticosteroids. *J Am Acad Dermatol* 1999;40:490-2.
- Kleinstiver BJ, Rodriguez HA. Nodular fasciitis. A study of forty-five cases and review of the literature. *J Bone Joint Surg Am* 1968;50:1204-12.
- Price EB Jr, Silliphant WM, Shuman R. Nodular fasciitis: A clinicopathologic analysis of 65 cases. *Am J Clin Pathol* 1961;35:122-36.
- Shimizu S, Hashimoto H, Enjoji M. Nodular fasciitis: An analysis of 250 patients. *Pathology* 1984;16:161-6.
- Carr MM, Fraser RB, Clarke KD. Nodular fasciitis in the parotid region of a child. *Head Neck* 1998;20:645-8.
- Montgomery EA, Meis JM. Nodular fasciitis. Its morphologic spectrum and immunohistochemical profile. *Am J Surg Pathol* 1991;15:942-8.
- Shafer HL. *Shafer's textbook of oral pathology*. 5th ed. Amsterdam: Elsevier; 2006. p. 178-180,194-195.
- Batsakis JG, Rice DH, Howard DR. The pathology of head and neck tumors: Spindle cell lesions (sarcomatoid carcinomas, nodular fasciitis, and fibrosarcoma) of the aerodigestive tracts, Part 14. *Head Neck Surg* 1982;4:499-513.
- Gelfand JM, Mirza N, Kantor J, Yu G, Reale D, Bondi E, *et al.* Nodular fasciitis. *Arch Dermatol* 2001;137:719-21.

How to cite this article: Subramaniam P, Balakrishna R, Mahendra P, Gilhotra K. Nodular fasciitis of the oro-facial region. *Contemp Clin Dent* 2012;3:S16-8.

Source of Support: Nil. **Conflict of Interest:** None declared.