



Case report

Pembrolizumab-induced pneumonitis with a perilymphatic nodular pattern in a lung cancer patient: A radio-pathologic correlation

Ryo Ueno^a, Masahiro Nemoto^{b,*}, Wataru Uegami^c, Junya Fukuoka^c, Masafumi Misawa^b

^a Department of Intensive Care Medicine, Kameda Medical Center, Kamogawa, Chiba, Japan

^b Department of Pulmonary Medicine, Kameda Medical Center, Kamogawa, Chiba, Japan

^c Department of Pathology, Kameda Medical Center, Kamogawa, Chiba, Japan

ARTICLE INFO

Keywords:

Pembrolizumab
Lung cancer
irAE

ABSTRACT

A 66-year-old Japanese man with recurrent adenocarcinoma of the lung p-stage IIIA (pT2bN2M0; version 8) on pembrolizumab was present with gradually worsening dyspnea. Although history and physical examination were unremarkable, high-resolution CT showed the perilymphatic distribution of the pembrolizumab-induced pneumonitis. Consistent with the CT result, biopsy revealed the aggregation of the cytotoxic (CD8⁺) T-lymphocytes around the lymph tracts. Given the clinical, radiological and pathological findings, pembrolizumab-induced pneumonitis was confirmed. The patient was discharged after terminating the pembrolizumab with ameliorated symptoms. This report, in conjunction with existing literature, illustrates the wide variety of the pembrolizumab-induced pneumonitis and bolsters the current understanding of its pathophysiology.

1. Introduction

Immune-checkpoint inhibitor (ICI) therapy using anti-PD-1 (anti-programmed cell death 1) or anti-PD-L1 (anti-programmed cell death ligand 1) inhibitors have shown marked efficacy in the treatment of lung cancer. However, systemic toxicities associated with the use of PD-1 inhibitors have been commonly reported and pneumonitis is one of those complications [1–3]. It has been recognized that ICI-induced pneumonitis has a broad spectrum of radiographic manifestations including cryptogenic organizing pneumonia (COP) pattern, nonspecific interstitial pneumonia (NSIP) pattern, and hypersensitivity pneumonia (HP) pattern [4,5], while no case has reported the perilymphatic nodular pattern with both radiological and pathological evidence.

2. Case presentation

Our patient is a 66-year-old Japanese man diagnosed with right upper lobe adenocarcinoma of p-stage IIIA (pT2bN2M0; version 8) post right upper lobectomy. After a year of surgical resection, recurrent mediastinal lymph node metastases were confirmed by endobronchial ultrasound-guided transbronchial needle aspiration (EBUS-TBNA). Based on the result of immunohistochemical staining (TTF-1+, p40-, Tumor Proportion Score (TPS); PD-L1 IHC 22C3 pharm DX Dako) 100%, EGFR-mutation -, ALK-rearrangement FISH-, ROS1-rearrangement RT-PCR-, The anti-Programmed Death receptor 1 (anti-PD-1) antibody

pembrolizumab 200mg/body once every three weeks was initiated. After the sixth cycle of the treatment, the patient presented to the clinic with worsening dyspnea. He was tachypneic without any fever nor desaturation. Lungs were clear to auscultation. Both complete blood count and chemistry panels were normal. Blood culture, sputum culture, serum β-D glucan, serum galactomannan, serum interferon-gamma release assays (IGRAs) for diagnosing mycobacterium tuberculosis, and serological assay by use of glycopeptide lipid core antigen for diagnosing mycobacterium avium complex came back negative.

High-resolution chest CT (HRCT) revealed bilateral diffuse well-defined 1–2 mm of small granular shadow along with thickened interlobular septa, consistent with perilymphatic distribution (Fig. 1). Given the lack of any evidence of pulmonary infection or any exposure to the stimulants of hypersensitivity pneumonia, an immune reaction to pembrolizumab was suspected and transbronchial random lung biopsy from the left upper lobe anterior segment and the left lower lobe anterior basal segment was performed (see Fig. 2).

Microscopically, type 2 pneumocytes with bizarre enlarged nuclei as well as lymphocytic infiltration in interstitium were identified. Pigmented macrophages suggested the hemorrhage. Most lymphocytes showed CD8+/CD4-, suggesting cytotoxic T lymphocytes. These findings were consistent with T cell-induced lung injury due to pembrolizumab. In addition, those lymphocytes aggregated around lymphatic vessels, which was confirmed by D2-40 immunohistochemistry.

* Corresponding author. Department of Pulmonary Medicine, Kameda Medical Center, 929 Kamogawa, Chiba, 296-8602, Japan.

E-mail addresses: rueno-tyk@umin.ac.jp (R. Ueno), masahiro.nemoto@kameda.jp (M. Nemoto).

<https://doi.org/10.1016/j.rmcr.2019.01.001>

Received 14 November 2018; Received in revised form 3 January 2019; Accepted 3 January 2019

2213-0071/© 2019 The Authors. Published by Elsevier Ltd. This is an open access article under the CC BY-NC-ND license (<http://creativecommons.org/licenses/by-nc-nd/4.0/>).

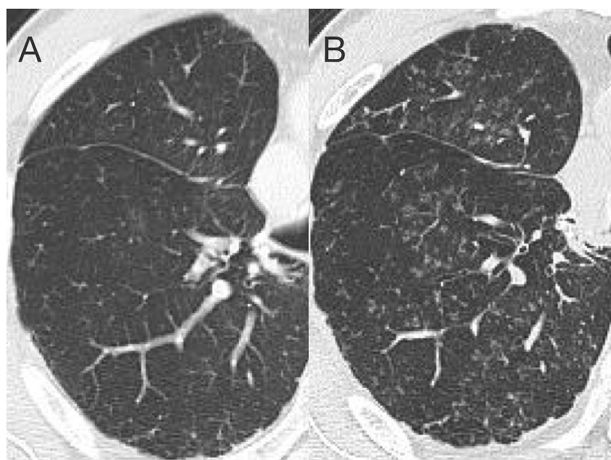


Fig. 1. Noncontrast chest computed tomography taken 5 months prior to admission (A) and on admission (B). Representative axial image demonstrate the diffuse nodular infiltration with inter- and intra-lobular septa or subpleural area.

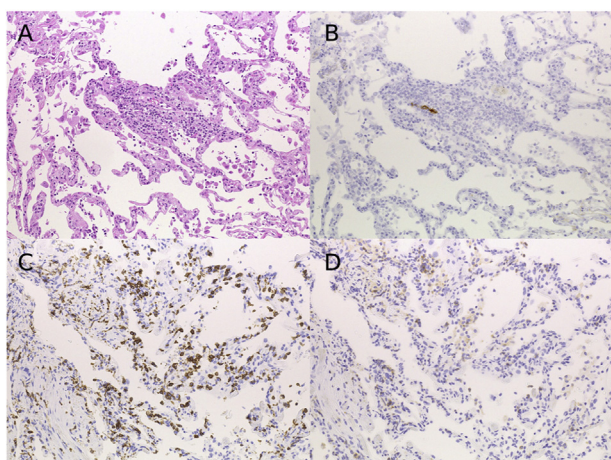


Fig. 2. Lung biopsy samples. Section from trans-bronchial lung biopsy. (A): Notable lymphocyte aggregation in interstitium along with lymphatic duct positive for D2-40 (B). Most lymphocytes are positive for CD8 (C) and negative for CD4 (D).

Those findings were confirmed in all samples of the random biopsy.

Given the clinical, radiological and pathological findings, pembrolizumab-induced pneumonitis was strongly suspected, thereby the treatment was immediately discontinued. After three-week admission, the patient was discharged with ameliorated symptoms. No corticosteroid was administered during admission to avoid potential interference with the anti-tumor effect of pembrolizumab. Complete remission of his tumor has been maintained throughout the follow-up period; pembrolizumab is still suspended.

3. Discussion

In line with the increased use of ICI, systemic toxicities associated with them have been widely reported [1–3]. Amongst those complications, ICI-induced pneumonitis is relatively uncommon: it occurs in about 3%–5% of patients with non-small cell lung cancer treated with ICI [6].

Currently, clinical identification and management of ICI-induced pneumonitis are contingent on radiographic assessment. Therefore, a variety of prior reports have summarised the radiological findings of ICI-induced pneumonitis [3–5,7]. Nishino and colleagues reported the following radiographic patterns observed in 20 patients with

nivolumab-induced pneumonitis: cryptogenic organizing pneumonia (COP) pattern, non-specific interstitial pneumonia (NSIP) pattern, hypersensitivity pneumonitis (HP) pattern, and acute interstitial pneumonia (AIP)/acute respiratory distress syndrome (ARDS) pattern [4]. Likewise, Naidoo and colleagues reported 27 patients with ICI-induced pneumonitis with similar classification including COP pattern, HP pattern, ground glass opacities (GGO) pattern, interstitial pattern, and pneumonitis not otherwise specified [5]. However, none of them reported patients with pembrolizumab-induced pneumonitis. To date, only a limited number of patients have been reported to have pneumonitis after the use of pembrolizumab [8–11]: 4 cases with COP pattern from the US [8], 2 cases with COP pattern and 1 case with NSIP pattern from France [9], 1 case with COP pattern from Greece [10], and one GGO case from Japan [11]. Overall, little is known about radiological findings of the pneumonitis associated with the use of pembrolizumab.

Similarly, there is a dearth of research in the pathological characteristics of the ICI-induced pneumonitis. Naidoo and colleagues reported diverse pathological findings amongst 11 patients with ICI-induced pneumonitis, such as alveolar damage and granulomatous inflammation [5]. Delaunay and colleagues summarised their biopsy findings from six transbronchial biopsy specimens and reported the presence of CD3 positive lymphocyte aggregation [12]. However, none of them have reported the association between radiological and pathological findings.

Our patient had pembrolizumab-induced pneumonitis with perilymphatic nodular pattern. CT findings including granular shadow on the bronchovascular bundle, intralobar pleura, and visceral pleura were strongly suggestive of perilymphatic distribution, whereas it could have been confused with a HP pattern similar to centrilobular distribution, had those details not been well captured. The interstitial pattern in a prior radiological study could also be considered [5], but no pathological assessment has been reported. Pathologically, no inflammatory cells were observed in the alveoli, while a tremendous number of CD8 positive cells were found around the lymph tracts dye-marked with D2-40. These findings further support cytotoxic T cell-mediated inflammation spreading via the lymphatic route and also refutes the possibility of trans-bronchial migration of the inflammatory cells, which is essential in developing the HP pattern infiltration. To the best of our knowledge, this is the first report to both radiographically and pathologically confirm the pembrolizumab-induced pneumonitis with the perilymphatic nodular pattern.

Another interesting factor is the treatment of this patient: we avoided using corticosteroids and pneumonitis was resolved both clinically and radiologically. In addition, complete remission has been maintained since the termination of pembrolizumab. Recently, several recommendations were developed to standardize the treatment options of the ICI-induced pneumonitis [13,14]. Treatment intensity is mainly determined by the severity of the pneumonitis. After excluding other diagnoses, including infection and malignant lung infiltration, clinical symptoms of the pneumonitis should be assessed. Asymptomatic pneumonitis can be reasonably managed by drug-withholding with fortnightly monitoring, while a symptomatic case with clinical deterioration is most likely managed with immunosuppressants such as systemic corticosteroids. Additional immunosuppression including infliximab and/or cyclophosphamide is considered amongst patients with recalcitrant pneumonitis [13,14].

Given the immunosuppressive effect of corticosteroids on T-cell function, there is a concern that these agents could decrease the anti-tumor property of ICI. Several clinical trials refute the association between the use of steroids and the decreased overall survival [15–19], while some argue that patients are less likely to respond to ICI if they use corticosteroids before the administration of ICI [19]. In addition, a fatal case was reported with overwhelming infection after using corticosteroids for an adverse event of ICI [5]. Likewise, progression of the primary cancer was triggered by corticosteroids in a patient treated

with ICI [18]. Overall, we are yet to establish a one-fits-all treatment for ICI-induced pneumonitis, but we need to considerate both clinical symptoms and accumulating knowledge to determine the best treatment for each patient. Our patient was slightly symptomatic, but we avoided using corticosteroids given the clinically stable condition and the potentially higher risk of infection and tumor progression. Complete remission has been maintained since the termination of pembrolizumab. To conclude, this is the first report to clinicoradiopathologically confirm the pembrolizumab-induced pneumonitis with the perilymphatic nodular pattern. Notably, both the resolution of the pneumonitis and complete remission of the primary cancer are maintained without corticosteroids. Given the wide variety of clinical, radiographic, and pathologic pictures, physicians should always be judicious when recognizing this complication.

Author contribution

Drafting of the manuscript: RU, MN, WU
Critical revision of the manuscript for important intellectual content: JF, MN, MM.

Declarations of interest

None.

Funding

None.

Appendix A. Supplementary data

Supplementary data to this article can be found online at <https://doi.org/10.1016/j.rmcr.2019.01.001>.

References

- [1] E.B. Garon, N.A. Rizvi, R. Hui, N. Leighl, A.S. Balmanoukian, J.P. Eder, A. Patnaik, C. Aggarwal, M. Gubens, L. Horn, E. Carcereny, M.-J. Ahn, E. Felip, J.-S. Lee, M.D. Hellmann, O. Hamid, J.W. Goldman, J.-C. Soria, M. Dolled-Filhart, R.Z. Rutledge, J. Zhang, J.K. Luceford, R. Rangwala, G.M. Lubiniecki, C. Roach, K. Emancipator, L. Gandhi, Pembrolizumab for the treatment of non-small-cell lung cancer, *N. Engl. J. Med.* 372 (2015) 2018–2028, <https://doi.org/10.1056/NEJMoa1501824>.
- [2] S.N. Gettinger, L. Horn, L. Gandhi, D.R. Spigel, S.J. Antonia, N.A. Rizvi, J.D. Powderly, R.S. Heist, R.D. Carvajal, D.M. Jackman, L.V. Sequist, D.C. Smith, P. Leming, D.P. Carbone, M.C. Pinder-Schenck, S.L. Topalian, F.S. Hodi, J.A. Sosman, M. Sznol, D.F. McDermott, D.M. Pardoll, V. Sankar, C.M. Ahlers, M. Salvati, J.M. Wigginton, M.D. Hellmann, G.D. Kollia, A.K. Gupta, J.R. Brahmer, Overall survival and long-term safety of nivolumab (Anti-Programmed death 1 antibody, BMS-936558, ONO-4538) in patients with previously treated advanced non-small-cell lung cancer, *J. Clin. Oncol.* 33 (2015) 2004–2012, <https://doi.org/10.1200/JCO.2014.58.3708>.
- [3] M. Nishino, A. Giobbie-Hurder, H. Hatabu, N.H. Ramaiya, F.S. Hodi, Incidence of programmed cell death 1 inhibitor-related pneumonitis in patients with advanced cancer: a systematic review and meta-analysis, *JAMA Oncol.* 2 (2016) 1607–1616, <https://doi.org/10.1001/jamaoncol.2016.2453>.
- [4] M. Nishino, N.H. Ramaiya, M.M. Awad, L.M. Sholl, J.A. Maattala, M. Taibi, H. Hatabu, P.A. Ott, P.F. Armand, F.S. Hodi, PD-1 inhibitor-related pneumonitis in advanced cancer patients: radiographic patterns and clinical course, *Clin. Cancer Res.* 22 (2016) 6051–6060, <https://doi.org/10.1158/1078-0432.CCR-16-1320>.
- [5] J. Naidoo, X. Wang, K.M. Woo, T. Iyriboz, D. Halpenny, J. Cunningham, J.E. Chaft, N.H. Segal, M.K. Callahan, A.M. Lesokhin, J. Rosenberg, M.H. Voss, C.M. Rudin, H. Rizvi, X. Hou, K. Rodriguez, M. Albano, R.-A. Gordon, C. Leduc, N. Rekhman, B. Harris, A.M. Menzies, A.D. Guminski, M.S. Carlino, B.Y. Kong, J.D. Wolchok, M.A. Postow, G.V. Long, M.D. Hellmann, Pneumonitis in patients treated with anti-programmed death-1/programmed death ligand 1 therapy, *J. Clin. Oncol.* 35 (2017) 709–717, <https://doi.org/10.1200/JCO.2016.68.2005>.
- [6] K. Suresh, J. Naidoo, C.T. Lin, S. Danoff, Immune checkpoint immunotherapy for non-small cell lung cancer: benefits and pulmonary toxicities, *Chest* 154 (2018) 1416–1423, <https://doi.org/10.1016/j.chest.2018.08.1048>.
- [7] M. Nishino, L.M. Sholl, H. Hatabu, N.H. Ramaiya, F.S. Hodi, Anti-PD-1-Related pneumonitis during cancer immunotherapy, *N. Engl. J. Med.* 373 (2015) 288–290, <https://doi.org/10.1056/NEJMc1505197>.
- [8] M. Nishino, N.H. Ramaiya, H. Hatabu, F.S. Hodi, P.F. Armand, PD-1 inhibitor-related pneumonitis in lymphoma patients treated with single-agent pembrolizumab therapy, *Br. J. Haematol.* 180 (2018) 752–755, <https://doi.org/10.1111/bjh.14441>.
- [9] V. Leroy, C. Templier, J.-B. Faivre, A. Scherpereel, C. Fournier, L. Mortier, L. Wemeau-Stervinou, Pembrolizumab-induced pneumonitis, *ERJ Open Res.* 3 (2017), <https://doi.org/10.1183/23120541.00081-2016>.
- [10] P. Fragkou, M. Souli, M. Theochari, C. Kontopoulou, S. Loukides, A. Koumariannou, A case of organizing pneumonia (OP) associated with pembrolizumab, *Drug Target Insights* 10 (2016) 9–12, <https://doi.org/10.4137/DTI.S31565>.
- [11] T. Sugano, M. Seike, R. Noro, S. Kaburaki, T. Tozuka, A. Takahashi, N. Takano, T. Tanaka, T. Kashiwada, S. Takeuchi, Y. Minegishi, Y. Saito, K. Kubota, Y. Terasaki, A. Gemma, A case of interstitial lung disease with alveolar hemorrhage induced by pembrolizumab, *OncoTargets Ther.* 11 (2018) 5879–5883, <https://doi.org/10.2147/OTT.S169321>.
- [12] M. Delaunay, J. Cadranet, A. Lusque, N. Meyer, V. Gounant, D. Moro-Sibilot, J.-M. Michot, J. Raimbourg, N. Girard, F. Guisier, D. Planchard, A.-C. Metivier, P. Tomasini, E. Dansin, M. Pérol, M. Campana, O. Gautschi, M. Früh, J.-D. Fumet, C. Audigier-Valette, S. Couraud, S. Dalle, M.-T. Leccia, M. Jaffro, S. Collot, G. Prévot, J. Milia, J. Mazieres, Immune-checkpoint inhibitors associated with interstitial lung disease in cancer patients, *Eur. Respir. J.* 50 (2017) 1700050, <https://doi.org/10.1183/13993003.00050-2017>.
- [13] I. Puzanov, A. Diab, K. Abdallah, C.O. Bingham, C. Brogdon, R. Dadu, L. Hamad, S. Kim, M.E. Lacouture, N.R. LeBoeuf, D. Lenihan, C. Onofrei, V. Shannon, R. Sharma, A.W. Silk, D. Skondra, M.E. Suarez-Almazor, Y. Wang, K. Wiley, H.L. Kaufman, M.S. Ernst, M.S. Society for immunotherapy of cancer toxicity management working Group, on behalf of the S. For I. Of C.T.M.W. Group, Managing toxicities associated with immune checkpoint inhibitors: consensus recommendations from the society for immunotherapy of cancer (SITC) toxicity management working Group, *J. Immunother. Cancer* 5 (2017) 95, <https://doi.org/10.1186/s40425-017-0300-z>.
- [14] A. Winer, J.N. Bodor, H. Borghaei, Identifying and managing the adverse effects of immune checkpoint blockade, *J. Thorac. Dis.* 10 (2018) S480–S489, <https://doi.org/10.21037/jtd.2018.01.111>.
- [15] K. Harmanakaya, C. Erasim, C. Koelblinger, R. Ibrahim, A. Hoos, H. Pehamberger, M. Binder, Continuous systemic corticosteroids do not affect the ongoing regression of metastatic melanoma for more than two years following ipilimumab therapy, *Med. Oncol.* 28 (2011) 1140–1144, <https://doi.org/10.1007/s12032-010-9606-0>.
- [16] F.C. Santini, H. Rizvi, O. Wilkins, M. van Voorthuysen, E. Panora, D. Halpenny, M.G. Kris, C.M. Rudin, J.E. Chaft, M.D. Hellmann, Safety of retreatment with immunotherapy after immune-related toxicity in patients with lung cancers treated with anti-PD(L)-1 therapy, *J. Clin. Oncol.* 35 (2017), https://doi.org/10.1200/JCO.2017.35.15_suppl.9012 9012–9012.
- [17] J.S. Weber, J.M.G. Larkin, D. Schadendorf, J.D. Wolchok, J. Wagstaff, R. Dummer, D. Hogg, M. Guidoboni, J.A. Sosman, B. Chmielowski, W. Gerritsen, R. Bhole, D. Walker, R. Gonzalez, Management of gastrointestinal (GI) toxicity associated with nivolumab (NIVO) plus ipilimumab (IPI) or IPI alone in phase II and III trials in advanced melanoma (MEL), *J. Clin. Oncol.* 35 (2017), https://doi.org/10.1200/JCO.2017.35.15_suppl.9523 9523–9523.
- [18] D. Schadendorf, J.D. Wolchok, F.S. Hodi, V. Chiarion-Sileni, R. Gonzalez, P. Rutkowski, J.-J. Grob, C.L. Cowey, C.D. Lao, J. Chesney, C. Robert, K. Grossmann, D. McDermott, D. Walker, R. Bhole, J. Larkin, M.A. Postow, Efficacy and safety outcomes in patients with advanced melanoma who discontinued treatment with nivolumab and ipilimumab because of adverse events: a pooled analysis of randomized phase II and III trials, *J. Clin. Oncol.* 35 (2017) 3807–3814, <https://doi.org/10.1200/JCO.2017.73.2289>.
- [19] S.C. Scott, N.A. Pennell, Early use of systemic corticosteroids in patients with advanced NSCLC treated with nivolumab, *J. Thorac. Oncol.* 13 (2018) 1771–1775, <https://doi.org/10.1016/j.jtho.2018.06.004>.