



Case Report

Bilateral Anterior Glenohumeral Dislocation Following Grand Mal Epileptic Seizure: A Case Report

Farid Samadov, Servin Rafi, Yusuf Sulek, Osman Tugrul Eren

Department of Orthopedics, University of Health Sciences Türkiye, Şişli Hamidiye Etfal Training and Research Hospital, İstanbul, Türkiye

Abstract

Bilateral simultaneous shoulder dislocations are very rare injuries. Majority of the cases in the literature are posterior shoulder dislocations due to widespread contractions seen in grand-mal epileptic seizures, electrocutions, and electric shocks. The literature shows us that bilateral anterior shoulder dislocations are generally seen after trauma related injuries rather than subsequent to epileptic seizures. A 39-year-old male presented to the emergency department our clinic with bilateral anterior glenohumeral dislocation following grand mal epileptic seizure. The patient was treated conservatively with close reduction, Velpeau bandage, PT&R, and neurology consultation. Due to the bilateral displacement of patients shoulders and his age treatment was planned conservatively.

Keywords: Bilateral, Epileptic seizures anterior glenohumeral dislocation, Grand mal

Please cite this article as "Samadov F, Rafi S, Sulek Y, Eren OT. Bilateral Anterior Glenohumeral Dislocation Following Grand Mal Epileptic Seizure: A Case Report. Med Bull Sisli Etfal Hosp 2022;56(4):568–571".

Bilateral simultaneous shoulder dislocations are very rare injuries.^[1,2] First case described is occurred with muscle contractions due to a Camphor poisoning in 1902.^[3] Majority of the cases in the literature are posterior shoulder dislocations due to widespread contractions seen in grand-mal epileptic seizures and electric shocks.

In 1984 Hartney-Velazco did a wide literature research and reported seven bilateral shoulder dislocation cases due to various reasons.^[4] A systemic review published in 2019 shows 100 cases in 90 scientific studies where 60% of these cases were due to trauma, other 40% were due to widespread muscle contractions in which 26% of these cases were secondary to epileptic seizures.^[5]

In this case report, we want to share our experience about

a patient with bilateral anterior shoulder dislocation after an epileptic seizure.

Case Report

A 39-year-old male presented to the emergency department clinic with complaints of bilateral shoulder pain, deformity, and decreased range of motion in both shoulders. The patient anamnesis indicated that he had a seizure in the morning while sleeping in his bed. There was no one who can interfere with the patient during the seizure. He was lying in the supine position before the seizure and was in the right lateral decubitus position after the seizure. The patient has been using sodium valproate 500 mg 1 × 1 since he was diagnosed with epilepsy in 1995. This was his third seizure,

Address for correspondence: Farid Samadov, MD. Şişli Hamidiye Etfal Eğitim Ve Araştırma Hastanesi Ortopedi Kliniği, İstanbul, Türkiye

Phone: +90 507 347 15 97 **E-mail:** ferid.samedov@gmail.com

Submitted Date: November 04, 2021 **Revised Date:** December 18, 2021 **Accepted Date:** January 02, 2022 **Available Online Date:** December 19, 2022

©Copyright 2022 by The Medical Bulletin of Sisli Etfal Hospital - Available online at www.sislietfaltip.org

OPEN ACCESS This is an open access article under the CC BY-NC license (<http://creativecommons.org/licenses/by-nc/4.0/>).



but he has no history of shoulder dislocation before. In the physical examination, bilateral humeral heads were palpable in anterior of shoulder. Acromion lateral edges were prominent and deltoids oval contour was distorted and flattened, epaulettes sign was seen in both shoulders. Neurological and vascular examinations were normal.

Radiological examination demonstrated bilateral anterior-inferior glenohumeral dislocation of shoulders (Figs. 1 and 2). Closed reduction, treatment to be applied, and possible complications were explained to the patient, and written consent was obtained from the patient. The patient was administered with sedation anesthesia and underwent closed reduction with Hippocrates maneuver for both shoulders.

Anatomical reduction was observed in the bilateral shoulder joint in control X-rays of the patient. Computed tomography after reduction revealed bilateral Hill-Sachs lesions (Figs. 3 and 4).

Conservative treatment was applied to the patient because the patient did not want operative treatment.

Bilateral Velpeau bandage was applied to the patient after reduction of both shoulders, then was consulted to neurology in the ER. His drugs were arranged in accordance with neurology recommendations as depacin 500 mg 2 × 1.

Velpeau bandage treatment was discontinued 2 weeks later under our polyclinic control. According to the Oxford Shoulder Score which is related with physical examination of the shoulder joint, in the 1st month, OSS values of the left

and right shoulders were 25 and 22, respectively. In the 3rd month, these values were obtained as 40 and 41, respectively, and in the 10th month, 45 and 43 were the OSS values respectively.

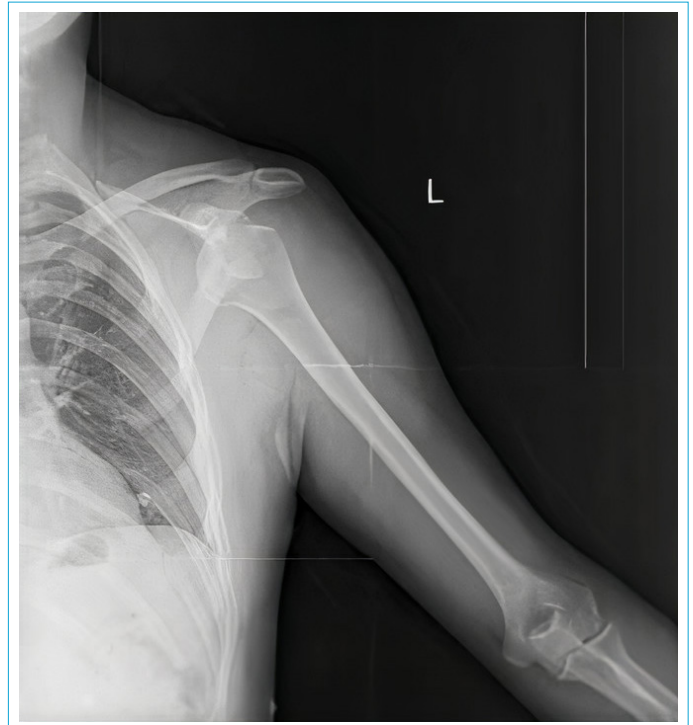

Figure 2. Male patient, 39 years old; AP X-rays of the left shoulder show bilateral anterior shoulder dislocation.

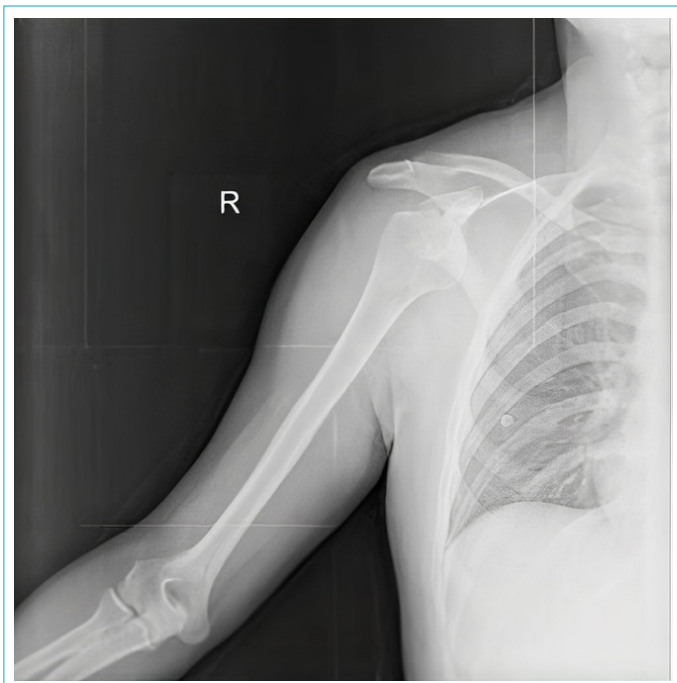

Figure 1. Male patient, 39 years old; AP X-rays of the right shoulder show bilateral anterior shoulder dislocation.

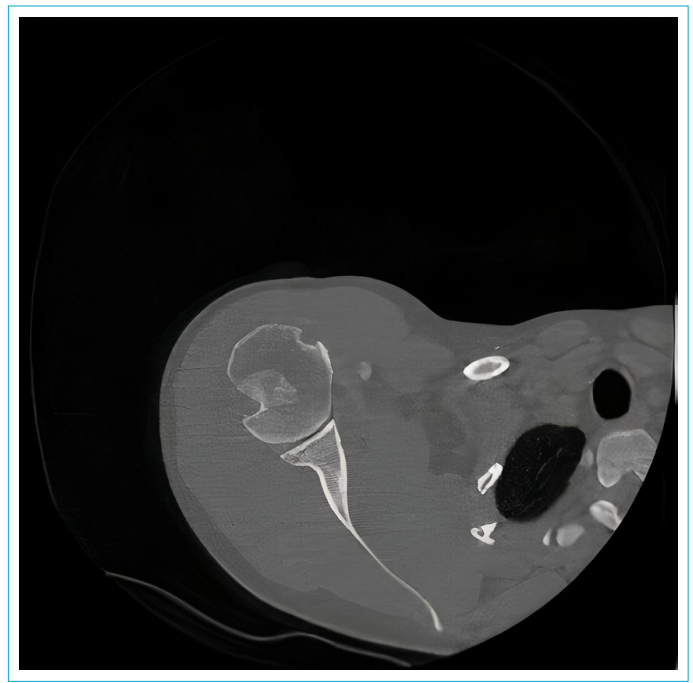


Figure 3. The view of the anatomical relation of both shoulder joints after reduction and Hill-Sachs lesions in the area that fits the postero-lateral of both humeral heads.

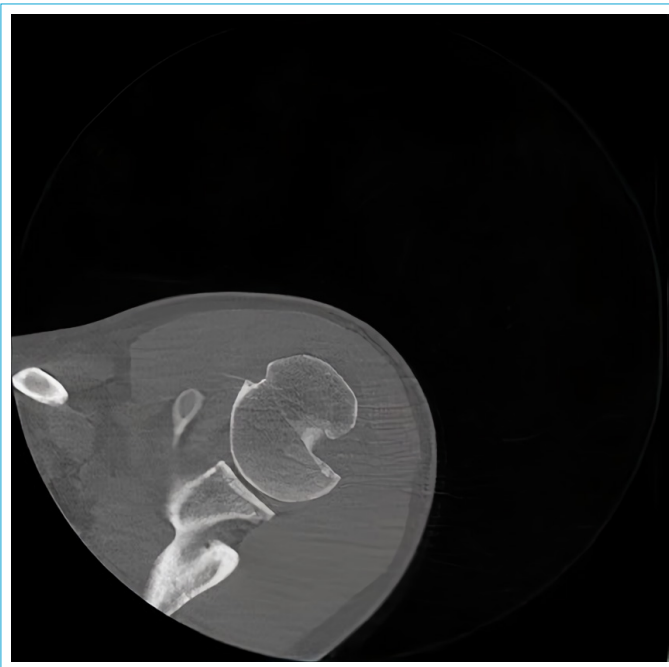


Figure 4. The view of the anatomical relationship of the Hill-Sachs lesion in the posterolateral region of the left humeral head and the shoulder joint after reduction.

The patient was consulted to physical therapy and rehabilitation clinic for rehabilitation of both shoulders. Rehabilitation program was consisted of 20 sessions in which TNS, pulse, USG, stretching and isometric reinforcement exercises, and cold pack therapies were administered to the patient for 2 months. After the rehabilitation program, the patient came to our polyclinic for control in 3rd and 10th months for physical examination, range of motion, and PT&R consultation.

Discussion

Anterior shoulder dislocations are the most common dislocations of the body, usually caused by sports injuries. Contrary to popular belief, nerve lesions are a common complication in these dislocations. Nerve lesions are seen in an average of 45%.^[6,7] In the rare causes of bilateral anterior shoulder dislocations, the reason is sudden and excessive muscle contractions that develop due to epilepsy, electric shock, alcohol withdrawal, and hypoglycemic convulsions. Other causes include weight lifting, diving, and traction injuries. Cresswell reported a case of bilateral anterior shoulder dislocation in an athlete during bench press in 1998 and Esenkaya et al. in 2000 during weight lifting.^[1,8]

In general, shoulder dislocations due to epileptic seizures are posterior glenohumeral dislocations where as our patient was diagnosed with bilateral anterior glenohumeral dislocation.^[5] Although severe contractions of the humeral

head generally cause posterior glenohumeral dislocations.^[9] In a patient with severe contractions due to electric shocks or seizures causes shoulders to adduction, internal rotation, and flexion position.^[10] The reason of this position is weak external rotators of the shoulder that are suppressed by relatively more powerful internal rotators force the glenohumeral joint in adduction and internal rotation which causes the shoulder joint to dislocate posteriorly. That is why anterior dislocations in contradistinction to posterior dislocations are generally seen secondary to trauma related injuries. To anteriorly dislocate the glenohumeral joint, the limb should be forced in a position of external rotation, abduction, and extension where the major tubercle of the humeral head will be pressed on the acromion and by the lever arm effect, humeral head will be forced anterior-inferiorly outside the glenohumeral joint.^[1-4-8-11,12] Bilateral anterior shoulder dislocations subsequent to epileptic seizures are seen rarely in literature and not been enlightened why these dislocations are seen anteriorly. It is possibility that our patient's internal rotation and adduction are prevented by the bed, possibly by returning to the prone position before or during the seizure. In some studies, the mechanism of posterior dislocation development by preventing external rotation and abduction while the patient is lying in the prone position has been described.^[13] Similarly, there is a slight possibility of anterior dislocation by preventing internal rotation and adduction while the patient is in the prone position, and further research is needed.

After anterior dislocations and subluxations of the shoulder, some of the patients who were examined have been seen with immobilization and pain-related ROM decrease. Most of the patients ROM were spontaneously improved although rarely some of patients suffered with decreases of ROM permanently.^[14]

Conclusion

Due to the bilateral displacement of patients shoulders and his age treatment was planned conservatively. For such patients, early PT&R and mobilization are important in terms of patient rehabilitation. The patients decrease in ROM and pain complaints were progressively declined by conservative treatment and early physical therapy and rehabilitation program. In the 11-month follow-up, the patient had no complaints in both shoulders and epileptic seizures were not seen.

Disclosures

Informed consent: Written informed consent was obtained from the patient for the publication of the case report and the accompanying images.

Peer-review: Externally peer-reviewed.

Conflict of Interest: None declared.

Authorship Contributions: Concept – O.T.E.; Design – F.S.; Supervision – O.T.E.; Materials – O.T.E.; Data collection &/or processing – Y.S.; Analysis and/or interpretation – S.R.; Literature search – F.S.; Writing – O.T.E.; Critical review – Y.S.

References

1. Cresswell TR, Smith RB. Bilateral anterior shoulder dislocations in bench pressing: an unusual cause. *Br J Sports Med* 1998;32:71–2.
2. Prillaman HA, Thompson RC Jr. Bilateral posterior fracture-dislocation of the shoulder. A case report. *J Bone Joint Surg Am* 1969;51:1627–30.
3. Page AE, Meinhard BP, Schulz E, Toledano B. Bilateral posterior fracture-dislocation of the shoulders: management by bilateral shoulder hemiarthroplasties. *J Orthop Trauma* 1995;9:526–9.
4. Hartney-Velazco K, Velazco A, Fleming LL. Bilateral anterior dislocation of the shoulder. *South Med J* 1984;77:1340–1.
5. Alkaff H, Alabdulkarim NH, Altwajri N, Alsabti R, Alabdullatif F, Alsanawi H. Causes of bilateral anterior shoulder dislocation: a systematic review. *IJMSCR* 2019;2:199–18.
6. Visser CP, Coene LN, Brand R, Tavy DL. The incidence of nerve injury in anterior dislocation of the shoulder and its influence on functional recovery. A prospective clinical and EMG study. *J Bone Joint Surg Br* 1999;81:679–85.
7. de Laat EA, Visser CP, Coene LN, Pahlplatz PV, Tavy DL. Nerve lesions in primary shoulder dislocations and humeral neck fractures. A prospective clinical and EMG study. *J Bone Joint Surg Br* 1994;76:381–3.
8. Esenkaya I, Tuycun H, Türkmen IM. Bilateral anterior shoulder dislocation in a weight lifter. *Phys Sportsmed* 2000;28:93–100.
9. Mancini GB, Lazzeri S. Bilateral posterior fracture-dislocation of the shoulder. *Orthopedics* 2002;25:433–4.
10. Shaw JL. Bilateral posterior fracture-dislocation of the shoulder and other trauma caused by convulsive seizures. *J Bone Joint Surg Am* 1971;53:1437–40.
11. Fullarton GM, MacEwan CJ. Bilateral posterior dislocation of the shoulder. *Injury* 1985;16:428–9.
12. Segal D, Yablon IG, Lynch JJ, Jones RP. Acute bilateral anterior dislocation of the shoulders. *Clin Orthop Relat Res* 1979:21–2.
13. Whiting WC, Zernicke RF. *Biomechanics of musculoskeletal injury*. 2nd ed. Champaign, IL: Human Kinetics; 2008. p. 350.
14. Harada Y, Iwahori Y, Kajita Y, Saito Y, Takahashi R, Deie M. Secondary frozen shoulder after traumatic anterior shoulder instability. *JSES Int* 2020;4:72–6.