



Case report

Numerous retinal pigment epithelial elevations and drusen associated with unusual dilated choroidal vessels seen at choriocapillaris level in macular area

Akiko Okubo^{a,*}, Kazuhiko Unoki^a, Munefumi Sameshima^b, Taiji Sakamoto^b^a Unoki Eye Clinic, Harara 1-7-15, Kagoshima City, Kagoshima, 890-0026, Japan^b Department of Ophthalmology, Kagoshima University Graduate School of Medical and Dental Sciences, Kagoshima City, Kagoshima, 890-8520, Japan

ARTICLE INFO

Keywords:

Dilated choroidal vessel
 Retinal pigment epithelium elevation
 Posterior ciliary vein
 Choroidal outflow
 Drusen
 Metamorphopsia

ABSTRACT

Purpose: To report the ocular findings in a patient with extensive diffuse elevations of the retinal pigment epithelium (RPE) and drusen associated with dilated choroidal vessels.

Observations: The eye of a 72-year-old woman with numerous drusen and dilated choroidal vessels in the macular and surrounding areas of the right eye was studied. Her visual acuity was 20/16 in this eye and she was asymptomatic although the Amsler grid testing showed mild metamorphopsia. Indocyanine green angiography showed dilated choroidal vessels that collected blood from their branches in the macular and surrounding areas and flowed out of the eye at the entry site of a short posterior ciliary artery. A large choroidal vein ran from the nasal quadrants toward the superotemporal quadrant. Optical coherent tomography (OCT) showed two types of RPE elevations over an extensive area: one was a relatively steep dome-shaped RPE elevation, and the other was a flatter placoid-shaped RPE detachment. Detailed examinations including OCT angiography showed that the dome-shaped RPE elevation coincided with the course of the dilated choroidal vessels which were seen at the level of the choriocapillaris. The visual acuity and the ocular findings remained stable during the 2.5-year follow-up period, and this condition did not require any treatments.

Conclusions and importance: We conclude that the dilated choroidal vessels are most likely parts of the posterior ciliary venous system, and they function as a posterior route of choroidal outflow. Because such eyes might be diagnosed and treated as age-related macular degeneration based on the presence of drusen, RPE detachments, and abnormal vessels beneath the RPE, knowledge of these observations in a functionally normal eye is important to avoid unnecessary treatments.

1. Introduction

A detachment of the retinal pigment epithelium (RPE) in the macular area is a common finding in eyes with age-related macular degeneration (AMD) and central serous chorioretinopathy.¹ When a detachment is found together with drusen, these eyes are usually diagnosed with AMD.^{2,3} We report the findings in a patient who presented with diffuse mild elevations of the RPE including RPE detachments in the extensive macular and surrounding area. This eye had many drusen, and some parts of the RPE elevations coincided with the course of dilated choroidal veins at the level of the choriocapillaris.

The purpose of this study was to examine these unusual findings which were not characteristic of any type of retinochoroidal disorder, and to discuss the origin of the dilated choroidal vessels and the possible cause for their development.

1.1. Case report

A 72-year-old mildly hyperopic Japanese woman underwent a routine visual examination. She did not report any visual symptoms but Amsler grid testing at which revealed that she perceived all of the straight vertical and horizontal grid lines as slightly wavy in the central visual field of her right eye (RE). Medically, she had controlled systemic hypertension. She had never visited an eye clinic but had annual medical examinations from ages 46–60 years. She reported that she was told after an earlier examination that her optic disc cup was enlarged, and the retinal vessels were arteriosclerotic. However, she did not remember whether she was told the changes were unilateral or bilateral.

At presentation, her best-corrected visual acuity was 20/16, and the intraocular pressure was 18 mmHg in both eyes. She had mild cataract, and the anterior segment and vitreous were normal bilaterally.

* Corresponding author.

E-mail address: akiko@m2.kufm.kagoshima-u.ac.jp (A. Okubo).<https://doi.org/10.1016/j.ajoc.2020.100634>

Received 1 April 2019; Received in revised form 27 January 2020; Accepted 24 February 2020

Available online 28 February 2020

2451-9936/© 2020 The Authors. Published by Elsevier Inc. This is an open access article under the CC BY-NC-ND license

<http://creativecommons.org/licenses/by-nc-nd/4.0/>.

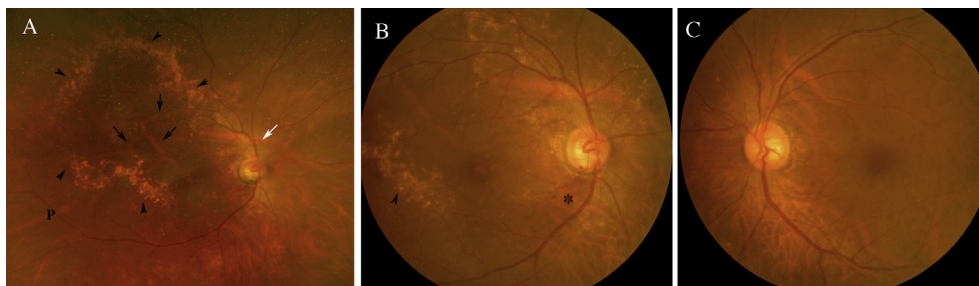


Fig. 1. Color fundus photographs. **A:** Widefield fundus photograph of the right eye showing numerous drusen arranged in an ellipse pattern (arrowheads), dilated choroidal vessels (black arrows) in the macular area, and a larger choroidal vein (white arrow) superior to the optic disc. A reddish-orange lesion is seen (p). **B:** Glaucomatous optic disc excavation with hemorrhage and defects in the inferior arcuate nerve fiber layer (asterisk) can be seen. The drusen are relatively hard in appearance,

varying in size from small to large, and coalesced (arrowhead) in places. **C:** Fundus photograph of the left eye. (For interpretation of the references to colour in this figure legend, the reader is referred to the Web version of this article.)

Ophthalmoscopy showed mild glaucomatous changes of the optic disc, numerous drusen, dilated choroidal vessels in the macular area, and a large choroidal vessel superior to the optic disc in RE (Fig. 1). The drusen varied from small to large in size, coalesced in some places, and arranged in an irregular ellipse-like pattern. A reddish-orange elevated lesion was observed on a choroidal vein near the inferotemporal vascular arcade. These findings were not found in the left eye (LE).

Our first impression was that she had early stage of AMD because of the drusen, even though the fundus appearances of the two eyes were quite different. She underwent imaging examinations including spectral-domain (SD) optical coherence tomography (OCT, Spectralis HRA + OCT, Heidelberg Engineering, Heidelberg, Germany), swept-source (SS) OCT, OCT angiography (OCTA; modified Cirrus prototype with a SS laser, Carl Zeiss Meditec, Dublin, CA), and standard and ultra-widefield indocyanine green angiography (ICGA; Optos California, Dunfermline, UK).

ICGA of RE showed dilated choroidal veins that collected blood through their branches in the macular, superonasal, and inferotemporal areas and converged to flow out at an entry site of a short posterior ciliary artery (Fig. 2). A short vein that ran from the superotemporal area also flowed out at the same site. Ultra-widefield ICGA showed that the large choroidal vein superior to the optic disc collected blood from the nasal quadrants and ran toward the superotemporal quadrant. Several branches from the widest part of this vein appeared to join the dilated choroidal veins. In the superotemporal quadrant, the choroidal venous flow from the posterior region toward the vortex veins at the equator was less distinct than that in the other quadrants. The area covered by these dilated choroidal veins was hypo-fluorescent.

The OCT images (Fig. 3B, D-F) showed diffuse mild RPE elevations in an extensive area that approximately corresponded with the area that was hypo-fluorescence in the ICGA image. Most of the drusen were located around the peripheral borders of the RPE elevations (Fig. 3C) and some were located along the branches of the dilated choroidal veins (Fig. 4B). Discrete drusen corresponded with granular or zonal hyperreflective materials within the RPE/Bruch's membrane complex in the OCT images in the area where the outer retinal hyperreflective bands were visible (Fig. 3F). On the other hand, coalesced drusen corresponded with the relatively thick hyperreflective zonal materials of the most outer retinal layer in the area where the outer retinal layers including the RPE were thin and were not observed as a separate layer. Fundus autofluorescence image did not show any hypofluorescence in the macula, which suggested that the RPE function was maintained in this region. Two types of elevations were detected: one type was a relatively steep dome-shaped RPE elevation (black arrowheads in Fig. 3D and E) that was accompanied by moderate hyperreflective discontinuous material beneath the RPE; Careful examinations of both the ICGA and the OCT images showed that this type of RPE elevation coincided with the course of the dilated choroidal veins, which was also shown by the "RPE elevation map" made by Macula Cube analysis (Fig. 4D). The second type was a less steep placoid-shaped elevation that was accompanied by a hyperreflective line of Bruch's membrane at the expected level, i.e., an RPE detachment. These two types of RPE

elevations were contiguous.

These dilated choroidal vessels were observed in both the OCTA and OCTA *en face* images (Fig. 4A and B) to be at the level of the choriocapillaris slab, while the large choroidal vein running over the supra-optic disc area was observed to be in Haller's layer. B-scan images of the RPE elevation overlying the dilated choroidal veins showed blood flow beneath the RPE. The SS-OCT images showed that the dilated choroidal veins ran within the choroid towards the sclera after they converged (Fig. 4C).

The subfoveal choroidal thickness was 239 μm for RE and 293 μm for LE. The axial length of RE was 22.29 mm and that of LE was 21.90 mm. During the 2.5-year follow-up period, her ocular findings remained the same without any treatments, although very slight changes in the height of the RPE elevations were observed from visit to visit.

2. Discussion

Our examinations showed that an extensive area of the central retina of the right eye consisted of diffuse RPE elevations. Amsler grid testing showed mild metamorphopsia. The inward displacement of the RPE should disturb the normal orientation of the cone photoreceptor cells, but the exact mechanisms of the metamorphopsia was not determined.⁴

Our observations showed that the dilated choroidal veins were most likely the cause of the dome-shaped RPE elevations, because the course of the dilated choroidal veins coincided with the elevations. The question then arises regarding the origin of these veins. The large vessels under the RPE, submacular choroidal varix, has been reported to cause choroidal elevations by Adam et al.⁵ In our case, however, the dilated choroidal veins were not located in the deeper choroid, which is different from their case. The location and arrangement of the dilated choroidal vessels were unusual. They were observed in the choriocapillary layer in spite of being large. Such configuration of the vessels under the RPE might resemble a branched vascular network in polypoidal choroidal vasculopathy (PCV). However, their size was much larger than that of the branched vascular network observed in eyes with PCV. In addition, eyes with PCV have polypoidal vascular lesions at the termination, while in our case, the distal portions of the vessels were tapered. This was because the veins converged and exited the posterior pole. The direction of the blood flow was different from those in the branched vascular networks, which consisted of not only a venous component but also an arterial component.^{6,7}

2.1. Unusual route of dilated choroidal veins

Normally, the choroidal venous drainage occurs through the vortex veins in the equatorial region of the eye.⁸ The unusual route of the dilated choroidal veins suggests that they may play a role in the drainage of the blood from the posterior choroid. However, there is another part of the ciliary venous circulation called the posterior ciliary venous system which runs into the central retinal vein in the optic nerve. The posterior ciliary veins have been reported to be inconsistent in their

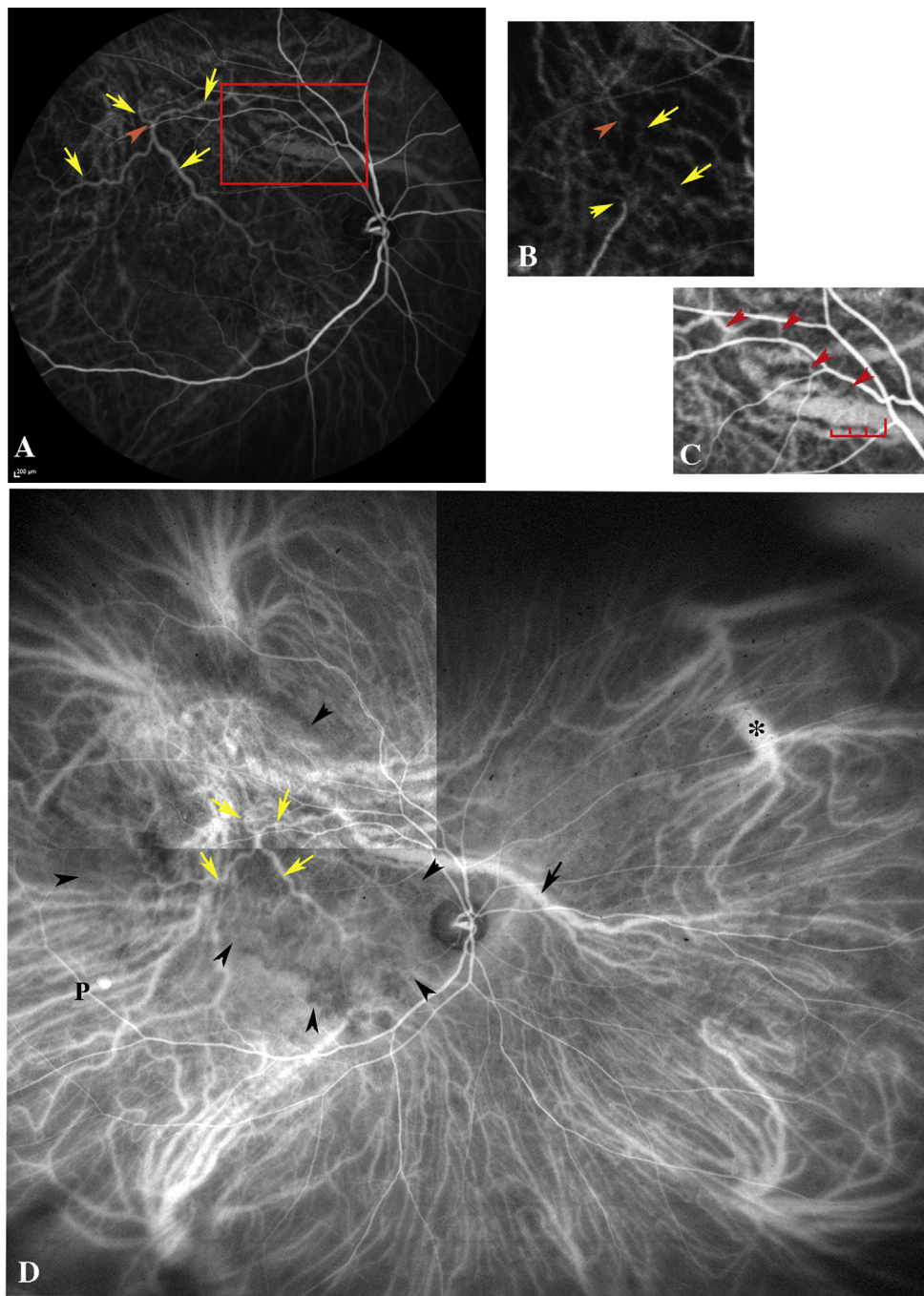


Fig. 2. Indocyanine green angiograms (ICGA) of the right eye. **A:** Choroidal venous phase shows dilated choroidal veins (yellow arrows) and their branches that collected blood from the macular, superonasal, and inferotemporal areas. The vessels flow out (orange arrowhead) at the entry site of the short posterior ciliary artery shown in Fig. 2B (orange arrowhead), together with a very short choroidal vein running from the superotemporal area. Leakage from those vessels is not seen. **B:** Magnified ICGA image at choroidal arterial phase. Arrowheads indicate entry sites of posterior ciliary arteries. A faint silhouette of the dilated choroidal vein (yellow arrows) running from the macular area is seen. **C:** Magnified ICGA image of the enclosed area in Fig. 2A. On the widest part of the large choroidal vein, several twigs (red bracket) that eventually joined the dilated choroidal vein through a branch (red arrowheads) are observed. **D:** Ultra-widefield ICGA shows one vortex vein at the equator in the inferotemporal and inferonasal quadrants and two vortex veins in superotemporal and superonasal quadrants with and without forming an ampulla (asterisk). The large choroidal vein (black arrow) collecting blood in the nasal quadrants runs toward the superotemporal quadrant over the supraoptic disc area. Yellow arrows point to the dilated choroidal veins seen in Fig. 2A. The choroidal venous flow from the posterior part toward the vortex vein in the superotemporal quadrant is less organized than those in the other 3 quadrants. There is a relatively broad area showing hypofluorescence (black arrowheads). A polypoidal structure (p), corresponding to the reddish-orange lesion (“p” in Fig. 1A) is seen along a choroidal vein. (For interpretation of the references to colour in this figure legend, the reader is referred to the Web version of this article.)

occurrence, were fewer in number, and smaller in size.^{9,10} Ohno-Matsui et al. observed that most of the macular vortex veins in eyes with high myopia exited the choroid at the entry site of a short ciliary artery and acted as posterior routes of choroidal outflow.¹¹ The authors concluded that they might develop as dilations of the small posterior ciliary veins to compensate for the enlarged myopic eye. They did not observe RPE elevations but observed a dilation of the macular vortex veins and a delayed perfusion of the choriocapillaris, which they interpreted as venous stasis and decreased choroidal perfusion. These findings suggest the possibility that the dilated choroidal veins seen in our case originated from the posterior ciliary veins even though the eye did not have a long axial length. The anatomical variations of the large choroidal vein that ran for an unusually long distance from the nasal quadrants to the vortex veins in the superotemporal quadrant might develop a posterior drainage route. The possible connection between this large

choroidal vein and the dilated choroidal veins and the less organized choroidal venous course in the superotemporal quadrant suggest this possibility.

2.2. Venous stasis and vessel dilation

It is likely that the increase in the venous pressure due to stasis and weakness of Bruch's membrane might have contributed to the vessel dilation that shifted the overlying RPE anteriorly. The close location of the vein and the artery at the exit and entry sites suggests that venous stasis might have resulted from sclerotic changes of the adjacent artery especially in their scleral portion, which is similar to the relationship between a vein and an artery in retinal venous occlusion.¹² Hara et al. observed a posterior ciliary vein as a branch vessel of vortex vein. It penetrated through the sclera in the same site from which the posterior

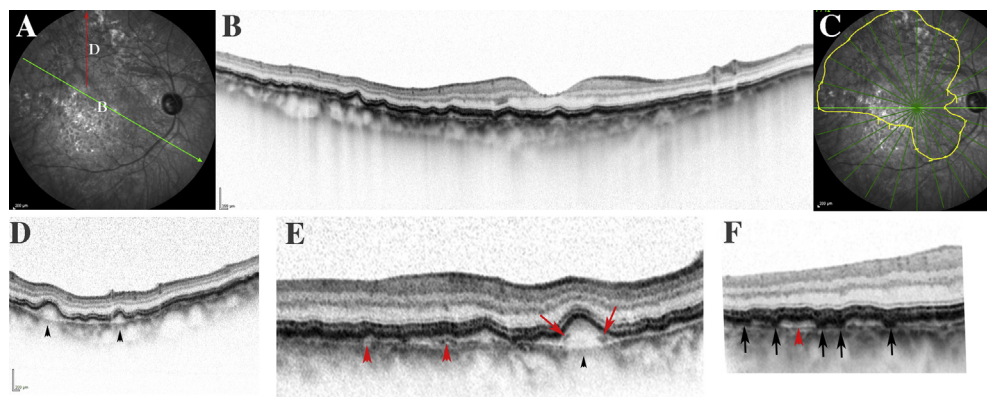


Fig. 3. Spectral domain optical coherence tomographic (SD-OCT) images of the right eye with infrared reflectance image (A, C). **A:** Green arrow and red arrow indicate the scanned location in Fig. 3B and D, respectively. **B:** SD-OCT image centered on the fovea showing mild elevations of the RPE in an extensive area. **C:** The yellow circled area which was obtained from 12 radial scans (green lines) centered on the fovea of the SD-OCT images, indicating the area where the retinal pigment epithelium (RPE) is elevated. Note that this area corresponds approximately with the choroidal hypo-fluorescent area on ICGA (Fig. 2D). **D-F:** Black arrowheads indicate steep dome-

shaped elevations of the RPE overlying the dilated choroidal veins. They are accompanied by discontinuous moderate hyperreflective material (red arrows) beneath the RPE and no Bruch's membrane at the expected level. These RPE elevations are contiguous with placoid-shaped elevations of the RPE (RPE detachments) that are accompanied by hyperreflective line of Bruch's membrane (red arrowheads) at the expected level. Hyperreflective granular materials (black arrows) are seen within the RPE/Bruch's membrane complex, corresponding with the discrete drusen. (For interpretation of the references to colour in this figure legend, the reader is referred to the Web version of this article.)

iliary artery penetrated into the eye.¹³ Apart from the physical relationship with the artery, the vein must have been overloaded to drain the choroidal blood from such an extensive area, if it had remained its original size. Continuous venous stasis might lead to a damage of Bruch's membrane, dysfunction and loss of the choriocapillaries and the RPE. Additional longitudinal studies are needed to answer this question.

2.3. Unusual location of dilated choroidal veins

There are several possibilities for the unusual location of the dilated choroidal veins. One possibility is that they might have developed in the choriocapillary layer congenitally. Another possibility is that they might have developed by an enlargement of pre-existing choriocapillaries or post-capillary venules.^{9,11} Alternatively, the thinning or loss of the choriocapillary layer following some pathologic condition

might have shifted the choroidal vessels in Sattler's layer internally.

2.4. Relationship of drusen and dilated choroidal veins

The spatial relationship of the drusen to the dilated choroidal veins suggests a possible relationship between drusen formation and the vessels. Some drusen have been reported to cluster about the collecting venules of the vortex system and the capillaries associated with them, suggesting a relationship between their formation and the plasma-derived constituents.^{14,15} The ellipse-like distribution of the drusen resembles a 'ring' or 'circinate' patterns of hard exudates around leaking vessels in retinal vascular diseases.¹ For this type of drusen, plasma-derived constituents from hyperpermeable vasculatures might also contribute to their formation. A continuous accumulation of them may cause a hydrophobic barrier in Bruch's membrane and lead to the RPE detachments² that we observed as the second type of RPE elevation.

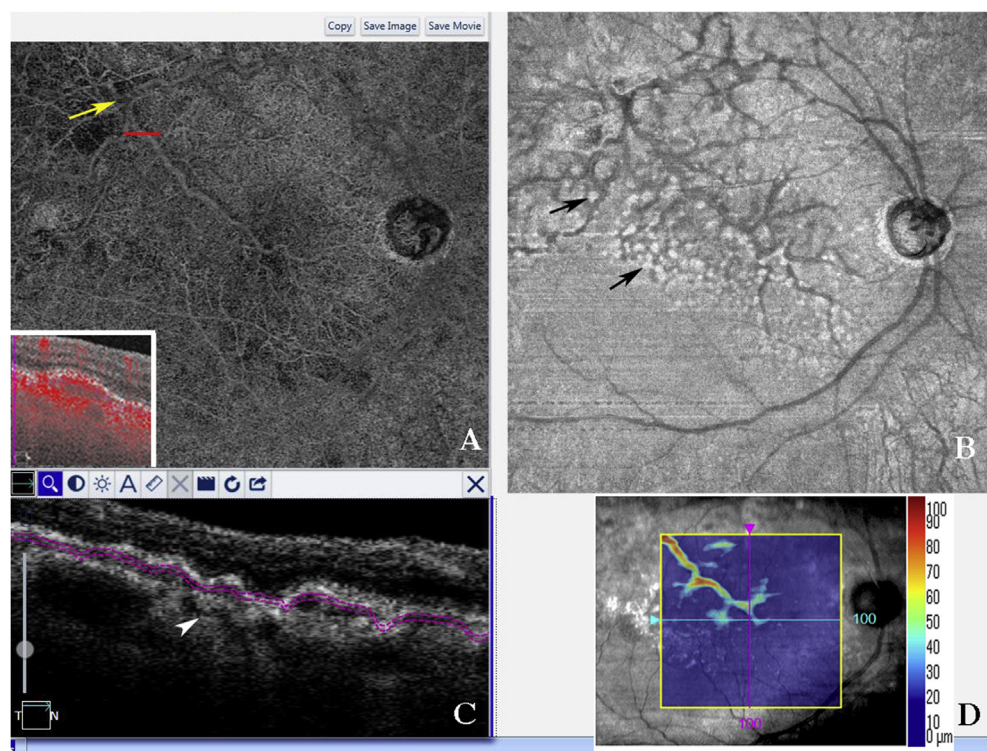


Fig. 4. OCT angiography and *en face* image with swept-source (SS) OCT images and RPE elevation map. **A, B:** OCT angiography (A) and *en face* image (B) centered on the fovea (12 × 12 mm) of the choriocapillaris slab. A portion of the dilated choroidal vessels can be seen. Inset, B-scan targeting of the RPE elevation indicated by red line showing blood flow (red dots) beneath the RPE. The *en face* image (B) shows some drusen (black arrows) along the branches of the dilated choroidal veins. The yellow arrow is described below. **C:** SS-OCT image scanned horizontally around the exit site (yellow arrow in Fig. 4A), showing the course (yellow arrowheads) of the dilated choroidal vein within the choroid after they converged as running nasally and then turning towards the sclera. The sclera is not observed because of the relatively thick choroid. Double pink lines indicate the upper offset 29 μm and lower offset 49 μm from the RPE reference which are based on the choriocapillaris slab. **D:** The RPE elevation map made by Macula Cube analysis, showing that the RPE elevations correspond to the course of the trunk of the dilated choroidal veins in the macular area. (For interpretation of the references to colour in this figure legend, the reader is referred to the Web version of this article.)

There are several limitations in this study. First, we could not observe the route of the dilated choroidal veins in the sclera in the SS-OCT images because the choroid is not thin as in myopic eyes. Second, it was not determined whether the dilated choroidal veins and drusen were present when the patient was younger which may have helped to decide whether the conditions is congenital, acquired, or due to aging. Third, this is a single case report and the frequency of its occurrence is not known.

Nevertheless, the information presented is important because there is the possibility that such eyes might be diagnosed and treated as AMD. If the dilated choroidal veins are treated as neovascular AMD, posterior routes of choroidal blood outflow might be interrupted.

3. Conclusions

Collecting and studying additional cases with similar ocular findings would be helpful to determine its pathogenesis, prognosis, and management.

Patient consent

The patient provided written informed consent for publication of this case report and any accompanying images.

Funding

No funding or grant support.

Declaration of competing interestCOI

All authors have no financial disclosures.

Authorship

All authors attest that they meet the current ICMJE criteria for Authorship.

Acknowledgements

None.

References

1. Gass JDM. fourth ed. *Stereoscopic Atlas of Macular Diseases*. vols. 49–105. St. Louis: Mosby-Year Book, Inc; 1997:472–569.
2. Casswell AG, Kohlen D, Bird AC. Retinal pigment epithelial detachments in the elderly: classification and outcome. *Br J Ophthalmol*. 1985;69(6):397–403.
3. Bird AC, Bressler NM, Bressler SB, et al. An international classification and grading system for age-related maculopathy and age-related macular degeneration. The international ARM epidemiological study group. *Surv Ophthalmol*. 1985;39(5):367–374.
4. Ichikawa Y, Imamura Y, Ishida M. Inner nuclear layer thickness, a biomarker of metamorphopsia in epiretinal membrane, correlates with tangential retinal displacement. *Am J Ophthalmol*. 2018;193(1):20–27.
5. Adam CR, Sigler EJ, Randolph JC, Calzada JI. Submacular choroidal varix simulating chorioretinal folds with metamorphopsia. *Ophthalmic Surg Lasers Imag Retina*. 2013;44(6):596–598.
6. Yuzawa M, Mori R, Kawamura A. The origin of polypoidal choroidal vasculopathy. *Br J Ophthalmol*. 2005;89(5):602–607.
7. Okubo A, Ito M, Sameshima M, Uemura A, Sakamoto T. Pulsatile blood flow in the polypoidal choroidal vasculopathy. *Ophthalmology*. 2005;112(8):1436–1441.
8. Hogan MJ, Alvarado JA, Weddell JE. *Histology of the Human Eye. An Atlas and Textbook*. first ed. Philadelphia, PA: W.B.Saunders Company; 1971:320–392.
9. Coats G. On the pathology of choriovaginal (posterior vortex) veins. *Ophthalm Rev*. 1903;25:99–113.
10. Duke-Elder S. *System of Ophthalmology*. vol. 2. London: Henry Kimpton; 1974:353–359.
11. Ohno-Matsui K, Morishima N, Yamashita S, Ito M, Tokoro T, Nakagawa T. Relationship between macular vortex veins and posterior ciliary veins in high myopia. *Jpn J Clin Ophthalmol*. 1996;50(12):1787–1793 (Abstract in English).
12. Frangieh GT, Green WR, Barraquer-Somers E, Finkelstein D. Histopathologic study of nine branch retinal vein occlusions. *Arch Ophthalmol*. 1982;100(7):1132–1140.
13. Hara A, Shimizu Y. Posterior ciliary veins. *Ganka*. 1985;27(2):173–175 (Abstract in English).
14. Friedman E, Smith TR, Kuwabara T. Senile choroidal vascular patterns and drusen. *Arch Ophthalmol*. 1963;69(2):220–230.
15. Lengyel I, Tufail A, Hosaini HA, Luthert P, Bird AC, Jeffery G. Association of drusen deposition with choroidal intercapillary pillars in the aging human eye. *Invest Ophthalmol Vis Sci*. 2004;45(9):2886–2892.