

## Clinical Features and Outcomes of Strabismus Treatment in Third Cranial Nerve Palsy during a 10-Year Period

Abbas Bagheri, MD; Morteza Borhani, MD; Mehdi Tavakoli, MD; Shahram Salehirad, MD

Ophthalmic Research Center, Shahid Beheshti University of Medical Sciences, Tehran, Iran

### Abstract

**Purpose:** To evaluate the demographics and management outcomes of strabismus surgery in patients with third cranial nerve palsy.

**Methods:** This retrospective study includes subjects with third cranial nerve palsy. We evaluated age, sex, laterality, severity of involvement, etiology, frequency of clinical findings, and types and results of treatments.

**Results:** 52 patients including 29 male and 23 female subjects with mean age of  $21.1 \pm 15.5$  years were studied between January 1999 and January 2009. Etiologies of third nerve palsy included congenital in 16 (30.8%), trauma in 26 (50%) and other causes in 10 (19.2%) patients. In 24 patients (46.2%), the palsy was complete. The most common type of strabismus was exotropia associated with hypotropia (40%). Medical treatment was used in 25 (48%) and surgical treatment in 46 (88.4%) subjects. One time strabismus surgery was performed in 30 (65.2%), 2 times in 11 (24%) and 3 times in 5 (10.8%) subjects. The most common operation was large horizontal recession and resection in 78.2% of cases. Mean horizontal deviation in primary position was  $66 \pm 29$  prism diopters (PD) before surgery decreasing to  $21 \pm 19$ ,  $13 \pm 12$  and  $6 \pm 8$  PD after first, second and third surgery, respectively. Corresponding figures for mean vertical deviation were  $13 \pm 15$ ,  $7 \pm 12$ ,  $4 \pm 6$  and  $1 \pm 2$  PD, respectively. Abnormal head posture was  $10-30^\circ$  in 11 (21.1%) cases before treatment which completely resolved after surgery.

**Conclusion:** Surgical management of strabismus in patients with third nerve palsy is difficult and challenging, however the majority of patients achieve ideal results with appropriate and stepwise surgical plans.

**Keywords:** Exotropia; Hypotropia; Strabismus Surgery; Third Nerve Palsy

*J Ophthalmic Vis Res* 2014; 9 (3): 343-349.

### INTRODUCTION

Paralytic strabismus due to extraocular muscle palsy is a common cause of strabismus which may be a self-limited disorder or the sequel of a more widespread disease. Paralytic strabismus poses a significant diagnostic and therapeutic challenge.<sup>[1]</sup>

The prevalence of paralytic strabismus is variable in different studies. At neurosurgery centers,<sup>[2]</sup> the most common ophthalmic motor palsy is sixth nerve palsy whereas at ophthalmic centers,<sup>[3]</sup> fourth nerve palsy is the most common type. Rucker<sup>[4,5]</sup> and Rush and Young<sup>[6]</sup> have reported third cranial nerve palsy as the second most prevalent ocular motor palsy following sixth cranial nerve palsy.

Treatment of the third nerve palsy is challenging for ophthalmologists. Management strategies differ from simple observation to complex surgeries such as muscle transposition for treatment of strabismus and different surgical procedures for treatment of ptosis.<sup>[7,8]</sup>

Although oculomotor nerve palsy is uncommon, it is associated with significant morbidity. Generally, patients present with blepharoptosis, limitation in eye movements accompanied by strabismus and a dilated pupil reacting to light.<sup>[9]</sup>

Most reports have stated ischemia as the most common cause of the oculomotor nerve paralysis.<sup>[4,5]</sup>

#### Correspondence to:

Abbas Bagheri, MD. Department of Ophthalmology, Labbafinejad Medical Center, Boostan 9 St., Pasdaran Ave., Tehran 16666, Iran.  
E-mail: abbasbagheri@yahoo.com

Received: 23-05-2013

Accepted: 17-02-2014

#### Access this article online

Quick Response Code:



Website:

[www.jovr.org](http://www.jovr.org)

DOI:

10.4103/2008-322X.143375

Although the majority of patients with ischemic oculomotor nerve palsy suffer from diabetes mellitus, other disorders such as hypertension, atherosclerosis and migraine may manifest similarly.<sup>[2]</sup> In a study conducted at our center,<sup>[10]</sup> trauma was reported as the most common reason of oculomotor nerve paralysis. Rucker reported aneurysms and neoplasms, and Rush and Younge reported trauma as the second main cause of oculomotor nerve palsy.<sup>[4-6]</sup>

After diagnosing the cause, nonsurgical approaches such as patching, prism prescription and botulinum toxin injection are used in the acute phase to treat horizontal misalignment.<sup>[11]</sup> After at least 6 months, surgical treatment is considered by most surgeons.<sup>[11]</sup> The treatment goals are adequate alignment for binocular function, and correction of ptosis and head position.

This study was performed to determine epidemiologic and etiologic distribution and results of strabismus surgery in patients with third nerve palsy referred to our clinic as a tertiary center over a 10-year period.

## METHODS

This retrospective study was performed on hospital records of 52 consecutive patients (53 eyes) with third nerve palsy who were referred to Labbafinejad Medical Center, Shahid Beheshti University of Medical Sciences from January 1999 to January 2009.

Medical records of patients treated at our center were reviewed to identify cases with third cranial nerve palsy. The patients' sex and age at the onset of palsy and age at presentation, the length of follow-up, and the etiology of palsy were recorded, as well as whether the palsy was complete or partial and whether clinical signs of aberrant regeneration were present. The palsy was complete if no adduction or vertical action of the superior or inferior rectus or the inferior oblique was recorded, the pupil was dilated and unresponsive to light, and ptosis was present. A partial palsy was characterized by limited adduction and vertical movements of the globe on ductions, a normal or dilated but responsive pupil, and a normal or ptotic eyelid. In each case, best-corrected visual acuity (BCVA) at presentation and subsequent visits, the methods used to assess visual acuity (according to patient age and level of cooperation) and the presence or absence of amblyopia, were recorded.

The degree of ocular misalignment was assessed in very young or nonresponsive patients by using the Krimsky light reflex test. In older, cooperative patients, horizontal and vertical ocular alignments were measured at 6 m and at 1/3 m using the alternate prism and cover test with best optical correction in place.

We divided the outcomes of strabismus surgery<sup>[12]</sup> to:

1. Acceptable (including orthophoria and microtropia): Deviation  $\leq 8\Delta$
2. Small angle strabismus or cosmetically acceptable:  $8\Delta < \text{Deviation} \leq 20\Delta$
3. Large angle strabismus or cosmetically unacceptable: Deviation  $> 20\Delta$ .



We performed neuroimaging for all patients. Acquired traumatic cases who had orbital fracture or intraorbital foreign bodies were excluded from the study. Acquired non traumatic patients who had no pupillary involvement or neuroimaging abnormality were investigated for myasthenia gravis.

Patients with new onset palsy (<6 months) underwent conservative treatment such as prism prescription, adductive exercises, patching and botulinum toxin-A injection in order to treat diplopia or head tilt. Six months after stabilizing the deviation, surgery was considered if deviation was cosmetically or functionally unacceptable. All deviomeric data gathered 6 months after surgery were analyzed in this study to investigate final results.

## RESULTS

This study included 52 patients consisting of 29 (55.8%) male and 23 (44.2%) female subjects with mean age of  $21.1 \pm 15.5$  years (range, 1 month to 60 years) [Figure 1]. Mean follow-up time was  $27.3 \pm 10$  months (range, 6 months to 10 years). The right eye was involved in 25 (48.1%) subjects, the left eye in 26 (50%) patients and both eyes in 1 (1.9%) individual.

Chief complaints included squint in 51 (98.1%), ptosis in 39 (75%), diplopia in 5 (9.7%) and abnormal head posture in 2 (3.8%) of cases.

Etiologies were congenital in 16 (30.8%), trauma in 26 (50%), tumors in 2 (3.8%), ischemia in 2 (3.8%), viral meningitis in 1 (1.9%) and unknown causes in 5 (9.6%). We did not have any case of multiple sclerosis or myasthenia gravis in this series [Table 1]. The third nerve palsy was isolated in 38 (73.2%) of cases and nonisolated in 14 (26.8%) [Table 2]. Oculomotor palsy was complete in 24 (46.2%) and incomplete in 28 (53.8%) cases including 4 (7.7%) patients with isolated inferior

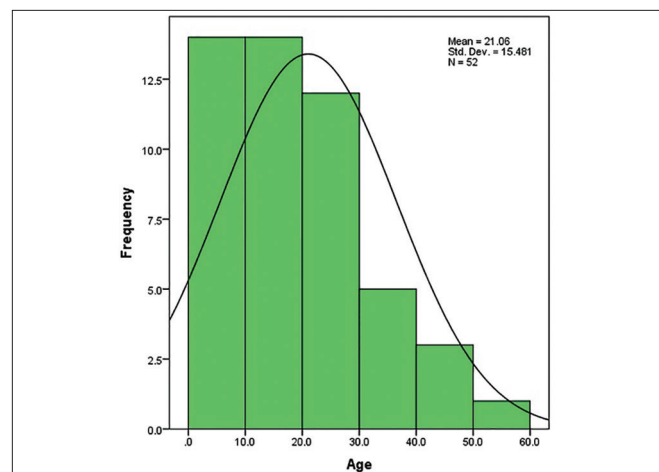


Figure 1. Age distribution of patients with third nerve palsy.

division involvement; one (1.9%) with isolated superior division involvement; one (1.9%) with isolated medial rectus branch involvement and one (1.9%) with isolated inferior oblique branch involvement.

Of 53 eyes with third nerve palsy, BCVA was 20/20 or better in 10 (18.8%) eyes and worse than 20/20 in 43 (81.2%) eyes (including the bilateral case) that was attributed to amblyopia, optic atrophy, media abnormalities, and retinal problems. Amblyopia was seen in 24 (46.2%) subjects secondary to deprivation due to ptosis and strabismus itself. In 2 (3.8%) subjects, vision was no light perception due to traumatic optic neuropathy.

Abnormal head posture was 10-30° in 11 (21.1%) patients of whom 4 (7.7%) had head tilt, 8 (15.7%) had face turn and 2 (3.9%) showed chin up position. Some cases had mixed type abnormal head posture.

Aberrant regeneration was reported in 6 (11.5%) cases. Pupillary involvement was seen in 29 (55.8%) patients and 23 (44.2%) cases had normal pupillary size. Ptosis was reported in 45 (86.5%) subjects of which 18 (40%) had complete ptosis, and 2 (4.4%) patients had associated jaw winking. Ptosis was mild in 5 (9.6%), moderate in 11 (21.2%), and severe in 29 (55.8%) subjects [Table 3]. Levator function was good in 21 (40.3%), fair in 7 (13.5%), weak in 24 (46.2%) cases. Limitation in eye movement ranged from nil to severe [Table 4].

Two (3.8%) subjects received only medical treatment. 26 (50%) patients received only surgical treatment and both medical and surgical treatments were done in 20 (38.4%) cases. Out of 4 (7.7%) patients who did not receive any treatment, one had complete spontaneous resolution, one was lost to follow-up, one underwent brain tumor resection and was not planned for the operation and in one subject surgery was cancelled due to medical issues [Table 5].

Medical treatment was considered in 22 (42.3%) of cases as described.

Botulinum toxin injection in the lateral rectus (LR) was performed in 4 (7.7%) patients with excellent result in one case. Three other cases received injections after surgery through which one patient gained good result after one injection and in one other subject, three injections were done, two consecutive injections after the first surgery and one injection after the second surgery with an excellent result. However, in the third patient, deviation did not show an ideal response after injection and the patient did not come for follow-up.

After surgery, complementary treatments were performed including prism prescription in 2 (3.8%), antismpression eye patching in 16 (30.8%), and adductive exercise in 14 (27%) subjects.

Strabismus surgery was performed in 46 (88.5%) patients. One-step, two-step, and three-step operations were performed in 30 (65.2%), 11 (24%), 5 (10.8%) patients, respectively. Diplopia in primary position

**Table 1. Etiologic distribution of third nerve palsy**

	Number	Percentage
Congenital	16	30.8
Acquired	36	69.2
Trauma	26	50
Ischemia	2	3.8
Tumors	2	3.8
Viral meningitis	1	1.9
Unknown	5	9.6
Total	52	100

**Table 2. Neurologic disorders associated with third nerve palsy**

	Number	Percentage
Isolated	38	73.2
Non isolated	14	26.8
Accompanying paresis	-	-
4 <sup>th</sup> nerve palsy	4	7.7
6 <sup>th</sup> nerve palsy	4	7.7
7 <sup>th</sup> nerve palsy	1	1.9
4 <sup>th</sup> and 6 <sup>th</sup> nerve palsy	1	1.9
6 <sup>th</sup> and 7 <sup>th</sup> nerve palsy	1	1.9
Dorsal midbrain syndrome	1	1.9
Brown syndrome	1	1.9
Benedikt syndrome	1	1.9
Total	52	100

**Table 3. Severity distribution of eyelid ptosis**

Eye lid	Frequency	Percentage
Ptosis	45	86.5
Mild	5	9.6
Moderate	11	21.2
Severe	29	55.8
No ptosis	7	13.4
Total	52	100

improved in all cases after the last surgery. In 27 (58.5%) patients, surgery was performed on >2 muscles in the first procedure and in 4 (8.5%) subjects, bilateral surgery was done.

Horizontal deviation in primary position was exotropia in 49 (94.3%) and esotropia in one (1.9%) subjects. No horizontal deviation was seen in 2 (3.8%) patients.

Vertical deviation was hypotropia in 21 (40.4%) and hypertropia in 10 (19.2%) subject; 21 (40.4%) cases had no vertical deviation.

Mean horizontal deviation was 66±29 (range, 0-100) PD and was 45±0.0 PD in the esotropic subgroup and 69±27.5 (range, 25-100) PD in the exotropic subgroup. Mean horizontal deviation decreased after first, second, and third surgery to 21±19, 13±12, 6±8 PD, respectively.

Mean vertical deviation was 13 ±15 (range, 0-70) PD before surgery which was 25.4±20.3 (range, 6-70) PD in

**Table 4. Limitation of gaze in primary position at presentation**

Severity of limitation (%)	Number (%)
<b>Elevation</b>	
0	4 (7.7)
25	0 (0.0)
50	6 (11.5)
75	13 (25)
100	29 (55.8)
<b>Depression</b>	
0	9 (17.3)
25	4 (7.7)
50	8 (15.4)
75	10 (19.2)
100	21 (40.4)
<b>Adduction</b>	
0	3 (5.8)
25	4 (7.7)
50	10 (19.2)
75	11 (21.2)
100	24 (46.2)
<b>Abduction</b>	
0	36 (69.2)
25	5 (9.6)
50	6 (11.5)
75	3 (5.8)
100	2 (3.8)

**Table 5. Medical and surgical treatment results for third nerve palsy**

No treatment	4 (7.7%)	
Medical treatment	2 (3.8%)	
Medical and surgical treatment	20 (38.4%)	One step surgery: 30 Two step surgery: 11
Surgical treatment	26 (50%)	Three step surgery: 5

**Table 6. Pretreatment ocular alignment in patents with third nerve palsy**

Primary deviation	n	Mean	SD	Median	Minimum	Maximum
<b>Horizontal</b>						
Total	52	66	29	70	0	100
ET	1	45.0	0	45	45	45
XT	49	69.0	27.5	70	25	100
Ortho	2	-	-	-	-	-
<b>Vertical</b>						
Total	52	13.0	15.0	10	0	70
Hyper	10	25.4	20.3	20	6	70
Hypo	21	19.2	10.1	15	8	45
Ortho	21	-	-	-	-	-

SD, standard deviation; ET, esotropia; XT, exotropia; Ortho, orthotropia; hyper, hypertropia; Hypo, hypotropia

the hypertropic subgroup and 19.2±10.1 (range, 8-45) PD in the hypotropic subgroup. Mean vertical deviation decreased after first, second and third surgery to 7±12, 4±6, 1±2 PD, respectively [Tables 6 and 7].

Results of first surgery were acceptable in 28.3%, small residual angle in 34.8% and large residual angle in 37%; corresponding figures after second surgery reached 41.3%, 43.5%, 15.2% and following third surgery reached 45.7%, 43.5%, 10.9%, respectively [Table 8]. Horizontal deviation significantly improved with the first ( $P < 0.001$ ) and second ( $P = 0.006$ ) operation, but change after third surgery was not statistically significant ( $P = 0.10$ , based on Wilcoxon test).

For first surgery, the most common procedure was horizontal recess and resect (R and R) which was performed in 36 (78.2%) out of 46 cases; this procedure was combined with horizontal muscle displacement in 12 (33%) cases. Transposition was performed in 17 (36.9%) out of 46 subjects. The most common transposition procedure was superior oblique (SO) muscle transposition toward medial rectus (MR) insertion. Other procedures included modified Knapp, medial Jensen and Hummelsheim. In 7 (15.2%) of 46 cases, lateral rectus (LR) disinsertion was performed.

The most common procedure for second and third surgery was LR disinsertion that was performed on 9 (81.8%) patients in second operation and 2 (40%) cases in third surgery. No transposition was done during second and third surgery. Mean horizontal deviation was 81.5±27.5 PD in the transposition subgroup which decreased to 31.5±18 PD after first surgery. In patients without transposition, mean horizontal deviation was 58±26 PD before surgery and decreased to 16±17 PD after first surgery. Surgical results in patients without transposition, were not significantly different from patients with transposition ( $P > 0.05$ , based on *t*-test).

Two patients with complete palsy underwent ocular sling with fascia lata, mean horizontal deviation which was 80±26 PD in these 2 cases was decreased to 10±16 PD after surgery.

Postoperative complications included undercorrection (cosmetically unacceptable results) in 17 (37%), overcorrection in 2 (4.3%) subjects and mild anterior ischemic syndrome in one (2.1%) case. This patient underwent three recti muscle surgery including displacement and myotomy. Diplopia after surgery was also reported in 2 (4.3%) subjects but improved with adductive exercise and segmental occlusion.

## DISCUSSION

Acquired third nerve palsy represents approximately 30% of ocular motor nerve palsies being less common than sixth nerve palsy and more common than fourth nerve palsy.<sup>[5,6]</sup>

Medghalchi et al<sup>[12]</sup> have reported that congenital third nerve palsy accounts for 20% of all cases of third nerve

**Table 7. Ocular alignment before and after treatment**

Primary deviation	n	Mean	SD	Median	Minimum	Maximum
Preop horizontal deviation	46	66	29	70	0	100
Postop horizontal deviation						
1	46	21	19	20	0	70
2	16	13	12	14	0	35
3	5	6	8	0	0	16
Preop vertical deviation	46	13	15	10	0	70
Postop vertical deviation						
1	46	7	12	0	0	50
2	16	4	6	0	0	20
3	5	1	2	0	0	5

SD, standard deviation

**Table 8. Strabismus surgery results**

Deviation	Time	Acceptable		Small angle residual		Large angle residual	
		Number	%	Number	%	Number	%
Horizontal	Postoperative day 1	14	30.4	15	32.6	17	37.0
	Postoperative day 2	20	43.5	19	41.3	7	15.2
	Postoperative day 3	22	47.8	19	41.3	5	10.9
Vertical	Postoperative day 1	31	67.4	11	23.9	4	8.7
	Postoperative day 2	34	73.9	11	23.9	1	2.2
	Postoperative day 3	36	78.3	9	19.6	1	2.2
Total	Postoperative day 1	13	28.3	16	34.8	17	37.0
	Postoperative day 2	19	41.3	20	43.5	7	15.2
	Postoperative day 3	21	45.7	20	43.5	5	10.9

palsy. In another study at our center congenital causes of third nerve palsy accounted for 31.6% of causes.<sup>[10]</sup>

In large retrospective series on third nerve palsies with defined causes, microvascular ischemia was among the most common etiologies representing 17-35% of causes.<sup>[4-6]</sup> However, aneurysmal and a neoplastic causes were nearly equal (up to 19%), and a large percentage of patients in each series had an undetermined etiology.<sup>[13,14]</sup> In the current study, trauma was the most common etiology of third nerve palsy (50%) followed by congenital causes (30.8%). The great portion of traumatic causes could be due to conducting our survey at a tertiary eye center to which a large number of vascular causes with spontaneous resolution may not be referred. Congenital third nerve palsy account for a sizable portion of patients in all reported series of childhood ocular motor nerve palsies.<sup>[2,4-6]</sup> In a study on 30 children with isolated oculomotor nerve palsy, Miller et al found the diagnoses of third nerve cranial palsy to be congenital (43%), trauma (20%), infection (13%), aneurysm (7%) and ophthalmoplegic migraine (7%).<sup>[2]</sup>

Other studies reported trauma, neoplasm, vascular causes and aneurysm as the main etiologies of oculomotor palsy.<sup>[5,6,16]</sup>

In the current study, about one-third of cases had congenital and two-third had acquired palsy of which

about 72% were traumatic. More than 80% of the patients were younger than 30 years at the time of presentation and this may account for the higher percentage of traumatic causes. Moreover, traumatic third nerve palsy is less probable than vascular causes to follow spontaneous resolution and this may also contribute to more frequent cases of traumatic third nerve palsy at tertiary care units. The high percentage of congenital cause in our study, as compared to other studies, may be due to the fact that in our country considerable number of patients with congenital ptosis are referred for surgery in adulthood.

In our study, partial palsy was seen in 53.8% of patients with more favorable outcomes. In another study at our center, we had observed more ideal treatment results in parietic patients in all types of paralytic strabismus.<sup>[15]</sup> In the present study, 9.6% of patients with third nerve palsy had undetermined cause which is comparable with Rush and Young<sup>[6]</sup> and Park et al<sup>[16]</sup> results (14% and 10.5%, respectively) but less than Rucker<sup>[5]</sup> results (26%). This difference can be attributed to widespread use of neuroimaging since 1980 with invaluable diagnostic yield.

In another study<sup>[17]</sup> conducted on 28 cases with third nerve palsy, 67.8% of patients had incomplete palsy, and ptosis and pupillary involvement were seen in 78.6% and 42.9% of subjects. However, in our study the higher percentage of ptosis (86.6%) and pupillary involvement

(57.5%) can be attributed to greater percentage of traumatic causes leading to more cases of complete palsy.

In the current study, eye deviation was the most common presenting symptom followed by ptosis. Pupillary involvement was seen in 55.8% of which 78% were traumatic.

The most common form of strabismus was isolated exotropia, followed by combined exotropia and hypotropia. Isolated vertical deviation was seen in 3.8% of cases which was due to superior division and inferior oblique involvement.

The most common initial surgery was R and R that was combined with displacement in one-third of patients to correct vertical deviation. Transposition was done in patients who had completely impaired force generation test. Most patients who had undergone transposition had complete palsy.

The most common second and third procedure was LR disinsertion. Transposition had not been performed in any patient as second or third procedure.

In the current study, we had good surgical results in 2 patients with complete third nerve palsy using fascia lata for anchoring the globe to the nasal periosteum.

Köse et al<sup>[18]</sup> have reported surgical results in 6 patients with complete third nerve palsy that had undergone hemi hangback R and R. Depending on the magnitude of vertical deviation horizontal rectus supraplacement or inferior rectus recession was performed. Mean horizontal and vertical deviation decreased from (66.6 PD and 16 PD) to (11.6 PD and 6.6 PD).

Yonghong et al<sup>[19]</sup> reported surgical results in 13 cases with third nerve palsy; 5 patients with complete palsy underwent SO transposition or globe fixation to the anterior lacrimal crest combined with large LR recession. Eight patients with partial palsy underwent large R and R or combined MR recession and transposition. Ocular alignment was achieved in these patients with some residual exotropia.

In a study by Merino et al<sup>[20]</sup> on 11 patients with third nerve palsy, large horizontal R and R was performed

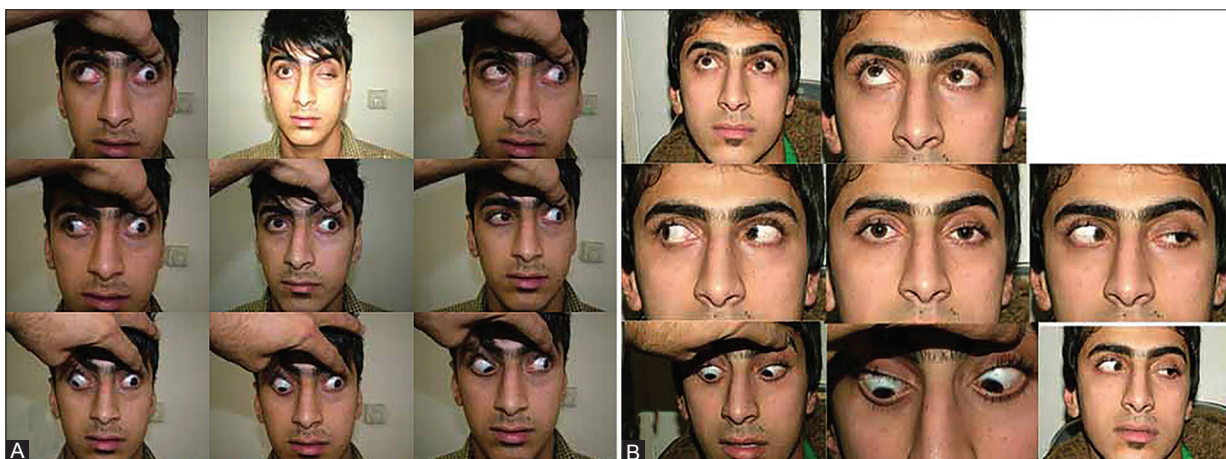
combined with Botulinum toxin injection in some of them; 3 out of 11 patients underwent >1 (up to 4) surgery and nine cases had moderate and good cosmesis.

In Flanders et al study<sup>[21]</sup> out of 12 patients with partial third nerve palsy who underwent horizontal R and R and vertical rectus recession combined with muscle transposition based on the type of deviation, seven cases had complete success.

Schumacher-Feero et al<sup>[8]</sup> conducted a survey on 52 eyes of 49 children through which the patients underwent horizontal R and R and modified Knapp procedure for horizontal deviation, and SO or vertical rectus muscle surgery for vertical deviation based on type of strabismus. Finally, 61% and 71% of subjects had good horizontal and vertical alignment, respectively.

In our study, first surgery had most corrective effect and this effect decreased in subsequent operations. About one-third of our patients after one surgery achieve acceptable surgical results. Sizable number of patients needed more than one procedure. Approximately 90% of patients gained cosmetically acceptable results after three surgeries. The most common surgical complication was under correction. Anterior segment ischemia was uncommon (2.1%) in our patients undergoing three or four muscle surgery; thus may be due to younger age in our study.

In conclusion, in most of patients with third nerve palsy who underwent surgical treatment in the present study, the main etiology was trauma followed by congenital causes. Severe ptosis, pupillary involvement, and complex strabismus are common in patients with history of trauma. A sizable portion of patients needed more than one surgery. Ptosis correction is difficult and a large number of patients require multistep surgeries. Although surgical treatment of third nerve palsy is challenging because of multiple muscle involvement with complex deviation and presence of ptosis, choosing appropriate and sometimes multistep surgical plans helps achieve acceptable results [Figure 2].



**Figure 2.** A patient with strabismus surgery after traumatic third nerve paresis before (A) and after (B) surgery.

## REFERENCES

1. Helveston EM. Surgical management of strabismus: An atlas of strabismus surgery. 4<sup>th</sup> ed. St Louis: Mosby;1993:502-508.
2. Miller NR, Newman NJ, Hoyt WF, Walsh FB, Walsh and Hoyt's clinical neuro-ophthalmology. 5<sup>th</sup> ed. Baltimore, MD: Williams and Wilkins; 1998.
3. Von Noorden GK. Binocular vision and ocular motility: Theory and management of strabismus. 7<sup>th</sup> ed. St Louis: Mosby; 2004.
4. Rucker CW. Paralysis of the third, fourth and sixth cranial nerves. *Am J Ophthalmol* 1958;46:787-794.
5. Rucker CW. The causes of paralysis of the third, fourth and sixth cranial nerves. *Am J Ophthalmol* 1966;61:1293-1298.
6. Rush JA, Younge BR. Paralysis of cranial nerves III, IV, and VI. Cause and prognosis in 1,000 cases. *Arch Ophthalmol* 1981;99:76-79.
7. American Academy of Ophthalmology. Basic and clinical science course: Pediatric ophthalmology and strabismus. Philadelphia, PSI: American Academy of Ophthalmology (AAO); 2010-2011. p. 132-134.
8. Schumacher-Feero LA, Yoo KW, Solari FM, Biglan AW. Third cranial nerve palsy in children. *Am J Ophthalmol* 1999;128:216-221.
9. American Academy of Ophthalmology. Basic and clinical science course: Neuro-ophthalmology. Philadelphia, PSI: American Academy of Ophthalmology (AAO); 2010-2011:228-232.
10. Bagheri A, Hendi K. Epidemiologic evaluation of extraocular muscle palsies. *Bina J Ophthalmol* 2000;5:237-244.
11. Rosenbaum AL, Santiago AP. Clinical strabismus and management: principles and surgical techniques. Philadelphia: W.B Saunders;1999:251-259.
12. Medghalchi AR. Survey of paralytic strabismus. *Acta Med Iran* 2009;47:221-224.
13. Soni SR. Aneurysms of the posterior communicating artery and oculomotor paresis. *J Neurol Neurosurg Psychiatry* 1974;37:475-484.
14. Kissel JT, Burde RM, Klingele TG, Zeiger HE. Pupil-sparing oculomotor palsies with internal carotid-posterior communicating artery aneurysms. *Ann Neurol* 1983;13:149-154.
15. Bagheri A, Khodabakhshi M, Anisian A, Mirdehghan A. Epidemiologic and etiologic characteristics of patients with paralytic strabismus. *Bina J Ophthalmol* 2003;4:323-332.
16. Park UC, Kim SJ, Hwang JM, Yu YS. Clinical features and natural history of acquired third, fourth, and sixth cranial nerve palsy. *Eye (Lond)* 2008;22:691-696.
17. Tabbasi AB, Dehghani AL. Etiology of oculomotor nerve paralysis. *J Ophthalmic Vis Res* 2006;1:1.
18. Köse S, Uretmen O, Pamukçu K. An approach to the surgical management of total oculomotor nerve palsy. *Strabismus* 2001;9:1-8.
19. Yonghong J, Kanxing Z, Wei L, Xiao W, Jinghui W, Fanghua Z. Surgical management of large-angle incomitant strabismus in patients with oculomotor nerve palsy. *J AAPOS* 2008;12:49-53.
20. Merino P, Gómez de Liaño P, Maestre I. Surgical treatment of third cranial nerve palsy. *Arch Soc Esp Ophthalmol* 2005;80:155-162.
21. Flanders M, Hasan J, Al-Mujaini A. Partial third cranial nerve palsy: Clinical characteristics and surgical management. *Can J Ophthalmol* 2012;47:321-325.

**How to cite this article:** Bagheri A, Borhani M, Tavakoli M, Salehirad S. Clinical Features and Outcomes of Strabismus Treatment in Third Cranial Nerve Palsy during a 10-Year Period. *J Ophthalmic Vis Res* 2014;9:343-9.

**Source of Support:** Nil. **Conflict of Interest:** None declared.