

Case Report

Visceral leishmaniasis with Roth spots

Jagdish Meena*, Monica Juneja, Devendra Mishra, Pallavi Vats and Arti Pawaria

Department of Pediatrics, Maulana Azad Medical College and attached Lok Nayak Hospital, New Delhi, India

*Correspondence address. Quarter No. 374, Mir Dard Lane Residential Complex, Lok Nayak Hospital, New Delhi 110002, India. Tel: +91-8826466408; E-mail: drjpmeena@yahoo.com

Received 10 July 2014; revised 6 August 2014; accepted 20 August 2014

Visceral leishmaniasis (VL) is caused by the protozoan parasite *Leishmania donovani* and transmitted by the bite of infected sandfly *Phlebotomus argentipes*. The protozoa is obliged intracellularly and causes a wide spectrum of clinical syndromes: VL ('kala azar'), cutaneous leishmaniasis and mucocutaneous leishmaniasis (espundia). Kala azar is the most aggressive form and if untreated causes high mortality. Here, we describe a case of VL that presented to us with high-grade fever and found to have Roth spots that were resolved after 15 days of therapy.

INTRODUCTION

Leishmaniasis is a disease caused by parasites of the genus *Leishmania*. Most cases tend to occur between April and September. The female sandfly specifically feeds at dusk, and tends to remain near its breeding area. Transmission of VL has also been seen by sexual intercourse, blood transfusion, contaminated needles and rarely congenitally. Nearly 50% of VL cases occur in children.

In India, the peak age is between 5 and 9 years and mostly seen in males. Visceral leishmaniasis (VL) results in systemic infection of the reticuloendothelial organs and bone marrow. The classical symptoms of VL are high-grade fever, pallor, refusal to feed, abdominal discomfort, weight loss, vomiting, hepatosplenomegaly, hyperpigmentation, epistaxis and gingival bleeding. Laboratory tests with classic kala azar usually reveal thrombocytopenia, anaemia, leucopenia, elevated hepatic transaminase levels and hypoalbuminaemia. The parasite may be detected through direct evidence in the peripheral blood, bone marrow or splenic aspirates.

CASE REPORT

We report a case of a 7-year-old male child, a resident of Delhi who migrated to Bihar (a state of India) 6 months back, had been resident in Bihar for 1 month only and developed symptoms after 6 months returning to Delhi, presented to us with poor oral intake and high-grade fever for 15 consecutive days. On admission he had pallor and spleno-hepatomegaly.

Laboratory tests gave the following results: haemoglobin 8.5 mg/dl, total leucocyte counts 2990/ μ l, platelet counts 54×10^3 / μ l, serum glutamate oxaloacetate transaminase 83 U/l, serum glutamic-pyruvic transaminase 85 U/l, serum albumin 3.7 g/dl and erythrocyte sedimentation rate 53 mm/h. Blood culture, tests for malaria and enteric fever were negative. Viral markers and HIV ELISA were also negative. Echocardiography was normal. Fundus by slit-lamp examination revealed *Roth spots* (Fig. 1). The rk39 (recombinant k 39) was negative but in the bone marrow aspiration, intracellular *Leishmani donovani* bodies were observed.

Therapy with conventional amphotericin B with IV infusion over 4 h was started and child became afebrile after 3 days of therapy. The child was given a total of 15 mg/kg of amphotericin B. No side effect of amphotericin was observed. After completion of therapy, Roth spots were disappeared. 3 months later, he came for follow-up and was found well.

DISCUSSION

Roth's spots are retinal haemorrhages with white or pale centres composed of coagulated fibrin. They are typically observed via funduscopy (using an ophthalmoscope) or slit-lamp examination [1, 2]. They are usually caused by immune-complex mediated vasculitis often seen in bacterial endocarditis. Roth's spots may be observed in leukaemia, diabetes, subacute bacterial endocarditis, anaemia, anoxia, carbon monoxide poisoning, prolonged intubation, pre-

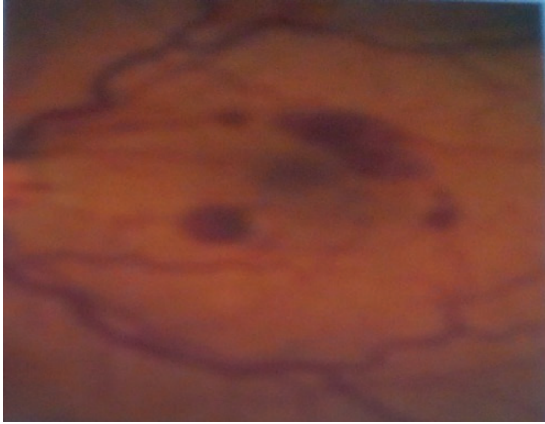


Figure 1: Slit-lamp examination showing Roth spots.

eclampsia, HIV retinopathy, complicated labour and traumatic delivery in mothers and neonates, shaken baby syndrome, intracranial haemorrhage from AV malformation or aneurysm and acute reduction of intraocular pressure following trabeculectomy [2, 3].

Possible aetiology of Roth spots in our patient could be due to thrombocytopenia and anaemia. Thrombocytopenia can cause haemorrhages in the retina on mucous surfaces and in the skin. Anaemia may cause further anoxic insult to retinal capillaries in patients with kala azar.

Leishmaniasis is endemic in many countries in tropical and subtropical regions, including Africa, Asia, Central and South Americas and Mediterranean regions. Five countries, namely Bangladesh, India, Nepal, Sudan and Brazil account for 90% of the world incidence [9].

VL is a potentially fatal parasitic disease, directly associated with poverty, overcrowding and poor-ventilation. The burden of this disease is also influenced by social factors such as under-nutrition, sanitation, presence of other infectious diseases such as HIV, which delays diagnosis and management. This leads to increased morbidity and mortality due to this disease [5, 6].

Kala azar is endemic in 52 districts in India, Bihar (31), Jharkhand (4), West Bengal (11) and Uttar Pradesh (6). While

both cutaneous and visceral disease occurs in India, Kala azar is by far the most important leishmaniasis in India.

The Aldehyde test remains reliable when testing for surveillance rather than diagnostic purposes. This is due to its relative lack of specificity but high sensitivity at even 3 months post-infection. The new and simple rk39 diagnostic test may be useful screening tool [7, 8]. It has a sensitivity and specificity of nearly 100%. Definitive diagnosis is made by demonstration of amastigotes by microscopic examination of materials obtained by bone marrow aspiration or splenic puncture.

The currently used drugs for the treatment of VL are (1) sodium stibogluconate, (2) amphotericin B, (3) miltefosine and (4) paromomycin [4]. Under NVBDCP (National Vector Borne Disease Control Programme) miltefosine as a first-line treatment and amphotericin B as a second-line treatment are used.

Our literature search was unable to find another recorded case of VL with Roth spots in children. We therefore conclude that Roth spots are a rare clinical finding in VL and could therefore be considered to be characteristic for kala azar.

REFERENCES

1. Daune TD, Osher RH, Green WR. White-centered haemorrhages: their significance. *Ophthalmology* 1980;**87**:66–69.
2. Von Barsewisch B. Morphology, section C: white fibrin thrombi of vessel ruptures and fibrin emboli in retinal vessels. In: Blodi FC, ed. *Perinatal Retinal Haemorrhages*. New York, NY: Springer-Verlag, 1979,47–51.
3. Ling R, James B. White-centered retinal haemorrhages (Roth spots). *Postgrad Med J* 1998;**74**:581–582.
4. Adopted from report of meeting of the WHO Expert Committee on control of leishmaniasis. WHO Technical Report Series No. 949. WHO Switzerland 2010.
5. Alvar J, Yactayo S, Bern C. Leishmaniasis and poverty. *Trends Parasitol* 2006;**22**:552–557.
6. Boelaert M, Meheus F, Robays J, Lutumba P. Socio-economic aspects of neglected diseases: sleeping sickness and visceral leishmaniasis. *Ann Trop Med Parasitol* 2010;**104**:535–542.
7. Singh S, Gilman-Sachs A, Chang KP, Reed SG. Diagnostic and prognostic value of rk39 antigen in Indian leishmaniasis. *J Parasitol* 1995;**81**:1000–1003.
8. Sunder S, Reed SG, Singh VP, Kumar PCK, Murray HW. Rapid accurate field diagnosis of Indian visceral leishmaniasis. *Lancet* 1998;**351**: 563–565.
9. WHO (2008). Health situation in South East Asia Region, 2001–2007.