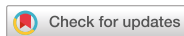

Original Article  
Neuroscience



# Frameless Fractionated Gamma Knife Radiosurgery with ICON™ for Large Metastatic Brain Tumors

Hye Ran Park <sup>1\*</sup>, Kwang-Woo Park <sup>2\*</sup>, Jae Meen Lee <sup>3</sup>, Jung Hoon Kim <sup>2</sup>, Sang Soon Jeong <sup>2</sup>, Jin Wook Kim <sup>2</sup>, Hyun-Tai Chung <sup>2</sup>, Dong Gyu Kim <sup>2</sup>, and Sun Ha Paek <sup>2,4,5</sup>

<sup>1</sup>Department of Neurosurgery, Soonchunhyang University Seoul Hospital, Seoul, Korea

<sup>2</sup>Department of Neurosurgery, Seoul National University Hospital, Seoul, Korea

<sup>3</sup>Department of Neurosurgery, Pusan National University Hospital, Pusan, Korea

<sup>4</sup>Cancer Research Institute, Seoul National University, Seoul, Korea

<sup>5</sup>Ischemia Hypoxia Disease Institute, Seoul National University, Seoul, Korea



Received: Nov 12, 2018

Accepted: Jan 29, 2019

**Address for Correspondence:**

Sun Ha Paek, MD, PhD

Department of Neurosurgery, Seoul National University Hospital, 101 Daehak-ro, Jongno-gu, Seoul 03080, Korea.

E-mail: paeksh@snu.ac.kr

\*Hye Ran Park and Kwang-Woo Park contributed equally to this work.

© 2019 The Korean Academy of Medical Sciences.

This is an Open Access article distributed under the terms of the Creative Commons Attribution Non-Commercial License (<https://creativecommons.org/licenses/by-nc/4.0/>) which permits unrestricted non-commercial use, distribution, and reproduction in any medium, provided the original work is properly cited.

**ORCID iDs**

Hye Ran Park   
<https://orcid.org/0000-0003-0506-4882>

Kwang-Woo Park   
<https://orcid.org/0000-0002-3384-079X>

Jae Meen Lee   
<https://orcid.org/0000-0002-5708-1644>

Jung Hoon Kim   
<https://orcid.org/0000-0002-8090-7758>

Sang Soon Jeong   
<https://orcid.org/0000-0002-8566-0117>

Jin Wook Kim   
<https://orcid.org/0000-0003-0934-3344>

Hyun-Tai Chung   
<https://orcid.org/0000-0001-8243-2568>

## ABSTRACT

**Background:** Recently, a new generation of gamma knife radiosurgery (GKRS) equipped with a frameless immobilization system has encouraged the use of fractionated GKRS as an increasingly favorable treatment option. We investigated the preliminary outcome of efficacy and toxicity associated with frameless fractionated gamma knife radiosurgery (FF GKRS) for the treatment of large metastatic brain tumors.

**Methods:** Fifteen patients with 17 lesions were treated using FF GKRS and included in this study, because of the large tumor size of more than 10 cm<sup>3</sup>. FF GKRS was performed based on a thermoplastic mask system for 3 to 5 consecutive days.

**Results:** The mean duration of clinical follow-up was 12 months (range, 4–24), and the local control rate was 100%. Tumor volume decreased in 13 lesions (76.5%), and remained stable in 4 lesions (23.5%). One patient was classified as new lesion development because of the occurrence of leptomeningeal seeding regardless of the tumor volume change. Compared with the initial volume at the time of FF GKRS, tumor volume change at the last follow-up was 62.32% ± 29.80%. Cumulative survival rate at 12 months was 93.3% ± 6.4%. One patient died during the follow-up period because of the progression of the primary disease. No patient showed radiation necrosis on the follow-up images.

**Conclusion:** Daily FF GKRS by gamma knife ICON™ revealed satisfactory tumor control rate and low morbidity, despite the short follow-up period. Further prospective studies and a longer follow-up of a large cohort of patients diagnosed with brain metastases are required to elucidate the effect of FF GKRS in brain metastases.

**Keywords:** Frameless Fractionated; Gamma Knife Radiosurgery; ICON™; Metastatic Brain Tumor

## INTRODUCTION

Stereotactic radiosurgery using Gamma Knife is one of the standard treatment options for brain metastases and resulted in high tumor control rates and low morbidity.<sup>1,2</sup> Although gamma knife radiosurgery (GKRS) for brain metastases is expected to show low morbidity

Dong Gyu Kim 

<https://orcid.org/0000-0002-5740-6189>

Sun Ha Paek 

<https://orcid.org/0000-0003-3007-8653>

### Funding

This study was supported by the Korea Healthcare Technology R&D Project (grant No. H11C21100200), funded by the Ministry of Health & Welfare, Republic of Korea; the Industrial Strategic Technology Development Program (grant No. 10050154, Business Model Development for Personalized Medicine Based on Integrated Genome and Clinical Information) funded by the Ministry of Trade, Industry & Energy (M, Korea); the Original Technology Research Program for Brain Science through the National Research Foundation of Korea (NRF) funded by the Ministry of Education, Science and Technology (grant No. 2015M3C7A1028926); the Original Technology Research Program for Brain Science through the National Research Foundation of Korea (NRF) funded by the Ministry of Education, Science and Technology (grant No. 2017M3C7A1047392); and Soonchunhyang University research fund.

### Disclosure

The authors have no potential conflicts of interest to disclose.

### Author Contributions

Conceptualization: Kim DG, Paek SH. Data curation: Jeong SS. Formal analysis: Chung HT. Investigation: Lee JM. Methodology: Kim JH, Kim JW. Writing - original draft: Park HR, Park KW. Writing - review & editing: Park HR, Park KW.

associated with irradiation due to steep dose fall-off at the tumor margin, concerns relate to the adverse effects involving large-sized tumors.

Studies report attempts to split the irradiation to decrease the treatment-related complications.<sup>3-5</sup> The benefit of fractionated GKRS is disputed because of the errors caused by movement of the head frame in patients. Traditional GKRS is based on a pin-based, rigid frame system that immobilized a patient and to accurately define the stereotactic coordinate. However, a new generation of GKRS with a frameless immobilization system has rendered fractionated GKRS an increasingly favorable treatment option. This is the first report of large metastatic brain tumors treated with frameless fractionated GKS (FF GKRS) using Gamma Knife ICON™ (Elekta AB, Stockholm, Sweden). Gamma Knife ICON™ tracks patient movement during treatment using a cone beam computed tomography (CBCT), a thermoplastic mask system, and an infrared-based high-definition motion management (HDMM) camera. Since the introduction of Gamma Knife ICON™, a few patients were treated with FF GKRS for large metastatic brain tumors using these useful tools.

We performed FF GKRS for large tumors with a tumor volume  $\geq 10 \text{ cm}^3$ . To investigate the effectiveness and toxicity of FF GKRS, we report a preliminary outcome of short-term clinical and radiologic follow-up.

## METHODS

All 15 patients treated by FF GKRS using gamma knife ICON™ over 3 or 5 consecutive days underwent imaging follow-up via contrast-enhanced magnetic resonance imaging (MRI). Patient characteristics, radiologic tumor response, and clinical progress were reviewed by medical records.

### Patient characteristics

Between April 2016 and Mar 2018, 408 patients with 1,604 lesions underwent GKRS for brain metastases at the Gamma Knife Center of our institution. Of these, 15 patients with 17 lesions were treated with FF GKRS because of the large volume tumor more than  $10 \text{ cm}^3$  were included in this study. **Table 1** lists the baseline patient demographics and clinical characteristics. The mean tumor volume was  $19.53 \pm 7.07 \text{ cm}^3$ . All patients were diagnosed with metastatic brain tumor.

### Radiosurgical technique of FF GKRS using ICON™

We performed thermoplastic mask-based FF GKRS for brain metastases. A brain MRI scan without Leksell frame was performed to obtain a thin-section image and a T1-weighted image with gadolinium enhancement to define the target volume. During the MRI, the patient's face was covered with a thermoplastic mask in a relaxed posture. The thermoplastic mask system consisted of customized cradles (Moldcare™; Alcare Co, Tokyo, Japan) and 3-point thermoplastic masks (Orfit® Industries, Wijnegem, Belgium). The nose portion of the mask was cut to place a single reflective optical marker on the nose of the patient's nose, which was visible in the radiation unit and served as a stable anatomic reference for motion tracking between fractions. Subsequently, we performed CBCT and co-registration with MRI scan for target localization and verification. Treatment was planned using the Leksell Gamma Plan Treatment Planning System (version 11.0.3; Elekta Instrument). Tumor margin was outlined using region and volume tool of GammaPlan software. The final target volume was defined

**Table 1.** Characteristics of the 15 patients included in the study

Characteristics	Value
No. of patients	15
<b>Gender</b>	
Men	7 (46.7%)
Women	8 (53.3%)
<b>Age, yr</b>	
Median	55
Range	35–69
<b>Primary tumor</b>	
NSCLC	8 (53.3%)
Breast carcinoma	2 (13.3%)
Melanoma	2 (13.3%)
Adenocarcinoma	1 (6.7%)
Renal cell carcinoma	1 (6.7%)
Hepatocellular carcinoma	1 (6.7%)
<b>No. of metastasis</b>	
1	9 (60%)
2–3	5 (33.3%)
≥ 4	1 (6.7%)
<b>Primary disease</b>	
Controlled	5 (33.3%)
Uncontrolled	10 (66.7%)
<b>Previous treatment</b>	
None	6 (40%)
Radiosurgery	4 (26.7%)
Surgical resection and WBRT	2 (13.3%)
Surgical resection and radiosurgery	1 (6.7%)
WBRT	1 (6.7%)
Surgical resection	1 (6.7%)
<b>GPA score</b>	
1.5	1 (6.7%)
2	3 (20%)
2.5	5 (33.3%)
3	4 (26.7%)
3.5	2 (13.3%)
<b>Karnofsky performance status</b>	
Median	90
Range	70–100

NSCLC = non-small cell lung cancer, WBRT = whole brain radiation therapy, GPA = graded prognostic assessment.

with a tumor volume without additional margin. The prescription dose was 21 to 40 Gy in 50% isodose line and fractionated daily for 3 to 5 consecutive days via multiple isocenter plan (Table 2). The majority of fractionated GKRS for brain metastasis has been used 8 Gy × 3 fraction. However, the total dose was reduced or increased depending on the tumor location, size, and surrounding normal organ. A threshold of 5 Gy was applied to the optic apparatus per fraction perpendicular to the tumor. Intra- or inter-fractional repositioning error was limited to less than 1.5 mm through HDMM and CBCT.

### Accuracy verification

Prior to each fraction, daily CBCT was performed to verify the actual skull position. The accuracy of imaging between CBCT and stereotactic CT was within 0.5 mm in the experiment using the anthropomorphic phantom performed in the Gamma Knife Center of our institution. Based on these results, we were confident that the accuracy was maintained during treatment over several consecutive days. The movement of the patients' head was controlled within 1.5 mm using a high definition motion management system.

**Table 2.** Radiosurgical parameters of the patient group

Characteristics	Value
No. of tumor	17
Gross tumor volume, cm <sup>3</sup>	
10–14	5 (29.4%)
> 14	12 (70.6%)
Mean	23.53
Range	10.28–34.35
Prescribed tumor volume, cm <sup>3</sup>	
Mean	21.16
Range	10.986–38.06
Covered ratio, %	96–100
Isodose line, median, %	50
Fractionation schedule	
7 Gy × 3	3 (17.6%)
8 Gy × 3	5 (29.4%)
9 Gy × 3	2 (11.8%)
10 Gy × 3	5 (29.4%)
8 Gy × 5	2 (11.8%)

### Follow-up

Preoperative and follow-up data were extracted from the registered patient groups. The clinical status was determined via telephone if required. Imaging tests were routinely performed with detailed neurological examinations at 1, 3, 5, 7, 9, and 12 months after FF GKRS. In addition to the change in tumor volume in MRI, the clinical findings including improvement or deterioration of the existing symptoms and appearance of new symptoms were determined. Tumor volume increase was defined as a 120% increase in tumor volume relative to the time of FF GKRS. Toxicity was graded using the Radiation Therapy Oncology Group Central Nervous System (CNS) toxicity scoring system.

### Statistical analysis

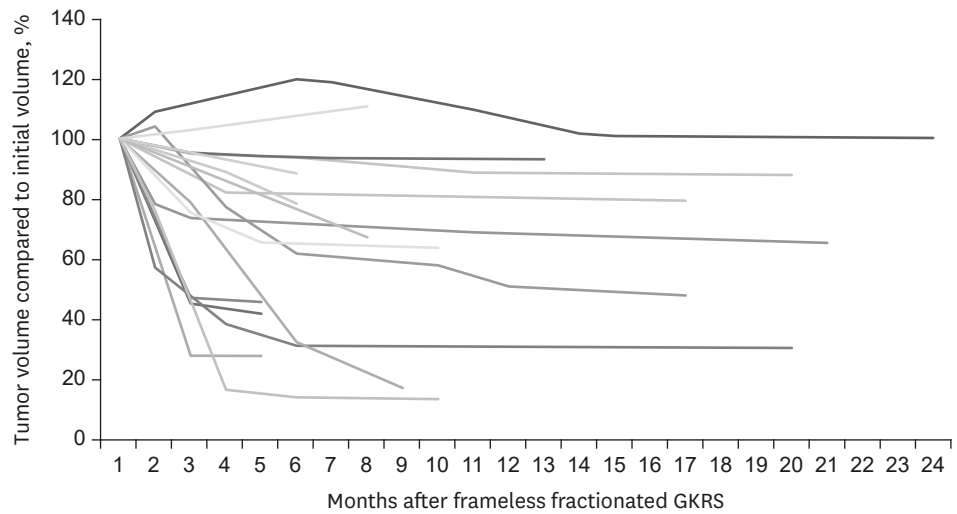
Differences between groups were assessed using the Mann-Whitney test or  $\chi^2$  test for continuous and categorical variables, respectively. Kaplan-Meier survival plots were used to estimate the tumor control distributions and the log-rank test (level of significance,  $P < 0.05$ ) was used to assess differences between the groups. All statistical analyses were performed using SPSS Statistics (version 19.0; IBM Inc., Armonk, NY, USA).

### Ethics statement

This study was approved by the Institutional Review Board (IRB) of Seoul National University Hospital (IRB No. H-1704-111-847) and was conducted according to the tenets of the Declaration of Helsinki. No written consent was needed due to the retrospective study design.

## RESULTS

The mean duration of clinical follow-up was 12 months (range, 2–24), and the local tumor control rate was 100%. The tumor volume decreased in 13 lesions (76.5%) and remained stable in 4 lesions (23.5%). One patient with melanoma was classified as new lesion development because of the new occurrence of leptomeningeal seeding, despite the tumor volume remaining stable. Compared with the initial volume at the time of FF GKRS, tumor volume change at the last follow-up was  $62.32\% \pm 29.80\%$ . **Fig. 1** shows the volumetric change after FF GKRS in each patient. Cumulative survival rate at 12 months was  $93.3\% \pm$



**Fig. 1.** Tumor volume changes in each patient after frameless fractionated GKRS. GKRS = gamma knife radiosurgery.

6.4%. One patient died during the follow-up period. This 40-year old men patient with a prior history of whole brain radiation therapy (WBRT) underwent FF GKRS for 3 metastatic lesions associated with non-small cell lung cancer (NSCLC). Despite the radiological decrease in tumor volume, the patient died because of progression of primary cancer at 4 months after FF GKRS.

Nine patients manifested neurological symptoms at the time of FF GKRS (**Table 3**). Pre-existing symptoms included headache in four patients, motor weakness in two patients, and diplopia, dysarthria, visual disturbance, dizziness, seizure, and paresthesia in one patient, respectively. Four patients manifested more than one symptom, and another 6 patients exhibited no presenting symptom before FF GKRS. Of nine patients, four experienced symptom improvement after FF GKRS, and five remained stable. One patient with motor weakness before treatment remained stationary after FF GKRS. One patient with visual disturbance due to parieto-occipital lesion, one with diplopia, and other patients with headache and paresthesia were not improved after FF GKRS. Four of the patients experienced symptoms afresh. Tolerable headache controlled by medication was reported in one patient. Another one patient exhibited motor weakness, which disappeared in one of them. One patient with melanoma complained of progressive dizziness, and leptomeningeal seeding was found afterward. Subjective memory disturbance was noted in one patient who underwent FF GKS for metastatic tumor in frontal lobe from breast carcinoma. The median

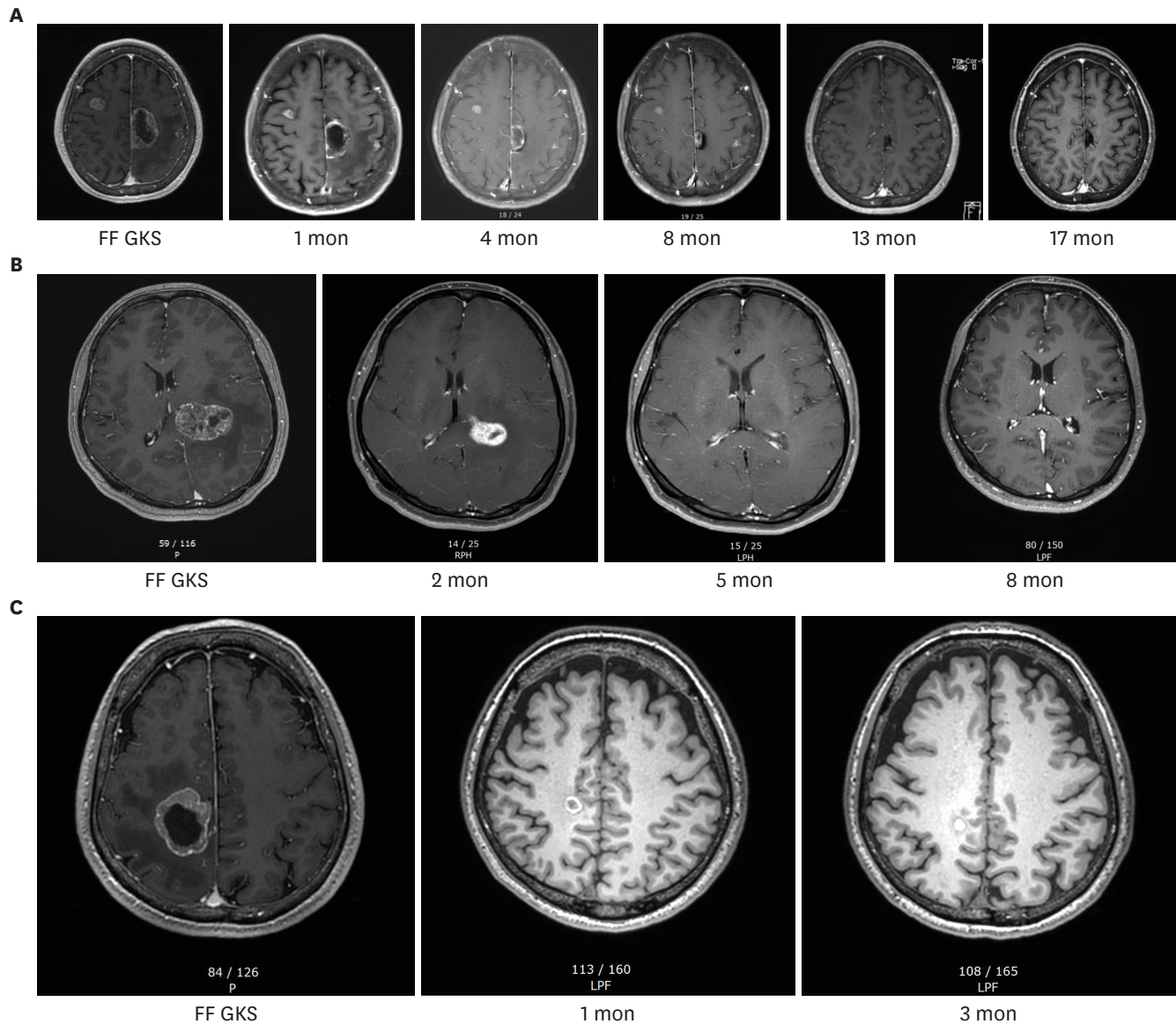
**Table 3.** Clinical course of neurological symptoms after FF GKRS

Pre-existing symptoms	Pre GKRS, No.	Post GKRS		
		Improved	Stable	Worsen
Headache	4	3	1	0
Diplopia	1	0	1	0
Motor weakness	2	1	1	0
Dysarthria	1	0	1	0
Visual disturbance	1	0	1	0
Dizziness	1	1	0	0
Seizure	1	0	1	0
Paresthesia	1	0	1	0

FF GKRS = frameless fractionated gamma knife radiosurgery.

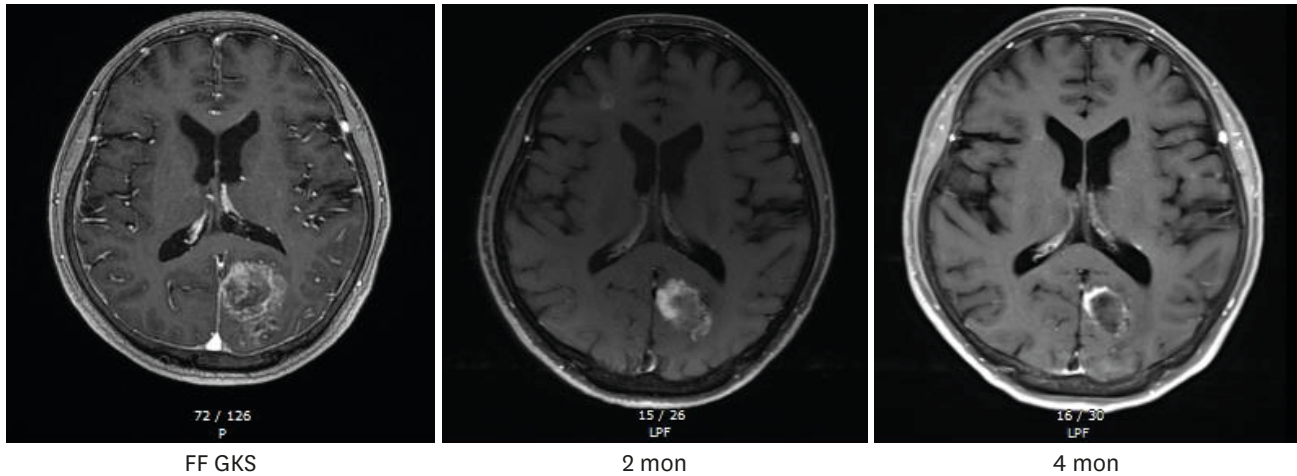
Karnofsky Performance Status score at the final clinical follow-up was 100. No patient showed radiation necrosis in the follow-up. Fig. 2 represents illustrative cases of four patients with favorable response to FF GKRS.

When defining tumor control failure as local control failure, clinical death, or new lesion development, two patients with four lesions were classified into tumor control failure group. There was no statistically significant relationship between fractionation schedule and tumor control failure (Table 4).



**Fig. 2.** Illustrative cases of four patients with favorable response to FF GKRS. (A) This 65-year-old female patient with history of NSCLC felt dizziness and underwent FF GKRS for large metastatic lesion on Lt frontal convex. The initial tumor volume was 27.084 cm<sup>3</sup>, but slowly decreased until 17 months after FF GKRS using 9 Gy for 3 consecutive days. (B) This 37-year old female patient was diagnosed as NSCLC and treated by Alectinib. Her neurologic symptoms were headache and vomiting, and she underwent FF GKRS for the large metastatic tumor of 22.701 cm<sup>3</sup> located nearby the posterior horn of left lateral ventricle. The radiosurgery parameter was 3 Gy with 3 fraction for 3 consecutive days. After 5 months after FF GKRS, the tumor nearly disappeared. (C) This figure shows a case of 59-year-old male with NSCLC treated by wedge resection. Brain metastasis with 22.124 cm<sup>3</sup> was incidentally found, and the tumor showed dramatic decrease until 3 months after FF GKRS using 8 Gy with 5 fraction. (D) The patient of this figure was 64-year-old female newly diagnosed with NSCLC and brain metastasis. After FF GKRS using 8 Gy with 5 fraction, the metastatic lesion of 31.413 cm<sup>3</sup> showed gradual decrease. FF GKRS = frameless fractionated gamma knife radiosurgery, NSCLC = non-small cell lung cancer. (continued to the next page)

D



**Fig. 2.** (Continued) Illustrative cases of four patients with favorable response to FF GKRS. **(A)** This 65-year-old female patient with history of NSCLC felt dizziness and underwent FF GKRS for large metastatic lesion on Lt frontal convex. The initial tumor volume was 27.084 cm<sup>3</sup>, but slowly decreased until 17 months after FF GKRS using 9 Gy for 3 consecutive days. **(B)** This 37-year old female patient was diagnosed as NSCLC and treated by Alectinib. Her neurologic symptoms were headache and vomiting, and she underwent FF GKRS for the large metastatic tumor of 22.701 cm<sup>3</sup> located nearby the posterior horn of left lateral ventricle. The radiosurgery parameter was 3 Gy with 3 fraction for 3 consecutive days. After 5 months after FF GKRS, the tumor nearly disappeared. **(C)** This figure shows a case of 59-year-old male with NSCLC treated by wedge resection. Brain metastasis with 22.124 cm<sup>3</sup> was incidentally found, and the tumor showed dramatic decrease until 3 months after FF GKRS using 8 Gy with 5 fraction. **(D)** The patient of this figure was 64-year-old female newly diagnosed with NSCLC and brain metastasis. After FF GKRS using 8 Gy with 5 fraction, the metastatic lesion of 31.413 cm<sup>3</sup> showed gradual decrease. FF GKRS = frameless fractionated gamma knife radiosurgery, NSCLC = non-small cell lung cancer.

When comparing the CBCT and preoperative CT images, the inter-fractional movement was less than 0.5 mm. Daily difference in intra-fractional movement was 0.1 mm with a maximum error of 0.5 mm in HDMM system. The accuracy of HDMM system was 0.1 mm with a maximum error of 0.5 mm.<sup>6</sup> We also performed an experiment using an anthropomorphic phantom and validated the accuracy of co-registration with a difference of less than 0.5 mm between the CBCT and stereotactic CT image.

## DISCUSSION

When treating large-volume tumors, fractionation yielded the four R's of radiobiology: repair of normal tissue, reoxygenation of tumor hypoxia, redistribution into radiosensitive cell cycle stages, and repopulation. In tumors with large volume and adjacent to the eloquent area, complete surgical resection without postoperative complications is almost impossible.<sup>7,8</sup> Radiosurgery is indicated in such cases. The current therapeutic dose for brain metastases may be excessive and not appropriate due to adjacent normal tissue, such as the optic apparatus or brain stem. Traditional single-session radiosurgery resulted in adverse radiation effects without rapid volume reduction.<sup>9</sup>

**Table 4.** Clinical outcome according to fractionation schedule

Fractionation schedule	No.	Tumor control failure, No. (%)	New lesion development, No. (%)	Death, No. (%)
7 Gy × 3	3	0 (0)	0 (0)	2 (66.7)
8 Gy × 3	5	0 (0)	0 (0)	1 (20)
9 Gy × 3	2	0 (0)	1 (50)	0 (0)
10 Gy × 3	5	0 (0)	0 (0)	0 (0)
8 Gy × 5	2	0 (0)	0 (0)	0 (0)
P value			0.235	0.137

Despite the poor radiobiological bases of fractionated radiosurgery, a few studies using LINAC-based instrument showed that fractionated radiosurgery was safe and effective in brain metastases.<sup>10-12</sup> Aoyama et al.<sup>11</sup> treated 87 patients with 35 Gy in 4 fractions, and concluded that fractionated radiosurgery is as effective as single-session radiosurgery with minimal toxicity. Kim et al.<sup>10</sup> compared single-session and fractionated radiosurgery for brain metastases in 98 patients. In their study, fractionated radiosurgery showed minimal toxicity and superior tumor control when compared with single-session radiosurgery, especially for large-volume tumors. However, few studies reported fractionated GKRS for brain metastases. A few studies investigated fractionated GKRS for brain metastases using several fractionated schemes.<sup>3,13,14</sup> They performed separate radiosurgeries at 1 to 4-weeks intervals, and showed symptomatic improvement of 74% without complications,<sup>13</sup> and a local control rate of 89.8% with a volume reduction rate of 39.8%.<sup>15</sup>

Our group previously reported that fractionated GKRS resulted in satisfactory tumor control and low morbidity in case of large brain metastases  $> 10 \text{ cm}^3$ .<sup>16</sup> In the published study, we analyzed the efficacy and toxicity of hypofractionated GKRS to treat metastatic brain tumors for which surgical resection were not considered as the primary treatment option. The previous study included 36 patients with 40 cases, and the mean gross tumor volume was  $18.3 \text{ cm}^3$ . The median dose was 8 Gy at 50% isodose line with 3 fractions, which was similar to this study. The cumulative survival rate at 1 and 2 year was 66.7% and 33.1%, respectively. The local tumor control rate was 90% and grade 3 or higher toxicity was 2.7%. In the previous study, we proposed the indications for fractionated GKRS as follows: 1) large tumors with a volume greater than  $10 \text{ cm}^3$ , 2) tumors adjacent to eloquent areas such as the optic apparatus or brain stem, and 3) previously irradiated tumors.

However, pin-based fractionated GKRS was a difficult method for patients with brain metastases. We interviewed patients who were exposed to FF GKRS using mask-based immobilization and found that it was certainly more comfortable for patients receiving GKRS for brain metastases. Another disadvantage of the pin-based, rigid head frame system is the lack of reproducibility once it was removed. To overcome this problem, an advanced instrument, Gamma Knife ICON™, was developed to facilitate fractionated radiosurgery as well as frameless fixation. This instrument enabled on-board verification of patient position and correction using a quality CBCT system. In addition, the intra-fraction patient position was monitored using an optical tracking system and the treatment delivery was controlled for positional excursion from the planned treatment position. Using these tools, fractionated and frame-based Gamma Knife ICON™ ensured treatment efficacy.<sup>6</sup> This study showed that the HDMM system was accurate with an error of almost 0.01 mm and a maximum of 0.05 mm. Other studies also showed that mask-based immobilization using Gamma Knife ICON™ reduced the mean width of the inter- and intra-fraction movement to within 1 mm.<sup>17</sup>

After introduction of FF GKRS using Gamma Knife ICON™, our group has performed FF GKRS based on this assumption. We investigated the feasibility of FF GKRS using mask-based immobilization. Our results showed that FF GKRS reduced radiation-induced complications and facilitated patients with brain metastases adjacent to the eloquent area, large volume tumors, and those previously exposed to radiation. Our results were similar to those of previously published data using hypofractionated GKRS using frame, showing a local control rate of 94.1% and a volume reduction rate of 27.7% for large brain metastases. In contrast to other investigators suggesting fractionation intervals between GKRS sessions



to reduce radiation toxicity, we performed dose-fractionated GKRS on a daily basis. Notably, daily fractionated GKRS showed no radiation-induced complications for brain metastases despite high irradiation doses.

Clinical studies with Gamma Knife ICON™ have rarely been reported. This study demonstrates that FF GKS using Gamma Knife ICON™ is safe and effective for the treatment of large metastatic brain tumors. Our results showed local tumor control rates of 89.8%, similar to other published data with a local control rate of 70% to 90%.<sup>18-21</sup> Longer follow-up is required for consolidation of the results, whereas FF GKRS using Gamma Knife ICON™ is a sufficiently reliable modality for large metastatic brain tumors based on the current study.

GKRS is also indicated as a salvage treatment for patients with recurrent tumors in spite of previous radiosurgery or WBRT. This present study included 8 patients who underwent radiosurgery or WBRT prior to FF GKRS. The indications for repeated GKRS in recurrent brain metastases remain unclear in terms of morbidity due to irradiation. However, our results show that repeated GKRS is effective for recurrent large metastatic brain tumors. These results have been corroborated in other studies, which showed no radiation-induced complication in 16 patients treated with an average of 2.6 cycles of radiosurgery.<sup>22</sup>

The complication rate of GKRS for brain tumors was reported at 1%–2% in previous studies.<sup>9,23</sup> However, GKRS is associated with irreversible toxicity due to radiation. Therefore, fractionated GKRS promotes tolerance by adjacent normal tissues and intracranial tumor control in multisession radiosurgery.<sup>5,24,25</sup> We previously reported the efficacy and toxicity for the treatment of large metastatic brain tumors using fractionated GKRS with pin-based immobilization resulting in effective tumor control and low toxicity rates.<sup>26</sup> We have shown that fractionated GKRS is a possible indication for tumors adjacent to the eloquent area or tumors irradiated previously. In our experience, no acute complication due to radiation was detected after daily consecutive FF GKRS in cases diagnosed with brain metastases.

This study reports the preliminary experience at a single institution using Gamma Knife ICON™, an advanced gamma knife system for FF GKRS. However, the relatively short follow-up duration and lack of prospective assessment of patients' progress is a limitation. Inconsistent radiological evaluation is another limitation. The effect of histology and radiosensitivity to radiosurgery may also confound the effect of FF GKRS due to the varying histology of patients included in this study. Further, eight patients were treated with concurrent chemotherapy regimen, including ceritinib, gefitinib, and erlotinib, and it is unclear whether tumor response was due to FF GKRS in these patients. The optimal dose and fractionation regimen for brain metastases has yet to be determined.

In this study, we demonstrated that daily application of FF GKRS by Gamma Knife ICON™ to patients with large metastatic brain tumors is an alternative to surgical resection or single-session radiosurgery, especially for patients with large-volume tumors. Daily FF GKRS by Gamma Knife ICON™ showed satisfactory tumor control rate and low morbidity compared to those of fractionated GKRS using frame, despite the short follow-up period. Further prospective studies with longer follow-up of large cohorts of patients diagnosed with brain metastases are required to elucidate the therapeutic effect of FF GKRS.

## REFERENCES

1. Kondziolka D, Martin JJ, Flickinger JC, Friedland DM, Brufsky AM, Baar J, et al. Long-term survivors after gamma knife radiosurgery for brain metastases. *Cancer* 2005;104(12):2784-91.  
[PUBMED](#) | [CROSSREF](#)
2. Yamamoto M, Serizawa T, Shuto T, Akabane A, Higuchi Y, Kawagishi J, et al. Stereotactic radiosurgery for patients with multiple brain metastases (JLKG0901): a multi-institutional prospective observational study. *Lancet Oncol* 2014;15(4):387-95.  
[PUBMED](#) | [CROSSREF](#)
3. McTyre E, Helis CA, Farris M, Wilkins L, Sloan D, Hinson WH, et al. Emerging indications for fractionated gamma knife radiosurgery. *Neurosurgery* 2017;80(2):210-6.  
[PUBMED](#)
4. Nguyen JH, Chen CJ, Lee CC, Yen CP, Xu Z, Schlesinger D, et al. Multisession gamma knife radiosurgery: a preliminary experience with a noninvasive, relocatable frame. *World Neurosurg* 2014;82(6):1256-63.  
[PUBMED](#) | [CROSSREF](#)
5. Devriendt D, De Smedt F, Glineur R, Massager N. Five-fraction Gamma Knife radiosurgery using the Extend relocatable system for benign neoplasms close to optic pathways. *Pract Radiat Oncol* 2015;5(3):e119-25.  
[PUBMED](#) | [CROSSREF](#)
6. Dorenlot A, Champoudry J. 25. End-to-end tests of the new Elekta gamma knife ICON. *Phys Med* 2016;32:353.  
[CROSSREF](#)
7. Obermueller T, Schaeffner M, Gerhardt J, Meyer B, Ringel F, Krieg SM. Risks of postoperative paresis in motor eloquently and non-eloquently located brain metastases. *BMC Cancer* 2014;14(1):21.  
[PUBMED](#) | [CROSSREF](#)
8. Paek SH, Audu PB, Sperling MR, Cho J, Andrews DW. Reevaluation of surgery for the treatment of brain metastases: review of 208 patients with single or multiple brain metastases treated at one institution with modern neurosurgical techniques. *Neurosurgery* 2005;56(5):1021-34.  
[PUBMED](#)
9. Vachhrajani S, Fawaz C, Mathieu D, Ménard C, Cusimano MD, Gentili F, et al. Complications of gamma knife surgery: an early report from 2 Canadian centers. 2008;109 Suppl:2-7.  
[CROSSREF](#)
10. Kim YJ, Cho KH, Kim JY, Lim YK, Min HS, Lee SH, et al. Single-dose versus fractionated stereotactic radiotherapy for brain metastases. *Int J Radiat Oncol Biol Phys* 2011;81(2):483-9.  
[CROSSREF](#)
11. Aoyama H, Shirato H, Onimaru R, Kagei K, Ikeda J, Ishii N, et al. Hypofractionated stereotactic radiotherapy alone without whole-brain irradiation for patients with solitary and oligo brain metastasis using noninvasive fixation of the skull. *Int J Radiat Oncol Biol Phys* 2003;56(3):793-800.  
[CROSSREF](#)
12. Narayana A, Chang J, Yenice K, Chan K, Lymberis S, Brennan C, et al. Hypofractionated stereotactic radiotherapy using intensity-modulated radiotherapy in patients with one or two brain metastases. *Stereotact Funct Neurosurg* 2007;85(2-3):82-7.  
[PUBMED](#) | [CROSSREF](#)
13. Hasegawa T, Kato T, Yamamoto T, Iizuka H, Nishikawa T, Ito H, et al. Multisession gamma knife surgery for large brain metastases. *J Neurooncol* 2017;131(3):517-24.  
[PUBMED](#) | [CROSSREF](#)
14. Sinclair G, Martin H, Fagerlund M, Samadi A, Benmakhlouf H, Doodo E. Adaptive hypofractionated gamma knife radiosurgery in the acute management of large thymic carcinoma brain metastases. *Surg Neurol Int* 2017;8(1):95.  
[PUBMED](#) | [CROSSREF](#)
15. Higuchi Y, Serizawa T, Nagano O, Matsuda S, Ono J, Sato M, et al. Three-Stage Stereotactic Radiotherapy Without Whole Brain Irradiation for Large Metastatic Brain Tumors. *Int J Radiat Oncol Biol Phys* 2009;74(5):1543-8.  
[CROSSREF](#)
16. Kim JW, Park HR, Lee JM, Kim JW, Chung HT, Kim DG, et al. Fractionated stereotactic gamma knife radiosurgery for large brain metastases: A retrospective, single center study. *PLoS One* 2016;11(9):e0163304.  
[PUBMED](#) | [CROSSREF](#)
17. Li W, Bootsma G, Von Schultz O, Carlsson P, Laperriere N, Millar BA, et al. Preliminary evaluation of a novel thermoplastic mask system with intra-fraction motion monitoring for future use with image-guided gamma knife. *Cureus* 2016;8(3):e531.  
[PUBMED](#)

18. Serizawa T, Ono J, Iichi T, Matsuda S, Sato M, Odaki M, et al. Gamma knife radiosurgery for metastatic brain tumors from lung cancer: a comparison between small cell and non-small cell carcinoma. *J Neurosurg* 2002;97(5 Suppl):484-8.  
[PUBMED](#) | [CROSSREF](#)
19. Simonová G, Liscák R, Novotný J Jr, Novotný J. Solitary brain metastases treated with the Leksell gamma knife: prognostic factors for patients. *Radiother Oncol* 2000;57(2):207-13.  
[PUBMED](#) | [CROSSREF](#)
20. Bhatnagar AK, Flickinger JC, Kondziolka D, Lunsford LD. Stereotactic radiosurgery for four or more intracranial metastases. *Int J Radiat Oncol Biol Phys* 2006;64(3):898-903.  
[CROSSREF](#)
21. Lippitz B, Kraepellen T, Hautanen K, Ritzling M, Rähn T, Uffarsson E, et al. Gamma knife radiosurgery for patients with multiple cerebral metastases. *Acta Neurochir Suppl (Wien)* 2004;91:79-87.
22. Shuto T, Fujino H, Inomori S, Nagano H. Repeated gamma knife radiosurgery for multiple metastatic brain tumours. *Acta Neurochir (Wien)* 2004;146(9):989-93.  
[PUBMED](#) | [CROSSREF](#)
23. Elliott RE, Rush S, Morsi A, Mehta N, Spriet J, Narayana A, et al. Neurological complications and symptom resolution following gamma knife surgery for brain metastases 2 cm or smaller in relation to eloquent cortices. *J Neurosurg* 2010;113 Suppl:53-64.  
[PUBMED](#) | [CROSSREF](#)
24. Casentini L, Fornezza U, Perini Z, Perissinotto E, Colombo F. Multisession stereotactic radiosurgery for large vestibular schwannomas. *J Neurosurg* 2015;122(4):818-24.  
[PUBMED](#) | [CROSSREF](#)
25. Kim BS, Im YS, Woo KI, Kim YD, Lee JI. Multisession gamma knife radiosurgery for orbital apex tumors. *World Neurosurg* 2015;84(4):1005-13.  
[PUBMED](#) | [CROSSREF](#)
26. Kim JW, Park HR, Lee JM, Kim JW, Chung HT, Kim DG, et al. Fractionated stereotactic gamma knife radiosurgery for large brain metastases: a retrospective, single center study. *PLoS One* 2016;11(9):e0163304.  
[PUBMED](#) | [CROSSREF](#)