

Elastic intramedullary nailing combined with methylprednisolone acetate injection for treatment of unicameral bone cysts in children: a retrospective study

JianWu Zhou¹
ShangKun Ning²
Yuxi Su²
Chuankang Liu³

Abstract

Purpose The aetiology of unicameral bone cysts (UBCs) is unclear. This study aims to evaluate the feasibility of elastic intramedullary nailing (EIN) combined with injections of methylprednisolone acetate (MPA) for the treatment of UBCs in children.

Methods We retrospectively analyzed 53 children with UBCs in our hospital between January 2010 and April 2016. A total of 24 patients (Group A) were treated by EIN and MPA, whilst

29 patients (Group B) were treated by curettage, bone grafts and EIN fixation. The radiographs of the UBCs were evaluated following the Capanna criteria. All patients were followed-up on the third, sixth, 12th, 24th and 36th months. Fixation time, hospitalization time and complications were evaluated.

Results In Group A, the mean number of MPA injections was 1.8 (1 to 3). Based on radiographic evaluation, eight patients were healed (Capanna grade I), 14 were healed with residual cysts (Capanna grade II), one showed recurrence (Capanna grade III) and one showed no response to the treatment (Capanna grade IV). In Group B, 11 patients were evaluated as Capanna grade I, 12 as Capanna grade II, three as Capanna grade III and three as Capanna grade IV. There was significant difference in the early postoperative function activity ($p < 0.001$), hospitalization time ($p = 0.028$), blood loss during surgery ($p < 0.001$) and surgery time ($p < 0.001$).

Conclusion The combination of EIN and MPA for the treatment of UBCs in children is feasible, has little operative trauma, short surgery time, short hospitalization time, less blood loss and a low risk of incision infection.

Level of evidence: III

Cite this article: Zhou J, Ning S, Su Y, Liu C. Elastic intramedullary nailing combined with methylprednisolone acetate injection for treatment of unicameral bone cysts in children: a retrospective study. *J Child Orthop* 2021;15:55-62. DOI: 10.1302/1863-2548.15.200184

Keywords: unicameral bone cysts; methylprednisolone acetate; elastic intramedullary nailing; children

Introduction

Unicameral bone cysts (UBCs) are benign lesions occurring in children and adolescents, located mainly in the metaphysis of long bones.¹ They form approximately 3% of all primary neoplastic bone lesions in the below 20 years of age group.^{2,3} Although a UBC is currently considered a self-limiting lesion, pathological fractures are the most common complication, making it essential to undertake aggressive surgical treatment.^{2,4} Currently, the most common treatment method is curettage of the cyst

¹ Department of Oncology; Chongqing Key Laboratory of Pediatrics; Ministry of Education Key Laboratory of Child Development and Disorders; National Clinical Research Center for Child Health and Disorders; China International Science and Technology Cooperation Base of Child Development and Critical Disorders; Children's Hospital of Chongqing Medical University, Chongqing, China

² Department of Orthopedics, Chongqing Key Laboratory of Pediatrics, Ministry of Education Key Laboratory of Child Development and Disorders, National Clinical Research Center for Child Health and Disorders; China International Science and Technology Cooperation Base of Child Development and Critical Disorders, The Children's Hospital of Chongqing Medical University, Chongqing, China

³ Department of Traumatology, Chongqing Key Laboratory of Pediatrics, Ministry of Education Key Laboratory of Child Development and Disorders, National Clinical Research Center for Child Health and Disorders; China International Science and Technology Cooperation Base of Child Development and Critical Disorders, The Children's Hospital of Chongqing Medical University, Chongqing, China

Correspondence should be sent to Yuxi Su, Children's Hospital of Chongqing Medical University, 136# Zhongshan 2road Yuzhong District, Chongqing, 400014, China.

E-mail: suyuxi@hospital.cqmu.edu.cn

and

Chuankang Liu, Children's Hospital of Chongqing Medical University, 136# Zhongshan 2road Yuzhong District, Chongqing, 400014, China.

Email:liuchuankang@126.com

with autologous or allogenic bone grafting; this was first proposed by Neer et al⁵ in 1970. Another method is the injection of various materials such as methylprednisolone acetate (MPA), autologous bone marrow and demineralized bone matrix.⁶ In recent years, drainage using screws or modified cement blocker along with drainage has been proved effective.^{4,7,8} However, the latter had a 23.9% failure rate with either cyst recurrence or no response to treatment.⁹

To date, there have been many theories and no consensus on the pathogenesis of UBCs.¹⁰ Among the theories, two are widely accepted by most surgeons. The first is blocked fluid drainage causing pressure changes; therefore, the treatment method is to destroy the local venous obstruction by aspiration, curettage, screw-assisted continuous drainage, elastic intramedullary nailing (EIN) or intra-drainage.^{8,9,11} However, all the above treatments still showed recurrences.¹² Another theory is related to the balance of osteoclasts and osteoblasts derived from human bone marrow stromal cells. The increased level of Prostaglandin E₂ (PGE₂) within a UBC and the good outcomes using steroid and bone marrow injections also proved that osteoclasts and osteoblasts play an important role in UBC formation.^{9,12,13} However, the above treatments also showed recurrences. Thus, we postulated that both the theories participate in the formation of the UBC. Recently, a combination of these two theories has received increased popularity. A previous study at our clinical centre proved that EIN combined with curettage and bone grafts had a good outcome, and the cure rate was as high as 90.0%.¹⁴ In this study, we try to evaluate a minimally invasive method which includes a combination of EIN and MPA to treat the UBC.

Minimally invasive operations or conservative treatments are always the best choice for patients. EIN combined with open surgery and bone grafts involves an open skin incision for a long duration and is invasive. Since a UBC is a benign tumour, no emergent operation is needed for the treatment. To the best of our knowledge, this is the first retrospective comparative study that aims to evaluate the feasibility of EIN combined with MPA for the treatment of UBCs in children.

Patients and methods

Patients

We performed a retrospective analysis using data on 53 patients with UBCs treated at our hospital between January 2010 and April 2016. The inclusion criteria were: patient's age < 18 years, UBC diagnosed based on postoperative pathology, UBC located at the proximal humerus (active UBC or with pathological fractures) or proximal femur, treatment by EIN fixation combined with injections of MPA or cyst curettage bone graft and followed-up for > 36 months. The exclusion criteria were as follows: incomplete clinical data, loss to follow-up, treatment by methods other than EIN combination, UBC not located on the humerus or femur, other tumours such as aneurysmal bone cyst and fibrous dysplasia. Group A was comprised of 24 patients (18 boys, six girls) with a mean age of 7.6 years (SD 3.9) who were treated with EIN combined with MPA injections. Group B consisted of 29 patients (21 boys, eight girls) with a mean age of 8.1 years (SD 3.7) who were treated with EIN and allogeneic bone. This study was approved by the ethics committee of our hospital.

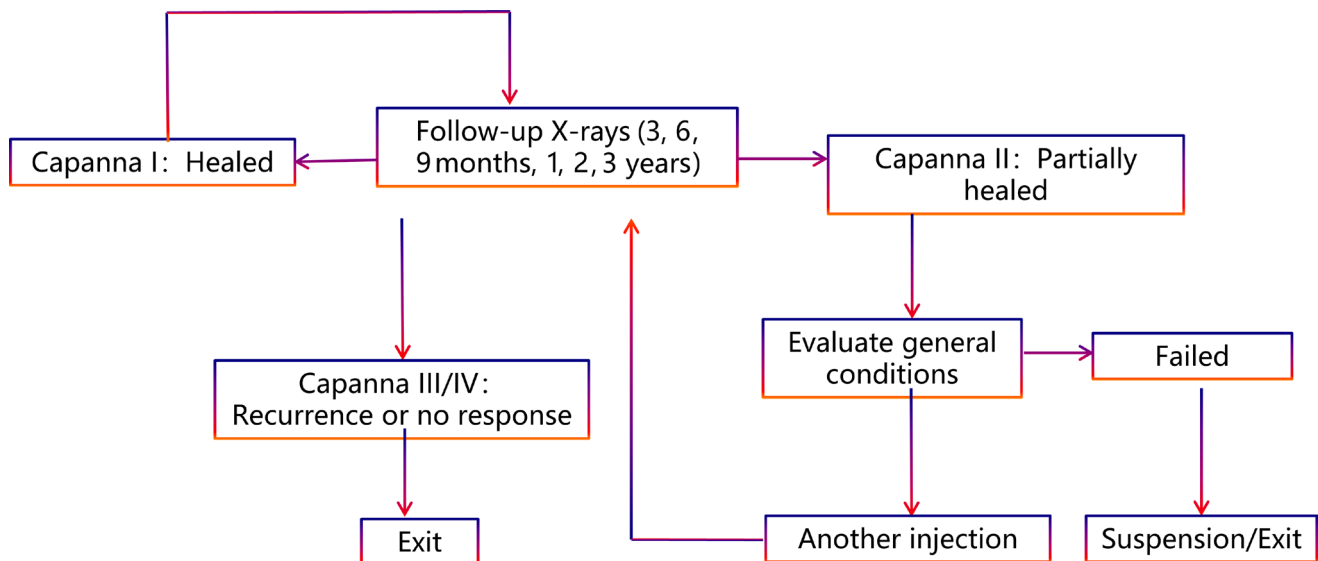


Fig. 1 Postoperative follow-up and exit procedures.

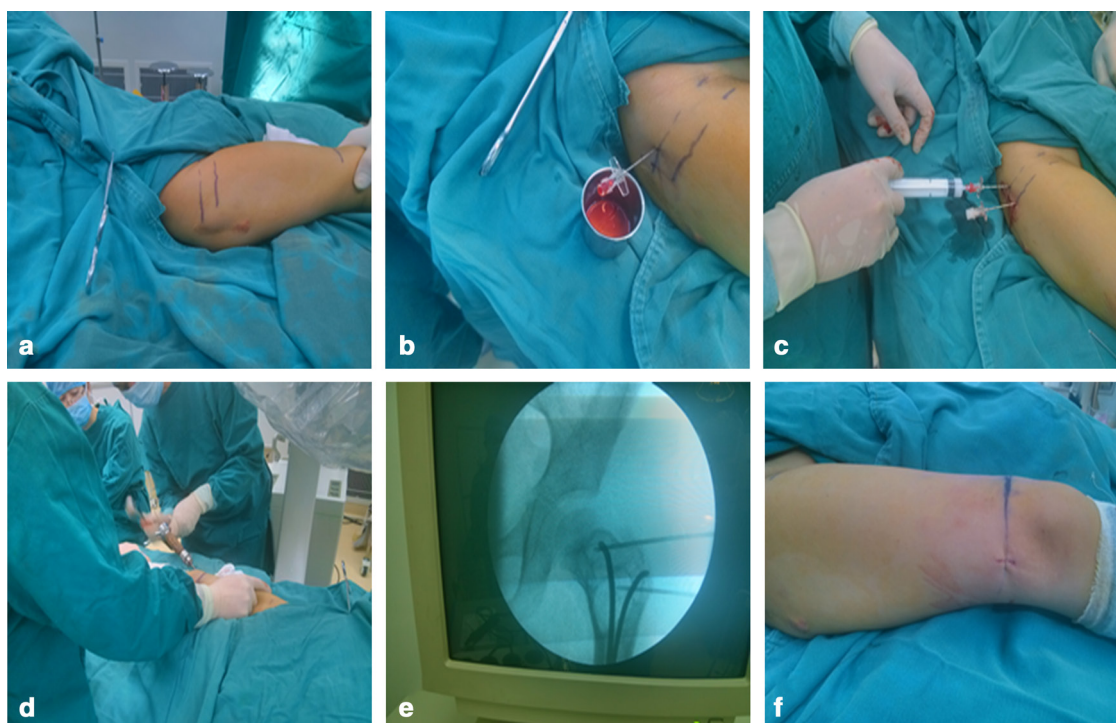


Fig. 2 Surgical procedures: **a)** marking puncture points under C-arm guidance; **b)** puncturing to aspirate fluid; **c)** wall cell inactivation by dehydrated alcohol and intracavitary injection of methylprednisolone acetate; **d)** placing of elastic intramedullary nails (EINs); **e)** adjusting positions of EINs under C-arm guidance; and **f)** stitching and bandaging.

Informed consent forms were signed by the children's parents before the initiation of the study. Our study was in accordance with the ethical standards of the institutional research committee and with the 1964 Helsinki declaration and its later amendments or comparable ethical standards.

Surgical details

For Group A patients, after general anaesthesia, C-arm fluoroscopy was used to make puncture marks on the upper and lower limits of the cyst, after which the cyst was perforated through the two marked puncture points and fluid was aspirated with a 50-mL syringe. We used dehydrated alcohol to irrigate between the two puncture points, and it was left in the cyst cavity for 10 minutes to ensure full dehydration and death of the wall cells. The volume of the UBC was evaluated by radiograph or CT; during the surgery, most of the dose of the UBC was 50 mL to 100 mL. We then used normal saline, repeating the above-mentioned steps twice to wash away the dehydrated alcohol and rinse the wall tissues inactivated by the dehydrated alcohol. An intracavitary injection of MPA (Fig. 1c) was administered using the same procedure as that used for the tissue inactivation by dehydrated alcohol. The volume of the drug injected was 3 mL to 5 mL (75 mg to 125 mg), depending on the size of the cyst and the weight

of the patient; the doses of MPA were mostly calculated by weight (25 mg per 10 kg, with a maximum dose of 125 mg). After making two 0.5-cm to 1.0-cm incisions medially and laterally near the distal end of the involved long bone, elastic nails were placed into the medullary cavity from each of the two incisions (Fig. 1d) until the nails approached the epiphyseal plate. Under C-arm guidance, the distal ends of the nails were advanced to perforate the bone cortex and epiphysis (Fig. 1e). The diameter of the ESIN was about 40% of that of the long bone. One stitch was inserted at each incision (Fig. 1f) and pressure bandaging was applied to the puncture points. If the patients had pathological fractures before surgery, braces were used for two to four weeks postoperatively.

For Group B patients, after the general anaesthesia, an incision was made according to the location of the UBC. The cortex of the UBC was opened, and cystic fluid was aspirated for pathological examination. Dehydrated alcohol was used to inactivate the membrane tumour cells, ensuring that the wall of the UBC and the inner wall membrane were entirely destroyed. Thereafter, the EINs were inserted from the distal femur or humerus, the allogeneic bone was used to fill the cavity of UBC and the incisions were finally closed. All patients were fixed with braces for two to four weeks depending on whether they had pathological fractures.

Table 1 Patients' demographic details and evaluation of the outcomes and complications

	Group A (steroid + EIN)	Group B (bone graft + EIN)	p-value: **
Patients	24	29	
Male	18	21	0.832
Female	6	8	
Age, yrs (sd)	7.6 (3.9)	8.1 (3.7)	0.758
UBC located area			
Proximal humerus	14	16	0.817
Proximal femur	10	13	
Pathological fractures	14	15	
Active UBC	13	17	0.745
Latent UBC	11	12	
Vacuum sealing drainage	31	37	
Hospitalization time, days (sd)	8.6 (2.7)	11.3 (2.2)	0.028
Postoperative activity, days (sd)	12.8 (5.1)	21.7 (6.3)	< 0.001
Capanna criteria			
Capanna I	8	11	0.537
Capanna II	14	12	
Capanna III	1	3	
Capanna IV	1	3	
Complications			
Incision-related infections	0	3	
Incision scars obvious	2	3	
Blood loss during surgery, mL (sd)	10.1 (13.5)	87.9 (28.9)	< 0.001
Recurrent fractures	0	0	

EIN, elastic intramedullary nailing; UBC, unicameral bone cysts

*Chi-square test or Fisher exact test and independent t-tests were used to compare data in categorical or continuous variables, respectively

**p < 0.05 was considered statistically significant

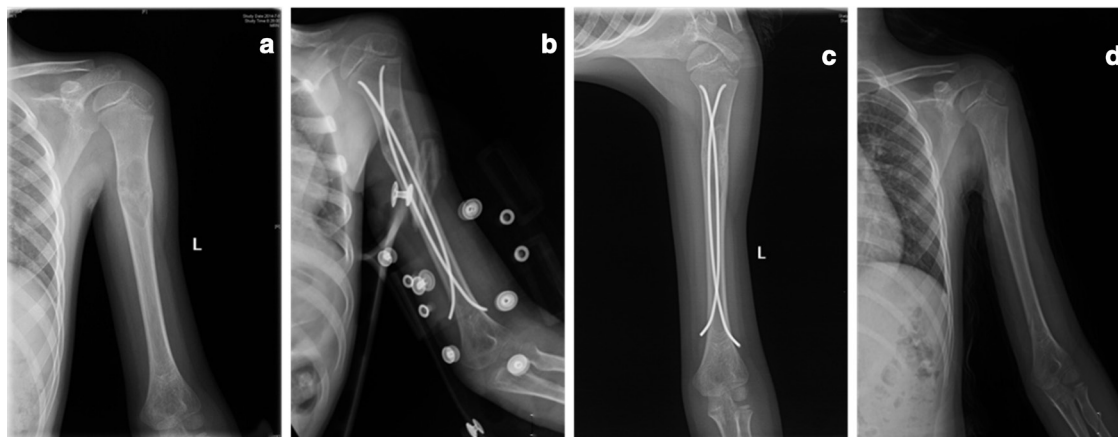


Fig. 3 Male aged eight years and three months, unicameral bone cyst at left humerus proximal, one injection, healed (Capanna grade I). Elastic intramedullary nails removed seven months after surgery: **a**) radiograph of left humerus preoperative; **b**) radiograph after one day; **c**) radiograph after four months; **d**) radiograph after eight months.

Follow-up and evaluation

In Group A, all the patients were treated according to the flow outlined in Figure 2 and were followed-up for at least 12 months or until totally cured. In Group B, all the patients were evaluated by radiographs as executed in Group A. The prognosis was evaluated using Capanna criteria.¹⁵ Grade I means 'healed', lateral radiographs showed the cyst cavity was completely filled with bone and the cortical margin had thickened; Grade II 'healed with residual cyst', the cyst was consolidated with bone and the cortical margin was thickened but parts of residual cyst remained; Grade III 'recurrence', the cyst initially consolidated with bone but large areas of osteolysis and cortical thinning subsequently recurred; and Grade IV 'no response', the

cyst showed no evidence of response to treatment. The ESINs were removed after the cyst was completely consolidated (Capanna I) as shown by the radiographs. The Statistics software SPSS (IBM Corp., Armonk, N.Y., USA) was used for analysis. The Chi-square test or Fisher exact test were used for categorical variables and independent t-tests were used for continuous variables. A value of p < 0.05 was considered as statistically difference.

Results

A total of 53 children (39 male, four female) were included in this study (Table 1). There were no significant differences in sex, age, UBC location or pathological fractures

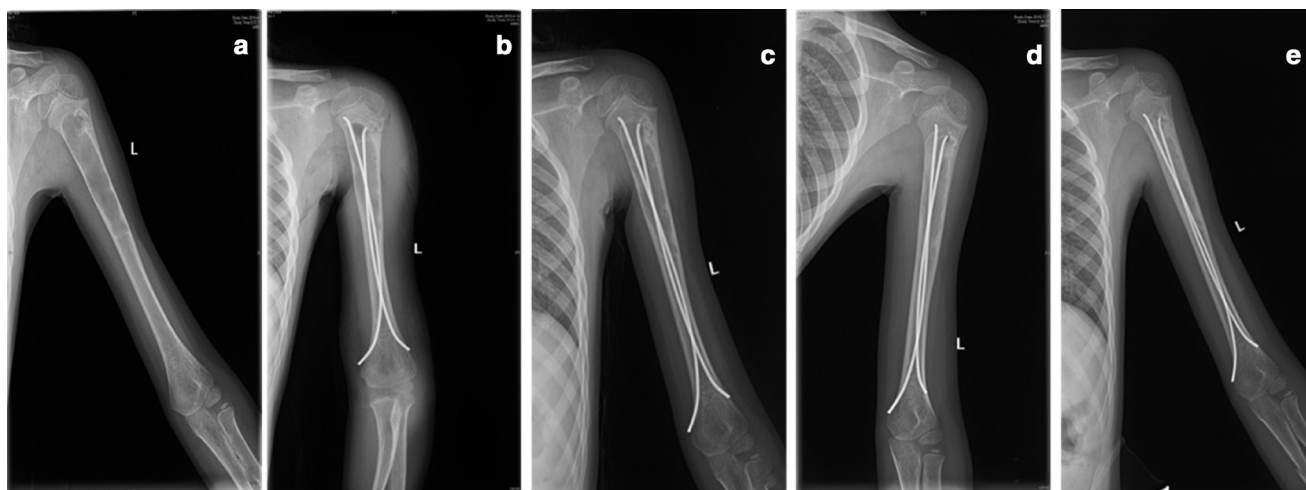


Fig. 4 Male aged seven years and seven months, unicameral bone cyst at left humerus proximal, two injections, partially healed (Capanna II). Another injection of methylprednisolone acetate administered three months after surgery: **a)** radiograph of left humerus preoperative; **b)** radiograph after one day; **c)** radiograph after two months; **d)** radiograph after three months; **e)** radiograph after six months.

Table 2 Evaluation of the outcomes and complications of proximal femur UBCs

	Group A (steroid + EIN)	Group B (bone graft + EIN)	p-value*
Patients	10	13	
Male	8	9	0.660
Female	2	4	
Age, yrs (sd)	8.1 (3.3)	9.5 (3.9)	0.614
Pathological fractures	7	9	
Active UBC	6	9	0.685
Latent UBC	4	4	
Hospitalization time, days (sd)	9.1 (1.9)	12.5(2.9)	0.025
Postoperative activity, days (sd)	14.6(6.6)	23.9 (9.1)	< 0.001
Capanna criteria			
Capanna I	3	4	0.776
Capanna II	6	6	
Capanna III	1	2	
Capanna IV	0	1	
Complications			
Incision-related infections	0	2	
Incision scars obvious	1	2	
Blood loss during surgery, mL (sd)	10.1 (13.5)	119.5 (33.7)	< 0.001
Recurrent fractures	0	0	

EIN, elastic intramedullary nailing; UBC, unicameral bone cyst

*Chi-square test or Fisher exact test and independent t-tests were used to compare data in categorical or continuous variables, respectively

**p < 0.05 was considered statistically significant

(Table 1). The follow-up time for both groups was > 36 months. All patients in Group A showed partial consolidation at a follow-up after two to three months postoperatively, and significant bone growth was observed on radiographs at a four-month follow-up. Complete consolidation of the cysts was detected six to eight months postoperatively. The mean number of MPA injections was 1.8 times (1 to 3). According to the Capanna criteria, eight patients were healed (Capanna I), 14 were healed with residual cysts (Capanna II), one showed recurrence (Capanna III) and one showed no response to treatment (Capanna IV). In Group B, 11, 12, three and three patients

were evaluated to be Capanna I, II, III, and IV, respectively. There were significant differences in the early postoperative function activity ($p < 0.001$), hospitalization time ($p = 0.028$), blood loss during surgery ($p < 0.001$) and surgery time ($p < 0.001$). The external fixation could be removed one to two weeks after surgery and the activity of affected extremities was resumed two to four weeks after surgery for Group A (Figs 3 and 4) compared with four to six weeks for Group B ($p = 0.014$). Patients in Group A had no postoperative pathological fractures, wound infections, skeletal deformities during growth or side effects from steroid pulse therapy, such as bone marrow

suppression, immunosuppression or osteoporosis. Three patients in Group B had incision infections, all of which healed after oral antibiotic drug treatment. There were no recurrent fractures observed in either group. Treatment of the lower limbs varied because of the need for weight bearing. Table 2 shows the results of patients with femur UBCs, which were similar to those of the overall cohort.

Discussion

Our study proved that EIN combined with MPA injection not only leads to little operative trauma but also less complications. In this study, we hoped to establish a new method that not only achieves higher healing and lower recurrence rates, but also minimal invasiveness. Based on this principle, this study focused on resolving the main clinical symptoms in children and preventing complications and recurrence of cysts.

Currently the aetiology and pathogenesis of UBCs are uncertain. Several factors may be involved: i) epiphyseal plate injury leading to disorder of osteogenesis function;^{13,16} ii) Interleukin 1 beta, PGE2, oxygen free radicals and lysosomes in the cyst fluid destroying bone tissue; and iii) pressure build-up in the cyst due to venous obstruction in the bone, destroying bone tissue.^{1,10,17} Because the aetiology is not completely elucidated, surgery performed on the basis of one theory might result in a recurrence. Steroid injection and autologous bone marrow injections aim at inducing the differentiation of the osteogenesis. EIN or screws aim at decompression while curettage with a different type of bone graft aims at decompression and destroying the bone tissue. In this study, we combined the EIN and MPA and verified that our method was minimally invasive and had the lowest recurrence rate.

The reason we chose EIN is that treatment and prevention of pathological fractures are extremely important. At present, most therapies aim for the alleviation of clinical symptoms (by decompression and fenestrated drainage) and treatment of the cyst itself, and there are very few reports on the treatment and prevention of pathological fractures. It is reported that, among children with UBC, approximately 80% were found to have pathological fractures as a primary symptom.¹⁸ EIN has been widely used in fixation of children's fractures, including those of the femur, tibia, humerus, radius and ulna. It has been proven that EIN is safe and minimally invasive, and is recommended by the American Academy of Orthopedic Surgeons.¹⁹⁻²² EIN in our study had three effects. First, it effectively prevented and fixed the pathological fractures. Second, it had the effect of continuous inner decompression drainage of the UBC; some studies suggest that using cannulated screws can depress the UBC.^{8,9} However, the cannulated screws may easily be obstructed because the periosteum is located in this area. For the EIN fixation studies, the sim-

ple EIN had a good effect on the treatment of the UBC.⁷ The inserted nails established a passage between the medullary and cyst cavity, achieving cyst decompression. This function is based on the same theory as decompression through cannulated screws in cases of venous obstruction. The internal drainage effect of EIN is continuous, can last a long time for continuous decompression of the UBC. Finally, a large amount of mesenchymal stem cell in the medullary cavity can be introduced into the cystic cavity to promote the differentiation and proliferation of osteoblasts and, thus, the consolidation of the cyst; however, this should be further demonstrated in a future study.

The reasons we chose MPA are as follows. Firstly, we agree with Scaglietti et al⁶ that microcrystals of corticoids can dissolve and destroy the connective tissue of the cyst wall, as well as help neighborhood capillaries to grow into the cavity and thereby promote consolidation of the UBC. Secondly, according to Shindell et al,²³ MPA can reduce the level of PGE2 in the cyst fluid, thus reducing stimulation of osteoclasts and, accordingly, occurrence of osteolysis. Thirdly, compared with marrow, steroids are more accessible, will not cause secondary trauma to the patient and are not limited by dose. Moreover, they are much more economical and convenient than demineralized bone matrix.

Based on the principle of minimally invasive treatment, this study proposed a comprehensive EIN treatment combined with MPA. After over three years of follow-up, we found that this surgical method has many advantages over the traditional one comprising of cyst wall curettage, grafting and EIN. Firstly, it is minimally invasive with only two 1-cm skin incisions required for the placement of EIN with almost no bleeding. Secondly, postoperative complications are rare, with almost no reported wound infection, bleeding, rejection or disorder and deformity in bone growth of the affected extremities. It is especially advantageous for femoral neck cysts, which are predisposed to coxa vara or coxa valgus if treated with conventional open surgery. Thirdly, the materials are cheap and easily accessible. The autologous implants are usually taken from the ilium and the amount implanted is very limited. For artificial bone substitute, both the price and the incidence of rejection is high. Fourthly, no mechanical injury is caused intraoperatively to the cyst wall, and the surrounding bone is relatively complete ensuring short immobilization of the patients, early removal of external fixation and early beginning of functional articular exercise and resumption of daily life.

Cystography is beneficial before percutaneous injection into the UBC as it provides both morphological and functional information on the UBC.^{24,25} However, in our study, we did not perform cystography using contrast agents. Fortunately, none of the patients developed pulmonary embolisms or other obvious complications during

injection. This was mainly due to the following reasons. First, we did not inject contrast agents or non-soluble substances into the medullar cavity, using instead dehydrated alcohol, MPA and normal saline. Secondly, we did not increase the medullar cavity's pressure, with two punched points on the UBC and only drainage of the UBC. Lastly, for the last step of EIN fixation, the nail was inserted into the UBC. Nevertheless, we stress that secondary pulmonary embolisms are one of the most severe complications of surgery and that surgeons and anaesthetists should be extra attentive when performed the injection.

Our study had several limitations: First, we did not study the effect of injection volumes, and only used relative estimations based on the body weight of the patients and the size of the cyst. This may be an important factor in cyst consolidation. Further study is required to determine whether the injection volume can be increased and whether the interval between two injections should be prolonged. Secondly, with EIN for internal immobilization, patients required removal of EIN. Thirdly, we had only one comparison group. Reddy et al²⁶ reported that curepsy and depression can achieve good outcomes in the treatment of aneurysmal bone cysts. Since we did not use this approach in this study, further comparative studies are needed to determine if this method, among others, can be useful in the treatment of UBC. Fourthly, this is a retrospective study; a prospective study may further be needed to overcome bias.

Conclusion

The combination of EIN and MPA for the treatment of UBCs in children is feasible, has little operative trauma, short surgery time, short hospitalization time, less blood loss and a low risk of incision infection. It is an effective treatment for children with UBCs, especially for those with pathological fractures and large cysts. It also enables fast relief of symptoms, effective treatment of UBCs, healing of pathological fractures, prevention of recurrence and early resumption of functional exercise of the affected extremities.

Received 1 September 2020; accepted after revision 12 December 2020.

COMPLIANCE WITH ETHICAL STANDARDS

FUNDING STATEMENT

No benefits in any form have been received or will be received from a commercial party related directly or indirectly to the subject of this article.

OA LICENCE TEXT

This article is distributed under the terms of the Creative Commons Attribution-Non Commercial 4.0 International (CC BY-NC 4.0) licence (<https://creativecommons.org/licenses/by-nc/4.0/>) which permits non-commercial use, reproduction and distribution of the work without further permission provided the original work is attributed.

licenses/by-nc/4.0/) which permits non-commercial use, reproduction and distribution of the work without further permission provided the original work is attributed.

ETHICAL STATEMENT

Ethical approval: This article does not contain any studies with human participants or animals performed by any of the authors.

Informed consent: Informed consent was obtained from all individual participants included in the study.

ICMJE CONFLICT OF INTEREST STATEMENT

None declared.

AUTHOR CONTRIBUTIONS

YS: Drafted the manuscript, Helped CL conceived the study.

SN: Participated in study design.

JZ: Helped in collecting the clinical data, Drafted the manuscript, Performed the statistical analysis.

CL: Conceived the study, Helped JZ draft the manuscript, Performed surgery.

All authors read and approved the final manuscript.

REFERENCES

1. **Mascard E, Gomez-Brouchet A, Lambot K.** Bone cysts: unicameral and aneurysmal bone cyst. *Orthop Traumatol Surg Res* 2015;101 (suppl):S119-S127.
2. **Hou HY, Wu K, Wang CT, et al.** Treatment of unicameral bone cyst: surgical technique. *J Bone Joint Surg [Am]* 2011;93-A(suppl 1):92-99.
3. **Jamshidi K, Mirkazemi M, Izanloo A, Mirzaei A.** Locking plate and fibular strut-graft augmentation in the reconstruction of unicameral bone cyst of proximal femur in the paediatric population. *Int Orthop* 2018;42:169-174.
4. **Hou HY, Wu K, Wang CT, et al.** Treatment of unicameral bone cyst: a comparative study of selected techniques. *J Bone Joint Surg [Am]* 2010;92-A:855-862.
5. **Neer CS, Francis KC, Johnston AD, Kiernan HA Jr.** Current concepts on the treatment of solitary unicameral bone cyst. *Clin Orthop Relat Res* 1973;97:40-51.
6. **Scaglietti O, Marchetti PG, Bartolozzi P.** The effects of methylprednisolone acetate in the treatment of bone cysts. Results of three years follow-up. *J Bone Joint Surg [Br]* 1979;61-B:200-204.
7. **de Sanctis N, Andreacchio A.** Elastic stable intramedullary nailing is the best treatment of unicameral bone cysts of the long bones in children?: prospective long-term follow-up study. *J Pediatr Orthop* 2006;26:520-525.
8. **Zaghloul A, Haddad B, Khan W, Grimes L, Tucker K.** A novel minimally invasive technique for treatment of unicameral bone cysts. *Open Orthop J* 2015;9:475-479.
9. **Kadhim M, Thacker M, Kadhim A, Holmes L Jr.** Treatment of unicameral bone cyst: systematic review and meta analysis. *J Child Orthop* 2014;8:171-191.
10. **Aarvold A, Smith JO, Tayton ER, et al.** The role of osteoblast cells in the pathogenesis of unicameral bone cysts. *J Child Orthop* 2012;6:339-346.
11. **Mavčič B, Saraph V, Gilg MM, et al.** Comparison of three surgical treatment options for unicameral bone cysts in humerus. *J Pediatr Orthop B* 2019;28:51-56.
12. **Li W, Xu R, Du M, Chen H.** Comparison of titanium elastic intramedullary nailing versus injection of bone marrow in treatment of simple bone cysts in children: a retrospective study. *BMC Musculoskelet Disord* 2016;17:343.
13. **Lee SY, Chung CY, Lee KM, et al.** Determining the best treatment for simple bone cyst: a decision analysis. *Clin Orthop Surg* 2014;6:62-71.

14. **Zhang K, Wang Z, Zhang Z.** Comparison of curettage and bone grafting combined with elastic intramedullary nailing vs curettage and bone grafting in the treatment of long bone cysts in children. *Medicine (Baltimore)* 2019;98:e16152.
15. **Capanna R, Dal Monte A, Gitelis S, Campanacci M.** The natural history of unicameral bone cyst after steroid injection. *Clin Orthop Relat Res* 1982;166:204-211.
16. **Rosenblatt J, Koder A.** Understanding unicameral and aneurysmal bone cysts. *Pediatr Rev* 2019;40:51-59.
17. **Noordin S, Allana S, Umer M, et al.** Unicameral bone cysts: current concepts. *Ann Med Surg (Lond)* 2018;34:43-49.
18. **Kim MC, Joo SD, Jung ST.** The role of fractures on pathologic bone in healing of proximal humerus unicameral bone cysts. *J Orthop Surg (Hong Kong)* 2018;26:2309499018778366.
19. **Marengo L, Nasto LA, Michelis MB, et al.** Elastic stable intramedullary nailing (ESIN) in paediatric femur and tibia shaft fractures: Comparison between titanium and stainless steel nails. *Injury* 2018;49:S8-S11.
20. **Zhang YT, Jin D, Niu J, et al.** A meta-analysis of external fixation and flexible intramedullary nails for femoral fractures in children. *Acta Orthop Belg* 2016;82:673-680.
21. **Shemshaki HR, Mousavi H, Salehi G, Eshaghi MA.** Titanium elastic nailing versus hip spica cast in treatment of femoral-shaft fractures in children. *J Orthop Traumatol* 2011;12:45-48.
22. **Barlas K, Beg H.** Flexible intramedullary nailing versus external fixation of paediatric femoral fractures. *Acta Orthop Belg* 2006;72:159-163.
23. **Shindell R, Connolly JF, Lippiello L.** Prostaglandin levels in a unicameral bone cyst treated by corticosteroid injection. *J Pediatr Orthop* 1987;7:210-212.
24. **Ramirez A, Abril JC, Touza A.** Unicameral bone cyst: radiographic assessment of venous outflow by cystography as a prognostic index. *J Pediatr Orthop B* 2012;21:489-494.
25. **Yandow SM, Marley LD, Fillman RR, Galloway KS.** Precordial Doppler evaluation of simple bone cyst injection. *J Pediatr Orthop* 2009;29:196-200.
26. **Reddy KI, Sinnaeve F, Gaston CL, Grimer RJ, Carter SR.** Aneurysmal bone cysts: do simple treatments work? *Clin Orthop Relat Res* 2014;472:1901-1910.