

Oncology

Urothelial carcinoma within the prostatic utricle of an adult with hypospadias and Fanconi anemia

Kevin Pineault^{*}, Ridwan Alam, Alexa Meyer, Michael H. Johnson

The James Buchanan Brady Urological Institute, Johns Hopkins Hospital, 600 N. Wolfe St., Baltimore, MD, 21287, USA

ARTICLE INFO

Keywords:

Urothelial carcinoma
Prostatic utricle
Fanconi anemia
Hypospadias

ABSTRACT

Prostatic utricles are rare in the general population and are often otherwise unremarkable anatomic variants. These structures are contiguous with the prostatic urethra and are nevertheless susceptible to urothelial carcinoma. This case report discusses the first reported patient with Fanconi anemia with urothelial carcinoma within an enlarged prostatic utricle.

Introduction

Fanconi anemia is an autosomal recessive disorder involving DNA repair, with associated with defects in spermatogenesis, renal abnormalities, and predisposition for hematologic malignancies.¹ To date, there is no known association between Fanconi anemia and prostatic utricles, a Mullerian duct structure in males homologous to the female vagina, cervix, and uterus. Although exceedingly rare in the general population, malignancies including urothelial carcinoma, clear cell adenocarcinoma, endometrial carcinoma, and squamous cell carcinoma have been reported within prostatic utricles.^{2,3} We report the first known case of urothelial carcinoma in an enlarged prostatic utricle in the setting of a patient with Fanconi anemia.

Case presentation

A 29 year-old man with a past medical history of Fanconi anemia, myelodysplastic syndrome requiring bone marrow transplant, perineal hypospadias requiring multi-stage repair, hypoplastic and bifid left thumbs requiring surgical repair and prosthesis, squamous cell carcinoma of the right lateral tongue requiring excision, hypothyroidism, and depression presented to the urology clinic in June 2019 for follow-up evaluation regarding difficulty voiding with continued straining after urethroplasty in February 2019. His urologic history dates back to December 2015, when his perineal hypospadias was repaired but subsequently complicated by recurrent urethral strictures requiring periodic dilation of the bladder ostium. Eventually, the patient opted for surgical repair in February 2019 with a perineal urethroplasty and

meatoplasty. During this procedure, he was found to have a prominent prostatic utricle. He underwent further exploration in July 2019 with cystoscopy and multiple biopsies of the prostatic urethra and utricle with cytology. Cystoscopy demonstrated multiple papillary tumors within a very large prostatic utricle (Fig. 1; Supplementary Video). Biopsy of the mass revealed invasive high-grade papillary urothelial carcinoma with squamous features. Urine cytology also demonstrated high-grade urothelial carcinoma with squamous differentiation. Following this pathology result, imaging of the abdomen and pelvis with CT and MRI was completed. MRI images (Fig. 2) show a widened prostatic utricle with irregular, enhancing, and near circumferential soft tissue thickening compatible with the patient's biopsy proven urothelial carcinoma. CT scan did not demonstrate evidence of metastatic disease.

Supplementary video related to this article can be found at <https://doi.org/10.1016/j.eucr.2019.101043>

He was presented at a multi-disciplinary tumor board and was recommended to undergo cystoprostatectomy. Transurethral resection was not recommended because of the concern for invasion into the prostatic apex as well as the volume of disease. Prostatectomy was not recommended, given his extensive urethral stricture disease and surgeries. For the same reasons, he was not recommended an orthotopic ileal neobladder following cystoprostatectomy. He elected for an Indiana pouch urinary diversion at the time of cystoprostatectomy. Pathology revealed invasive high-grade urothelial carcinoma with 5% squamous features involving the subepithelial connective tissue smooth muscle beneath the surface of the prostatic urethra, but not invading into the prostatic stroma (Fig. 3). All lymph nodes and surgical margins were negative for malignancy.

^{*} Corresponding author. The James Buchanan Brady Urological Institute, Johns Hopkins Hospital, Park Building 217, 600 N. Wolfe St. Baltimore, MD, 21287, USA.
E-mail address: kpineau1@jhmi.edu (K. Pineault).

<https://doi.org/10.1016/j.eucr.2019.101043>

Received 7 September 2019; Received in revised form 8 October 2019; Accepted 11 October 2019

Available online 15 October 2019

2214-4420/© 2019 The Authors.

Published by Elsevier Inc.

This is an open access article under the CC BY-NC-ND license

(<http://creativecommons.org/licenses/by-nc-nd/4.0/>).

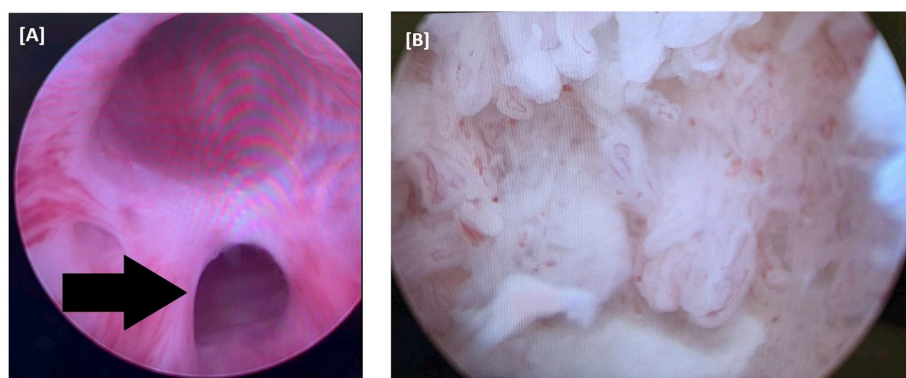


Fig. 1. Cystoscopy of prostatic utricle

Images from cystoscopy demonstrating [A] an enlarged prostatic utricle (marked by arrow) with concurrent visualization of the urethra superiorly and [B] multiple papillary tumors within the prostatic utricle.

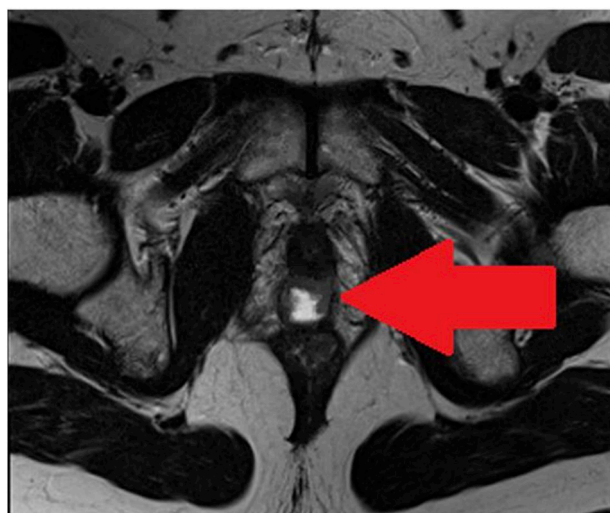


Fig. 2. MRI of prostatic utricle

MRI image demonstrating the presence of tumors within the prostate, correlating with the patient's known prostatic utricle.

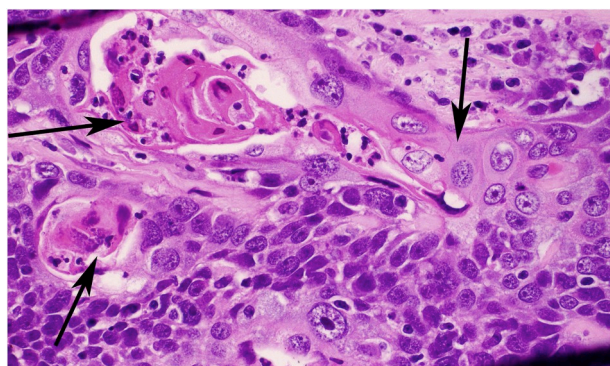


Fig. 3. Histology of urothelial carcinoma within the prostatic utricle

High-power (400x) image of an area with both squamous and urothelial features. The squamous features are indicated by the black arrows. The areas of the tumor showing squamous differentiation are characterized by distinct cell borders with hard, bright pink cytoplasm and focal overt keratinization with formation of squamous pearls. The surrounding urothelial differentiation shows less distinct cell borders, less abundant pink cytoplasm, and lacks keratinization. (For interpretation of the references to colour in this figure legend, the reader is referred to the Web version of this article.)

Discussion

Although physical abnormalities among patients with Fanconi anemia are well described, this is the first report of a patient with Fanconi anemia and a prostatic utricle. In the literature, Fanconi anemia has been associated with absent or malformed kidneys and other defects of the urinary tract; however, presence of a prostatic utricle, let alone the additional presence of urothelial carcinoma within the prostatic utricle, has not been described.¹ Common presenting symptoms of patients with an enlarged prostatic utricle include irritative lower urinary tract symptoms, as in this patient, and hematospermia.⁴ The incidence of an enlarged prostatic utricle is rare in the general population but has been shown to be present in 10–15% of patients with hypospadias or other intersex anomalies.⁵ Devine et al. further observed enlarged utricles in 57% of perineal and 10% of penoscrotal hypospadias patients.⁵ While enlarged prostatic utricles are most commonly benign, Schuhrke et al. reported a 3% incidence of malignancy in a case series of 88 patients with this condition.⁴ Reported malignancies in the prostatic utricle include urothelial carcinoma, clear cell adenocarcinoma, endometrial carcinoma, and squamous cell carcinoma.^{2,3} Although there are no standardized guidelines for these patients, the authors of this report suggest prioritizing management of localized malignancy with surgical resection.

Conclusion

This is the first reported case of urothelial carcinoma of the prostatic utricle in the setting of a patient with Fanconi anemia. Interestingly, Fanconi anemia is associated with other urinary tract abnormalities but has never been associated with an enlarged prostatic utricle. Patients with Fanconi anemia may be at increased risk for both enlarged prostatic utricles and urothelial carcinoma and should be managed with medical and/or surgical therapy as appropriate.

Funding

This research did not receive any specific grant from funding agencies in the public, commercial, or not-for-profit sectors.

Declaration of competing interest

The authors have no conflicts of interest relevant to this article to disclose.

Appendix A. Supplementary data

Supplementary data to this article can be found online at <https://doi.org/10.1016/j.urocr.2020.101043>.

org/10.1016/j.eucr.2019.101043.

References

1. Sathyanarayana V, Lee B, Wright NB, et al. Patterns and frequency of renal abnormalities in fanconi anaemia: implications for long-term management. *Pediatr Nephrol*. 2018;33(9):1547–1551.
2. Gualco G, Ortega V, Ardao G, Cravioto F. Clear cell adenocarcinoma of the prostatic utricle in an adolescent. *Ann Diagn Pathol*. 2005;9(3):153–156.
3. Zhang C, Li X, He Z, Xiao Y, Li S, Zhou L. Squamous cell carcinoma of the enlarged prostatic utricle in an adult. *Urology*. 2012;79(2):23–24.
4. Schuhrke TD, Kaplan GW. Prostatic utricle cysts (müllerian duct cysts). *J Urol*. 1978;119(6):765–767.
5. Devine CJ, Gonzalez-Serva L, Stecker JF, Devine PC, Horton CE. Utricular configuration in hypospadias and intersex. *J Urol*. 1980;123(3):407–411.