



## Original Article

# Septic arthritis and arthropathy of the rotator cuff: remember this association<sup>☆</sup>



Danilo Sobreira<sup>\*</sup>, Neydson de Souza, José Inácio de Almeida, Alberto de Castro Pochini, Carlos Vicente Andreoli, Benno Ejnisman

Universidade Federal de São Paulo, Escola Paulista de Medicina, Departamento de Ortopedia e Traumatologia, Centro de Traumatologia do Esporte, São Paulo, SP, Brazil

## ARTICLE INFO

## Article history:

Received 31 May 2015

Accepted 25 September 2015

Available online 29 June 2016

## Keywords:

Joint diseases

Rotator cuff

Arthritis infectious

Arthroscopy

## ABSTRACT

**Objective:** To describe occurrences of septic glenohumeral arthritis among patients with arthropathy of the rotator cuff, and to highlight the importance of correct diagnosis and surgical procedures.

**Methodology:** Eight surgical drains were installed in seven patients with glenohumeral pyoarthritis. All the patients presented arthropathy of the rotator cuff (four males and three females). Six patients presented pyoarthritis in the dominant shoulder. The age range was from 53 to 93 years (mean: 74 years). The mean duration of the symptoms before the surgical lavage was six weeks. Six patients underwent treatment consisting of a combination of arthroscopic irrigation and debridement, and one patient was treated by means of open arthrotomy. All the patients received systemic antibiotic therapy in accordance with their bacterial sensitivity.

**Results:** All seven patients achieved satisfactory results, taking into consideration especially the improvement of pain and the patients' satisfaction. The functional assessment was performed using the University of California Los Angeles (UCLA) scale. Only one patient needed to go through another arthroscopic procedure. *Staphylococcus aureus* was isolated from four cultures and *Escherichia coli* from one culture. There were two situations in which the patients used empirical antibiotic therapy and the cultures showed negative results. Among the associated procedures, tenotomy of the biceps was performed in four cases, resection of the lateral third of the clavicle due to osteomyelitis in one case and arthrotomy of the knee in one case.

**Conclusion:** Surgical treatment was effective in the cases of arthritis associated with arthropathy of the rotator cuff. In patients with arthropathy of the rotator cuff and subclinically altered laboratory signs, the possibility of pyoarthritis should always be suspected.

© 2016 Published by Elsevier Editora Ltda. on behalf of Sociedade Brasileira de Ortopedia e Traumatologia. This is an open access article under the CC BY-NC-ND license (<http://creativecommons.org/licenses/by-nc-nd/4.0/>).

<sup>☆</sup> Study conducted at the Universidade Federal de São Paulo, Escola Paulista de Medicina, Departamento de Ortopedia e Traumatologia, Centro de Traumatologia do Esporte, São Paulo, SP, Brazil.

<sup>\*</sup> Corresponding author.

E-mail: [danilosobreiraombro@gmail.com](mailto:danosobreiraombro@gmail.com) (D. Sobreira).

<http://dx.doi.org/10.1016/j.rboe.2015.09.016>

2255-4971/© 2016 Published by Elsevier Editora Ltda. on behalf of Sociedade Brasileira de Ortopedia e Traumatologia. This is an open access article under the CC BY-NC-ND license (<http://creativecommons.org/licenses/by-nc-nd/4.0/>).

## Artrite séptica e artropatia do manguito rotador: lembrar-se dessa associação

### R E S U M O

#### Palavras-chave:

Artropatias  
Manguito rotador  
Artrite infecciosa  
Artroscopia

**Objetivo:** Descrever a ocorrência de artrite séptica glenoumeral em pacientes com artropatia do manguito rotador, bem como destacar a importância do correto diagnóstico e procedimento cirúrgico.

**Metologia:** Foram feitas oito drenagens cirúrgicas em sete pacientes com pioartrite glenoumeral. Todos os pacientes apresentavam artropatia do manguito rotador (quatro do sexo masculino e três do feminino). Seis pacientes apresentavam pioartrite no ombro dominante, a idade variou de 53 a 93 anos (média de 74 anos). A duração média dos sintomas antes da lavagem cirúrgica foi de seis semanas. Seis pacientes foram submetidos ao tratamento com a combinação de irrigação artroscópica e desbridamento, um paciente foi tratado por artrotomia aberta. Todos os pacientes receberam antibioticoterapia sistêmica de acordo com a sensibilidade bacteriana.

**Resultados:** Os sete pacientes obtiveram resultados satisfatórios, se levarmos em consideração principalmente a melhoria da dor e a satisfação dos pacientes. A avaliação funcional foi feita por meio da escala da Universidade da Califórnia em Los Angeles (UCLA). Apenas um paciente precisou passar por um novo procedimento artroscópico, em quatro culturas foi isolado o *Staphylococcus aureus*, em uma cultura a *Escherichia coli* e em duas situações, nas quais os pacientes usavam antibioticoterapia empírica, essas culturas tiveram resultado negativo. Entre os procedimentos associados fez-se quatro tenotomias do bíceps, uma ressecção do 1/3 lateral da clavícula devido à osteomielite e uma artrotomia do joelho.

**Conclusão:** O tratamento cirúrgico foi eficaz nos casos de artrite associada a artropatia do manguito rotador. Sempre suspeitar, em pacientes com artropatia do manguito rotador com sinais subclínicos e laboratoriais alterados, da possibilidade de uma pioartrite.

© 2016 Publicado por Elsevier Editora Ltda. em nome de Sociedade Brasileira de Ortopedia e Traumatologia. Este é um artigo Open Access sob uma licença CC BY-NC-ND (<http://creativecommons.org/licenses/by-nc-nd/4.0/>).

## Introduction

Degenerative arthropathy of the rotator cuff is the collapse of the glenohumeral joint secondary to chronic massive rotator cuff injury. It causes elevation of the humeral head, joint destruction, synovial fluid changes, subchondral cysts, flattening of the greater tubercle, osteophytes, acetabularization of the coracoacromial arch, and osteopenia<sup>1,2</sup> (Fig. 1). It manifests as pain, crepitus, and decreased range of motion.<sup>3</sup>

Pyogenic arthritis of the shoulder is characterized by an inflammatory process of infectious origin affecting the glenohumeral joint. Hematogenic route is the most common cause. However, other causes include contiguity, previous surgery, or intra-articular injection.<sup>4,5</sup>

Septic arthritis of the glenohumeral joint is relatively rare, representing 10–15% of all joint infections, and can lead to severe residual limitation with potentially fatal implications.<sup>6</sup> The most commonly found pathogen is *Staphylococcus aureus*, and their enzymes may destroy the auricular cartilage within 24–48 h.<sup>7</sup>

To the best of the authors' knowledge, there are no studies that correlate both conditions. This study aimed to describe the occurrence of septic glenohumeral arthritis in patients with rotator cuff arthropathy, as well as to highlight the

importance of correct diagnosis of infection and early adequate treatment to prevent irreversible changes to both the bone and surrounding soft tissues.

## Methodology

Between May 2009 and March 2014, seven patients with rotator cuff arthropathy developed septic arthritis of the glenohumeral joint and underwent surgical treatment by surgical drainage and systemic antibiotic therapy to the infecting germ. Eight surgical procedures were performed: four patients were male and three were female, whose age ranged from 53 to 93 years (mean 74 years). Associated comorbidities were investigated, and patients were evaluated using the UCLA functional scale three months after the procedure. Six patients were subjected to arthroscopic procedure by combining arthroscopic irrigation and debridement and one was treated with open arthrotomy. The mean interval from symptom onset to surgical debridement was six weeks (range: 15–70 days).

Laboratory tests, X-rays, and magnetic resonance imaging were used as diagnostic methods, as well as intraoperative joint puncture (Fig. 2). Pyogenic arthritis of the shoulder was confirmed by histologic analysis and culture of the material collected during surgery.

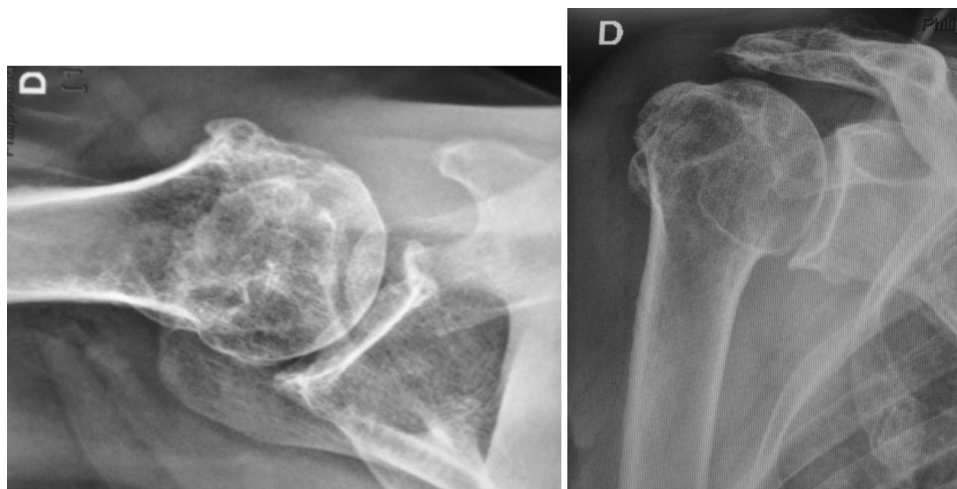


Fig. 1 – X-rays in anteroposterior and axillary incidence of a shoulder with rotator cuff arthropathy.

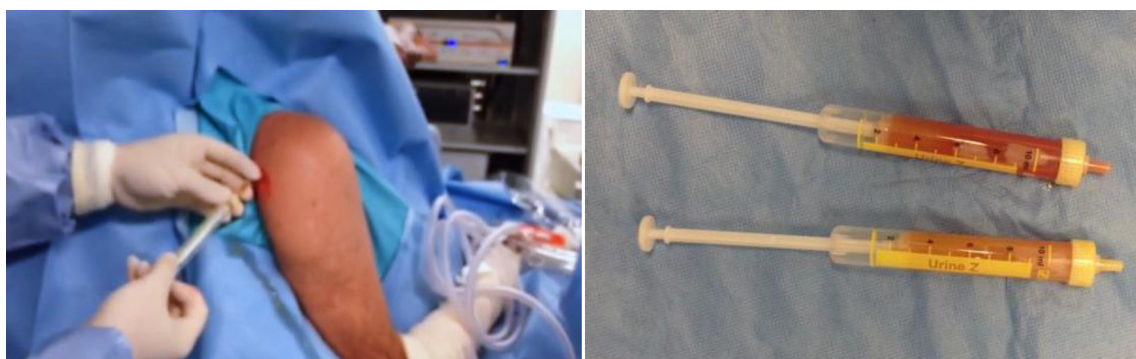

Fig. 2 – Left image shows a puncture in the glenohumeral joint. Right image shows the aspirated purulent liquid.

## Surgical technique

Of the eight joint surgeries, seven were conducted arthroscopically. Arthroscopic debridement of the glenohumeral joint was performed with patient under general anesthesia over beach chair positioning. An arthroscope with 30° angular inclination was introduced through the posterior portal and an initial inspection of the joint was made. Then, a second anterosuperior portal was created in the rotator interval and the joint was irrigated with 10 L of saline solution. Through the anterior portal, a motorized shaver blade was introduced for debridement of the inflamed synovium and of the articular fibrotic tissue. A third lateral portal was created for debridement of the subacromial space.

An open arthrotomy was performed with the patient under general anesthesia over beach chair positioning, using the deltopectoral approach and dissection by layers until joint exploration; devitalized tissue was removed and the joint was irrigated with 10L of saline solution.

## Results

All seven patients in the study had comorbidities: five had type 2 diabetes mellitus, one had chronic liver disease, four had

Table 1 – Comorbidities vs. number of cases.

Comorbidities	Number of cases
Arterial hypertension	Four
Diabetes mellitus	Five
Smoking	Two
Alcoholism	One
Liver disease	One
Infection at another site (pyogenic arthritis of the knee)	One
HIV	One
Osteomyelitis in lateral third of the clavicle	One

arterial hypertension, one had a history of pyogenic arthritis of the knee, one was a chronic alcoholic, two were smokers, one had osteomyelitis at the lateral third of the clavicle, and one was HIV-positive (Table 1).

The following associated procedures were performed intraoperatively: four biceps tenotomies, one resection of the lateral third of the clavicle in the patient with osteomyelitis, and one knee arthrotomy in the patient who had concomitant pyogenic arthritis of the knee; synovectomy and bursectomy were performed in all cases (Table 2).

The agent causing the infection could be isolated in five patients: *Staphylococcus aureus* was the most prevalent, found

**Table 2 – Associated procedures vs. quantity.**

Associated procedure	Quantity
Biceps tenotomy	Four
Resection of the lateral third of the clavicle	One
Knee arthroscopy	One
Synovectomy	All
Bursectomy	All

in four patients, and *Escherichia coli* was observed in one case. The two patients who presented negative cultures were using oral antibiotics.

In six cases, the infection was eradicated with only one surgical procedure. In one patient, a second arthroscopy was necessary due to infection recurrence.

Mean follow-up was 12.2 months (6–24). Mean UCLA score at time of last follow-up was 22 points (15–29). Only one patient was not satisfied with the result.

## Discussion

The term “Milwaukee shoulder syndrome” was first used in 1981 to describe four elderly women in Milwaukee, in the state of Wisconsin, United States, who presented with recurrent bilateral shoulder effusions, radiographic evidence of severe destructive alterations in the glenohumeral joint, and massive rotator cuff injuries.<sup>8,9</sup>

Patients with rotator cuff arthropathy have significant pain, functional limitation, and strength reduction.<sup>4</sup> When these patients develop glenohumeral septic arthritis superimposed by a rotator cuff injury, the pre-existing symptoms may mask the infection.

The authors of the present study believe that infection should be suspected in any patient with a progressive painful condition that primarily affects the shoulder in the presence of elevated inflammatory markers (WBC, CRP, and ESR). History of previous shoulder procedure, whether an infiltration or previous surgery, with subsequent progression of symptoms, should only increase suspicion.

Early diagnosis and treatment of pyogenic arthritis of the glenohumeral joint is essential to prevent irreversible changes to the bone or surrounding soft tissues, thereby avoiding compromising the results of other surgical procedures that may be necessary.<sup>10–12</sup> Jeon et al.,<sup>10</sup> in their retrospective study, demonstrated the safety and efficacy of arthroscopic treatment in 19 patients diagnosed with pyogenic arthritis of the glenohumeral joint. Patients who underwent surgery within two weeks of arthroscopic lavage had better outcomes than those who had symptoms for a longer time. Those authors also observed a high proportion of medical comorbidities, such as diabetes, previous infiltrations in the shoulder, and pre-existing rotator cuff injuries in their sample. However, in that study, the authors did not mention a direct association between the massive rotator cuff injury and pyogenic arthritis.

Arthroscopical treatment of septic arthritis of the shoulder with lavage and debridement has been reported in selected cases after the early diagnostic of infection.<sup>11,12</sup> In turn, an open surgical approach is more commonly performed in cases of late diagnosis or late stages of infection.<sup>13</sup>

Duncan et al. advocate the early detection and proper treatment of pyogenic arthritis of the glenohumeral joint in order to prevent irreversible changes to the bone and surrounding soft tissues.<sup>11</sup>

Abdel et al.<sup>14</sup> observed that most patients with septic arthritis are elderly, immunocompromised, and present increased inflammatory markers. Patients and surgeons should be aware that one in three patients requires additional surgery after primary arthroscopy.

In this literature review, no other studies correlating rotator cuff arthropathy with pyogenic arthritis of the glenohumeral joint were retrieved.

As strengths of the present study, the sample indicated an association that had not been described in the literature, and shows the importance of early diagnosis and treatment of pyogenic arthritis of the glenohumeral joints in patients with rotator cuff arthropathy.

As weaknesses, the small sample size and the short follow-up time in some patients are noteworthy. Also, as the UCLA questionnaire was not applied preoperatively, comparison of clinical outcomes pre and post-treatment was not possible.

## Conclusion

Pyogenic arthritis of the glenohumeral joint should be suspected in patients with rotator cuff arthropathy associated with subclinical and/or laboratory alterations. Surgical treatment should be conducted as early as possible, whether open or arthroscopically.

## Conflicts of interest

The authors declare no conflicts of interest.

## REFERENCES

- Hamada K, Fukuda H, Mikasa M, Kobayashi Y. Roentgenographic findings in massive rotator cuff tears. A long-term observation. *Clin Orthop Relat Res.* 1990;(254):92–6.
- Neer CS, Craig EV, Fukuda H. Cuff-tear arthropathy. *J Bone Joint Surg Am.* 1983;65(9):1232–44.
- Pollock RG, Deliz ED, McIlveen SJ, Flatow EL, Bigliani LU. Prosthetic replacement in rotator cuff-deficient shoulders. *J Shoulder Elbow Surg.* 1992;1(4):173–86.
- Jerosh J. Acute joint infection: diagnosis and treatment. *Orthopade.* 2004;338(11):1309–18.
- Leslie BM, Harries JM 3rd, Driscoll D. Septic arthritis of the shoulder in adults. *J Bone Joint Surg.* 1989;71(10):1516–22.
- Kelly PJ, Coventry MB, Martin WJ. Bacterial arthritis of the shoulder. *Mayo Clin Proc.* 1965;40:695–9.
- Brower AC. Septic arthritis. *Radiol Clin N Am.* 1996;34(2):293–309.
- Garancis JC, Cheung HS, Halverson PB, McCarty DJ. “Milwaukee shoulder” – association of microspheroids containing hydroxyapatite crystals, active collagenase, and neutral protease with rotator cuff defects. III. Morphologic and biochemical studies of an excised synovium showing chondromatosis. *Arthritis Rheum.* 1981;24(3):484–91.
- McCarty DJ, Halverson PB, Carrera GF. Milwaukee shoulder—association of microspheroids containing hydroxyapatite crystals, active collagenase, and neutral

- protease with rotator cuff defects. I: Clinical aspects. *Arthritis Rheum.* 1981;24(3):464-73.
10. Jeon IH, Choi CH, Seo JS, Seo KJ, Ko SH, Park JY. Arthroscopic management of septic arthritis of the shoulder joint. *J Bone Joint Surg Am.* 2006;88(8):1802-6.
  11. Duncan SFM, Sperling JW. Treatment of primary isolated shoulder sepsis in the adult patient. *Clin Orthop Relat Res.* 2008;466:1392-6.
  12. Kirchoff C, Braunstein V, Buhmann S, Oedekoven T, Mutschler W, Biberthaler P. Stage-dependant management of septic arthritis of shoulder in adults. *Int Orthop.* 2009;33(4):1015-24.
  13. Ruhmann O, Schmolke S, Bohnsack M, Flamme C, Wirth CJ. Shoulder arthrodesis: indications, technique, results, and complications. *J Shoulder Elbow Surg.* 2005;14(1):38-50.
  14. Abdel MP, Perry KI, Morrey ME, Steimann SP, Sperling JW, Cass JR. Arthroscopic management of native shoulder septic arthritis. *J Shoulder Elbow Surg.* 2013;22:418-21.