

## Original Article

# Endoscopic endonasal transsphenoidal surgery for patients aged over 80 years with pituitary adenomas: Surgical and follow-up results

Kenji Fujimoto, Shigetoshi Yano, Naoki Shinojima, Takuichiro Hide, Jun-ichi Kuratsu

Department of Neurosurgery, Faculty of Life Sciences, Kumamoto University School of Medicine, Kumamoto, Japan

E-mail: \*Kenji Fujimoto - [schwarz\\_k1216@yahoo.co.jp](mailto:schwarz_k1216@yahoo.co.jp); Shigetoshi Yano - [yanos@kumamoto-u.ac.jp](mailto:yanos@kumamoto-u.ac.jp); Naoki Shinojima - [nshinojima@kuh.kumamoto-u.ac.jp](mailto:nshinojima@kuh.kumamoto-u.ac.jp); Takuichiro Hide - [thide@kuh.kumamoto-u.ac.jp](mailto:thide@kuh.kumamoto-u.ac.jp); Jun-ichi Kuratsu - [j.kuratsu@sakurajyuji.jp](mailto:j.kuratsu@sakurajyuji.jp)

\*Corresponding author

Received: 26 May 17 Accepted: 15 July 17 Published: 06 September 17

## Abstract

**Background:** With the rapid aging of the general population, the number of pituitary adenoma (PA) diagnosed in elderly patients is increasing. The aim of this study was to evaluate the efficacy of endoscopic endonasal transsphenoidal surgery (ETSS) for PA in patients aged  $\geq 80$  years.

**Methods:** We retrospectively reviewed the medical records of all patients aged  $\geq 80$  years who underwent ETSS for PA at our hospital from January 2001 through December 2014. Treatment results were assessed by the extent of surgical removal, symptom improvement, postoperative complications, and Karnofsky performance status (KPS). The results were also compared with the surgical result of PA patients aged  $< 80$  years.

**Results:** Twelve patients aged  $\geq 80$  years underwent ETSS for PA. Recovery of visual function was observed in 11 patients (91.7%). Postoperative cerebrospinal fluid (CSF) leakage was observed in 3 patients. New hormonal replacement therapy was required in 2 patients. These complications had not affected patient prognosis. During the follow-up periods, deterioration of KPS was observed in 2 patients due to pneumonia or cerebral infarction. In total, 150 PA patients aged  $< 80$  years were compared with the patients aged  $\geq 80$  years. The percentage of total removal was significantly higher in the younger patient group than that in the older one (54.0% vs 16.6%, respectively;  $P = 0.016$ ). Visual improvement was observed in 93.2% of the younger patient group, which was almost equal to that in the older one.

**Conclusion:** ETSS is a safe and effective surgical technique in PA patients aged  $\geq 80$  years.

**Key Words:** Eighty years old or over, endoscopic endonasal transsphenoidal surgery, pituitary adenoma

### Access this article online

**Website:**[www.surgicalneurologyint.com](http://www.surgicalneurologyint.com)**DOI:**

10.4103/sni.sni\_189\_17

**Quick Response Code:**

This is an open access article distributed under the terms of the Creative Commons Attribution-NonCommercial-ShareAlike 3.0 License, which allows others to remix, tweak, and build upon the work non-commercially, as long as the author is credited and the new creations are licensed under the identical terms.

**For reprints contact:** [reprints@medknow.com](mailto:reprints@medknow.com)

**How to cite this article:** Fujimoto K, Yano S, Shinojima N, Hide T, Kuratsu J. Endoscopic endonasal transsphenoidal surgery for patients aged over 80 years with pituitary adenomas: Surgical and follow-up results. *Surg Neurol Int* 2017;8:213.

<http://surgicalneurologyint.com/Endoscopic-endonasal-transsphenoidal-surgery-for-patients-aged-over-80-years-with-pituitary-adenomas:-Surgical-and-follow-up-results/>

## INTRODUCTION

In a rapidly aging society such as Japan, the population at least 75 years of age is currently increasing at the fastest pace ever and is expected to increase to 2.179 million (18.1%) by 2025.<sup>[20]</sup> Thus, indications for the treatment of elderly patients start to come under discussion.

Pituitary adenoma (PA) is the third most common intracranial tumor, accounting for 15–20% of all primary intracranial tumors.<sup>[4,21]</sup> In addition, PA is one of the common postmortem findings.<sup>[27]</sup> Autopsy studies of elderly patients aged 80 years or older revealed that the prevalence of PA was 14.4%.<sup>[13]</sup> As the population becomes older, the proportion of elderly patients diagnosed with PA continues to rise. Although elderly patients usually present several comorbidities and higher odds for postoperative complications when undergoing neurosurgical operation, those with visual or neurological alterations or with symptoms secondary to hormonal dysfunction should be considered for surgical treatment.<sup>[10,12]</sup>

In our hospital, we have performed a total of 3880 neurosurgical operation from January 2001 through December 2014. Patients were aged 80 years or older in 173 cases (4.5%). PA accounted for 365 cases in total, among which the patients were aged 80 years or older in 12 cases (3.3%). This ratio must not be viewed as unimportant.

We usually performed pure endoscopic endonasal transsphenoidal surgery (ETSS) with a bilateral nostril approach for PA. ETSS allows safe and sufficient resection of sellar lesion tumors and is reported to be effective even for elderly patients aged 65–70 years or older.<sup>[7,32]</sup> There are several reports on traditional microscopic transsphenoidal surgery for PA patients aged 65–70 years or older.<sup>[5,10,14,16,19,24,28,31]</sup> In these reports, transsphenoidal surgery for PA in elderly patients is shown to be generally safe and successful. Yunoue *et al.* reported the safety and efficacy of endoscopy-assisted microscopic transsphenoidal surgery for patients aged 80 years or older.<sup>[31]</sup> However, it has not been made clear that performing pure ETSS for PA is effective and safe for patients over 80 years old.

In the present study, we retrospectively analyzed the results of pure ETSS for PA in patients aged 80 years or older. Characteristics of this group were compared with the characteristics of patients younger than 80 years treated in our hospital for PA.

## MATERIALS AND METHODS

### Patients

This study included all patients aged 80 years or older operated for PA by ETSS at our hospital from January

2001 through December 2014. Multiple surgeries on the same patient were divided into multiple cases because the purpose of this investigation was to evaluate the effectiveness of pure ETSS for PA in patients aged 80 years or older. Surgical indications were presence of neurological signs related to the tumor.

### Preoperative assessment

All patients underwent preoperative magnetic resonance imaging (MRI) using a 1.5- or 3.0-T unit with T1- and T2-weighted imaging with or without Gd-based contrast medium. The degree of lateral expansion of the tumor on its prominent side was evaluated by the Knosp grading system.<sup>[12]</sup> A facial computed tomography (CT) scan was used to evaluate the paranasal sinuses for surgical planning.

Endocrinological tests were routinely done of the basal level of growth hormone (GH), insulin-like growth factor-I, prolactin, thyroid-stimulating hormone (TSH), free thyroxin (FT), adrenocorticotrophic hormone (ACTH), free cortisol, luteinizing hormone, follicle-stimulating hormone, estradiol, and testosterone. A hormone loading test was not routinely performed considering the risk of pituitary stroke induced by that test.

The preoperative physical status was evaluated according to the American Society of Anesthesiologists Physical Status (ASA-PS) grading.<sup>[22]</sup>

### Postoperative assessment

As a postoperative evaluation, we assessed the extent of surgical removal, symptom improvement, postoperative complication, length of postoperative hospital stay, and the Karnofsky performance status (KPS). We classified the extent of surgical removal as total (no residual tumor), subtotal (presence of a residual part but more than 95% removed), and partial (less than 95% removed) on the basis of a postoperative MRI obtained in the immediate postoperative period. KPS was assessed at discharge and every 6 months. The latest KPS was obtained by telephone.

### Comparison with patients younger than 80 years old

To investigate the difference in effectiveness of pure ETSS between patients aged 80 years or older and younger than 80 years old, we collected the medical records of all consecutive patients younger than 80 operated for PA by pure ETSS. Patient data collected included age, tumor size, surgical indication, preoperative and postoperative complications, symptom improvement, and length of postoperative hospital stay.

### Statistical analysis

Statistical analyses were performed using SPSS software (version 19, IBM Corp.). Results are presented as means  $\pm$  standard deviations. Clinical variables were compared between patients aged 80 years or

older and those younger than 80 by the Fisher exact or Mann–Whitney U tests. The Fisher exact test was used for categorical variables and Mann–Whitney U test for continuous variables. Differences for which the probability values were less than 0.05 were considered statistically significant.

## RESULTS

### Preoperative clinical characteristics

From January 2001 through December 2014, we performed ETSS on 11 PA patients aged 80 years or older. Among them, 1 patient was re-operated due to regrowth with a visual field defect, so the number of operations was 12. All patients' characteristics are summarized in Table 1. Cases 8 and 9 were the same patient; case 9 was the second surgery. Our series included 5 men and 6 women, with a mean age of  $82.0 \pm 2.9$  years. Endocrinological investigation revealed that all patients had nonfunctioning PA. Preoperative decrease in the secretion of any pituitary hormone was observed in 6 patients. The mean size of the lesion was  $31.9 \pm 14.9$  mm. Pituitary apoplexy, giant PA (>40 mm), and reoperation due to tumor regrowth with symptom were observed in three lesions each. Knosp grades of II, III, and IV were identified in 6, 1, and 5 patients, respectively. The reasons for surgical treatment were a visual field defect in 9 patients, and external ophthalmoplegia in the other 3 patients.

Patients presented with a high incidence of preoperative comorbidities, including hypertension in 5 patients, cardiac disease in 3 patients, endocrinological disease in 4 patients, respiratory disease in 3 patients, diabetes mellitus in 3 patients, hyperlipidemia in 2 patients,

cerebral infarction in 1 patient, dementia in 1 patient, seizure in 1 patient, and joint trouble in 2 patients. There were 2 patients taking antiplatelet agent (cases 7, 11). According to ASA-PS grading, preoperative patients' physical status was categorized into grade 1 (no systemic disease) in 3 patients, grade 2 (mild systemic disease and normal daily life) in 7 patients, and grade 3 (severe systemic disease and possible daily life with support) in 2 patients. Preoperative KPS was 50 in 1 patient (Case 6) due to heart failure and 80 or more in the other patients.

### Surgery and results

Results of the surgery are summarized in Table 2. All patients underwent pure ETSS with a bilateral nostril approach. Mean operating time was  $216.6 \pm 104.7$  minutes. The purpose of the extraction was to decompress the optic nerve first. Basically, surgery was done with the policy to decompress as much as possible within the safe range, not seeking total removal to prevent postoperative complications such as cerebral spinal fluid (CSF) leakage or additional pituitary dysfunction. For that reason, we did not routinely prepare a pedicled mucosal flap to reconstruct the skull base.

In case a large amount of CSF leakage would occur during surgery, we intended to prepare a pedicled mucosal flap, and there was one such case (case 8).

Bony septum was not used for the construction of skull base in subtotal or partial removal cases considering the risk for postoperative hemorrhage compressing the optic nerve.

Among the total of 12 procedures, total removal was done in 2 patients [Figure 1], subtotal removal was done in 3 patients, and the other 7 patients underwent partial

**Table 1: Patient characteristics**

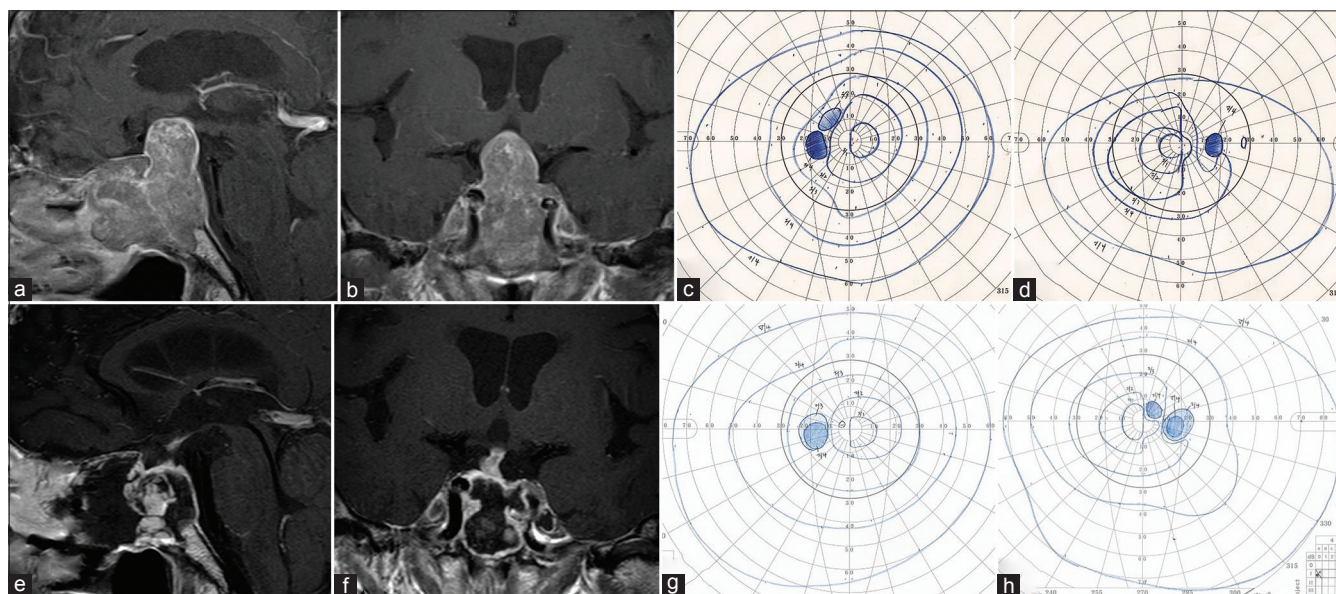
Case no	Age	Gender	Subtype	Tumor size (mm)	Knosp grade	Feature of the tumor	Clinical presentation	Pre-op hormone impairment	ASA-PS	Comorbidity on admission
1	82	M	NF	20	II	Ap	Abducinal nerve palsy	ACTH	2	HT, DM, cardiomyopathy, arrhythmia, osteoarthritis
2	85	F	NF	18	II	Ap	Oculomotor nerve palsy	-	2	HT, DM, thyroid tumor
3	80	M	NF	12	III	Ap	Oculomotor nerve palsy	-	2	HT, cerebral infarction, interstitial pneumonia
4	85	F	NF	30	II	Re	Visual loss, VFD	GH, TSH, ACTH	1	Dementia, seizure
5	84	M	NF	18	IV	Re	VFD	GH, Gonad	2	HT, HL, respiratory problem
6	82	F	NF	35	IV	-	VFD	-	3	Heart failure, asthma, osteoarthritis
7	81	F	NF	32	IV	-	VFD	TSH*	2	HL, cerebral infarction, primary hypothyroidism
8	80	F	NF	50	II	GA	VFD	-	1	-
9	81	F	NF	25	II	Re	VFD	-	1	-
10	83	M	NF	60	IV	GA	VFD	GH, TSH	2	HT, asthma
11	84	M	NF	50	IV	GA	Visual loss, VFD	-	3	Myocardial infarction
12	81	F	NF	33	II	-	VFD	GH, TSH	2	HT, DM

ACTH: Adrenocorticotropic hormone, Ap: Apoplexy, ASA-PS: American Society of Anesthesiologist' Physical Status, DM: Diabetes mellitus, GA: Giant adenoma, GH: Growth hormone, Gonad: Gonadotropin HL: Hyperlipidemia, HT: Hypertension, NF: Clinically nonfunctioning adenoma, Re: Regrowth, TSH: Thyroid stimulating hormone, VFD: Visual field defect, \*TSH increased and free thyroxin 4 decreased which was suspected primary hypothyroidism

**Table 2: Postoperative outcome**

Case no	Removal rate	Operating time	Intra-op CSF leakage*	Hemorrhage volume (mL)	Hospital stay (day)	Visual function	Post-op hormone impairment	Post-op CSF leakage	Other complications
1	Partial	2 h 30 min	-	Little	20	Improved	-	-	Pneumonia, cystitis, renal failure, pneumoedema
2	Subtotal	1 h 56 min	-	Little	16	Improved	-	-	Transient diabetes insipidus
3	Partial	2 h 42 min	+	Little	14	Improved	-	-	-
4	Partial	2 h 20 min	+	Little	13	Improved	-	+	-
5	Subtotal	3 h 00 min	-	Little	19	Improved	-	-	Transient diabetes insipidus, hyponatremia
6	Partial	3 h 10 min	+	269	41	Improved	TSH	-	Deterioration of heart failure
7	Subtotal	4 h 13 min	+	Little	12	Improved	-	-	Transient left oculomotor nerve palsy
8	Partial	5 h 49 min	++	Little	16	Improved	-	-	-
9	Partial	5 h 23 min	++	Little	16	Improved	-	-	-
10	Partial	7 h 35 min	-	475	25	deteriorated	ACTH	+	Left thalamic infarction
11	Total	3 h 55 min	-	250	26	Improved	-	+	-
12	Total	2 h 26 min	-	Little	10	Improved	-	-	-

ACTH: Adrenocorticotropic hormone, CSF: Cerebral spinal fluid, TSH: Thyroid stimulating hormone, \*Degree of CSF leakage was indicated as -: No leakage, +: Little, ++: Moderate



**Figure 1:** In Case 11, preoperative sagittal (a) and coronal (b) views of contrast-enhanced magnetic resonance imaging (MRI) demonstrated a tumor extending the suprasellar area and compressing the optic chiasm upward. Bitemporal hemianopia was detected preoperatively using the Goldmann perimeter (c, left; d, right). Postoperative sagittal (e) and coronal (f) views of contrast-enhanced MRI revealed total removal of the tumor. Postoperatively, the bitemporal hemianopia improved (g, left; h, right)

removal. For the 3 patients with pituitary apoplexy, we did not dare to remove the entire tumor due to fibrous adhesion with surroundings. Moreover, for the patients with progression into the suprasellar region or with a giant PA, we removed the suprasellar region as much as possible within the safe range to prevent CSF leakage.

### Neurological and endocrinological outcome

Recovery of visual function was accomplished in 11 patients, but deterioration was observed in 1 patient.

One patient was complicated by incomplete paralysis of the oculomotor nerve that lasted for 1 month. The cause was thought to be compression of the oculomotor nerve by a hematoma formed in the left cavernous sinus at the time of removal of the tumor.

Regarding the endocrinological functions, transient diabetes insipidus (DI) was observed in 2 patients during the hospital stay, but there was no patient in whom desmopressin was needed after discharge. Additional

pituitary hormone impairment was observed in 2 patients. Case 6 demonstrated decreased TSH level postoperatively, although FT3 and FT4 levels were normal. Case 10 revealed preoperative impairment of GH and TSH and additional ACTH impairment postoperatively.

### Postoperative complication

Postoperative hospital stay ranged from 12 to 41 days with a mean of  $19.0 \pm 8.5$  days. Intraoperative CSF leakage observed in 4 patients (cases 3, 4, 6, 7) was minor, whereas that in 2 patients (cases 7, 8) was moderate. Postoperative CSF leakage was observed in 3 patients (cases 4, 10, 11). In case 4, we only positioned fat graft inside the residual cavity without tight packing because intraoperative CSF leakage was minor and a residual tumor was present. However, postoperative CSF leakage lasted; therefore, we underwent multilayer reconstruction using a nasoseptal pedicled mucosal flap. In cases 10 and 11, we reconstructed the skull base with fat graft and polyglactin acid sheet owing to the absence of intraoperative CSF leakage. Four days after the operation, CSF leakage was suspected but showed improvement after 2 days of rest.

Three patients experienced postoperative general complications (cases 1, 6, 10). Case 1 was complicated by aspiration pneumonia and cystitis. This induced an adrenal crisis due to cortisol deficiency. Hydrocortisone administration improved the adrenal crisis, but pulmonary edema and renal failure were prolonged. In case 6, heart failure, from which patient had suffered before, transiently deteriorated postoperatively and required medical treatment. In case 10 [Figure 2], the

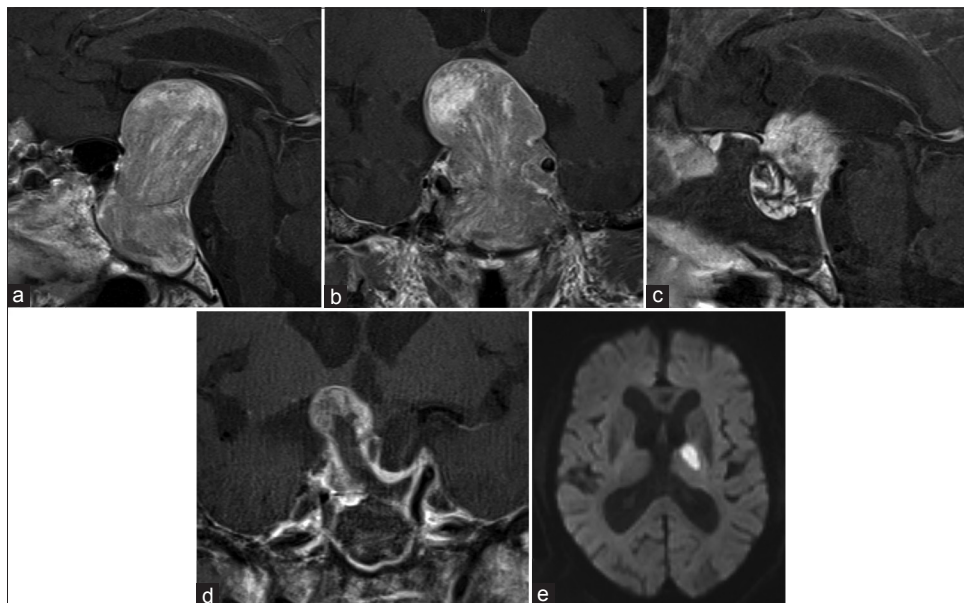
patient developed left thalamic infarction postoperatively and consciousness disturbance lasted for 1 week. After 1 month, he had recovered sufficiently to move around in a wheelchair without assistance and was transferred to a rehabilitation hospital. However, he died from pneumonia 1 month after the transfer.

### Follow-up results

Follow-up periods ranged from 1 to 87 months with a mean of  $34.4 \pm 24.1$  months. One patient (case 8) suffered from regrowth of a residual tumor and underwent re-operation. The other patients did not suffer from deterioration of their visual function after surgery. None of the patients underwent gamma knife radiosurgery in follow-up periods. The time course of KPS from preoperative to final survey time is shown in Table 3. Two patients died during the follow-up period (cases 1, 10). In Case 1, patient died from pneumonia 27 months after discharge. Deterioration of KPS in the follow-up period was observed in 2 patients (cases 3, 4), but in both the cause of deterioration was thought to be worsening of the general condition by aging.

### Comparison with patients younger than 80 years old

In the present study, all PAs in the patients aged 80 years or older were nonfunctioning, therefore, we compared these patients with nonfunctioning PA patients younger than 80. From January 2001 through December 2014, we performed ETSS for consecutive 150 nonfunctioning PA patients younger than 80, with a mean age of  $60.0 \pm 12.4$  years. Table 4 shows a comparison of the patients aged 80 years or older and those younger



**Figure 2:** In Case 10, preoperative sagittal (a) and coronal (b) views of contrast-enhanced magnetic resonance imaging (MRI) showed a giant (60 mm) tumor presenting a major suprasellar extension and compression of the third ventricle. Postoperatively, sagittal (c) and coronal (d) views contrast-enhanced MRI revealed decompression of the tumor. Postoperative diffusion-weighted image (e) showed a left thalamic infarction

**Table 3: Follow-up outcome**

Case no	Follow-up period (months)	KPS			
		Preoperative	Discharge	Six months after discharge	Latest
1	27	80	50	50	0
2	6	80	90	90	90
3	87	80	80	100	50
4	53	80	50	80	30
5	26	80	80	90	90
6	42	50	50	60	80
7	38	90	80	90	90
9	30	90	80	80	80
10	1	80	50	0	0
11	40	80	90	100	90
12	28	90	90	90	90

KPS: Karnofsky performance status

**Table 4: Comparison of patients aged  $\geq 80$  years with patients aged  $\leq 79$  years**

Characteristics	$\geq 80$ years (n=12)	$\leq 79$ years (n=150)	P
Median age (range)	82 (80-91)	60 (29-79)	
Female rate (%)	7 (58.3)	80 (53.3)	0.77
Tumor size (mean $\pm$ SD mm)	31.9 $\pm$ 14.9	29.2 $\pm$ 9.2	0.68
Preoperative comorbidity	8 (66.7)	25 (16.6)	<0.001
Total removal (%)	2 (16.6)	81 (54.0)	0.016
Visual improvement (%)	11 (91.7)	125/134 (93.2)	0.59
Postoperative complication (%)			
Visual deterioration	1 (8.3)	4 (2.7)	0.32
New hormone deficiency	2 (16.7)	15 (10.0)	0.47
Permanent DI	0 (0)	6 (4.0)	1.0
CSF leakage	3 (25.0)	5 (3.3)	0.014
Other complication	4 (33.3)	3 (2.0)	0.001
Length of postoperative hospital stay (mean $\pm$ SD day)	19.0 $\pm$ 8.5	12.5 $\pm$ 6.4	0.001

CSF: Cerebral spinal fluid, DI: Diabetes insipidus, SD: Standard deviation

than 80 years old. The percentage of total removal was significantly higher in the younger patient group than that in the older one (54.0% vs 16.6%, respectively;  $P = 0.016$ ), reflecting the policy to decompress the optic nerve as much as possible within the safe range, not seeking total removal in elderly patients. Visual improvement was observed in 91.7% of the patients aged 80 years or older and 93.2% of the younger patients; this difference was not significant. Postoperative complications, especially CSF leakage, were observed more frequently in patients aged 80 years or older. CSF leakage was significantly more frequent in these patients. ( $P = 0.014$ ) Permanent DI was not observed in the older patient group.

Length of postoperative hospital stay of these patients was longer than that of the patients younger than 80 (19.0  $\pm$  8.5 days vs 12.5  $\pm$  6.4 days, respectively;  $P = 0.001$ ).

## DISCUSSION

In a rapidly aging society such as Japan, the population of people aged 75 years or older is expected to rise to 2.179 million (18.1%) by 2025.<sup>[20]</sup> Also, the number of PA diagnosed in elderly patients is estimated to increase. However, it has not been demonstrated that pituitary surgery is effective and safe for patients aged 80 years or older. ETSS has been adopted and is reported to provide decreased invasiveness, better visualization, quicker recovery, and fewer complications compared to that provided by the traditional microscopic transsphenoidal surgery. However, there is no report on the performance of pure ETSS for these elderly PA patients.<sup>[3,25,32]</sup>

### Surgical outcome

The present study shows that ETSS for PA in patients aged 80 years or older is effective enough to improve compression symptoms caused by the tumor. Though we did not dare to remove the entire tumor to decompress the optic nerve first, visual improvement was observed in 91.7%, which was almost the same as the result in patients younger than 80 years of age (93.2%). One patient underwent re-operation for symptom recurrence, but the other patients did not require re-operation or gamma knife radiosurgery during the follow-up period.

Yunoue *et al.* reported the good outcome of endoscopy-assisted microscopic transsphenoidal surgery in 10 patients aged 80 years or older.<sup>[31]</sup> In that series, total, subtotal, and partial removals were performed in 7, 2, and 1 patient, respectively. The visual disturbance seen preoperatively was improved in all patients, and no regrowth of residual tumor was detected during the follow-up with a mean of 37.9 months. Postoperative KPS was not deteriorated from the preoperative figures in all patients. In that series, the maximum tumor diameter ranged from 20 to 39.3 mm with mean of 28.5 mm  $\pm$  5.79 (SD), and Knosp grade of IV was identified in 1 patient. On the contrary, in our series, there were 3 patients with giant PA (>40 mm) and 5 patients with Knosp grade of IV. This indicates that our series included more aggressive cases.

Thus, our series are not necessarily typical cases of PA patients aged 80 years or older, but our series together with Yunoues' series indicate that transsphenoidal surgery is effective for various types of PA patients aged 80 years or older.

Treatment outcomes of pure ETSS for PA have been reported in patients aged 65 or 70 years or older.<sup>[7,32]</sup> In these reports, pure ETSS was also considered to be an efficient and safe treatment for PA in elderly patients.

The present study is the first study revealing the effectivity of pure ETSS for PA patients aged 80 years or older.

Considering the slow growing nature of PA, especially in the elderly and their limited life expectancy, our policy of decompression as much as possible within the safe range, in which total removal is not always sought, may have validity.<sup>[17,24,26]</sup> Subtotal and partial removal provided sufficient decompression of the optic nerve and prolonged the progression-free status.

### Surgical complications

Postoperative complications were observed more frequently in the elderly patients studied in the present report. In particular, CSF leakage was significantly more frequent (25%).

It has been previously reported that more postoperative complications occur in elderly people than that in young people.<sup>[7-9]</sup> Gondim *et al.* reported that, after ETSS for PA, patients aged 70 years or older have more complications than those younger than 60 years of age (32.7% vs 10%, respectively).<sup>[7]</sup>

Previously published rates of postoperative CSF leakage after surgery for PA vary from 0.5% to 6.0% and in the elderly population studies they vary from 4.9% to 15.6%.<sup>[1,5,8,15,18]</sup> In the present study, 3 patients suffered from postoperative CSF leakage, including 1 patient with recurrent tumor and 2 patients with a giant PA. Surgery for recurrent tumor has been reported to be an independent risk factor for postoperative CSF leakage.<sup>[29,30]</sup> Transsphenoidal surgery for giant PA requires extended resection of the sellar floor; therefore, large cranial base defects have a higher rate of postoperative CSF leakage.<sup>[2,6,11]</sup> These reasons may have contributed to the relatively high incidence of CSF leakage rather than influence of old age in our analysis.

Although we have removed tumors to prevent CSF leakage, in cases of recurrent or giant PA, a pedicled mucosal flap to reconstruct the skull base should be prepared regardless of CSF leakage during surgery.

Previous reports have indicated that postoperative new anterior hypopituitarism occurred in 1.4–19.8% of the patients.<sup>[1,18,32]</sup> In our analysis, two cases (16.7%) aged 80 years or older suffered from postoperative additional hormone deficiency. This occurrence rate was same as that reported previously and that of the patients younger than 80 years old (10.0%). No patient suffered from permanent DI. Considering that our patients aged 80 years or older included many aggressive PA, these results indicate that our surgical procedure for PA patients aged 80 years or older is effective.

Although postoperative hormone replacement was required in 8 patients, none of the patients required additional treatment with symptoms of hormone deficiency in the follow-up period after discharge. Hormone deficiency had been well controlled with oral medicine at discharge. Zhan *et al.* reported that there

was no difference between patients aged 65 years or older and 40–55 years old in postoperative new anterior hypopituitarism occurrence, but there is no report on patients aged 80 years or older.<sup>[32]</sup> Elderly patients have been reported to have a higher rate of preoperative hypopituitarism and a lower rate of its remission, and therefore appropriate assessment of pituitary function and long-term follow-up is required.<sup>[5,7,19,23,31]</sup>

In the present study, postoperative hospital stay was longer in patients aged 80 years or older due to the therapy for postoperative complications. In the follow-up period, poor prognosis was observed in 2 patients (cases 1, 10). In case 10, with a giant PA, left thalamic infarction was thought to occur by stretching or kinking of the thalamotuberal arteries caused by tumor reduction. The surgery-related left thalamic infarction affected prognosis. Giant PA has been reported to have more postoperative complications than nongiant PA, therefore the poor prognosis in case 10 was likely to be due to the characteristics of the tumor itself rather than the influence of old age.<sup>[2,6,11]</sup> In case 1, postoperative aspiration pneumonia gave rise to a deterioration of the general condition and subsequent poor prognosis 27 months after discharge. Old age and comorbidities such as diabetes mellitus and cardiomyopathy may have caused worsening of the pneumonia. The other patients followed favorable courses, even though in 2 patients (cases 4, 6) KPS was temporarily deteriorated at discharge. ETSS-specific surgical complications such as CSF leakage and postoperative hormone deficiency had not affected patients' prognosis.

### Study limitations

Our study has several limitations. To begin, this study is a retrospective study of data that were acquired previously, and it has the inherent limitations of this kind of studies. Second, the number of cases is small. Third, the follow-up period of some patients may have been short. Considering that recurrence of PA can occur many years after surgery, a longer follow-up is required.

### CONCLUSION

Pure endoscopic endonasal surgery is an effective and safe surgical technique in terms of visual function recovery even in PA patients aged 80 years or older. Considering the slow-growing nature of PA in the elderly and the limited life expectancy of the elderly, it is not always necessary to aggressively perform total removal of the tumor; this is in contrast to the situation in young people. Subtotal and partial removal provides sufficient decompression of the optic nerve and a prolonged progression-free status without postoperative complications influencing the long-term prognosis. Elderly age would not preclude such patients from undergoing vision-saving surgery as needed when their general condition is well preserved.

## Financial support and sponsorship

Nil.

## Conflicts of interest

There are no conflicts of interest.

## REFERENCES

- Berker M, Hazer DB, Yucel T, Gurlek A, Cila A, Aldur M, *et al.* Complications of endoscopic surgery of the pituitary adenomas: Analysis of 570 patients and review of the literature. *Pituitary* 2012;15:288-300.
- Chabot JD, Chakraborty S, Imbarrato G, Dehdashti AR. Evaluation of Outcomes After Endoscopic Endonasal Surgery for Large and Giant Pituitary Macroadenoma: A Retrospective Review of 39 Consecutive Patients. *World Neurosurg* 2015;84:978-88.
- Dallapiazza RF, Grober Y, Starke RM, Laws ER, Jr., Jane JA, Jr. Long-term results of endonasal endoscopic transsphenoidal resection of nonfunctioning pituitary macroadenomas. *Neurosurgery* 2015;76:42-52; discussion 52-43.
- Ezzat S, Asa SL, Couldwell WT, Barr CE, Dodge WE, Vance ML, *et al.* The prevalence of pituitary adenomas: A systematic review. *Cancer* 2004;101:613-9.
- Ferrante L, Trillo G, Ramundo E, Celli P, Jaffrain-Rea ML, Salvati M, *et al.* Surgical treatment of pituitary tumors in the elderly: Clinical outcome and long-term follow-up. *J Neurooncol* 2002;60:185-91.
- Gondim JA, Almeida JP, Albuquerque LA, Gomes EF, Schops M. Giant pituitary adenomas: Surgical outcomes of 50 cases operated on by the endonasal endoscopic approach. *World Neurosurg* 2014;82:e281-90.
- Gondim JA, Almeida JP, de Albuquerque LA, Gomes E, Schops M, Mota JI. Endoscopic endonasal transsphenoidal surgery in elderly patients with pituitary adenomas. *J Neurosurg* 2015;123:31-8.
- Grossman R, Mukherjee D, Chaichana KL, Salvatori R, Wand G, Brem H, *et al.* Complications and death among elderly patients undergoing pituitary tumour surgery. *Clin Endocrinol (Oxf)* 2010;73:361-8.
- Halvorsen H, Ramm-Petersen J, Josefsen R, Ronning P, Reinlie S, Meling T, *et al.* Surgical complications after transsphenoidal microscopic and endoscopic surgery for pituitary adenoma: A consecutive series of 506 procedures. *Acta Neurochir (Wien)* 2014;156:441-9.
- Hong J, Ding X, Lu Y. Clinical analysis of 103 elderly patients with pituitary adenomas: Transsphenoidal surgery and follow-up. *J Clin Neurosci* 2008;15:1091-5.
- Juraschka K, Khan OH, Godoy BL, Monsalves E, Kilian A, Krischek B, *et al.* Endoscopic endonasal transsphenoidal approach to large and giant pituitary adenomas: Institutional experience and predictors of extent of resection. *J Neurosurg* 2014;121:75-83.
- Knosp E, Steiner E, Kitz K, Matula C. Pituitary adenomas with invasion of the cavernous sinus space: A magnetic resonance imaging classification compared with surgical findings. *Neurosurgery* 1993;33:610-7; discussion 617-618.
- Kovacs K, Ryan N, Horvath E, Singer W, Ezrin C. Pituitary adenomas in old age. *J Gerontol* 1980;35:16-22.
- Kurosaki M, Ludecke DK, Flitsch J, Saeger W. Surgical treatment of clinically nonsecreting pituitary adenomas in elderly patients. *Neurosurgery* 2000;47:843-8; discussion 848-849.
- Kurosaki M, Saeger W, Ludecke DK. Pituitary tumors in the elderly. *Pathol Res Pract* 2001;197:493-7.
- Locatelli M, Bertani G, Carrabba G, Rampini P, Zavanone M, Caroli M, *et al.* The trans-sphenoidal resection of pituitary adenomas in elderly patients and surgical risk. *Pituitary* 2013;16:146-51.
- Losa M, Franzin A, Mangili F, Terreni MR, Barzaghi R, Veglia F, *et al.* Proliferation index of nonfunctioning pituitary adenomas: Correlations with clinical characteristics and long-term follow-up results. *Neurosurgery* 2000;47:1313-8; discussion 1318-1319.
- Mamelak AN, Carmichael J, Bonert VH, Cooper O, Melmed S. Single-surgeon fully endoscopic endonasal transsphenoidal surgery: Outcomes in three-hundred consecutive cases. *Pituitary* 2013;16:393-401.
- Minniti G, Esposito V, Piccirilli M, Fratticci A, Santoro A, Jaffrain-Rea ML. Diagnosis and management of pituitary tumours in the elderly: A review based on personal experience and evidence of literature. *Eur J Endocrinol* 2005;153:723-35.
- National Institute of Population and Social Security Research [database on the Internet]. Actual and Projected Population by Age: 1920-2060. 2016 [cited 18 February 2017]. Available from: [http://www.ipss.go.jp/youshika/tohkei/Popular/P\\_Detail2016.asp?fname=T02-09.htm](http://www.ipss.go.jp/youshika/tohkei/Popular/P_Detail2016.asp?fname=T02-09.htm).
- Ostrom QT, Gittleman H, Fulop J, Liu M, Blanda R, Kromer C, *et al.* CBRUS Statistical Report: Primary Brain and Central Nervous System Tumors Diagnosed in the United States in 2008-2012. *Neuro Oncol* 2015;17(Suppl 4):iv1-iv62.
- Owens WD, Felts JA, Spitznagel EL, Jr. ASA physical status classifications: A study of consistency of ratings. *Anesthesiology* 1978;49:239-43.
- Robenshtok E, Benbassat CA, Hirsch D, Tzvetov G, Cohen ZR, Iraqi HM, *et al.* Clinical course and outcome of nonfunctioning pituitary adenomas in the elderly compared with younger age groups. *Endocr Pract* 2014;20:159-64.
- Sheehan JM, Douds GL, Hill K, Farace E. Transsphenoidal surgery for pituitary adenoma in elderly patients. *Acta Neurochir (Wien)* 2008;150:571-4; discussion 574.
- Tabaei A, Anand VK, Barron Y, Hiltzik DH, Brown SM, Kacker A, *et al.* Endoscopic pituitary surgery: A systematic review and meta-analysis. *J Neurosurg* 2009;111:545-54.
- Tanaka Y, Hongo K, Tada T, Sakai K, Kakizawa Y, Kobayashi S. Growth pattern and rate in residual nonfunctioning pituitary adenomas: Correlations among tumor volume doubling time, patient age, and MIB-1 index. *J Neurosurg* 2003;98:359-65.
- Teramoto A, Hirakawa K, Sanno N, Osamura Y. Incidental pituitary lesions in 1,000 unselected autopsy specimens. *Radiology* 1994;193:161-4.
- Turner HE, Adams CB, Wass JA. Pituitary tumours in the elderly: A 20 year experience. *Eur J Endocrinol* 1999;140:383-9.
- Wagenmakers MA, Netea-Maier RT, van Lindert EJ, Timmers HJ, Grotenhuis JA, Hermus AR. Repeated transsphenoidal pituitary surgery (TS) via the endoscopic technique: A good therapeutic option for recurrent or persistent Cushing's disease (CD). *Clin Endocrinol (Oxf)* 2009;70:274-80.
- Yamada S, Fukuhara N, Oyama K, Takeshita A, Takeuchi Y. Repeat transsphenoidal surgery for the treatment of remaining or recurring pituitary tumors in acromegaly. *Neurosurgery* 2010;67:949-56.
- Yunoue S, Tokimura H, Tominaga A, Fujio S, Karki P, Usui S, *et al.* Transsphenoidal surgical treatment of pituitary adenomas in patients aged 80 years or older. *Neurosurg Rev* 2014;37:269-76; discussion 276-267.
- Zhan R, Ma Z, Wang D, Li X. Pure Endoscopic Endonasal Transsphenoidal Approach for Nonfunctioning Pituitary Adenomas in the Elderly: Surgical Outcomes and Complications in 158 Patients. *World Neurosurg* 2015;84:1572-8.