

Incredible position of broken sliding dynamic hip screw implant in the medial of thigh



Saeed Solooki, Amir Reza Vosoughi*

Bone and Joint Diseases Research Center, Department of Orthopedic Surgery, Chamran Hospital, Shiraz University of Medical Sciences, Shiraz, Iran

ARTICLE INFO

Article history:

Received 10 July 2016

Received in revised form

14 July 2016

Accepted 17 November 2016

Available online 25 April 2017

Keywords:

Dynamic hip screw

Intertrochanteric fracture

Nonunion

Implant failure

Broken device

ABSTRACT

We report a case with implant failure after nailing of an unstable pertrochanteric fracture with dynamic hip screw. The patient presented with a medial sided thigh pain at 5 years after the surgery. Plain radiographs showed nonunion of the fracture with distant migration of assembled hip screw and side plate to the subcutaneous area of the inner thigh.

© 2017 Turkish Association of Orthopaedics and Traumatology. Publishing services by Elsevier B.V. This is an open access article under the CC BY-NC-ND license (<http://creativecommons.org/licenses/by-nc-nd/4.0/>).

Introduction

Intertrochanteric fracture is the most common osteoporotic fracture in the elderly especially in women.¹ Dynamic hip screw (DHS) implant system is one of the devices used for fixation of intertrochanteric fractures.² Failure of DHS has been reported multiple times in different parts of the implant,^{3–6} but to the best of our knowledge, a side plate with assembled sliding hip screw, all as one piece, placed to the medial of thigh following device failure with broken screws has not been reported yet.

Case report

An 84-year-old woman came with pain and mass on medial aspect of left thigh. She had undergone reduction and fixation of left pertrochanteric fracture with DHS implant via direct lateral approach about five years before presentation (Figs. 1 and 2). She could walk with a cane without any pain in left hip area. In exam, a strange bulging was palpable in subcutaneous area of medial left

thigh. All nerves beside vascular supply of the left lower limb were intact. Although she had osteoarthritis of the knee joint with decreased range of motion of the knee joint, motion of joints of left lower limb was equal to the right side. Moreover no evidence of infection in exam and laboratory data was detected.

On the plane anteroposterior radiograph, nonunion and deformed pertrochanteric area beside migrated implant in an unbelievable position of medial thigh was obvious (Fig. 3). The broken implant and engaged screws were simply removed through medial thigh incision exactly on the prominent device (Fig. 4). The patient denied any surgery to correct nonunion because of painless walking using a cane.

One year after removal of the implant on medial side of the thigh, the patient was pain free but dependent on a cane for walking.

Discussion

As stated by Spivak et al³ there are two modes of failure of DHS implant; the usual kind is the result of multiple-cycle, low stress fatigue failure of the device which is related to the design of screw such as its internal threaded region and barrel length. The other type of DHS failure is the result of high stress loading which is seen in nonunion of pertrochanteric area. The presented subject was a case of unstable subtrochanteric-intertrochanteric femoral fracture

* Corresponding author.

E-mail address: vosoughiar@hotmail.com (A.R. Vosoughi).

Peer review under responsibility of Turkish Association of Orthopaedics and Traumatology.

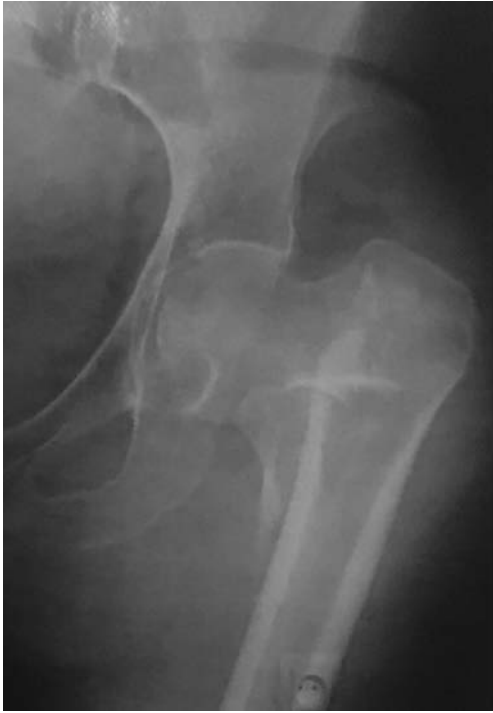

Fig. 1. Pre-op anteroposterior plain radiograph showed unstable pertrochanteric fracture.

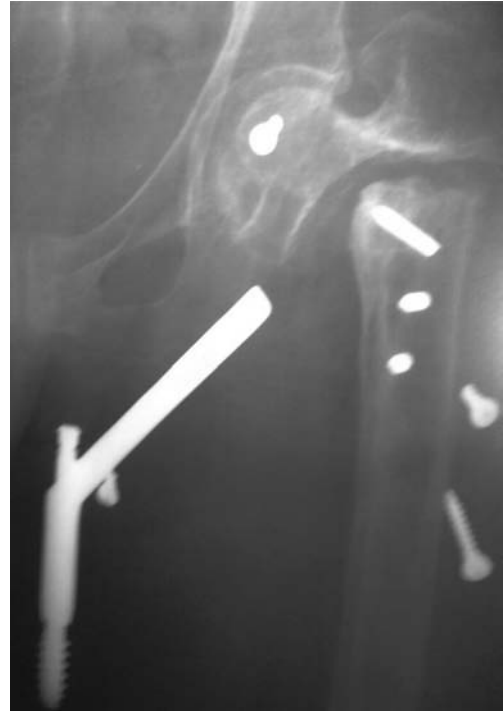

Fig. 3. Anteroposterior plain radiograph of the patient revealed nonunion and incredible position of broken device in medial of thigh.

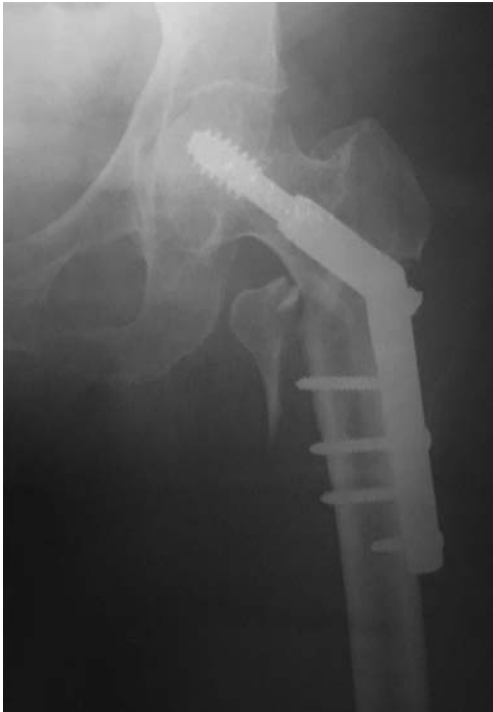

Fig. 2. Post-op anteroposterior plain radiograph displayed reduction and fixation with DHS implant.

of left side. The mechanical stability of DHS to achieve union in this case was inadequate; therefore implant failure was clear from beginning. Another cause of failure in this case would be occult infection which was ruled out by exam and normal laboratory data.

Technical malposition of hip screw may result in immediate failure of the implant. This common failure of the implant is called “cut out” which is penetration of the screw to the hip joint with varus deformity in the site of fracture. Cut out of the implant from the femoral neck is seen in about 7% of patients treated with DHS implant. Accurate position of the screw in the femoral neck, considered as tip-apex distance, is the most useful criterion to prevent sliding screw cut out. Other factors including unstable pattern of fracture, inadequate reduction of the fracture, trabecular bone strength, and age of the patient were determined as the other predictive factors.^{7–9}

Beside cut out of the hip screw from femoral neck to the hip joint, several types of failure in hip screw have been reported in the literature such as bending of the hip screw at the screw–barrel interface without breakage,⁴ hip screw breakage,^{10,11} and breakage in the barrel of plate and bending in the hip screw.⁶ Breakage of side plate or cortical screws especially in nonunion cases have been described previously³ but migration of unbroken hip screw linked to the side plate into the medial side of the thigh has not been reported.

In conclusion, fixation of unstable pertrochanteric fractures with DHS may result in nonunion and eventually device failure and displacement with possible injuries to the surrounding vital structures.

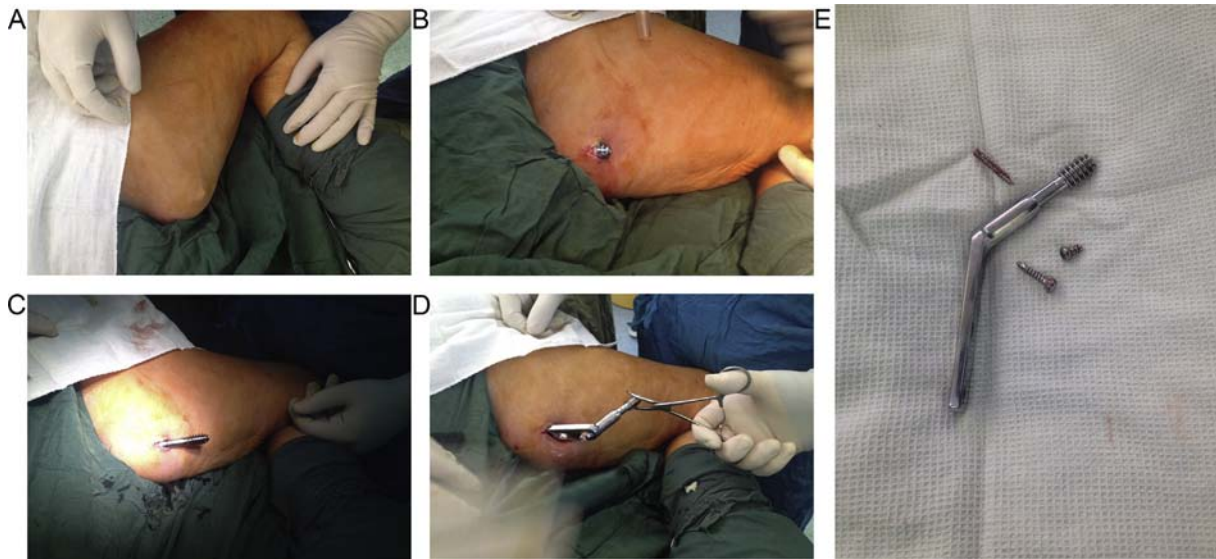


Fig. 4. Sequences of implant removal during surgery (A to E).

References

- Maharlouei N, Khodayari M, Forouzan F, Rezaianzadeh A, Lankarani KB. The incidence rate of hip fracture in Shiraz, Iran during 2008–2010. *Arch Osteoporos*. 2014;9:165. <http://dx.doi.org/10.1007/s11657-013-0165-9>.
- Kazemian GH, Manafi AR, Najafi F, Najafi MA. Treatment of intertrochanteric fractures in elderly highrisk patients: dynamic hip screw vs. external fixation. *Injury*. 2014;45:568–572.
- Spivak JM, Zuckerman JD, Kummer FJ, Frankel VH. Fatigue failure of the sliding screw in hip fracture fixation: a report of three cases. *J Orthop Trauma*. 1991;5:325–331.
- Arastu MH, Phillips L, Duffy P. An unusual failure of a sliding hip screw in the immediate post-operative period. *Inj Extra*. 2013;44:23–27.
- Khanna A, Khanna A, Parker M. Rare mode of dynamic hip screw failure. *Hip Int*. 2008;18:239–241.
- Roy K, Nemade P, Aggarwal R, Patil N. Unusual mode of failure of intertrochanteric femur fracture fixation. *BMJ Case Rep*. 2015 Nov 12;2015. <http://dx.doi.org/10.1136/bcr-2015-213012>. pii: bcr2015213012.
- Hsueh KK, Fang CK, Chen CM, Su YP, Wu HF, Chiu FY. Risk factors in cutout of sliding hip screw in intertrochanteric fractures: an evaluation of 937 patients. *Int Orthop*. 2010;34:1273–1276.
- De Bruijn K, den Hartog D, Tuinebreijer W, Roukema G. Reliability of predictors for screw cutout in intertrochanteric hip fractures. *J Bone Jt Surg Am*. 2012;94:1266–1272.
- Müller MA, Hengg C, Krettek C, et al. Trabecular bone strength is not an independent predictive factor for dynamic hip screw migration—A prospective multicenter cohort study. *J Orthop Res*. 2015;33:1680–1686.
- Hrubina M, Skoták M, Krumpl O, Míka P, Letocha J. Osteosynthetic material breakage in patients treated with DHS for proximal femoral fracture. *Rozhl Chir*. 2012;91:146–150.
- Jakobsen BW. Breakage of a sliding hip screw. A case report. *Acta Orthop Scand*. 1987;58:292–293.