



# The role of neurectomy in the management of spasticity of the upper limb

Petros Mikalef  
Dominic Power

- Neurectomy is one of the treatments available to the surgeon treating patients with spasticity of the upper limb.
- Its popularity has increased in recent years.
- Accurate knowledge of the anatomical variations of the terminal branches to the muscles is required in order to achieve a successful outcome.
- Although the anatomy has been thoroughly studied, there are still controversies regarding the percentage of the nerve to be resected for a successful result, and also regarding the terminology that has been used in the literature to describe the procedure.
- The literature for neurectomies for the upper limb is reviewed and an agreement regarding terminology is proposed.

**Keywords:** neurectomy; upper limb spasticity

Cite this article: *EFORT Open Rev* 2017;2:469-473.  
DOI: 10.1302/2058-5241.2.160074

Spasticity is one of the leading causes of impaired mobility in patients with cerebral palsy (CP), and in patients who have sustained a cerebrovascular accident, multiple sclerosis or other neurological disorders. The main treatment approach for these patients' impaired mobility is non-surgical, with oral medication, physiotherapy, splinting, chemodeneration, or, most likely, an individualised combination of some or all of these treatment modalities. When an indication for surgical treatment is established, there are many alternative operative techniques that have been described in the literature. The principle of surgery in the functional limb is to restore the balance between agonists and antagonists by reducing the overactivity of the spastic muscles, redirecting muscle forces, mobilising stiff joints or stabilising joints with the aim of improving limb functional status.

Spasticity patterns are often predictable and for the upper limb the most common presentation is adduction and internal rotation of the shoulder, flexion of the elbow,

pronation of the forearm, flexion and ulnar deviation of the wrist, thumb-in-palm deformity, clenched fist deformity or hyperextension of the fingers because of intrinsic tightness. In order to reduce the overactivity of spastic muscles the treatment options include lengthening of the tendon-muscular unit, either by step lengthening or by intramuscular/fractional lengthening, release of the aponeurosis, for example, the flexor aponeurotic release to treat spasticity of the finger flexors in the CP patient, and procedures that aim to reduce hyperexcitability by reducing the motor nerve supply by dissection of the whole nerve. If no remaining function is expected a neurotomy is performed or, if volitional control is present or expected, sectioning of a proportion of the nerve by partial neurotomy is carried out. In order to prevent regrowth across the neurotomy, one preferred option is to remove the dissected nerve completely or partially, known as a complete or partial/selective neurectomy.

The idea of intervening in the level of the peripheral nerve is not new. The first ever intervention was described by Lorenz<sup>1</sup> in 1887, which was a neurotomy by performing ablation of the obturator nerve for reduction of spasticity of the hip adductors. In 1913, Adolf Stoffel<sup>2</sup> first published his technique in the upper limb. He found the results from tendon operations for spasticity to be unsatisfactory so he introduced a new approach, which was to weaken the muscle through neurotomies. He highlighted the importance of precise knowledge of the involved anatomy and he acknowledged the variations in the number of terminal branches to the muscle as well as the importance of nerve stimulation. He had developed a nerve stimulator in order to localise the fascicular anatomy and branching anatomy of the peripheral nerves. He advised surgeons planning neurotomy to familiarise themselves with the anatomy and variations through cadaveric dissection.<sup>2</sup> This was before the era of antibiotics, where there was a need for short incisions, short operations and brief anaesthesia, so his results were inconsistent and incomplete and the operation never achieved widespread uptake and was eventually abandoned.<sup>3</sup>

Brunelli and Brunelli<sup>3</sup> revisited peripheral nerve surgery to treat functional upper limbs for spasticity over 50 years after Stoffel's first publication. They described the adoption phenomenon to explain the apparent delayed relapse in spasticity due to re-innervation of the denervated muscle fibres. The adoption phenomenon explains how denervated motor units are re-innervated through axonal sprouting from adjacent motor axon terminals. The consequence is the current recommendation for more extensive nerve resection at the primary surgery. They also described the surgical technique and suggested extension to any spastic muscle in the upper limb, no matter which nerve provides the innervation. The importance of thorough pre-operative assessment of the muscles to be operated on, as well as the need for the operation to be performed under magnification and the need for a generous denervation because of the adoption phenomenon were highlighted.

The anatomy of the peripheral nerves in the upper limb have been studied with regard to neurectomy in three separate cadaveric studies.<sup>4-6</sup> Cambon-Binder and Leclercq<sup>4</sup> dissected the musculocutaneous nerve in 16 limbs and found significant variations. The innervation of the biceps brachii included up to five main trunks from the musculocutaneous nerve and in four cases (25%) the last trunk exited the nerve more distally than the motor branch to the distally located brachialis muscle. The innervation to the brachialis muscle demonstrated up to three trunks from the musculocutaneous nerve exiting from the medial side in ten cases (62.5%), from the lateral side in five cases (31.25%) and from both sides in one case (6.25%). The first trunk from the musculocutaneous nerve can be identified at 17.9% of the distance from the coracoid process to the lateral epicondyle and the last trunk at 75% of this same distance. A generous incision is needed in order to fully explore the nerve and identify all possible motor branches during surgery for denervation.

Similarly Paulos and Leclercq<sup>5</sup> after dissecting 20 cadaveric forearms identified between two and five trunks exiting the ulnar nerve forming 11 different branching patterns. The first trunk can exit 2 cm proximal to the medial epicondyle and the last exiting branch 11.6 cm distal to it. The need for a careful and extensive dissection was highlighted. Parot and Leclercq<sup>6</sup> presented the results of 20 dissections of the median nerve. The branches to all median nerve-innervated muscles were studied. Careful directions were given as the surgeon has to identify all branches coming from the median nerve. The surgical incision should start from proximal to the point where the first branch enters the muscle (which is 7 mm distal to the medial epicondyle) and should extend to more than 224 mm from the medial epicondyle in order not to miss any crucial trunk. They also concluded that since the most proximal branches of the flexor digitorum profundus run

deep to the flexor digitorum superficialis (FDS), they are inaccessible to hyperselective neurectomy unless the FDS is detached or split.

In the literature that has followed Brunelli's publication, despite the acceptance of the role of neurectomy in spasticity surgery, there is no consensus on the technical details. The original Brunelli and Brunelli<sup>3</sup> paper recommendation was to remove two-thirds of the fascicles innervating a muscle and to re-assess after six months when the adoption phenomenon is complete and at that stage re-operate to correct residual muscle impairment or deformity. The procedure is called partial selective denervation (hyponeurotisation) when there was dissection of motor branches, unless there was only one motor branch, where fascicles were separated and a proportion was dissected.

Purohit et al<sup>7</sup> published their results after treating 52 patients for spasticity of the elbow flexors, operating on 75 musculocutaneous nerves in total with an average follow-up of 17 months. Describing their technique, they mentioned that the procedure was performed over the main trunk of the musculocutaneous nerve, where the perineurium was incised and fascicles were separated and stimulated, and the ones that showed intense contraction were considered for ablation. The proximal stump of fewer than 50% of the fascicles in total were cauterised thoroughly with bipolar cautery. Three elbows underwent an additional second-stage procedure after significant spasticity recurred. The terminology used for the procedure was musculocutaneous fasciculotomy.

Maarrawi et al<sup>8</sup> published their results after treating 31 patients with 64 procedures in the upper limb. They described resection of 50% to 80% of the isolated motor branches or fascicles to a muscle over a 5 mm distance and bipolar coagulation proximally to prevent regrowth. The branches or fascicles to be resected were chosen using nerve stimulation, and further electrical stimulation after the resection was used as a subjective measure of adequacy of denervation. Spasticity recurred in five patients and two of them underwent repeat surgery. The terminology that was used in this publication was "selective peripheral neurotomy", although a part of the nerve was removed. The resection took place on the main nerve trunk for the musculocutaneous nerve, and more distally at the level of motor branches or fascicles in the median and ulnar nerves.

Shin et al<sup>9</sup> published their experience treating 14 patients with elbow spasticity in 2010. Nerve stimulation was used to distinguish motor from sensory fibres and 50% to 80% of the motor fascicles were resected over a 5 mm length with no cases of recurrent spasticity requiring further surgery. The terminology used was "selective neurotomy", although part of the nerve was removed. The procedure took place at the level of the main nerve trunk.

Puligopu and Puhorit<sup>10</sup> published the results of 20 patients from their series with more than six months follow-up. The technique they reported was to section the motor nerve branches with the most intense contraction at low stimulation thresholds and typically they would section and resect between one-third and three-quarters of the total branches identified. They reported no recurrences at six months. The terminology they used was “selective motor fasciculotomy”. The resection took place at the level of the motor branches to individual muscles.

In their 2011 study of 22 patients treated for spasticity of the wrist and the fingers, Kwak et al<sup>11</sup> described careful dissection to identify all motor branches using nerve stimulation followed by resection of 50% to 80% of the motor branches or fascicles. The term used was “selective neurectomy”. The procedure took place at the level of the motor branches to individual muscles.

Fouad<sup>12</sup> published the results of ten patients who had spasticity in the median and ulnar nerve-innervated muscles. After careful dissection and use of nerve stimulation the motor branches were identified and resection of 50% to 80% of the isolated motor branches or fascicles was performed. When there was more than one branch to a muscle one or more branches were sectioned to achieve the desired denervation. One recurrence was reported and was possibly due to insufficient nerve sectioning. The term used to describe the procedure was “selective peripheral neurectomy”, and the procedure was performed at the level of the motor branches to individual muscles.

Leclercq and Gras<sup>13</sup> reported a series of 63 procedures in 20 patients in conjunction with other procedures. The technique described identifies all motor branches using nerve stimulation and resection of approximately two-thirds of each nerve branch at the level of the rami, depending on the degree of spasticity and the anticipated result. There were no recurrences but there was one failure related to a technical issue. The technique was defined as “hyperselective neurectomy”.

In many publications reporting motor nerve resection for the management of spasticity there is a reasonable consensus that the technique should involve resection of approximately 5 mm of nerve proximal to the site of neurotomy. However, the degree of denervation of the muscle is controversial. Although Brunelli and Brunelli<sup>3</sup> advised removal of two-thirds of the fascicles, further surgery was advocated at or beyond six months. Purohit et al<sup>7</sup> had three recurrences requiring further surgery when fewer than 50% of the fascicles identified at the first surgery were cauterised thoroughly. When 50% to 80% of the nerve branches were resected, two papers reported no recurrence.<sup>9,11</sup> Where it was reported that there was resection of part of the nerve, two more publications reported recurrence.<sup>8,12</sup> Fouad<sup>12</sup> reported in his technique that if there

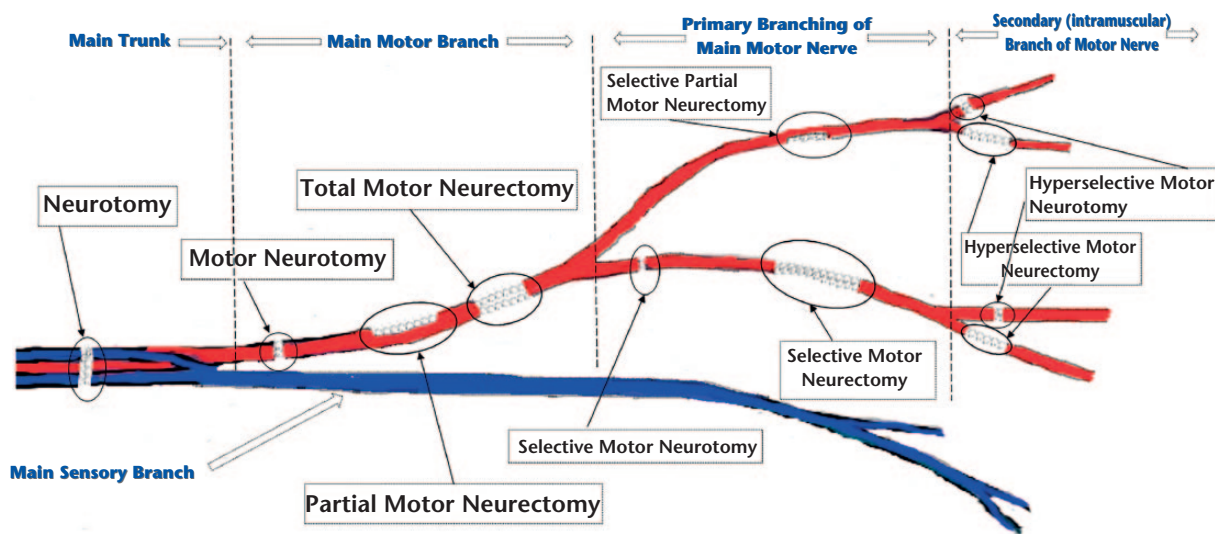
was more than one motor branch to the spastic muscle he performed sectioning of one or more of the branches, but when there was only one motor branch he performed resection of part of the nerve at that level. He also stated that the recurrence reported in his paper was due to insufficient nerve sectioning. Maarrawi et al<sup>8</sup> reported that in their technique they performed resection through bipolar cauterisation. Puligopu and Puhorit<sup>10</sup> reported no recurrence after ablating between one-third and three-quarters of the motor nerve fascicles, having selected ones that demonstrated the most intense contraction when stimulated. They emphasised the need to ensure that the colour of the tissue would change after coagulation to ensure no chance of nerve regrowth. Leclercq and Gras<sup>13</sup> reported resecting two-thirds of the motor nerve fascicles with no recurrence. It is very well understood that dissection of fewer than 50% of the fascicles can increase the likelihood of recurrence, and there is a tendency to dissect more generously because this seems to decrease the recurrence rate. Table 1 summarises the available data in the literature.

## Controversies

The published literature to date suggests that resection of more than 50% of the motor nerve branches is appropriate and that extensive dissection is required to identify all of the motor branches, as anatomical variations are common. Neurectomy is also preferable to neurotomy to avoid regrowth across the site of sectioning, with a 5 mm resection being typical. However, which nerve branches should be sectioned is not clear and the role of intra-operative nerve stimulation is unproven. Future research should focus on providing an accurate electrophysiological assessment of denervation, perhaps through maximal stimulation of the main nerve trunk proximal to branching and direct intramuscular ElectroMyoGraphy (EMG) recording across the whole target muscle. Nerve stimulation is a useful adjunct to help to identify motor branches during dissection. Puligopu and Puhorit<sup>10</sup> reported preferential resection of hyperexcitable nerve branches, but there is no other evidence to support this approach and it is probable that the stimulation achieved is more representative of the degree of extraneural connective tissue resection rather than true axon excitability within the individual motor nerve branches. Consensus is also required on the nomenclature for motor nerve resection for the surgical management of spasticity. “Selective neurotomy” is a commonly described term;<sup>8,9,11</sup> however, “fasciculotomy” has been reported in two publications which seem to originate from the same team,<sup>7,10</sup> whilst Brunelli and Brunelli<sup>3</sup> used the term “partial selective denervation (hyponeurotisation)” in 1983. Fouad<sup>12</sup> used the term “selective peripheral neurectomy” and Leclercq and Gras used the term “hyperselective neurectomy”. The definition of the term “neurotomy”

**Table 1.** Publications on neurectomy for upper limb spasticity

Publications	Patients (n)	Follow-up time	Method of measuring spasticity	Level of neurectomy	Recurrences	Complications
Brunelli and Brunelli 1983 <sup>3</sup>	N/A	N/A	N/A	Motor branches to individual muscle	N/A (high)	N/A
Purohit et al 1998 <sup>7</sup>	52	17 mths (3 to 48)	Grading of spasticity (mild, moderate, severe)	Fasciculotomy at the level of the nerve trunk	9 patients had harmful moderate spasticity – 3 of which underwent repeat surgery	No complications
Maarawi et al 2006 <sup>8</sup>	31	4.5 yrs (1 to 10.2)	Ashworth scale	Fasciculotomy at the level of the nerve trunk, or close to the motor branches close to the main nerve	5 patients – 2 required re-operation	5 patients (2 haematomata, 2 transitory hypoesthesia of the anterior part of the forearm, 1 transient paresis in the wrist and finger flexors for 3 months)
Shin et al 2010 <sup>9</sup>	14	30.71 mths (14 to 54)	Modified Ashworth Scale	Fasciculotomy at the level of the nerve trunk	No recurrence	2 patients (1 wound infection, 1 transient paraesthesia)
Puligopu and Puhorit 2011 <sup>10</sup>	20	10 mths (6 to 24)	Modified Ashworth Scale	Fascicles into the muscle	No recurrence	No complications
Fouad 2011 <sup>12</sup>	10	21 mths (12 to 42)	Modified Ashworth Scale	Isolated motor branches of fascicles were resected (5 mm long from the proximal stump). When several nerve branches, one or more branches were sectioned completely until the global amount needed for the considered muscle was attained	1 patient	1 wound infection, 1 transient paresis of flexors
Kwak et al 2011 <sup>11</sup>	22	39.64 mths (14 to 93)	Modified Ashworth Scale	isolated motor branches or fascicles	No recurrence	2 cases of wound infection, 1 paraesthesia, and 1 dysaesthesia
Leclercq and Gras 2016 <sup>13</sup>	20	10 mths (1.5 to 20)	Modified Ashworth Scale, Tardieu Scale	Each ramus dissected until the neuro-muscular junction and the required amount of fascicles are resected from each ramus (usually 2/3)	1(?) recurrence (related to a technical problem)	1 post-operative haematoma, 1 complete failure of the procedure (related to a technical problem)



**Fig. 1** Proposed terminology based on the definition of the currently-used terms.

is cutting a nerve, when “neurectomy” is defined as the removal of all or part of a nerve. Similarly, “fasciculotomy” means cutting of a fascicle and “denervation” means interruption of the nerve connection to an organ or part. Since all of these terms have been used to describe the same

operation we suggest that there should be a consensus in the terminology and we propose a nomenclature based on the site and degree of nerve resection. Figure 1 shows the proposed terminology that is based on the definition of the used terms.

## Conclusion

Spasticity in muscles may be reduced through surgical resection of all or part of the motor nerve branches to a given muscle. A thorough understanding of the variations in motor nerve innervation is required as well as extensive dissection to identify all branches, and nerve stimulation helps to identify these branches. Further studies are needed to assess the extent of resection necessary, but publications to date suggest that more than 50% of the motor branches should be resected typically in the functional limb. Nerve stimulation and quantification of compound muscle action potentials may help to provide more controlled denervation and predict post-operative function. Research could also be focused on identifying the most excitable fibres within the motor nerve branches to the spastic muscle. Consensus is required on the appropriate nomenclature for nerve resection in spasticity and we define the key terms for selective neurectomy.

### AUTHOR INFORMATION

Birmingham Hand Centre, Queen Elizabeth Medical Centre, UK.

Correspondence should be sent to: Petros Mikalef, The Centre for Nerve Injury and Paralysis, Queen Elizabeth Hospital Birmingham, 6th Floor Nuffield House, Mindelsohn Way, Birmingham, B15 2WB, United Kingdom.  
Email: pmikalef2000@gmail.com

### ICMJE CONFLICT OF INTEREST STATEMENT

None declared.

### FUNDING

No benefits in any form have been received or will be received from a commercial party related directly or indirectly to the subject of this article.

### LICENCE

© 2017 The author(s)

This article is distributed under the terms of the Creative Commons Attribution-Non Commercial 4.0 International (CC BY-NC 4.0) licence (<https://creativecommons.org/licenses/by-nc/4.0/>) which permits non-commercial use, reproduction and distribution of the work without further permission provided the original work is attributed.

### REFERENCES

- Lorenz F.** Über chirurgische behandlung der angeborenen spastischen gliedstarre. *Wien Klin Wochenschr* 1887;2:25-27. (In German)
- Stoffel A.** Treatment of spastic contractures. *Am J Orthop Surg* 1913;210:611.
- Brunelli G, Brunelli F.** Partial selective denervation in spastic palsies (hyponeurotization). *Microsurgery* 1983;4:221-224.
- Cambon-Binder A, Leclercq C.** Anatomical study of the musculocutaneous nerve branching pattern: application for selective neurectomy in the treatment of elbow flexors spasticity. *Surg Radiol Anat* 2015;37:341-348.
- Paulos R, Leclercq C.** Motor branches of the ulnar nerve to the forearm: an anatomical study and guidelines for selective neurectomy. *Surg Radiol Anat* 2015;37:1043-1048.
- Parot C, Leclercq C.** Anatomical study of the motor branches of the median nerve to the forearm and guidelines for selective neurectomy. *Surg Radiol Anat* 2016;38:597-604.
- Purohit AK, Raju BS, Kumar KS, Mallikarjun KD.** Selective musculocutaneous fasciculotomy for spastic elbow in cerebral palsy: a preliminary study. *Acta Neurochir (Wien)* 1998;140:473-478.
- Maarawi J, Mertens P, Luaute J, et al.** Long-term functional results of selective peripheral neurotomy for the treatment of spastic upper limb: prospective study in 31 patients. *J Neurosurg* 2006;104:215-225.
- Shin DK, Jung YJ, Hong JC, Kim MS, Kim SH.** Selective musculocutaneous neurotomy for spastic elbow. *J Korean Neurosurg Soc* 2010;48:236-239.
- Puligopu AK, Purohit AK.** Outcome of selective motor fasciculotomy in the treatment of upper limb spasticity. *J Pediatr Neurosci* 2011;6:S118-S125.
- Kwak KW, Kim MS, Chang CH, Kim SW, Kim SH.** Surgical results of selective median neurotomy for wrist and finger spasticity. *J Korean Neurosurg Soc* 2011;50:95-98.
- Fouad W.** Management of spastic hand by selective peripheral neurotomies. *Alexandria Journal of Medicine* 2011;47:201-208.
- Leclercq C, Gras M.** Hyperselective Neurectomy in the Treatment of the Spastic Upper Limb. *Phys Med Rehabil Int* 2016;3:1075.