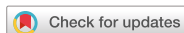

Case Report



Benign Recurrent Intrahepatic Cholestasis Type 2 in Siblings with Novel *ABCB11* Mutations

Min Ji Sohn,¹ Min Hyung Woo,¹ Moon-Woo Seong,² Sung Sup Park,²
Gyeong Hoon Kang,³ Jin Soo Moon,¹ and Jae Sung Ko¹

¹Department of Pediatrics, Seoul National University College of Medicine, Seoul, Korea

²Department of Laboratory Medicine, Seoul National University College of Medicine, Seoul, Korea

³Department of Pathology, Seoul National University College of Medicine, Seoul, Korea



Received: Jan 19, 2018

Revised: May 28, 2018

Accepted: Jun 27, 2018

Correspondence to

Jae Sung Ko

Division of Pediatric Gastroenterology and Hepatology, Department of Pediatrics, Seoul National University Children's Hospital, 101 Daehak-ro, Jongno-gu, Seoul 03080, Korea.
E-mail: kojs@snu.ac.kr

Copyright © 2019 by The Korean Society of Pediatric Gastroenterology, Hepatology and Nutrition

This is an open-access article distributed under the terms of the Creative Commons Attribution Non-Commercial License (<https://creativecommons.org/licenses/by-nc/4.0/>) which permits unrestricted non-commercial use, distribution, and reproduction in any medium, provided the original work is properly cited.

Conflict of Interest

The authors have no financial conflicts of interest.

ABSTRACT

Benign recurrent intrahepatic cholestasis (BRIC), a rare cause of cholestasis, is characterized by recurrent episodes of cholestasis without permanent liver damage. BRIC type 2 (BRIC2) is an autosomal recessive disorder caused by *ABCB11* mutations. A 6-year-old girl had recurrent episodes of jaundice. At two months of age, jaundice and hepatosplenomegaly developed. Liver function tests showed cholestatic hepatitis. A liver biopsy revealed diffuse giant cell transformation, bile duct paucity, intracytoplasmic cholestasis, and periportal fibrosis. An *ABCB11* gene study revealed novel compound heterozygous mutations, including c.2075+3A>G in IVS17 and p.R1221K. Liver function test results were normal at 12 months of age. At six years of age, steatorrhea, jaundice, and pruritus developed. Liver function tests improved following administration of phenylbutyrate and rifampicin. Her younger brother developed jaundice at two months of age and his genetic tests revealed the same mutations as his sister. This is the first report of BRIC2 confirmed by *ABCB11* mutations in Korean siblings.

Keywords: Cholestasis, intrahepatic; *ABCB11*; Mutation; Bile salt export pump

INTRODUCTION

Benign recurrent intrahepatic cholestasis (BRIC) is defined and characterized by intermittent episodes of cholestasis without progression to liver failure. These episodes include symptoms of pruritus and jaundice without extrahepatic bile duct obstruction [1]. The exact prevalence of BRIC remains unknown, but its estimated incidence is approximately 1 in 50,000 to 100,000 people worldwide [2]. BRIC, a rare autosomal recessive inherited disorder in children, is divided into two types, BRIC1 and BRIC2, according to its genetic cause. An *ATP8B1* gene mutation causes BRIC1, while an *ABCB11* gene mutation causes BRIC2, but their phenotypes are nearly identical. A 2004 publication was the first report of a mutation in *ABCB11*, the gene encoding the hepatocellular bile salt export pump (BSEP), causing BRIC2. Mutations in *ABCB11* are also present in progressive familial intrahepatic cholestasis type 2 (PFIC2), but the phenotypes of PFIC2 and BRIC2 differ, despite both being caused by mutations in the same gene [3]. PFIC2 is characterized by progressive liver damage, is more severe than BRIC, and usually requires liver transplantation [4]. Here we report the first case of Korean BRIC2 siblings with novel BSEP mutations.

CASE REPORT

A 6-year-old girl had recurrent episodes of jaundice and pruritus. At two months of age, jaundice with hepatosplenomegaly occurred for the first time. There was no significant familial or medication history. Liver function tests showed cholestatic hepatitis, including elevated levels of bilirubin and liver enzymes: serum aspartate aminotransferase (AST), 2,122 IU/L; alanine aminotransferase (ALT), 1,291 IU/L; total bilirubin (TB), 18.3 mg/dL; and direct bilirubin (DB), 11.0 mg/dL. The testing also revealed a low γ -glutamyltransferase (GGT) level (59 IU/L). The neonatal screening test results for inherited metabolic diseases were normal and other biochemical parameters were within normal ranges. Viral and parasite studies were negative for hepatitis A, B, and C viruses; cytomegalovirus; Epstein-Barr virus; herpes simplex virus; rubella virus; and toxoplasmosis.

On examination, her abdomen was soft and slightly rigid. Bowel sounds were normoactive, and the liver and spleen were both palpated two fingerbreadths below the costal margin. Ultrasonography of the abdomen revealed hepatosplenomegaly, a diffuse gall bladder wall, periportal edema, and no evidence of biliary atresia. A liver biopsy showed a diffuse giant cell transformation, ballooning degeneration, bile duct paucity, intracytoplasmic cholestasis, moderate portal inflammation, and periportal fibrosis (**Fig. 1A**).

She was given medium-chain triglyceride formula, vitamin D, ursodeoxycholic acid, tocopherol, and multivitamins. Her liver function test results were improved a week later: AST, 536 IU/L; ALT, 369 IU/L; TB, 7.8 mg/dL; DB, 6.1 mg/dL; and GGT, 44 IU/L.

ABCB11 and *ATP8B1* gene studies were performed, and the latter was normal. However, the *ABCB11* gene study revealed novel compound heterozygous mutations, including p.R1221K and c.2075+3A>G in IVS17. A familial gene study showed p.R1221K heterozygote status in the mother and c.2075+3A>G in IVS17 heterozygote status in the father. There was no family history except her brother (**Fig. 2A**).

The guanine was replaced by adenosine (c.3662G>A), leading to an amino acid substitution from arginine to lysine (p.R1221K) at the protein level. This mutation is found in 0% (0/180 alleles) of normal controls. The effect of the amino acid substitution on protein function was predicted by PolyPhen-2 analysis (<http://genetics.bwh.harvard.edu/pph2>) and the result

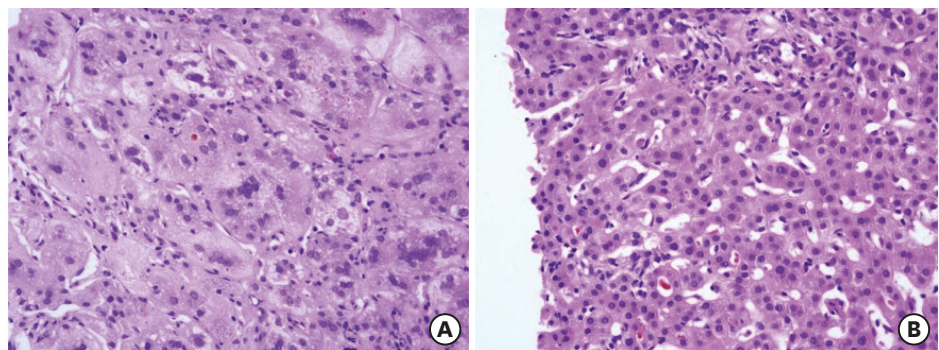


Fig. 1. (A) Photomicrograph of the liver biopsy shows diffuse giant cell transformation of hepatocyte, ballooning degeneration, bile duct paucity, moderate portal inflammation and intracytoplasmic cholestasis (initial liver biopsy, H&E stained, $\times 400$), and (B) intracanalicular cholestasis, bile duct paucity, and minimal to mild focal pericellular fibrosis (recurrent state follow up liver biopsy, H&E stained, $\times 400$). H&E: hematoxylin and eosin.

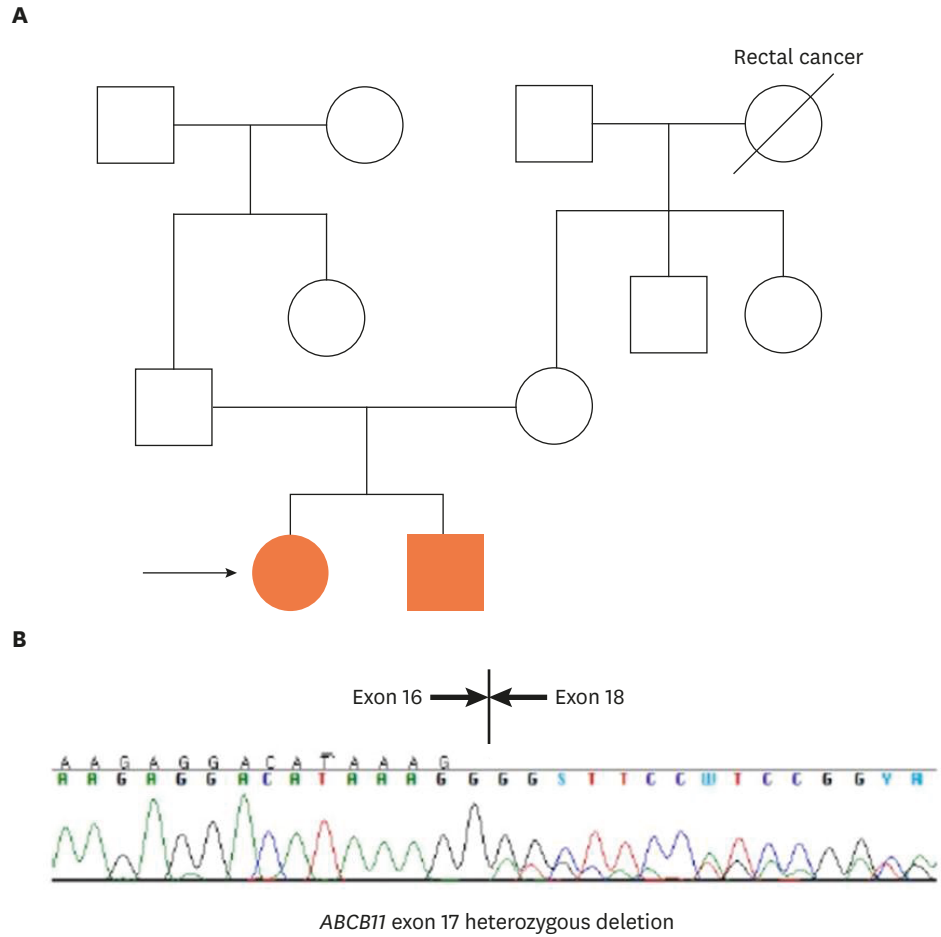


Fig. 2. (A) Pedigrees of family who were subjected to familial genetic analysis and (B) reverse transcription polymerase chain reactions of *ABCB11* gene in both patients showed exon 17 heterozygous deletion.

was predicted to be likely damaging [5]. The pathogenic effects of the missense mutation were also evaluated by Mutation Taster (<http://www.mutationtaster.org>), which revealed its potential to cause disease [6]. The splicing site mutation of c.2075+3A>G is located at the site of intron 17 and causes exon 17 skipping. Exon 17 deletion in our patient was confirmed by reverse transcription polymerase chain reaction (**Fig. 2B**).

Her liver function test results were normal at 12 months of age and she was managed without any medication. However, at six years of age, abdominal pain, steatorrhea, jaundice, and pruritus recurred. Jaundice and pruritus were aggravated and the abdominal pain was relieved after yellowish diarrhea. Her total and direct bilirubin levels were elevated again (TB, 17.0 mg/dL; DB, 11.92 mg/dL), while other liver enzyme levels were normal or slightly higher than normal (AST, 58 IU/L; ALT, 36 IU/L; GGT, 14 IU/L). After treatment with rifampin and phenylbutyrate, the bilirubin values improved (TB, 12.5 mg/dL; DB, 9.18 mg/dL). The pruritus and steatorrhea recurred and the liver enzyme levels increased again when the medication was tapered (TB, 17.4 mg/dL; DB, 12.96 mg/dL; AST, 91 IU/L; ALT, 51 IU/L; GGT, 32 IU/L). A repeat liver biopsy showed bile duct paucity, slender periportal fibrosis, mild pericellular fibrosis, and intracanalicular cholestasis, but the fibrosis had not progressed (**Fig. 1B**). The liver function test results and pruritus improved with phenylbutyrate and rifampicin treatment. Following the last episode and medication cessation, she had no symptom recurrence. BRIC2 was

diagnosed by the clinical findings of recurrent cholestasis and the genetic finding of an *ABCB11* mutation.

Our patient's younger brother was three years old and had jaundice at two months of age. He had loose stools and no vomiting and his jaundice lasted for one month. An evaluation for neonatal cholestasis was performed and his liver function tests also showed cholestatic hepatitis and a low GGT level (AST, 356 IU/L; ALT, 538 IU/L; TB, 5.1 mg/dL; DB, 3.82 mg/dL; GGT, 43 IU/L). Metabolic disease screening test results were within the normal range. Abdominal sonography showed no hepatomegaly, revealed normal hepatic parenchymal echogenicity, and excluded biliary atresia. Genetic testing revealed the same mutations as our patient, his sibling. His liver function test results were normal at six months of age and have remained normal since.

DISCUSSION

BRIC is characterized by recurrent episodes of cholestasis without progressive liver disease. The clinical features of BRIC were first described in 1959 [7], and Luketic and Shiffman [8] have since proposed the following diagnostic criteria: 1) at least two episodes of jaundice separated by a symptom-free interval lasting several months to years, 2) laboratory data consistent with intrahepatic cholestasis, 3) a normal or minimally-elevated GGT level, 4) severe pruritus secondary to cholestasis, 5) centrilobular cholestasis evident on a liver biopsy, 6) normal intra- and extrahepatic bile ducts on cholangiography, and 7) an absence of factors known to be associated with cholestasis. Our patients fulfilled these criteria.

BRIC2 and PFIC2 are considered to be part of a spectrum of intrahepatic cholestasis disorders and the difference between the two diseases is based on phenotypic presentation. They have the same genetic mutation in *ABCB11*, the gene encoding the BSEP protein, the transporter for the secretion of bile salts from the hepatocytes into the canaliculus [3]. The BSEP is the most important transporter of bile salts into the canalicular space, so a deficiency in this gene can cause severe cholestasis. *ABCB11* gene mutations reduce BSEP function and eventually reduce bile salt secretion, which causes the features of BRIC2. More than 100 *ABCB11* mutations have been identified and more than half are missense mutations, including E297G or D482G, the most common BRIC-associated mutations in European families [9,10]. Genetic investigation of the corresponding genes can confirm this diagnosis and immunohistochemical analysis of BSEP in the liver tissue of patients with an *ABCB11* deficiency shows reduced or absent BSEP staining [10,11]. Compared to BRIC, about half of the PFIC2 mutations involve an early stop codon or frameshift in the encoded protein [12].

By sequencing all coding exons of *ABCB11* and *ATP8B1*, we detected c.2075+3A>G and p.R1221K in the *ABCB11* gene of both siblings. The p.R1221K mutation has not been reported before but the effect of this mutation can be predicted by PolyPhen-2 and Mutation Taster. This mutation was expected to affect protein structure and host phenotype. The p.R1221K mutation in the *ABCB11* gene is likely to be pathogenic by the criteria for classifying variants in the American College of Medical Genetics and Genomics guidelines [13]. Our patient had a splicing-site mutation of c.2075+3A>G, which is located at intron 17. This splicing mutation led to exon 17 skipping. A BRIC2 patient was previously reported to have a splicing-site mutation, a nucleotide alteration of IVS 19+1 G>A. Furthermore, 15 splicing site mutations of *ABCB11* were identified in PFIC2, as well as in BRIC2 patients [3,10]. Exon 17 skipping was

also reported in a PFIC patient with an IVS 16-8T>G mutation [14]. Therefore, BRIC2 was confirmed by discovering heterozygotic novel mutations in the *ABCB11* gene.

Treatment of BRIC is symptomatic. No specific treatment to prevent attacks or limit their duration is available [8]. Medication therapy for BRIC involves relieving symptoms, such as pruritus, for which rifampicin and phenylbutyrate are effective [8,15]. Pruritus is caused by the accumulation of bile acid in the hepatocyte membranes. Rifampin competes with the hepatic uptake of bile acid, thus lowering hepatocyte bile concentrations and reducing pruritus [16]. Phenylbutyrate, histone deacetylase inhibitor 4-phenyl butyric acid, was reported to increase functional BSEP expression and bile acid transport via the canalicular membrane *in vivo* in E297G and D482G BSEP, common missense mutations in European BRIC2 patients [15,17,18]. Additionally, its effect on the biochemical markers of cholestasis and liver histology likely depend on the mutation type [19]. Phenylbutyrate was an effective drug for treating various mutations, such as PFIC2 and BRIC2 in *in vitro* studies. In particular, it decreased the biological parameters of cholestasis, increased biliary bile acid secretion, and partially corrected BSEP canalicular expression detected by immunostaining in PFIC2 patients with *ABCB11* mutants [20]. Our patient responded well to phenylbutyrate and rifampicin. However, a further *in vitro* study is needed to evaluate the effect of phenylbutyrate on the transport function of novel BSEP mutations and to develop mutation-targeted therapy.

In conclusion, this is the first report of BRIC2 confirmed by an *ABCB11* gene study in Korean siblings. The novel identification of the mutations of c.2075+3A>G in IVS17 and p.R1221K could help further our understanding of the mechanism of BRIC and determine mutation-specific therapies in the future.

REFERENCES

1. Chawla N, Kudesia S. Benign recurrent intrahepatic cholestasis (BRIC) – a case report and review of literature. *Internet J Pathol* 2008;9.
2. Geethalakshmi S, Mageshkumar S. Benign recurrent intrahepatic cholestasis: a rare case report. *Int J Sci Study* 2014;2:222-4.
3. van Mil SW, van der Woerd WL, van der Brugge G, Sturm E, Jansen PL, Bull LN, et al. Benign recurrent intrahepatic cholestasis type 2 is caused by mutations in *ABCB11*. *Gastroenterology* 2004;127:379-84. [PUBMED](#) | [CROSSREF](#)
4. Kagawa T, Watanabe N, Mochizuki K, Numari A, Ikeno Y, Itoh J, et al. Phenotypic differences in PFIC2 and BRIC2 correlate with protein stability of mutant Bsep and impaired taurocholate secretion in MDCK II cells. *Am J Physiol Gastrointest Liver Physiol* 2008;294:G58-67. [PUBMED](#) | [CROSSREF](#)
5. Adzhubei I, Jordan DM, Sunyaev SR. Predicting functional effect of human missense mutations using PolyPhen-2. *Current protocols in human genetics*. Hoboken (NJ): John Wiley & Sons, Inc., 2013.
6. Schwarz JM, Rödelsperger C, Schuelke M, Seelow D. MutationTaster evaluates disease-causing potential of sequence alterations. *Nat Methods* 2010;7:575-6. [PUBMED](#) | [CROSSREF](#)
7. Summerskill WH, Walshe JM. Benign recurrent intrahepatic “obstructive” jaundice. *Lancet* 1959;2:686-90. [PUBMED](#) | [CROSSREF](#)
8. Luketic VA, Shiffman ML. Benign recurrent intrahepatic cholestasis. *Clin Liver Dis* 2004;8:133-49. [PUBMED](#) | [CROSSREF](#)
9. van der Woerd WL, van Mil SW, Stapelbroek JM, Klomp LW, van de Graaf SF, Houwen RH. Familial cholestasis: progressive familial intrahepatic cholestasis, benign recurrent intrahepatic cholestasis and intrahepatic cholestasis of pregnancy. *Best Pract Res Clin Gastroenterol* 2010;24:541-53. [PUBMED](#) | [CROSSREF](#)

10. Strautnieks SS, Byrne JA, Pawlikowska L, Cebecauerová D, Rayner A, Dutton L, et al. Severe bile salt export pump deficiency: 82 different *ABCB11* mutations in 109 families. *Gastroenterology* 2008;134:1203-14.
[PUBMED](#) | [CROSSREF](#)
11. Keitel V, Burdelski M, Warskulat U, Köhlkamp T, Keppler D, Häussinger D, et al. Expression and localization of hepatobiliary transport proteins in progressive familial intrahepatic cholestasis. *Hepatology* 2005;41:1160-72.
[PUBMED](#) | [CROSSREF](#)
12. Noe J, Kullak-Ublick GA, Jochum W, Stieger B, Kerb R, Haberl M, et al. Impaired expression and function of the bile salt export pump due to three novel *ABCB11* mutations in intrahepatic cholestasis. *J Hepatol* 2005;43:536-43.
[PUBMED](#) | [CROSSREF](#)
13. Richards S, Aziz N, Bale S, Bick D, Das S, Gastier-Foster J, et al. Standards and guidelines for the interpretation of sequence variants: a joint consensus recommendation of the American College of Medical Genetics and Genomics and the Association for Molecular Pathology. *Genet Med* 2015;17:405-24.
[PUBMED](#) | [CROSSREF](#)
14. Knisely AS, Strautnieks SS, Meier Y, Stieger B, Byrne JA, Portmann BC, et al. Hepatocellular carcinoma in ten children under five years of age with bile salt export pump deficiency. *Hepatology* 2006;44:478-86.
[PUBMED](#) | [CROSSREF](#)
15. Hayashi H, Sugiyama Y. 4-phenylbutyrate enhances the cell surface expression and the transport capacity of wild-type and mutated bile salt export pumps. *Hepatology* 2007;45:1506-16.
[PUBMED](#) | [CROSSREF](#)
16. Balsells F, Wyllie R, Steffen R, Kay M. Benign recurrent intrahepatic cholestasis: improvement of pruritus and shortening of the symptomatic phase with rifampin therapy: a case report. *Clin Pediatr (Phila)* 1997;36:483-5.
[PUBMED](#) | [CROSSREF](#)
17. Lee SJ, Kim JE, Choe BH, Seo AN, Bae HI, Hwang SK. Early diagnosis of *ABCB11* spectrum liver disorders by next generation sequencing. *Pediatr Gastroenterol Hepatol Nutr* 2017;20:114-23.
[PUBMED](#) | [CROSSREF](#)
18. Misawa T, Hayashi H, Sugiyama Y, Hashimoto Y. Discovery and structural development of small molecules that enhance transport activity of bile salt export pump mutant associated with progressive familial intrahepatic cholestasis type 2. *Bioorg Med Chem* 2012;20:2940-9.
[PUBMED](#) | [CROSSREF](#)
19. van der Woerd WL, Houwen RH, van de Graaf SF. Current and future therapies for inherited cholestatic liver diseases. *World J Gastroenterol* 2017;23:763-75.
[PUBMED](#) | [CROSSREF](#)
20. Gonzales E, Grosse B, Schuller B, Davit-Spraul A, Conti F, Guettier C, et al. Targeted pharmacotherapy in progressive familial intrahepatic cholestasis type 2: evidence for improvement of cholestasis with 4-phenylbutyrate. *Hepatology* 2015;62:558-66.
[PUBMED](#) | [CROSSREF](#)