

# Rapid reversal of right ventricular pacing–induced cardiomyopathy by His bundle pacing



Amit J. Thosani, MD, FHRS, Emerson Liu, MD, George Shaw, MD, William Belden, MD, John Chenarides, MD

*From the Division of Cardiology, Section of Cardiac Electrophysiology, Allegheny General Hospital, Allegheny Health Network, Pittsburgh, Pennsylvania.*

## Introduction

Chronic right ventricular (RV) pacing may result in left ventricular (LV) systolic dysfunction and heart failure. We present a case of RV pacing–induced cardiomyopathy rapidly and dramatically reversed by His bundle pacing.

## Case report

A 78-year-old woman with hypertension, paroxysmal atrial fibrillation treated with pulmonary vein isolation 4 years prior, and normal biventricular systolic function presented with symptomatic high-grade heart block with junctional escape rhythm and QRS duration of 84 ms (Figure 1A). She underwent dual-chamber pacemaker implantation with apical RV lead placement and resolution of her presenting symptoms. After 6 months of 99% RV pacing with paced QRS duration of 166 ms (Figure 1B), she developed increasing exertional dyspnea and volume overload necessitating hospital admission. Transthoracic echocardiogram during this admission showed decline in left ventricular ejection fraction (LVEF) from 60% prior to pacemaker implantation to 35% (Video 1, available online) with 3+ mitral and tricuspid regurgitation. Following intravenous diuresis, she was discharged with beta blocker, angiotensin-converting enzyme inhibitor, and oral diuretic therapy. Attempts to minimize RV pacing by reprogramming her device were unsuccessful owing to underlying symptomatic slow junctional escape (30–40 beats per minute [bpm]). Two weeks after her initial heart failure hospitalization, she was readmitted with acute systolic heart failure and volume overload. Due to suspected RV pacing–related

cardiomyopathy, and given her narrow intrinsic QRS, we decided to attempt His bundle pacing. We were prepared to perform conventional biventricular pacing if His bundle pacing lead implant was not successful.

Left axillary venous access was obtained and a 7F peel-away sheath placed. A Medtronic (Minneapolis, MN) C315 43-cm His nondeflectable sheath was then advanced through the 7F axillary venous sheath to the right atrium over a guidewire. A Medtronic 3830 69-cm His lead was advanced through the nondeflectable sheath with the distal tip minimally exposed for unipolar mapping of the His bundle region through the pacemaker system analyzer. Twelve-lead electrocardiography was used to analyze pacing morphologies and confirm His bundle capture (Figure 1C). His bundle pacing threshold was 3.0 V at 1.0 ms at implant, and improved to 2.75 V at 1.0 ms after 24 hours. His bundle pacing output was programmed to 5.0 V at 1.0 ms. A biventricular pacemaker was implanted with His bundle pacing 80 ms earlier than RV pacing, as previously described.<sup>1</sup> At 6 months of follow-up the His bundle pacing threshold remained 2.75 V at 1.0 ms with a consistent junctional escape rhythm of 40 bpm. In an effort to improve battery longevity, the RV lead and rate response were programmed off, the His lead pacing output was lowered to 4.0 V at 1.0 ms, the lower rate was decreased to 55 bpm, and a sleep rate of 40 bpm was added. The patient has tolerated these parameters well, with estimated battery longevity of 4 years. Her symptoms fully resolved within 7 days of His bundle pacing and have not recurred. Transthoracic echocardiogram 1 month after His bundle pacing showed improvement of LVEF to 60% with only trace mitral and tricuspid regurgitation (Video 2, available online).

**KEYWORDS** Right ventricular pacing; High-grade heart block; Symptomatic bradycardia; Right ventricular pacing–induced cardiomyopathy; His bundle pacing (Heart Rhythm Case Reports 2017;3:189–191)

**Address reprint requests and correspondence:** Dr Amit J. Thosani, Division of Cardiology, Section of Cardiac Electrophysiology, Allegheny General Hospital, Allegheny Health Network, 320 East North Avenue, Pittsburgh, PA 15212. E-mail address: amit.thosani@ahn.org.

## Discussion

RV pacing–induced cardiomyopathy is a well-documented but incompletely understood phenomenon. LV systolic dysfunction, cumulative ventricular pacing exceeding 40%,

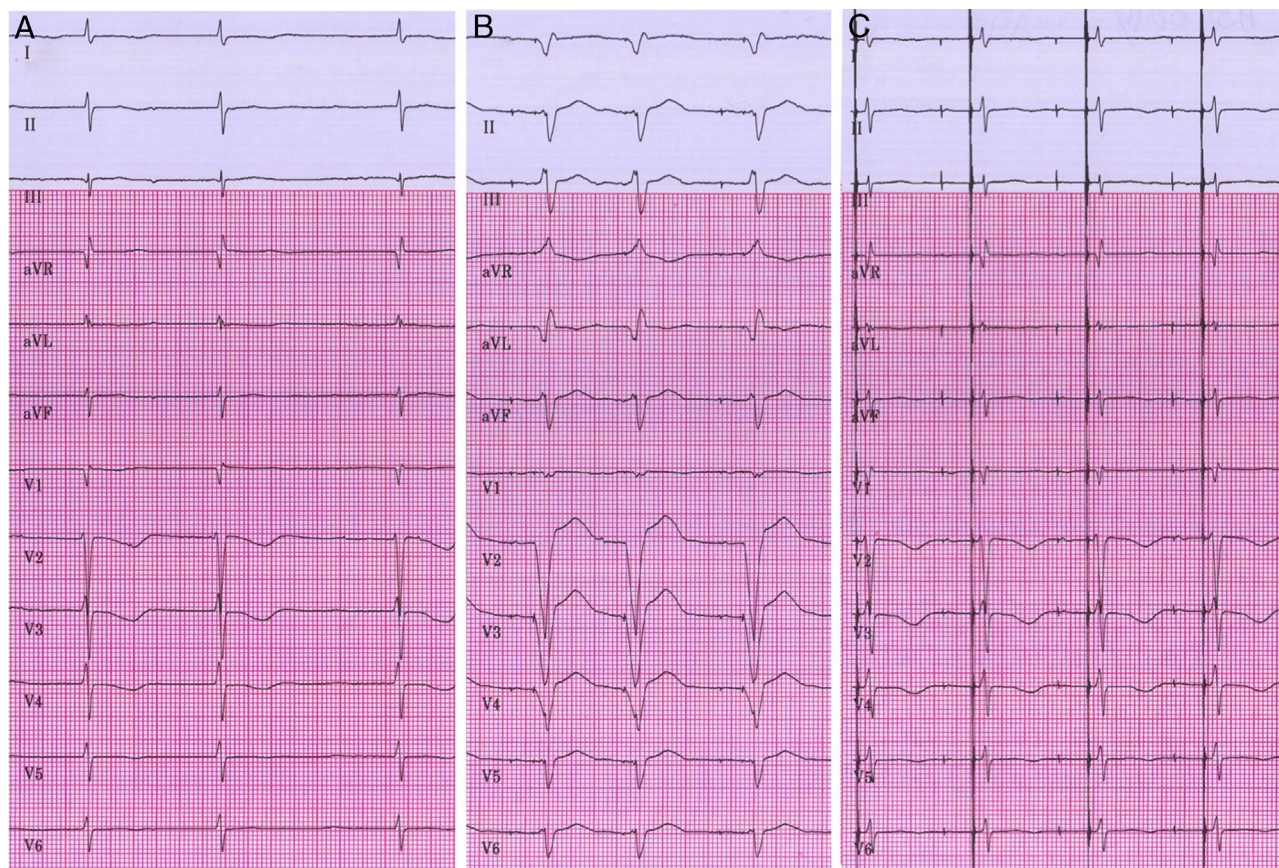
### KEY TEACHING POINTS

- Right ventricular (RV) pacing can result in cardiomyopathy within months of chronic pacing.
- His bundle pacing is a feasible alternative to biventricular pacing for treatment of suspected RV pacing-related cardiomyopathy in the setting of a narrow underlying QRS.
- Physiologic His bundle pacing may result in rapid reversal of cardiomyopathy induced by RV pacing.

and longer paced QRS duration have been reported to increase the risk for developing heart failure.<sup>2,3</sup> Native QRS duration greater than 115 ms with more than 20% RV pacing may also predict development of LV systolic

dysfunction.<sup>4</sup> His bundle pacing has been reported to reverse RV pacing-induced LV systolic dysfunction and decrease mitral regurgitation, likely owing to physiologic ventricular and papillary muscle resynchronization.<sup>5</sup> His bundle pacing has been reported to preemptively reduce heart failure hospitalizations compared with RV pacing in patients requiring more than 40% ventricular pacing.<sup>6</sup>

Patients who have developed suspected RV pacing-induced cardiomyopathy and have a narrow underlying QRS have been reported to benefit from direct His bundle pacing.<sup>7,8</sup> In our patient's case, restoration of physiologic ventricular activation by His bundle pacing resulted in dramatically rapid normalization of LVEF and resolution of heart failure symptoms. Further investigation of His bundle pacing in this patient subset is warranted.



**Figure 1** A: High-grade heart block with narrow underlying QRS. B: Dual-chamber pacing. C: His bundle pacing.

## Appendix

### Supplementary data

Supplementary data are available in the online version of this article at <http://dx.doi.org/10.1016/j.hrcr.2017.01.004>

### References

1. Dandamudi G, Vijayaraman P. How to perform permanent His bundle pacing in routine clinical practice. *Heart Rhythm* 2016;13:1362–1366.
2. Lamas GA, Lee KL, Sweeney MO, et al. Most Selection Trial in sinus node dysfunction (MOST). *N Engl J Med* 2002;346:1854–1862.
3. Shukla HH, Hellkamp AS, James EA, Flaker GC, Lee KL, Sweeney MO, Lamas GA. Heart failure hospitalization is more common in pacemaker patients with sinus node dysfunction and a prolonged paced QRS duration. *Heart Rhythm* 2005;2:245–251.
4. Khurshid S, Epstein AE, Verdino RJ, Lin D, Goldberg LR, Marchlinski FE, Frankel DS. Incidence and predictors of right ventricular pacing-induced cardiomyopathy. *Heart Rhythm* 2014;11:1619–1625.
5. Catanzariti D, Manies M, Manica A, Angheben C, Varbaro A, Vergara G. Permanent His-bundle pacing maintains long-term ventricular synchrony and left ventricular performance, unlike conventional right ventricular apical pacing. *Europace* 2013;15:546–553.
6. Sharma PS, Dandamudi G, Naperkowski A, Oren JW, Storm RH, Ellenbogen KA, Vijayaraman P. Permanent His-bundle pacing is feasible, safe, and superior to right ventricular pacing in routine clinical practice. *Heart Rhythm* 2015;12:305–312.
7. Rehwinkel AE, Muller JG, VanBuren PC, Lustgarten DL. Ventricular resynchronization by implementation of direct His bundle pacing in a patient with congenital complete AV block and newly diagnosed cardiomyopathy. *J Cardiovasc Electro-physiol* 2011;22:818–821.
8. Iida Y, Izawa T, Kobari C, Yatsuhashi T, Makishima N. Successful resynchronization by permanent His-bundle pacing in a patient with pacing-induced cardiomyopathy. *J Arrhythm* 2016;32(6):499–501.