

Case Report

Challenge and Outcome for the Prostate Squamous Cell Carcinoma Which Developed 8 Years after Low-Dose-Rate Brachytherapy Approached by a Combined Multimodal Treatment with High-Dose-Rate Interstitial Brachytherapy, External Beam Radiation Therapy, and Chemotherapy

Toru Matsugasumi^{a, b} Koji Masui^c Kaori Yamada^d Sho Watanabe^d
Koji Okihara^{a, e} Nana Kozawa^f Yasuhiro Yamada^a Hideya Yamazaki^c
Kei Yamada^c Osamu Ukimura^a

^aDepartment of Urology, Kyoto Prefectural University of Medicine, Kyoto, Japan;

^bDepartment of Urology, Kyoto Kidugawa Hospital, Kyoto, Japan; ^cDepartment of Radiation Oncology, Kyoto Second Red Cross Hospital, Kyoto, Japan; ^dDepartment of Radiology, Kyoto Prefectural University of Medicine, Kyoto, Japan; ^eDepartment of Urology, North Medical Center, Kyoto Prefectural University of Medicine, Kyoto, Japan; ^fDepartment of Radiology, Kyoto Kuramaguchi Medical Center, Kyoto, Japan

Keywords

High-dose-rate interstitial brachytherapy · Prostate cancer · Prostate squamous cell carcinoma

Abstract

Prostate squamous cell carcinoma (pSCC) rarely develops as a secondary cancer after treatment with low-dose-rate brachytherapy (LDR-BT). There is no established effective treatment for the disease condition. Herein, we present a 78-year-old man who developed pSCC 8 years after LDR-BT. He was subsequently selected to receive a combined multimodal treatment with high-dose-rate interstitial brachytherapy (HDR-ISBT), external beam radiation therapy, and chemotherapy for his pSCC. Eleven months later, he displayed no biochemical failure nor clinical radiographic recurrence. However, MRI detected a newly developed prostatic-rectal fistula

Toru Matsugasumi and Koji Masui contributed equally.

(grade 4), and a colostomy was performed to relieve pain and inflammation. To our knowledge, this is the first report to perform a combined multimodal treatment with HDR-ISBT for pSCC suspected as a secondary cancer due to LDR-BT.

© 2021 The Author(s).
Published by S. Karger AG, Basel

Introduction

Squamous cell carcinoma (SCC) rarely develops as a secondary cancer in the prostate after treatment with low-dose-rate brachytherapy (LDR-BT). There is not yet established effective treatment for this disease condition. Local salvage therapy for recurrent prostate cancer (PCa) is clinically indicated as compared with radical prostatectomy (RP), brachytherapy, cryotherapy, high-intensity focused ultrasound, and stereotactic body radiotherapy [1, 2]. The National Comprehensive Cancer Network guidelines recommend high-dose-rate interstitial brachytherapy (HDR-ISBT) as a salvage therapy for local PCa recurrence. Here, we have experienced a man with prostate SCC (pSCC) who underwent a combined multimodal treatment with HDR-ISBT, external beam radiation therapy (EBRT), and chemotherapy for the pSCC which developed 8 years after LDR-BT. To our knowledge, this is the first report of a combined multimodal treatment with HDR-ISBT for pSCC suspected as a secondary cancer due to LDR-BT.

Case Report

A 78-year-old man underwent a prostate biopsy 8 years ago. PCa was detected with a Gleason score of 3 + 4 at one site, located in the transitional zone, out of 8 prostate biopsies. He was diagnosed with localized PCa (T2aN0M0) by CT/bone scan and treated with neoadjuvant androgen-deprivation therapy for 6 months. He also had iodine-125 (¹²⁵I) implantation and LDR-BT. In total, 15.3 MBeq and 60 ¹²⁵I seeds were applied (total 145 Gy). He experienced no biochemical failure, in accordance with the Phoenix definition with the prostate-specific antigen of <0.04 ng/mL. Eight years later, he had a complaint of persistent micturition pain. Urine cytology and cultures were negative, and the value of prostate-specific antigen was 0.017 ng/mL. Cystoscopy revealed urethral stenosis near the colliculus seminalis, due to fibrous deposits. On MR examination, the entire prostate was occupied by lesions with strong hypointensity on T2-weighted images, obscuring the normal prostatic urethra. Diffusion-weighted and dynamic contrast-enhanced MRI showed peripheral hyperintense and central hypointense appearance. Sagittal images showed that the tumor extended directly to the dorsal cortex of the pubis. These findings suggested an infiltrative malignant tumor with internal necrosis (PI-RADS 5) (Fig. 1).

He underwent an MRI/ultrasound fusion biopsy. From this, SCC was detected in all 8 sites out of 8 prostate biopsy specimens (Fig. 2). A contrast-enhanced whole-body CT showed no other cancer. Prostate SCC was diagnosed as T4N1M0, with pubic infiltration and swelling of the obturator lymph node. As total pelvic exenteration was planned but as radical surgery was considered to be too difficult, a combined multimodal treatment with HDR-ISBT, EBRT, and chemotherapy was finally selected. He underwent administration of 2 chemotherapy courses, including cisplatin (CDDP) at 80 mg/m² on day 1 and continuous 5-fluorouracil (5-FU) infusion at 800 mg/m² on days 1–5 prior to HDR-ISBT. This was combined with EBRT for the pelvis at 45 Gy/25 fractions, in order to treat the obturator lymph node metastasis. Fourteen applicators (ProGuide Sharp Needle; Nucletron, ELEKTA AB, Stockholm, Sweden) were

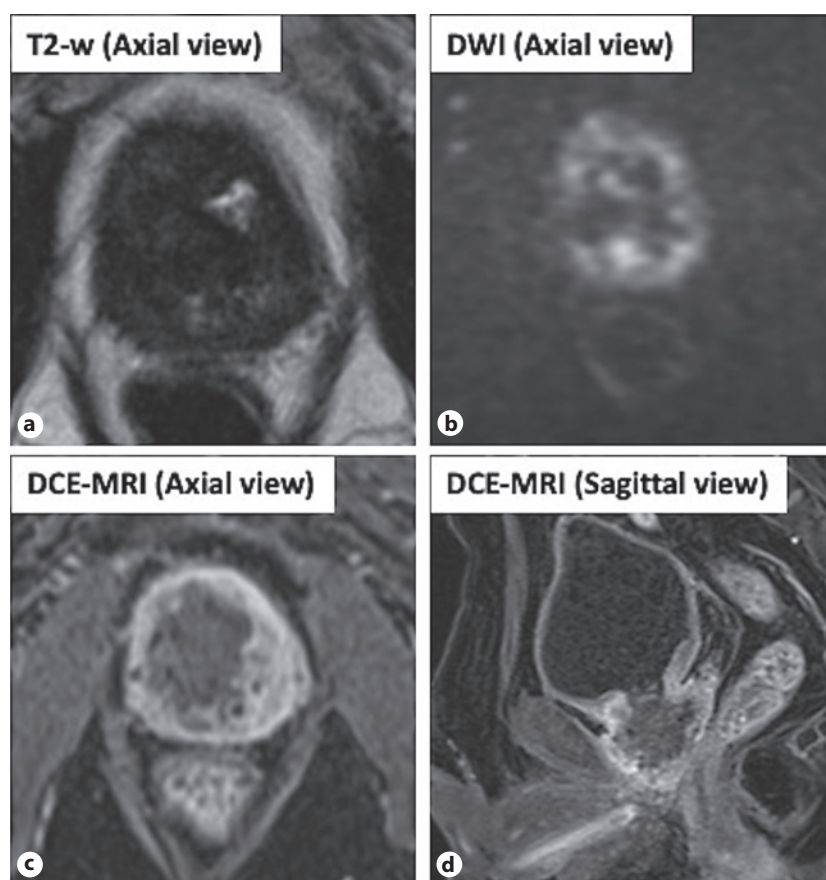


Fig. 1. Prebiopsy MRI showed that the entire prostate was occupied by lesions with strong hypointensity on T2-weighted images (a), obscuring the normal prostatic urethra. Diffusion-weighted (b) and dynamic contrast-enhanced MRI (c, d) showed peripheral hyperintense and central hypointense appearance. Sagittal images (d) showed that the tumor extended directly to the dorsal cortex of the pubis. These findings suggested an infiltrative malignant tumor with internal necrosis (PI-RADS 5).

inserted combined with transrectal and transabdominal ultrasound (ALOKA Prosound Alpha 7; Hitachi ALOKA Medical, Tokyo, Japan) under spinal anesthesia. After inserting the applicators, a space creator for Denonvilliers' space (Space OAR; Boston Scientific, Marlborough, MA, USA) was applied to avoid adverse event for the rectum. Bleeding was minimal, and perioperative complications were not found. Through dose calculations using Oncentra Brachy (Nucletron), HDR-ISBT at 25 Gy was performed in 5 fractions for 2 days (twice daily with 6-h intervals) using a ^{192}Ir remote after-loading system (MicroSelectron V3[®] HDR; Nucletron). No adjuvant chemotherapy was administered.

After HDR-ISBT, serum SCC markers decreased from 3.3 to 0.8 ng/mL. On MRI evaluated at 1, 3, 4, 6, and 10 months after the treatment, the contrast enhancement of the cancer lesion was significantly reduced (Fig. 3), resulting in accomplishment of radiographic complete response 6 months after the treatment. Acute and late side effects were classified according to the Radiation Therapy Oncology Group and the European Organization for Research and Treatment of Cancer [3]. Four months later, a urethral stricture (grade 3), as a new-onset toxicity in late phase, was observed, and a transurethral prostate resection and MR/ultrasound fusion biopsy were performed. Two positive cores out of 12 prostate biopsies detected remnant SCC. Six months later, he complained of perineal pain and gas turbidity in the urine. As MRI detected a newly developed prostatic-rectal fistula (grade 4), a colostomy was

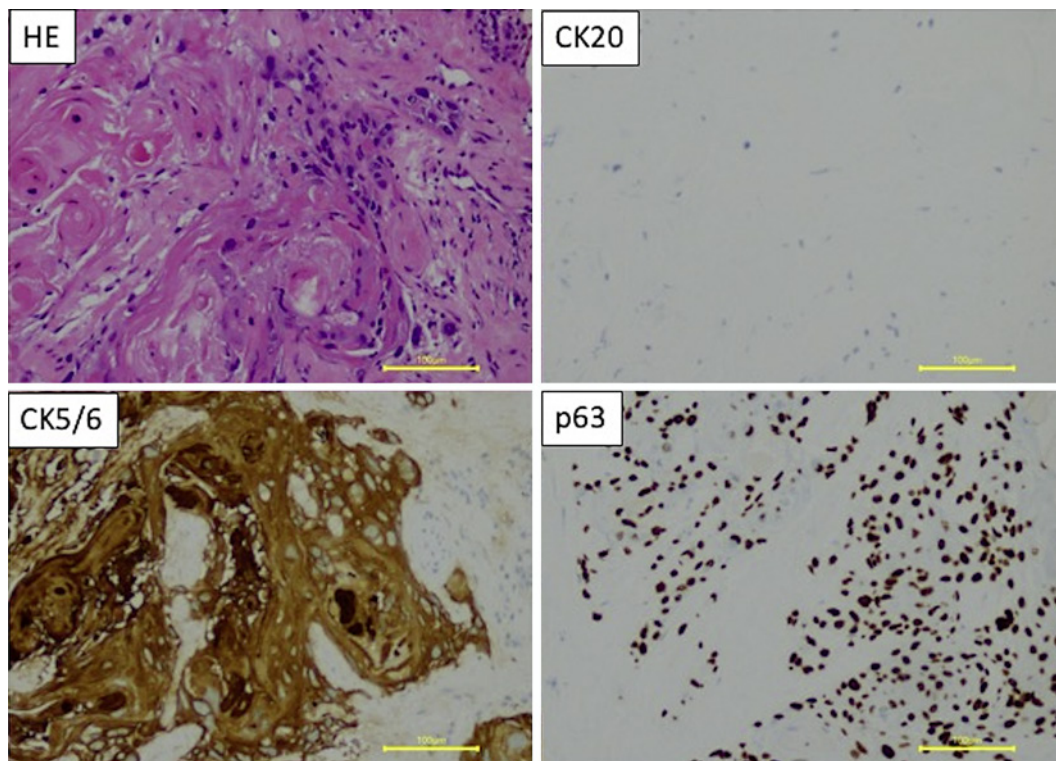


Fig. 2. Pathology revealed a nest of malignant squamous cells, with cytoplasmic keratinization and heterocysts of various karyotype sizes and shapes (HE staining; scale, 100 μ m). This was accompanied by keratinization without clear lumen-like structures. pSCC diagnosis; negative CK20, positive CK5/6, positive p63. pSCC, prostate squamous cell carcinoma.

performed to relieve pain and inflammation. No biochemical failure or clinical radiographic recurrence was observed at 12 months after the salvage treatment.

Discussion

Prostate SCC is rare and accounts for 0.6–1.0% of primary prostate tumors [4]. Murray et al. [5] described cancers with different tissue types to the primary cancer as secondary, which is developing in an irradiation field >5 years after radiotherapy. The frequency of secondary pSCC is unknown. In our institute, 817 LDR-BT cases were conducted between 2005 and 2020, and only one developed pSCC (0.1%). pSCC may develop from prostatic urethral epithelial cells, the periurethral duct, or pluripotent stem cells [4]. Approximately 50% of the reported pSCCs underwent androgen-deprivation therapy and/or radiation therapy for primary PCa [4]. Mott [6] proposed the following criteria for pure primary SCC diagnosis because squamous cell metaplasia may also occur in normal prostate and adenocarcinoma due to inflammation and treatment effects: (1) clearly malignant features including disorganized growth patterns, cellular anaplasia, and invasion; (2) squamous differentiation, including keratinization, squamous pearls, or distinct intercellular bridges; (3) lack of glandular/acinar components; (4) no prior estrogen therapy; and (5) no primary SCC elsewhere. Our case matched these criteria. Urinary retention and dysuria are the most common clinical symptoms of pSCC, with hematuria and pain often reported. Increased metastases such as in the liver, lung, lymph nodes, penis, and peritoneal dissemination are observed more frequently

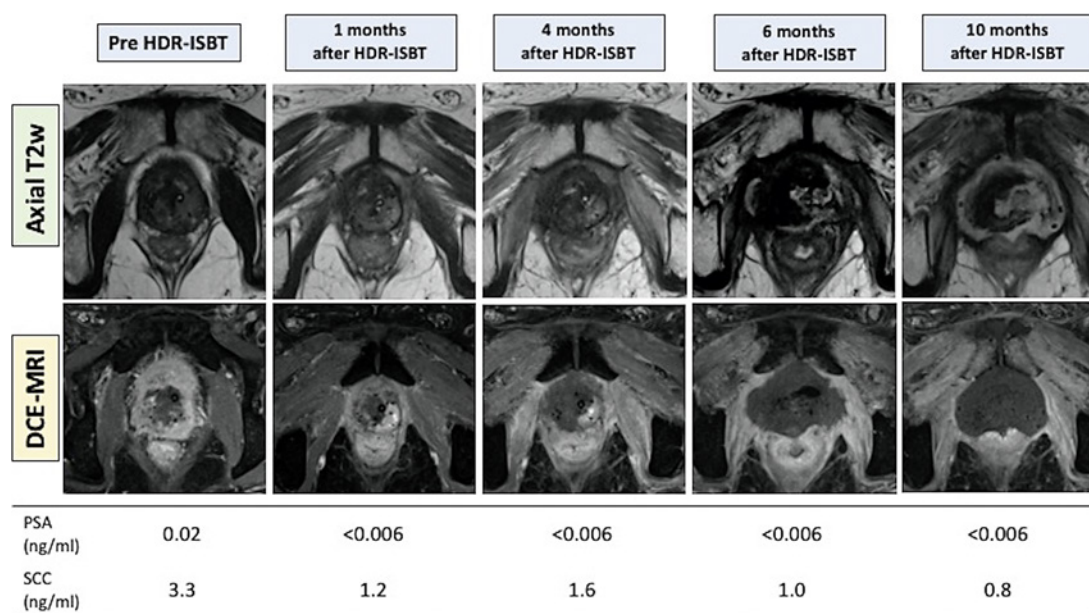


Fig. 3. Time course of MRI and serum PSA and SCC data. MRI at 1, 3, 4, and 6 months after HDR-ISBT and EBRT revealed significant decrease in size and/or enhancement of the cancerous lesions. PSA, prostate-specific antigen; SCC, squamous cell carcinoma; HDR-ISBT, high-dose-rate interstitial brachytherapy; EBRT, external beam radiation therapy.

when compared to adenocarcinoma of the prostate, and bone lesions may cause osteolytic metastasis [3]. The prognosis for pSCC is poor, and average survival times are 14–24 months, which are poorer compared to adenocarcinoma. However, the average survival time for secondary PCa remains unknown [7]. In our case, pain triggered the diagnosis before occurrence of distant metastasis. As no standard radical treatments have been established due to its condition rarity, multidisciplinary treatment, including surgery, chemotherapy, radiation, and hormone therapy, has been attempted [3]. Here, although total pelvic exenteration was planned for the purpose of pSCC volume reduction, it was not selected because of difficulty due to pubic infiltration, and as a consequence combined multimodal treatment with HDR-ISBT, EBRT, and chemotherapy was selected.

Salvage therapies after radiotherapy for PCa include local control such as RP, brachytherapy, cryotherapy, high-intensity focused ultrasound, and stereotactic body radiotherapy [1]. HDR-ISBT is reported to be applicable for intermediate- to high-risk PCa [8] and SCC in head and neck regions [9–11]. Currently, although no consensus exists for strategy for repeat of local therapy for organ-confined recurrent PCa [12], salvage ISBT is reported for PCa recurrence [2]. Wojcieszek et al. [13] reported 83 recurrent PCa cases who had 3- and 5-year biochemical disease-free survival of 76 and 67% in a median follow-up of 41 months, and 5-year cause-specific survival and overall survival were 87 and 86%, respectively.

HDR-ISBT is an ideal RT approach for salvage irradiation, with technological advances in real-time image guidance and 3D image-guided treatment planning. As recurrent PCa often has local extension to extraprostate space, HDR is expected to provide greater treatment effects on the extraprostate extension in addition to prostate itself in comparison with the surgical prostatectomy which aims to remove only prostate-organ itself; in addition, as the bladder and rectal doses remain significantly lower than when treated with dose-escalation EBRT, adverse events could be less [12].

To our knowledge, this is the first report of HDR-ISBT for pSCC suspected as secondary cancer. Interstitial radio needles were safely delivered to cover the entire tumor, with use of spaceOAR® to reduce adverse event to the rectum. No biochemical failure or clinical radiographic recurrence was observed at 12 months after salvage treatment; however, urethral stricture (grade 3) at 4 months and prostatic-rectal fistula (grade 4) at 6 months after treatment occurred. Lyszek et al. [14] reported their experience of salvage HDR in 115 patients with locally recurrent PCa after definitive RT, in which uncontrolled hematuria, urethral fistulas, bladder outlet obstruction requiring continuous catheterization, and complete urinary incontinence were observed. Similarly, Oliai et al. [15, 16] reported their experience of salvage HDR in 22 patients, in which 7 (32%) developed urethral strictures requiring transurethral resection. On the other hand, a systematic review reported rate of adverse event for rectal injury was 0–28% in salvage RP for radiation-recurrent PCa [15].

Conclusion

We reported pSCC suspected as a secondary cancer 8 years after LDR-BT. The patient was treated by a combined multimodal treatment with HDR-ISBT, EBRT, and chemotherapy, with no biochemical failure or clinical radiographic recurrence at 12 months after the treatment. To our knowledge, this is the first report of multimodal treatment with HDR-ISBT for pSCC suspected as secondary cancer 8 years after LDR-BT.

Statement of Ethics

Our patient provided written informed consent for the publication of her clinical course.

Conflict of Interest Statement

The authors have no conflicts of interest to declare.

Funding Sources

This research did not receive any specific grant from funding agencies in the public, commercial, or not-for-profit sectors.

Author Contributions

Toru Matsugasumi and Koji Masui designed the study and wrote the initial draft of the manuscript. Hideya Yamazaki, Kei Yamada, and Osamu Ukimura contributed to revise it critically for important intellectual content. All other authors have contributed to data collection and interpretation and reviewed the manuscript. All authors approved the final version of the manuscript and agree to be accountable for all aspects of the work in ensuring that questions related to the accuracy or integrity of any part of the work are appropriately investigated and resolved.

References

- 1 Ward JF, Pagliaro LC, Pisters LL. Salvage therapy for radiorecurrent prostate cancer. *Curr Probl Cancer*. 2008; 32:242–71.
- 2 Valle LF, Lehrer EJ, Markovic D, Elashoff D, Levin-Epstein R, Karnes RJ, et al. A systematic review and meta-analysis of local salvage therapies after radiotherapy for prostate cancer (Master). *Eur Urol*. 2020;S0302–2838(20):30874–5.
- 3 Cox JD, Stetz J, Pajak TF. Toxicity criteria of the radiation therapy oncology group (RTOG) and the European organization for research and treatment of cancer (EORTC). *Int J Radiat Oncol Biol Phys*. 1995;31:1341–6.
- 4 Arva NC, Das K. Diagnostic dilemmas of squamous differentiation in prostate carcinoma case report and review of the literature. *Diagn Pathol*. 2011;6:46.
- 5 Murray L, Henry A, Hoskin P, Siebert FA, Venselaar J; PROBATE group of GEC ESTRO. Second primary cancers after radiation for prostate cancer: a systematic review of the clinical data and impact of treatment technique. *Radiother Oncol*. 2014;110:213–28.
- 6 Mott LJ. Squamous cell carcinoma of the prostate: report of 2 cases and review of the literature. *J Urol*. 1979; 121:833–5.
- 7 Matsugasumi T, Nakanishi H, Yokota T, Shiraishi T, Ukimura O. Prostate squamous cell carcinoma developing 11 years after external radiotherapy for prostate adenocarcinoma. *IJU Case Rep*. 2020;3(4):121–4.
- 8 Yoshida K, Yamazaki H, Takenaka T, Kotsuma T, Yoshida M, Masui K, et al. High-dose-rate interstitial brachytherapy in combination with androgen deprivation therapy for prostate cancer: are high-risk patients good candidates? *Strahlenther Onkol*. 2014;190:1015–20.
- 9 Bansal A, Ghoshal S, Oinam AS, Sharma SC, Dhanireddy B, Kapoor R. High-dose-rate interstitial brachytherapy in early stage oral tongue cancer: 15 year experience from a tertiary care institute. *J Contemp Brachytherapy*. 2016;8:56–65.
- 10 Murakami N, Ueno T, Yatsuoka W, Okamoto H, Tselis N, Masui K, et al. Dose coverage comparison between “interstitial catheter-only” and “hybrid intracavitary-interstitial brachytherapy” for early stage squamous cell carcinoma of the buccal mucosa. *J Contemp Brachytherapy*. 2018;10:486–91.
- 11 Strnad V. Treatment of oral cavity and oropharyngeal cancer. Indications, technical aspects, and results of interstitial brachytherapy. *Strahlenther Onkol*. 2004;180:710–7.
- 12 Chatzikonstantinou G, Zamboglou N, Rödel C, Zoga E, Strouthos I, Butt SA, et al. High-dose-rate brachytherapy as salvage modality for locally recurrent prostate cancer after definitive radiotherapy: a systematic review. *Strahlenther Onkol*. 2017;193:683–91.
- 13 Wojcieszek P, Szlag M, Głowacki G, Cholewka A, Gawkowska-Suwińska M, Kellas-Ślęczka S, et al. Salvage high-dose-rate brachytherapy for locally recurrent prostate cancer after primary radiotherapy failure. *Radiother Oncol*. 2016;119:405–10.
- 14 Łyczek J, Kawczyńska MM, Garmol D, Kasproicz A, Kulik A, Dąbkowski M, et al. HDR brachytherapy as a solution in recurrences of locally advanced prostate cancer. *J Contemp Brachytherapy*. 2009;1(2):105–8.
- 15 Chade DC, Eastham J, Graefen M, Hu JC, Karnes RJ, Klotz L, et al. Cancer control and functional outcomes of salvage radical prostatectomy for radiation-recurrent prostate cancer: a systematic review of the literature. *Eur Urol*. 2012;61:961–71.
- 16 Oliai C, Yang L, Lee JY. Prospective quality of life and efficacy of high-dose-rate brachytherapy salvage for recurrent prostate cancer. *Int J Radiat Oncol Biol Phys*. 2013;87:396.