

Management of anesthesia in unspecified extra-adrenal pheochromocytoma patient who used beta-blocker

Ayşe Belin Ozer,

Ismail Demirel, Ozgur Duzgol,

Refik Ayten¹, Omer Lutfi Erhan

Departments of Anesthesiology and Reanimation, and ¹General Surgery, Faculty of Medicine, Firat University, Elazig 23119, Turkey

Address for correspondence:

Dr. Ayşe Belin Ozer,
Department of Anesthesiology and Reanimation, Faculty of Medicine,
Firat University, Elazig 23119, Turkey.
E-mail: abelinozer@gmail.com

ABSTRACT

An operation was planned for a female patient aged 59 for intra-abdominal mass. The patient was using nebivolol for hypertension. Blood pressure (BP) of the patient was raised to 200/130 mmHg during anesthesia induction. BP was gradually reduced by remifentanyl infusion. Following the manipulation of the mass, BP began to increase (225/160 mmHg), thus nitroglycerin and followed nitroprusside infusion was started. Propofol (200 + 200 mg) and furosemide (20 mg) were administered intravenously. BP suddenly dropped (90/60 mmHg) following the removal of the mass, nitroglycerine, and nitroprusside infusions were stopped; remifentanyl dose was decreased and fluid was quickly infused. The patient was uneventually recovered. Vanilmandelic acid level was higher in the patient and pheochromocytoma was considered.

Key words: Adrenergic beta-antagonists, anesthesia, general, pheochromocytoma

INTRODUCTION

Pheochromocytoma is a neuroectodermal tumor stemming from chromaffin cells of sympathetic nervous system.^[1] Its prevalence in the general population is 2-8 in a million.^[2]

While pheochromocytoma is localized in the adrenal medulla in 90% of the patients, its localization is extra-adrenal in 10%. Extra-adrenal pheochromocytoma develops predominantly in the organ of Zuckerlandl, and also in thorax, abdomen, pelvis, mediastinum, and neck.^[1] The most frequent symptoms are paroxysmal hypertension, headache, palpitation, and sweating. However, it can also follow a course with such atypical symptoms as nausea, vomiting, and epigastric distress.^[3] An uncontrolled pheochromocytoma may cause life-threatening hypertensive crisis and cardiac arrhythmia. While surgery-related mortality in pheochromocytoma patients undergoing treatment is 2.4%, surgery-related mortality in unspecified

pheochromocytoma was reported to reach up to 80%. Therefore, it is the importance for pheochromocytoma to be specified in the preoperative period and suitable pharmacotherapy to be implemented.^[4,5]

We would like to present our approach to a patient with pheochromocytoma with extra-adrenal localization unspecified in the preoperative period who use beta-blockers and that follow a course with malignant hypertension.

CASE REPORT

Laparotomy and mass excision was planned following the detection of intra-abdominal mass in a 59-year-old female patient that presented to general surgery clinic with complaints of epigastric distress. Patient was evaluated preoperatively. The patient had hypertension for 2 years and was using nebivolol (5 mg). Her physical examination was normal. Heart rate was 79/min and blood pressure (BP) was 150/90 mmHg at the time of preoperative examination laboratory findings of the patient were normal (hemoglobin/hematocrit: 14/44, fasting blood glucose: 84 mg/dl, aspartate aminotransferase/alanine transaminase: 21/41, urea/creatinine: 40/0.89). Electrocardiogram (ECG) and posterior to the anterior chest radiography did not present any characteristics, and abdominal ultrasonography showed an approximately

Access this article online

Quick Response Code:



Website:

www.saudija.org

DOI:

10.4103/1658-354X.144088

10 cm × 9 cm mass with heterogeneous appearance in the adjacency of pancreas tail and left kidney in left upper quadrant. As it stands, the patient was considered American Society of Anesthesiologists II risk class and was recommended her to use own drug in the morning of operation day.

The patient that was planned general anesthesia was administered intramuscular 2.5 mg midazolam and 0.5 mg atropine half an hour before the operation. The patient that was taken to the operation room was monitored with ECG, noninvasive blood pressure, and SpO₂. Heart rate of the patient was 65/min, BP was 165/106 mmHg, and SpO₂ was 96%. Anesthesia was induced with 400 mg sodium thiopental, 8 mg vecuronium, and 100 mcg fentanyl intravenously. Following the anesthesia induction, BP was raised to 200/130 mmHg. BP of the patient who was known to have hypertension was considered to increase as a response to endotracheal intubation; however, this increase was much higher than expected. While anesthetics were maintained with 2-2.5% sevoflurane in 50% O₂ -50% air, remifentanyl infusion was commenced for analgesics purposes (0.25 >0.5 mcg/kg/min). BP dropped gradually, and surgery was commenced 10 min after induction. Hemodynamics followed a stable course at the time of laparotomy [Figure 1]. BP began to rise after the manipulation of the mass was started 60 min after induction; therefore, remifentanyl dose was increased (0.5 >1 >1.5 mcg/kg/min) and nitroglycerin infusion was commenced (5 > 100 >5 mcg/min). Surgery was stopped along with an increase in BP to 225/160 mmHg; 200 mg propofol and 20 mg furosemide were administered intravenously. Pheochromocytoma was considered and left radial artery cannulation was inserted for the monitoring of BP. Upon the absence of a significant decrease in BP, surgery continued; propofol (200 mg) was repeated, and nitroprusside infusion (2 >10 mcg/kg/min) was commenced. Due to the fact that the BP spontaneously dropped to 90/60 mmHg upon the removal of mass,

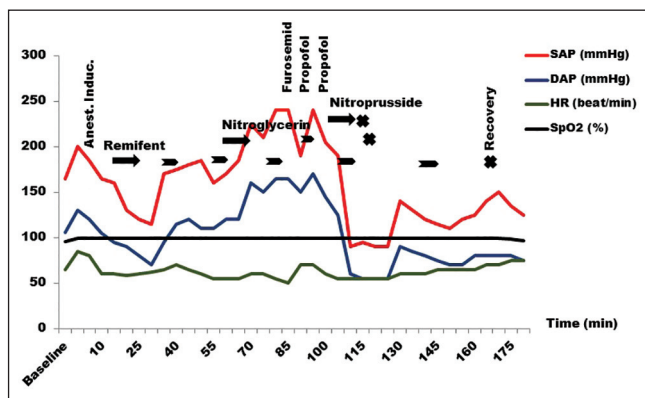


Figure 1: Anesthesia management of the patient with pheochromocytoma

nitroglycerin, and nitroprusside infusion were terminated; remifentanyl infusion rate (0.5 >0.2 mcg/kg/min) was decreased and 2000 ml 0.9% NaCl solution was infused quickly. Systolic BP was maintained at 120-150 mmHg. Upon the termination of surgery 165 min after the induction, patient was recovered uneventfully. In the intraoperative period, patient was infused 4000 ml crystalloid of which 2000 ml was ringer lactate and the remaining 2000 ml was 0.9% NaCl. Urination was monitored through urinary catheterization conducted in the clinic in the preoperative period, and 1000 ml urine was collected in the drainage bag. Vanilmandelic acid was investigated in urine and excised mass was examined pathologically.

Patient who was taken to the recovery room had normal conscience and hemodynamics and was then transferred to the clinic as modified Aldrete score was higher than 9. Because intraoperative BP was high for a long time, patient was evaluated by Neurology Clinic on the first postoperative day and computerized brain tomography was evaluated. Patient who was not established to have any neurological pathology was discharged on postoperative 5th day. Urine vanilmandelic acid level was measured as 52.9 mg/creatinine (reference interval <6 mg/creatinine). Pathological examination showed pheochromocytoma.

DISCUSSION

While pheochromocytoma with adrenal localization is observed in fourth and fifth decades and mostly in females, the ones with extra-adrenal localization are found in second and third decades and mostly in males.^[6,7] However, the fact that the patient who was different than literature was a female in the sixth decade gave rise to the thought of atypical extra-adrenal pheochromocytoma case.

Pheochromocytoma should be considered in patients with complaints of headache, palpitation, and sweating accompanied by hypertension in the preoperative period.^[1,3] During the preoperative examination, there were not palpitation and sweating complaints; heart rate was 70/min and BP was 150/90 mmHg in the patient. Therefore, pheochromocytoma was not considered in the preoperative period. However, beta-blockers use was believed to mask pheochromocytoma-related complaints and thus it was not possible to be specified preoperatively.

Control of hydration and hypertension in preoperative preparation of patients with pheochromocytoma is importance. Although alpha-adrenergic blockers are traditionally preferred as antihypertensive, calcium channel blockers, angiotensin-converting-enzyme inhibitors, metyrosine, octreotide, and beta-adrenergic blockers in

cases with sufficient use of alpha-adrenergic blockers can also be administered.^[3,8] It has reported that the use of alpha-blockers in the preoperative period and during the preparation phase before the procedure decreased pheochromocytoma resection-related mortality.^[9] Yet, beta-blocker use was present without preoperative alpha-blockers due to the fact that the patient had an unspecified pheochromocytoma. In pheochromocytoma patients that blocked beta-adrenergic receptors without blocking alpha-adrenergic receptors, catecholamines secreted from the mass may cause severe vasoconstriction and related severe hypertension by stimulating unblocked alpha-adrenergic receptors.^[3,9] Intraoperative malignant hypertension was believed to occur in our patient due to the mentioned reason. It was reported that the use of atropine as premedication might cause arrhythmia and hypertension even in patients that use preoperative alpha-adrenergic blocker.^[10] Atropine premedication was also believed to contribute to hypertension in the patient.

Invasive artery cannulation, central venous cannulation, and Swan-Ganz catheterization may conducted in addition to standard monitoring in intraoperative management of pheochromocytoma patients.^[8] Since pheochromocytoma was not known in the patient in the preoperative period, invasive monitoring was not planned. Invasive arterial BP was monitored for severe intraoperative hypertension developed and considered pheochromocytoma. There are some medications such as nitroprusside, nitroglycerine, and phentolamine mesylate recommended for the preparation for intervention of intraoperative hypertension that may develop in these patients especially during induction, intubation, pneumoperitonium, and manipulation of the mass.^[3,8] In our patient, severe hypertension was present during induction; although such an increase was not expected, a not well-treated hypertension and superficial anesthetics came to mind. Anesthetics and analgesics levels were increased. However, pheochromocytoma was considered following the re-development of hypertension along with the manipulation of mass. We were not fully prepared for hypertension developed in relation with pheochromocytoma; however, nitroglycerine, nitroprusside, esmolol, and metoprolol were present in the operation room for a potential intraoperative hypertension. First nitroglycerine and then nitroprusside was commenced, but even though both were infused in high doses, desired arterial tension decrease was not achieved. Therefore, propofol which well-known effects such as vasodilatation and hypotension was injected twice as bolus, as Isik *et al.*'s study.^[11] However, it caused short-time reductions in BP. Beta-blockers are among preferred agents in patients with intraoperative tachycardia and hypertension or in patients with treated pheochromocytoma that developed intraoperative tachycardia and hypertension.^[3,12] However,

beta-blockers were not used, as there was no alpha-adrenergic blockade in the patient.

Another expected hemodynamic change in pheochromocytoma cases is sudden hypotension that occurs by the adrenal vein ligation.^[8,13] This is also an indication that mass is completely excised. Although we carried out intervention on our patient upon the suspicion of pheochromocytoma when intraoperative malignant hypertension developed, sudden drop in BP following the removal of mass lead to clarifying the clinical diagnosis of pheochromocytoma. Hypotension developing with vein ligation may be at severity so as to necessitate the use of vasopressor agent. Therefore, infusions should be reduced or terminated immediately before vein ligation and BP should be tried to maintain.^[13] Hence, BP of the patient was tried to maintain by fluid infusion in the period following the resection of the mass. Any additional vasopressor agent was not needed.

That no neurological deficits developed in the postoperative period, which was pleasing was attributed to exposure of the patient to paroxysmal BP increase for a long time and accordingly to have high cerebral perfusion pressure and cerebrovascular resistance.

Pheochromocytoma is a condition that demonstrates properties in terms of anesthesia practice. In the preoperative period, recognition of pheochromocytoma is very important for the precautions to be taken and interventions to be carried out. In treatment, conducting beta-blockade without sufficient alpha-blockade may cause changes in hemodynamics that are not possible to intervene. Therefore, pheochromocytoma should be considered in a patient with hypertension and intra-abdominal mass with unknown origin, although rarely. In addition, propofol infusion may also be considered moving from the fact that transient decreases occur in BP thanks to bolus doses of propofol.

REFERENCES

1. Yeo H, Roman S. Pheochromocytoma and functional paraganglioma. *Curr Opin Oncol* 2005;17:13-8.
2. Townsend CB, Evers M, Beauchamp RD. The pituitary and adrenal glands. In: Townsend CM, Beauchamp RD, Evers BM, Mattox KL, editors. *Sabiston Textbook of Surgery*. 17th ed. Philadelphia: Elsevier; 2004. p. 1052-89.
3. Fitzgerald PA. Pheochromocytoma and paraganglioma. In: Clark OH, Duh QY, Perrier ND, Jahan TM, editors. *Endocrine Tumors*. 1st ed. Hamilton, Canada: BC Decker Inc.; 2003. p. 100-22.
4. Sellevold OF, Raeder J, Stenseth R. Undiagnosed phaeochromocytoma in the perioperative period. *Case reports. Acta Anaesthesiol Scand* 1985;29:474-9.
5. Plouin PF, Duclos JM, Soppelsa F, Boubilil G, Chatellier G. Factors associated with perioperative morbidity and mortality in

- patients with pheochromocytoma: Analysis of 165 operations at a single center. *J Clin Endocrinol Metab* 2001;86:1480-6.
6. Whalen RK, Althausen AF, Daniels GH. Extra-adrenal pheochromocytoma. *J Urol* 1992;147:1-10.
 7. Shinn HK, Jung JK, Park JK, Kim JH, Jung IY, Lee HS. Hypertensive crisis during wide excision of gastrointestinal stromal cell tumor (GIST): Undiagnosed paraganglioma – A case report. *Korean J Anesthesiol* 2012;62:289-92.
 8. Lentschener C, Gaujoux S, Tesniere A, Dousset B. Point of controversy: Perioperative care of patients undergoing pheochromocytoma removal-time for a reappraisal? *Eur J Endocrinol* 2011;165:365-73.
 9. Roizen MF, Fleisher LA. Anesthetic implications of concurrent diseases. In: Miller RD, editor. *Miller's Anesthesia*. New York: Churchill Livingstone; 2010. p. 1067-149.
 10. Kirby BD, Ham J, Fairley HB, Benowitz N, Schambelan M. Normotensive pheochromocytoma. Pharmacologic, paraneoplastic and anesthetic considerations. *West J Med* 1983;139:221-5.
 11. Isik A, Taydas E, Ulukaya S, Balcioglu T, Aydin U, Kilic M. Additive effect of propofol for attenuation of hypertension in a patient with undiagnosed phaeochromocytoma. *Eur J Anaesthesiol* 2007;24:561-2.
 12. Varon J, Marik PE. Perioperative hypertension management. *Vasc Health Risk Manag* 2008;4:615-27.
 13. Mannelli M, Dralle H, Lenders JW. Perioperative management of pheochromocytoma/paraganglioma: Is there a state of the art? *Horm Metab Res* 2012;44:373-8.

How to cite this article: Ozer AB, Demirel I, Duzgol O, Ayten R, Erhan OL. Management of anesthesia in unspecified extra-adrenal pheochromocytoma patient who used beta-blocker. *Saudi J Anaesth* 2014;8:105-8.

Source of Support: Nil, **Conflict of Interest:** None declared.