

RESEARCH ARTICLE

A model to predict nodal metastasis in patients with oral squamous cell carcinoma

R. K. De Silva^{1*}, B. S. M. S. Siriwardena², A. Samaranayaka³, W. A. M. U. L. Abeyasinghe², W. M. Tilakaratne^{2*}

1 Department of Oral Diagnostic and Surgical Sciences, Faculty of Dentistry, University of Otago, Dunedin, New Zealand, **2** Department of Oral Pathology, Faculty of Dental Sciences, University of Peradeniya, Peradeniya, Sri Lanka, **3** Department of Preventive and Social Medicine, Faculty of Medicine, University of Otago, Dunedin, New Zealand

* rohana.kumara@otago.ac.nz (RKDeS); wmtlak@pdn.ac.lk (WMT)



Abstract

Difficulty in precise decision making on necessity of surgery is a major problem when managing oral squamous cell carcinomas (OSCCs) with clinically negative neck. Therefore, use of clinical and histopathological parameters in combination would be important to improve patient management. The main objective is to develop a model that predicts the presence of nodal metastasis in patients with OSCC. 623 patients faced neck dissections with buccal mucosal or tongue squamous cell carcinoma (SCC) were selected from patients' records. Demographic data, clinical information, nodal status, Depth of invasion (DOI) and pattern of invasion (POI) were recorded. The parameters which showed a significant association with nodal metastasis were used to develop a multivariable predictive model (PM). Univariate logistic regression was used to estimate the strengths of those associations in terms of odds ratios (OR). This showed statistically significant associations between status of the nodal metastasis and each of the following 4 histopathological parameters individually: size of the tumour (T), site, POI, and DOI. Specifically, OR of nodal metastasis for tongue cancers relative to buccal mucosal cancers was 1.89, P -value < 0.001. Similarly, ORs for POI type 3 and 4 relative to type 2 were 1.99 and 5.83 respectively. A similar relationship was found with tumour size; ORs for T2, T3, and T4 compared to T1 were 2.79, 8.27 and 8.75 respectively. These four histopathological parameters were then used to develop a predictive model for nodal metastasis. This model showed that probability of nodal metastasis is higher among tongue cancers with increasing POI, with increasing T, and with larger depths while other characteristics remained unchanged. The proposed model provides a way of using combinations of histopathological parameters to identify patients with higher risks of nodal metastasis for surgical management.

OPEN ACCESS

Citation: De Silva RK, Siriwardena BSMS, Samaranayaka A, Abeyasinghe WAMUL, Tilakaratne WM (2018) A model to predict nodal metastasis in patients with oral squamous cell carcinoma. PLoS ONE 13(8): e0201755. <https://doi.org/10.1371/journal.pone.0201755>

Editor: Ruby John Anto, Rajiv Gandhi Centre for Biotechnology, INDIA

Received: February 18, 2018

Accepted: July 20, 2018

Published: August 9, 2018

Copyright: © 2018 De Silva et al. This is an open access article distributed under the terms of the [Creative Commons Attribution License](https://creativecommons.org/licenses/by/4.0/), which permits unrestricted use, distribution, and reproduction in any medium, provided the original author and source are credited.

Data Availability Statement: All relevant data are within the paper and its Supporting Information files.

Funding: The author(s) received no specific funding for this work.

Competing interests: The authors have declared that no competing interests exist.

Introduction

The incidence of oral squamous cell carcinoma (OSCC) is increasing globally and is a leading cause of death accounted for 8.8 million deaths in 2015 [1]. It is one of the most common cancers in Sri Lankan male population [2]. The survival rates have not improved significantly

despite the advances in technology and treatment protocols. It is apparent that the high death rate relates to delayed diagnosis. The main attribute for above scenario is due to the fact that most oral cancers do not produce pain at early stage [2,3]. Tobacco use is the most important risk factor for cancer and is responsible for approximately 22% of cancer deaths [3].

The management of clinically negative neck nodes (N0) poses a significant challenge for surgeons, as there are no reliable parameters to predict occult metastasis. In order to identify patients who are likely to have nodal metastases, several parameters like tumour differentiation, perineural invasion, lymphovascular invasion, pattern of invasion (POI) and depth of invasion (DOI) have been previously studied [4,5]. According to our previous studies on OSCC, it has been shown that POI, tumour size (T) and stage are important parameters in predicting nodal metastasis [5,6]. Although DOI has been shown to be one of the important factors in predicting lymph node metastasis, it differs according to the sub site in the oral cavity. DOI is considered as an objective parameter and has been evaluated by several investigators for OSCC. Although most authors substantially agree that DOI is an important parameter for nodal metastasis and survival, the results vary in the literature and there is no cut-off point to prompt neck dissection [5]. One of the main etiological agents among patients from South Asian countries is betel quid, and many of them develop oral cancers if they have oral submucous fibrosis, hence the tumour invasive depth may differ due to fibrosis of the submucosa. Oral submucous fibrosis is a chronic, inflammatory disease characterized by progressive submucosal fibrosis of the mucosa and underlying connective tissues in the oral cavity and the oropharynx. People affected by this disease mostly live in south Asia, while migrants from these countries to the United States and Europe may also present with oral submucous fibrosis [5, 6].

Tumour thickness or the maximum depth of tumour infiltration is a well-established risk factor for many cancers mainly for gastrointestinal tract tumours [7]. However, there is no specific data available for oral cancer sub-sites. Some reports indicate that the rate of nodal metastasis differs according to the oral cavity sub-sites, and the thickness of invasion varies from 2-8mm between studies. Most of these studies discussed the relationship between DOI of the tongue, floor of the mouth and metastasis [7]. However, it is important to have data for the buccal mucosal cancers as it is the most common site affected in South and Southeast Asian patients.

The aetiological factors for OSCC show significant variation across different parts of the world. In the developed world it is mostly due to smoking, alcohol and human papilloma virus. However, in South and Southeast Asia OSCC is mostly related to betel chewing containing tobacco and arecanut [8]. Therefore, the most common site affected is buccal mucosa as they keep the betel quid in buccal pouch [5]. Further, most OSCCs are associated with oral submucous fibrosis, a potentially malignant disorder [8, 9]. Due to the difference in aetiology and extensive fibrosis, the relationship between tumour depth and metastasis may vary in patients with the history of betel chewing and those from the developed world. With this background we wanted to investigate the size of the tumour (T), POI and DOI in an attempt to propose a model for prediction of nodal metastasis, which may help surgeons to plan the management of clinically negative neck nodes in patients with OSCC. Having an accurate predictive model for oral cancer is important to identify patients that require extensive prophylactic surgical management of neck nodes. Such predictions would have an immediate clinical impact, especially to avoid unnecessary radical treatment of patients who are at a low risk of metastasis [5]. Further it is understood that cancers from two sites namely, buccal mucosa and tongue, have different rates of metastasis. Therefore, we planned to investigate the site, and incorporate it in predicting nodal metastasis [5]. The presence of cervical lymph node metastases is the most important prognostic factor for survival in patients with OSCC [5] hence

prediction of metastasis will enable the surgeon to select the best mode of treatment to improve the prognosis. We therefore aimed to evaluate the association between DOI, POI and occurrence of metastasis of OSCC from buccal mucosa and tongue. We aim to (I) evaluate the associations between these clinical parameters and presence of nodal metastases, (II) develop a simple model for predicting the nodal metastasis (III) identify combinations of clinical parameters that can be used as a screening tool for nodal metastasis that can be used for Sri Lankan OSCC patients as well as in South Asian region.

Results

Medical records and histological sections were available for 623 patients; of these nodal metastasis was observed for 189 (30%). Majority (76%) were males, 95% were aged 40 or more, 50% had cancer of the tongue, nearly half (47%) were in POI type IV with just one person in POI type I, and 11% were in T1 with near equal numbers in T2-T4 (Table 1). More than half (59%) of the depths were 5mm or more, corresponding percentage among 385 non-censored depth measurements was 53%. Chi-square test found the presence of nodal metastasis is associated with cancer site, T, POI, DOI, but not with age or sex (Table 1). Results were similar when this analysis was repeated with subsets of data for each site separately (results not included).

After excluding 8 cases due to missing data and a single person in POI type I, 614 complete cases were included in the rest of the analyses. Univariate logistic regression found an odds ratio (OR) of 1.89 (95% CI: 1.33–2.69) for metastasis of tongue cancers relative to buccal mucosa (Table 2). OR for invasive patterns III and IV were 1.99 (95% CI: 1.01–3.95) and 5.83 (95% CI: 3.05–11.11) respectively relative to invasive pattern II. A similar dose-response relationship was also found with tumour size; OR for T2, T3, and T4 were 2.79 (95% CI: 1.05–7.44), 8.27 (95% CI: 3.15–21.70), 8.75 and (95% CI: 3.36–22.76) respectively relative to tumour size T1. Such a dose-response relationship was not observed with depth categories when either all cases were used or analyses were restricted only to non-censored cases. However, depth was found to be associated with presence of nodal metastasis ($P < 0.01$). All these associations were statistically significant. However such associations were not found to be significant with regard to age or gender (Table 2).

Based on univariate results, age and sex were not used in the multivariable model. The model fit of the multivariable predictive model was acceptable (Chi-square goodness of fit test P -value = 0.28, area under the ROC curve = 0.77). Probability of nodal metastasis predicted by the model for each of the 48 combinations of four clinical parameters are presented in Table 3. Tongue cancers were associated with a higher probability of nodal metastasis, so does the increasing POI, increasing T, and larger DOI (>4mm) when other characteristics remained unchanged. The table allows identifying combination of clinical characteristics with relatively higher (or lower) likelihood of having nodal metastasis than a probability level chosen by the practitioner. Fig 1 presents the sensitivity and specificity corresponds to such cut-off probabilities. For example, if one opt to select 0.25 probability of having metastasis as the cut-off for selecting those require neck dissections (ie, corresponds to pink or red cells in Table 3), figure reports corresponding sensitivity and specificity of that choice as about 83% and 63% respectively.

Discussion

Currently there are controversies in the management of clinically node-negative neck. Majority suggest elective neck dissections while some encourage close observation often with frequent ultrasound imaging [10]. Since late 1800s, radical neck dissection was performed to avoid cancer recurrences even though it caused significant post-operative complications such

Table 1. Univariate relationships between clinical parameters and presence of nodal metastasis.

Clinical parameter	Cancer absent in nodes (N = 434)	cancer present in nodes (N = 189)	P-value (Chi-Square test)
	N (%)	N (%)	
Age			
40 or below	18 (64.3)	10 (35.7)	
41 or more	415 (70)	178 (30.0)	0.52
Sex			
female	106 (70.7)	44 (29.3)	
male	328 (69.3)	145 (30.7)	0.76
Primary site of cancer			
Buccal mucosa	239 (76.4)	74 (23.6)	
Tongue	195 (62.9)	115 (37.1)	<0.01
Pattern of invasion (POI)			
I	1 (100)	0 (0.0)	
II	92 (88.5)	12 (11.5)	
III	176 (78.2)	49 (21.8)	
IV	164 (56.2)	128 (43.8)	<0.01
Size of the tumour (T)			
T1	63 (92.6)	5 (7.4)	
T2	160 (81.6)	36 (18.4)	
T3	99 (60.4)	65 (39.6)	
T4	112 (58.0)	81 (42.0)	<0.01
Depth of invasion (DOI)			
1 to <2mm	38 (76.0)	12 (24.0)	
2 to <3mm	59 (79.7)	15 (20.3)	
3 to <4mm	64 (86.5)	10 (13.5)	
4 to <5mm	39 (75.0)	13 (25.0)	
5+mm	233 (63.3)	135 (36.7)	<0.01
Depth (non-censored cases only, n = 385)			
1 to <2mm	32 (74.4)	11 (25.6)	
2 to <3mm	49 (83.1)	10 (16.9)	
3 to <4mm	47 (87.0)	7 (13.0)	
4 to <5mm	21 (84.0)	4 (16.0)	
5+mm	137 (67.2)	67 (32.8)	0.009

Percentage (%) is the row percentage. POI type 1 group not used in Chi-Square test due to single person in it. Frequencies may not sum to total shown in column heading due to missing values.

<https://doi.org/10.1371/journal.pone.0201755.t001>

as shoulder dysfunction [11]. In 1980s more selective neck dissections were performed where the lymph nodes which drained the primary site of the tumour were removed. However sometimes it results in shoulder dysfunction despite of how conservative the management is. At present it is generally accepted that elective neck dissection is indicated for patients presenting with OSCC with a clinically N0 if the reported risk of occult metastases exceeds 15% - 20% [12]. Yet in most cases this may not be necessary [13]. In a study carried out by Shah et al 1990 revealed that even in the clinically node negative neck, nodal metastases were present in levels I-IV in up to 40% of neck dissections [14]. On the other hand, this describes that almost 60% of these patients have undergone unnecessary neck dissections.

Table 2. Strength of univariate associations between each characteristics and presence of nodal cancer (measured as univariate odds ratio) (N = 614).

Characteristic	OR	95% CI for OR		Pvalue
Age				
40 or below	Ref			
41 or more	0.76	0.34	1.68	0.50
Sex				
female	Ref			
male	1.06	0.71	1.59	0.78
Primary site of cancer				
Buccal mucosa	Ref			
Tongue	1.89	1.33	2.69	<0.01
Pattern of invasion (POI)				
II	Ref			
III	1.99	1.01	3.95	<0.01
IV	5.83	3.05	11.11	
Size of the tumour (T)				
T1	Ref			
T2	2.79	1.05	7.44	<0.01
T3	8.27	3.15	21.70	
T4	8.75	3.36	22.76	
Depth of invasion(DOI)				
1 to <2mm	Ref			
2 to <3mm	0.80	0.34	1.89	<0.01
3 to <4mm	0.48	0.19	1.22	
4 to <5mm	1.03	0.42	2.54	
5+mm	1.78	0.90	3.53	
Depth (Non-censored cases only, n = 382)				
1 to <2mm	Ref			
2 to <3mm	0.59	0.22	1.55	<0.01
3 to <4mm	0.42	0.15	1.20	
4 to <5mm	0.54	0.15	1.92	
5+mm	1.39	0.66	2.93	

OR = odds ratio, CI = confidence interval

<https://doi.org/10.1371/journal.pone.0201755.t002>

To carry-out the most suitable management, PET/CT and CT and/or MRI imaging are being commonly used in developed countries to diagnose distant nodal metastasis in patients presenting with OSCCs [15]. Some authors suggest that PET/CT is a superior method when compared to CT/MRI [15], while others have found that it does not add much to a conventional imaging [16]. For example, neither PET/CT nor CT/MRI can identify micro metastases of 1-3mm in size [16]. Hence not only the use of such advance imaging modalities to detect metastases in clinically negative neck is controversial, it is not practical in most developing countries due to lack of modern facilities [5].

So far it is evident that the most significant determinant of overall survival in patients with OSCC is the cervical lymph node metastasis that is associated with 50% decrease in survival rate [15]. Due to the fact that detection of micro metastases and metastases of clinically negative neck is difficult, many cancer researchers were persuaded to develop predictive models to predict metastasis, recurrences and survival [17–20]. These predictive models were developed based on clinical, histopathological and molecular parameters related to cancers [17–20]. A

Table 3. Predicted probability of nodal metastasis when depth is dichotomised as <4mm and 4+mm.

Size of the Tumour (T)		Buccal mucosa			Tongue		
		POI 2	POI 3	POI 4	POI 2	POI 3	POI 4
T1	depth <4mm	0.01	0.02	0.05	0.03	0.05	0.11
	depth 4+ mm	0.02	0.03	0.07	0.04	0.07	0.15
T2	depth <4mm	0.04	0.06	0.13	0.08	0.13	0.27
	depth 4+ mm	0.05	0.08	0.18	0.12	0.18	0.34
T3	depth <4mm	0.12	0.18	0.34	0.24	0.34	0.55
	depth 4+ mm	0.16	0.24	0.43	0.31	0.43	0.64
T4	depth <4mm	0.14	0.21	0.39	0.28	0.39	0.60
	depth 4+ mm	0.19	0.28	0.48	0.36	0.48	0.69

POI- pattern of invasion, T- size of the tumour. Colour codes: white = probability is <0.10 (low risk), yellow = probability between 0.10 and 0.17 (minor risk), blue = probability between 0.18 and 0.24 (moderate risk), pink = probability between 0.25 and 0.34 (high risk), red = probability 0.35 or higher (severe risk).

<https://doi.org/10.1371/journal.pone.0201755.t003>

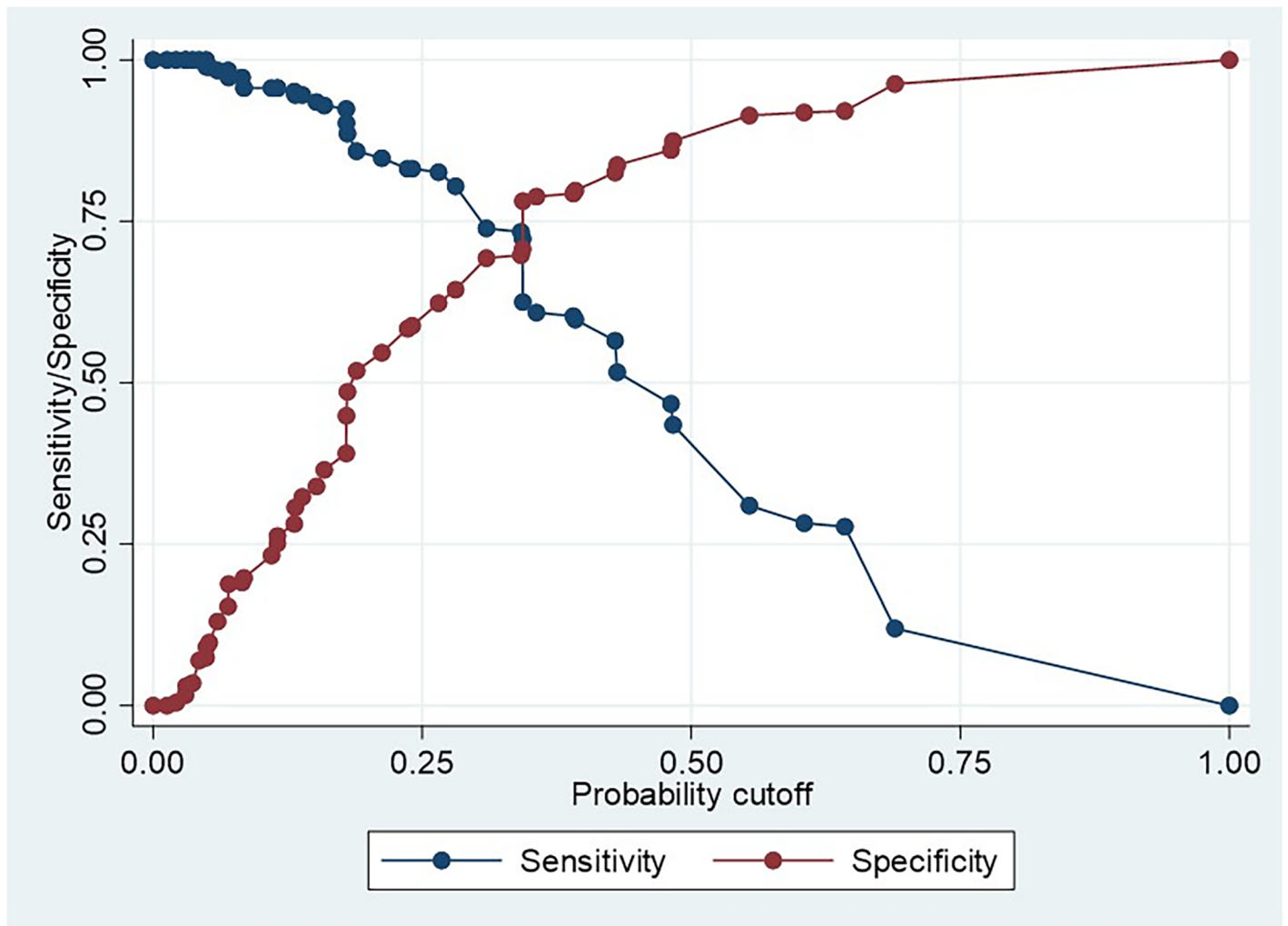


Fig 1. Sensitivity /specificity–probability cut off plot.

<https://doi.org/10.1371/journal.pone.0201755.g001>

group of researchers has developed and validated a prognostic model using gene profiles and clinicopathological co-variables [21]. Such models are difficult to be used in this part of the world since majority of the patients who present with OSCC are in low economic status and cannot afford expensive investigations such as gene profiling. Further in most diagnostic centers these advanced facilities are not available.

It is also worthwhile to mention that majority of OSCCs occur in South Asian population due to the habit of chewing betel quid with areca and due to the use of freeze dried areca products [8]. Arecoline in arecanut has been found to cause changes in the extracellular matrix of the oral submucosa, which can cause a potentially malignant disease like oral submucous fibrosis where the submucosa becomes fibrosed [8]. It is hypothesised that the dysplastic epithelium of OSF fails to invade the underlying connective tissue due to the fibrotic changes in the submucosa thus resulting in exophytic OSCCs [22]. Hence it can be argued whether the existing literature is reliable when treating OSCC patients in South Asia since the studies in the literature have used patients with different aetiological backgrounds. This may be true when assessing some important histopathological parameters such as depth of invasion and pattern of invasion in the background of oral submucous fibrosis [5, 8].

Our study specifically addressed this issue by using patients from a South Asian country to develop a model to predict the likelihood of nodal metastasis by using clinical and histopathologic parameters rather than depending on the existing literature.

Except DOI, all other data were extracted from patients' records available in the Department of Oral Pathology, Faculty of Dental Sciences, University of Peradeniya, Sri Lanka. These reports were primarily designed to record data in order to facilitate histopathologic diagnosis of the disease and were not designed specifically for this study. Thus this study includes a secondary data analysis. Our data showed 70% of the patients did not have neck metastasis yet has undergone elective neck dissections (Table 1). This emphasizes the importance of constructing a method to predict or to identify patients who may have nodal metastasis and thereby to reduce unnecessary neck dissections in clinically negative necks.

Several studies suggest predictive models and scoring systems to predict nodal metastasis, recurrences and survival, using parameters such as gender, age, tumour site, tumour size, depth of invasion/ tumour thickness, pattern of invasion, perineural invasion, tumour grade (differentiation), lymphoid response, tumour budding, degree of keratinisation, nuclear pleomorphism, habits and gene profiling [23–27]. Therefore, we selected age, gender, primary site of the tumour, T, DOI, and POI as parameters to identify the association with nodal metastasis in order to propose a predictive model. In the present study it was evident that DOI ($P < 0.01$), POI ($P < 0.01$), primary site ($P < 0.01$) and T ($P < 0.01$) had significant associations with cervical nodal metastasis while age or gender did not show a significant association.

Site of the tumour

When reviewing the literature, it was distinct that the tongue was considered as the most common site of oral cancer and exhibits high rates of metastasis outside South Asia while buccal cancers are much more predominant in South Asian countries [28–30]. Anatomically, the tongue is located on the floor of the oral cavity which is an area characterized by a rich supply of lymphatic vessels and neurovascular bundles. This is a reason to increase nodal metastasis in patients with tongue cancers. In contrast cancer in the buccal mucosa has a low rate of lymph-node metastasis [31]. The results of the current study showed that, although the number of cases are similar from two sites, higher proportion of nodal metastasis were observed in tongue cancers than in buccal mucosa cancers (37% vs 24%, $P < 0.01$) (Table 1). The strength of this association was significant (OR = 1.89 CI 95% 1.33 to 2.69, $P < 0.01$) (Table 2).

Size of the tumour

The greatest diameter of the tumour surface is used to indicate tumour size in the TNM classification. Controversies exist regarding this parameter where some authors suggest that increased tumour size has a link to cervical nodal metastasis [32–34], while some suggest that tumour size does not predict nodal metastasis [35]. Current study supports the former of these having a significant association between T and nodal metastasis. The likelihood of nodal metastasis is significantly higher with increasing tumour size showing a ‘dose-response relationship’; univariate odds ratios of metastasis are 2.79 (95% CI: 1.05 to 7.44), 8.27 (3.15 to 21.7), and 8.75 (3.36 to 22.76) for size T2, T3, and T4 respectively relative to size T1, ($P < 0.01$) (Table 2).

Pattern of invasion

The literature provides strong evidence for association of POI with local and distant nodal metastasis [17, 36–38]. Lim et al 2004 has reported that grade 3 or grade 4 pattern of invasion independently predicts late cervical metastasis in stage 1 and 2 OSCC (17). Another study has shown that POI was the most significant predictor for occult nodal metastasis [38]. Almangush et al 2014 has also reported similar findings [37]. Dissanayaka et al 2012 found a significant association between the pattern of invasion of the tumour and metastasis of the tumour to regional lymph nodes at presentation [39]. They have mentioned that tumours invading with POI 3 and 4 show a higher tendency to metastasize compared to tumours with POI 1 and 2 [39]. The results of the current study are consistent with above by pattern of invasion having a significant association with cervical nodal metastasis (Table 1), and also by showing a dose-response relationship between increasing type of POI and likelihood of nodal metastasis (Table 2).

Depth of invasion

When reviewing the literature, it was noted that lack of standardized method of measuring tumour thickness/ depth of invasion has resulted in different cut off values to decide elective neck dissection for clinically negative neck. Some authors have used a technique developed by Breslow [40] where they have measured vertically, starting from the surface of the tumour or from the base of the ulcer to the deepest point of invasion [41–52]. While some have measured after constructing an imaginary line indicating the level of the adjacent intact oral mucosa [17, 53–57] or the basement membrane [58–61] up to the deepest point of invasion. Moore et al 1986 found that longer survival of patients with verrucous carcinoma was well associated with the thickness measured from the line of a basement membrane constructed through the tumour than with the complete thickness of the exophytic tumour [62]. Pentenero et al 2005 also suggested that it would be better to consider the actual mass beneath the basement membrane rather than measuring the entire thickness of the tumour [63]. Thus we decided to measure the depth of invasion starting from the intact basement membrane up to the point of deepest invasion.

Our descriptive ($P < 0.01$, Table 1) and univariate ($P < 0.01$, Table 2) analyses showed a significant association between DOI and nodal metastasis; however, in contrast to what were observed with POI and T, a dose-response relationship was not observed in this association. One possible reason for this could be the censored DOI measurements. In this study where the invasion in cancer tissues extended up to the inferior margin of the excisional biopsy specimen in H&E sections were only measured up to the inferior margin. Thus the DOI of about one third of the cases were under-measured (censored). This may have caused misclassification of DOI that suggests we may have underestimated the effect of DOI on the nodal metastasis

because differential misclassification is known to bias the estimates negatively [64]. Therefore, the true effect of DOI likely be greater than what was reported by our results. Hence we carried out similar separate univariate analysis for uncensored measurements of DOI which revealed similar results (of odds ratios) (Table 2). Another possible reason for not observing a dose-response relationship could be the categorisations used for DOI (1mm categories). This prompted us to dichotomise the DOI for the predictive model using 4mm cut-off as those in less than 4mm DOI category were found to be associated with lower probability of nodal metastasis compared to others.

As mentioned before, different studies have suggested different cut-off values for DOI to predict metastasis for different sites in the oral cavity. Therefore, it is difficult to compare these cut off values due to the discrepancies of the methods used to measure the tumour thickness/DOI. For example, certain studies which DOI has been measured starting from the adjacent intact mucosa have suggested 4mm [53, 56–58, 65] and 5mm [54, 55, 65] for tongue cancers and 2mm [66] for floor of the mouth cancers. On the other hand some other studies which have measured the tumour thickness starting from the surface of the tumour have suggested 4mm [49] for tongue cancers, 5mm [46] and 6mm [43] for cancers in the lip and 6mm [44] and 7mm [47] for overall oral cavity. In the present study the method which was used to measure DOI is similar to Giacomarra et al 1999 [61] and Ambrosch et al 1995 [58]. Their results revealed a DOI of 7mm [61] and 4mm [58] for cancers in upper aero digestive tract. Therefore, it is evident that DOI alone may not predict nodal metastasis with high accuracy. This demands a better method combining few other parameters to evaluate the clinically node negative neck and its management.

Developing a predictive model

Results of the current study revealed strong associations between cervical nodal metastasis and the four parameters, site, T, POI and DOI. We hypothesised that the use of these parameters together may increase the accuracy of predicting nodal metastasis. Therefore, we used these four parameters to develop a multivariate logistic model which predicts possible presence of nodal metastasis more accurately. For reasons given above, and also to simplify the model, we dichotomised DOI as less than 4mm and equal or more than 4mm. Therefore, the predictive model included two sites, four categories of tumour size, two categories of DOI, and three grades of POI. Probability of nodal metastasis predicted by the model in Table 3 allows identifying combinations of clinical parameters which correspond to the likelihood of higher than any given probability threshold. Sensitivity-specificity plot in Fig 1 helps to assess the suitability of any such threshold. For example, say one intends to follow the 0.17 probability threshold as an approximation for the generally accepted probability of 15%-20% mentioned in first paragraph of discussion. Clinical parameters corresponds to that probability are identifiable from Table 3 as those in blue, pink, or red. Then using Fig 1 we can assess the sensitivity and specificity corresponding to that probability as 88% and 55% respectively. This means, using this threshold to identify patients for neck dissections may not include 12% of the patients who have nodal metastasis, while carrying out unnecessary dissections in 45% of those without nodal metastasis.

In order to predict the presence of nodal metastasis and to avoid under treatment the sensitivity of the cut off value must be high. At the same time, it should have a considerable specificity to reduce over-treatment (unnecessary neck dissections). Hence this value requires a compromise between sensitivity and specificity [67]. We do not intend to make recommendation on the suitability or otherwise of any probability threshold as it is not within the scope of this study.

The final outcome of the model revealed that T4 tumours in the buccal mucosa that have POI type 3 and has a depth of invasion > 4 mm are more likely to metastasize. It also showed that T3 and T4 tumours in the buccal mucosa with POI type 4 tend to metastasize regardless of its depth of invasion.

The model showed that there is a high chance of nodal metastasis when there is a tumour on the tongue that has a POI of type 4 regardless of depth of invasion. T3 tumours in the tongue tend to metastasize when the POI is 2 and DOI is more than 4mm. T3 tumours also has a high chance of metastasis when the POI is type 3 or 4 regardless of its DOI. The model also revealed that T4 tongue tumours have a high chance of cervical nodal metastasis regardless of its DOI and POI.

Strengths, limitations and conclusion

This study proposes a simple predictive model for the risk of nodal metastasis in clinically negative necks. The major drawback of this study was the difficulty in measuring exact DOI in significant number of cases. However, the study has strength that, it is based on a large sample, proposed model being simple, and based on parameters empirically supported as well as established in literature, easy to use in routine clinical practice, and cost effective. Although findings of this retrospective investigation needs required to be validated in a prospective study, it provides a useful model that is practicable to use in developing countries of South and Southeast Asia where OSCC aetiology is similar and advanced facilities are not available.

Materials and methods

All patients who underwent surgery for OSCC of the tongue or buccal mucosa with neck dissection between 1998 and 2015 were retrospectively studied. The cases were selected from archives of the Department of Oral Pathology, Faculty of Dental Sciences, University of Peradeniya, the only Head and neck Pathology centre which receives most biopsies from almost all Oral and Maxillofacial units in Sri Lanka. Therefore this can be considered as a representative sample of the entire country. Demographic data including age, gender and clinical information such as size of the tumour (T), primary site; tongue or buccal mucosa, and pathological factors (POI, lymph node metastasis) were recorded. Arrangement of tumour cells at the advancing front was graded as large cohesive tumour islands (POI- I), small islands (POI- II), thin strands (POI- III) and individual tumour cells (POI- IV) [68] (Fig 2). Eight cases ($<15\%$) were excluded due to missing data on one or more of above parameters. Patients with recurrent tumours or extensive tumours involving multiple intraoral sites were not included. DOI was obtained from histological sections following the standard method of measuring the distance from the deepest point of infiltration to the basal layer of overlying epithelium using an optical micrometer with a graticule [58, 61]. The depth (0.25mm accuracy) was taken from an imaginary line at the basement membrane of the healthy oral mucosa to the deepest point of tumour invasion (Fig 3A and 3B). Multiple sections of the tumour were measured to identify the region with maximum thickness. All data were anonymised before analysis and informed consent has been taken from all patients to use their information/ material for research. Ethical clearance for the study was obtained from the Faculty Research and Ethical Review Committee (ERC/FDS/UoP/I/2016/05).

Data analysis

Patient's histological sections had been prepared primarily for managing with curative intent; therefore full width of the tumour had not been taken to a single section in about one third of the sections. Since the DOI was measured from the basement membrane of the healthy oral mucosa, section containing this may not contained the full depth of the tumour in these cases

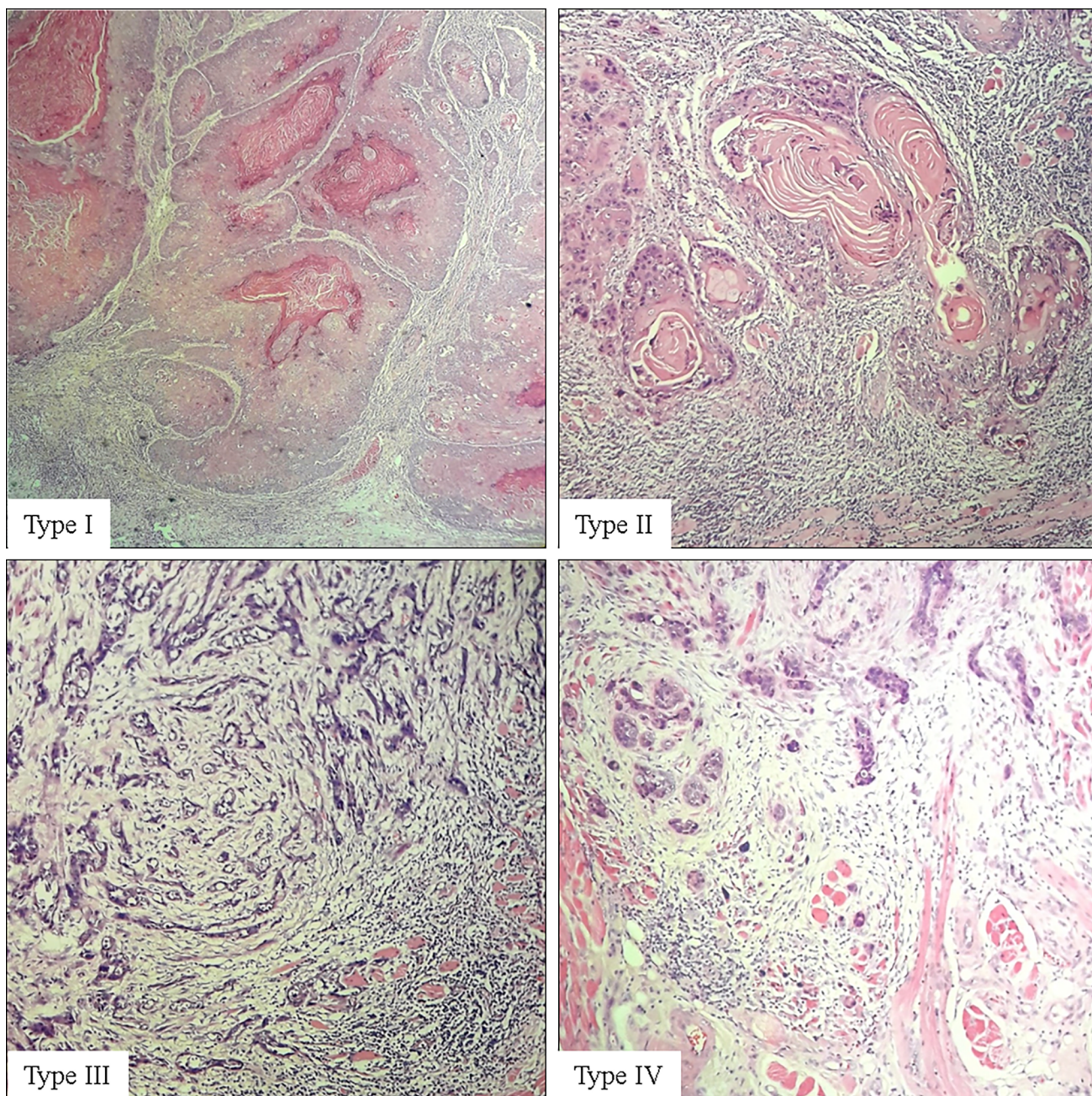


Fig 2. Different invasive patterns of oral squamous cell carcinoma.

<https://doi.org/10.1371/journal.pone.0201755.g002>

which prevented from accurate measurement of the depth of the tumour. We recorded the DOI of these sections and used in the analysis as the lower end for their actual tumour depth knowing that these are under-measurements of the actual thickness of these cases. Those measurements are hereafter referred to as censored depths.

For the purpose of analysis, age was dichotomised as 40 years or below vs 41 or more years. Depth was initially categorised into five groups; four 1mm groups and one group containing cases with 5mm or more depths (Table 1). Association between each variable and presence of nodal metastasis was assessed using chi-square test. Univariate logistic regression was used to

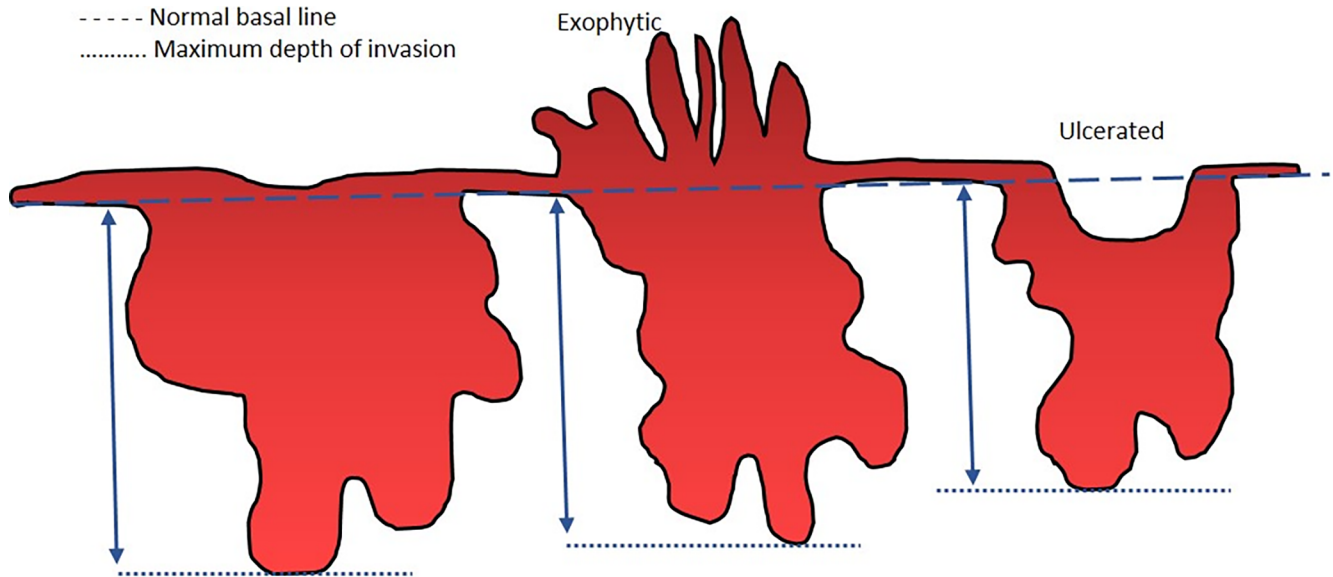


Fig 3. Representative schema of tumour depth and measurement of depth of invasion.

<https://doi.org/10.1371/journal.pone.0201755.g003>

estimate the strength of these associations in terms of odds ratios (and 95% confidence intervals, CIs). Based on univariate results for developing a predictive model, we dichotomised depth as less than 4mm, and 4mm or more. Clinical parameters identified in univariate assessments were then used in multivariable logistic regression to estimate the probability of having nodal metastasis for each combinations of parameters. These probabilities were then used to rank combinations of parameters on the basis of associated risk of having nodal metastasis. The number of cases with missing data was small (<1.5%), thus all statistical modelling was done as complete case analyses using Stata 15.1® software [69].

Supporting information

S1 Dataset. Raw dataset.
(XLS)

Author Contributions

Conceptualization: R. K. De Silva, W. M. Tilakaratne.

Data curation: B. S. M. S. Siriwardena.

Formal analysis: A. Samaranyaka.

Investigation: R. K. De Silva, B. S. M. S. Siriwardena.

Methodology: R. K. De Silva, B. S. M. S. Siriwardena, W. M. Tilakaratne.

Project administration: B. S. M. S. Siriwardena, W. M. Tilakaratne.

Software: A. Samaranyaka.

Supervision: W. M. Tilakaratne.

Visualization: R. K. De Silva, B. S. M. S. Siriwardena, A. Samaranyaka, W. A. M. U. L. Abeyasinghe, W. M. Tilakaratne.

Writing – original draft: B. S. M. S. Siriwardena, W. A. M. U. L. Abeyasinghe.

Writing – review & editing: R. K. De Silva, B. S. M. S. Siriwardena, A. Samaranyaka, W. A. M. U. L. Abeyasinghe, W. M. Tilakaratne.

References

1. <http://www.who.int/mediacentre/factsheets/fs297/en/>
2. National cancer control programme Sri Lanka www.nccp.health.gov.lk/images/PDF.../Cancer_Incidence_Data_2010.pdf.
3. <https://www.cancer.gov/about-cancer/causes-prevention/risk/tobacco>
4. Tai SK, Li WY, Yang MH, Chu PY, Wang YF. Perineural invasion in T1 oral squamous cell carcinoma indicates the need for aggressive elective neck dissection. *Am J SurgPathol*. 2013; 37: 1164–1172.
5. Rajapakshe RM, Pallegama RW, Jayasooriya PR, Siriwardena BSMS, Attygalla AM, Hewapathirana S, et al. A retrospective analysis to determine factors contributing to the survival of patients with oral squamous cell carcinoma. *Cancer Epidemiol*. 2015; 39:360–6. <https://doi.org/10.1016/j.canep.2015.02.011> PMID: 25779678
6. Siriwardena BSMS, Tilakaratne A, Amaratunga EAPD, Udagama MNGPK, Ogawa I, Kudo Y, et al. Analysis of histopathological and immunohistochemical differences of oral squamous cell carcinoma in the young and the old patients in Sri Lanka. *J Oral Pathol Med*. 2007; 36:357–362. <https://doi.org/10.1111/j.1600-0714.2007.00548.x> PMID: 17559498
7. Huang SH, Hwang D, Lockwood G, Goldstein DP, O’Sullivan B. Predictive value of tumor thickness for cervical lymph-node involvement in squamous cell carcinoma of the oral cavity: a meta-analysis of reported studies. *Cancer*. 2009; 115: 1489–1497. <https://doi.org/10.1002/ncr.24161> PMID: 19197973
8. Tilakaratne WM, Ekanayaka RP, Warnakulasuriya S. Oral submucous fibrosis: a historical perspective and a review on etiology and pathogenesis. *Oral Surgery, Oral Medicine, Oral Pathology and Oral Radiology*. 2016; 122: 178–191. <https://doi.org/10.1016/j.oooo.2016.04.003> PMID: 27422417
9. Merchant A, Husain SS, Hosain M, Fikree FF, Pitiphat W, Siddiqui AR, et al. Paan without tobacco: an independent risk factor for oral cancer. *Int J Cancer*. 2000; 86:128–31. PMID: 10728606
10. Brennan P, Subramaniam S, Tsioryannis C, Green B. An update on the latest evidence for managing the clinically negative neck (cN0) in oral squamous cell carcinoma. *Oral Diseases*. 2016; 23: 287–291. <https://doi.org/10.1111/odi.12528> PMID: 27341071
11. Ferlito A, Rinaldo A, Silver CE, Shah JP, Suárez C, Medina JE, et al. Neck dissection: then and now. *AurisNasus Larynx*. 2006; 33:365–74.
12. Jalisi S. Management of the clinically negative neck in early squamous cell carcinoma of the oral cavity. *OtolaryngolClin North Am* 2005; 38: 37–46.
13. Green B, Bisase B, Godden D, Mitchell D, Brennan P. Current surgical management of metastases in the neck from mucosal squamous cell carcinoma of the head and neck. *British Journal of Oral and Maxillofacial Surgery*. 2016; 54:135–140. <https://doi.org/10.1016/j.bjoms.2015.06.025> PMID: 26432197
14. Shah J. Patterns of cervical lymph node metastasis from squamous carcinomas of the upper aerodigestive tract. *The American Journal of Surgery*. 1990; 160: 405–409. PMID: 2221244
15. Roh JL, Park JP, Kim JS, Lee JH, Cho KJ, Choi SH, et al. 18Ffluorodeoxyglucose PET/CT in head and neck squamous cell carcinoma with negative neck palpation findings: a prospective study. *Radiology*. 2014; 271:153–61 <https://doi.org/10.1148/radiol.13131470> PMID: 24475791
16. Sohn B, Koh YW, Kang WJ, Lee JH, Shin NY, Kim J. Is there an additive value of 18 F-FDG PET-CT to CT/MRI for detecting nodal metastasis in oropharyngeal squamous cell carcinoma patients with palpably negative neck? *ActaRadiol*. 2016; 57:1352–1359. <https://doi.org/10.1177/0284185115587544> PMID: 26013025
17. Lim SC, Zhang S, Ishii G, et al. Predictive markers for late cervical metastasis in stage I and II invasive squamous cell carcinoma of the oral tongue. *Clin Cancer Res*. 2004; 10:166–172. PMID: 14734465
18. Tertipis N, Hammar U, Nasman A, Vlastos A, Nordfors C, Grun N, et al. A model for Predicting clinical outcome in patients with human papillomavirus-positive tonsillar and base of tongue cancer. *Eur J Cancer*. 2015; 51:1580–1587. <https://doi.org/10.1016/j.ejca.2015.04.024> PMID: 26025766
19. Rietbergen MM, Witte BI, Velazquez ER, Sniijders PJ, Bloemena E, Speel EJ, et al. Different prognostic models for different patient populations: validation of a new prognostic model for patients with oropharyngeal cancer in Western Europe. *Br J Cancer*. 2015; 112:1733–1736. <https://doi.org/10.1038/bjc.2015.139> PMID: 25950384

20. Almangush A, Coletta RD, Bello IO, Bitu C, Keski-Santti H, Makinen LK, et al. A simple novel prognostic model for early stage oral tongue cancer. *Int J Oral Maxillofac Surg*. 2015; 44:143–150. <https://doi.org/10.1016/j.ijom.2014.10.004> PMID: 25457829
21. Mes S, teBeest D, Poli T, Rossi S, Scheckenbach K, Van Wieringen WN, et al. Prognostic modeling of oral cancer by gene profiles and clinicopathological co-variables. *Oncotarget*. 2017; 8: 59312–59323 <https://doi.org/10.18632/oncotarget.19576> PMID: 28938638
22. Jayasinghe L, Peiris P, Tilakaratne WM, Attygalla AM, Jayasinghe RD, Sitheeque MAM, et al. Clinically malignant exophytic lesions in the background of oral submucous fibrosis: report of five cases. *Oral Surgery, Oral Medicine, Oral Pathology and Oral Radiology*. 2016; 122: 210–215. <https://doi.org/10.1016/j.oooo.2016.06.001> PMID: 27422419
23. Arora A, Husain N, Bansal A, Neyaz A, Jaiswal R, Jain K, et al. (2017). Development of a New Outcome Prediction Model in Early-stage Squamous Cell Carcinoma of the Oral Cavity Based on Histopathologic Parameters With Multivariate Analysis. *The American Journal of Surgical Pathology*. 2017; 41: 950–960. <https://doi.org/10.1097/PAS.0000000000000843> PMID: 28346327
24. Jerjes W, Upile T, Petrie A, Riskalla A, Hamdoon Z, Vourvachis M, et al. Clinicopathological parameters, recurrence, locoregional and distant metastasis in 115 T1-T2 oral squamous cell carcinoma patients. *Head & Neck Oncology*. 2010; 2: 9.
25. Yuen A, Lam K, Wei W, Lam K, Ho C, Chow T, et al. A comparison of the prognostic significance of tumor diameter, length, width, thickness, area, volume, and clinicopathological features of oral tongue carcinoma. *The American Journal of Surgery*. 2000; 180: 139–143. PMID: 11044531
26. de Matos F, Lima E, Queiroz L, da Silveira É. Analysis of Inflammatory Infiltrate, Perineural Invasion, and Risk Score Can Indicate Concurrent Metastasis in Squamous Cell Carcinoma of the Tongue. *Journal of Oral and Maxillofacial Surgery*. 2012; 70: 1703–1710. <https://doi.org/10.1016/j.joms.2011.08.023> PMID: 22154400
27. Kurokawa H, Zhang M, Matsumoto S, Yamashita Y, Tomoyose T, Tanaka T, et al. The high prognostic value of the histologic grade at the deep invasive front of tongue squamous cell carcinoma. *Journal of Oral Pathology and Medicine*. 2005; 34: 329–333. <https://doi.org/10.1111/j.1600-0714.2005.00244.x> PMID: 15946179
28. Conway DI, Stockton DL, Warnakulasuriya KA, Ogden G, Macpherson LM. Incidence of oral and oropharyngeal cancer in United Kingdom (1990–1999): Recent trends and regional variation. *Oral Oncol*. 2006; 42: 586–592. <https://doi.org/10.1016/j.oraloncology.2005.10.018> PMID: 16469526
29. Muller S, Pan Y, Li R, Chi AC. Changing trends in oral squamous cell carcinoma with particular reference to young patients: 1971–2006. The Emory University experience. *Head Neck Pathol*. 2008; 2:60–66. <https://doi.org/10.1007/s12105-008-0054-5> PMID: 20614324
30. Hosal AS, Unal OF, Ayhan A. Possible prognostic value of histopathologic parameters in patients with carcinoma of the oral tongue. *Eur Arch Otorhinolaryngol*. 1998; 255:216–219. PMID: 9592681
31. Mishra R, Parida G, Mishra T, Mohanty S. Tumour thickness and relationship to locoregional failure in cancer of the buccal mucosa. *European Journal of Surgical Oncology*. 1999; 25: 186–189. <https://doi.org/10.1053/ejso.1998.0624> PMID: 10218463
32. Woolgar JA. Histopathological prognosticators in oral and oropharyngeal squamous cell carcinoma. *Oral Oncol*. 2006; 42:229–39. <https://doi.org/10.1016/j.oraloncology.2005.05.008> PMID: 16150633
33. Woolgar JA, Rogers S, West CR, Errington RD, Brown JS, Vaughan ED. Survival and patterns of recurrence in 200 oral cancer patients treated by radical surgery and neck dissection. *Oral Oncol*. 1999; 35:257–65. PMID: 10621845
34. Maddox WA. Hayes Martin lecture. Vicissitudes of head and neck cancer. *Am J Surg*. 1984; 148:428–32. PMID: 6486306
35. Larsen SR, Johansen J, Sørensen JA, Kroghdal A. The prognostic significance of histological features in oral squamous cell carcinoma. *J Oral Pathol Med* 2009; 38: 657–62.
36. Brandwein-Gensler A, Teixeira MS, Lewis CM, Lee B, Rolnitzky L, Hille JJ, et al. Oral squamous cell carcinoma: histologic risk assessment, but not margin status, is strongly predictive of local disease-free and overall survival. *Am J Surg Pathol*. 2005; 29:167–178.
37. Almangush A, Coletta RD, Bello IO, Bitu C, Keski-Santti H, Mäkinen LK, et al. Depth of invasion, tumour budding, and worst pattern of invasion: prognostic indicators in early-stage oral tongue cancer. *Head Neck*. 2014; 36:811–818. <https://doi.org/10.1002/hed.23380> PMID: 23696499
38. Hiratsuka H, Miyakawa A, Nakamori K, Kido Y, Sunakawa H, Kohama G. Multivariate analysis of occult lymph node metastasis as a prognostic indicator for patients with squamous cell carcinoma of the oral cavity. *Cancer*. 1997; 80:351–356. PMID: 9241067
39. Dissanayaka WL, Pitiyage G, Kumarasiri P, Liyanage R, Dias DK, Tilakaratne WM. Clinical and histopathologic parameters in survival of oral squamous cell carcinoma. *Oral Surgery, Oral Medicine, Oral*

- Pathology and Oral Radiology. 2012; 113: 518–525. <https://doi.org/10.1016/j.oooo.2011.11.001> PMID: 22668430
40. Breslow A. Prognostic factors in the treatment of cutaneous melanoma. *J CutanPathol* 1979; 6:208–212.
 41. Baredes S, Leeman DJ, Chen TS, Mohit-Tabatabai MA. Significance of tumor thickness in soft palate carcinoma. *Laryngoscope* 1993; 103:389–393. PMID: 8459747
 42. Brown B, Barnes L, Mazariegos J, Taylor F, Johnson J, Wagner RL. Prognostic factors in mobile tongue and floor of mouth carcinoma. *Cancer* 1989; 64:1195–1202. PMID: 2766218
 43. Frierson HF Jr, Cooper PH. Prognostic factors in squamous cell carcinoma of the lower lip. *Hum Pathol* 1986; 17: 346–354. PMID: 3957335
 44. Kim HC, Kusakawa J, Kameyama T. Clinicopathologic parameters in predicting cervical nodal metastasis in early squamous cell carcinoma of the oral cavity. *Kurume Med J* 1993; 40:183–192. PMID: 8007626
 45. Sheahan P, O’Keane C, Sheahan JN, O’Dwyer TP. Effect of tumour thickness and other factors on the risk of regional disease and treatment of the N0 neck in early oral squamous carcinoma. *ClinOtolaryngol* 2003; 28: 461–471.
 46. Onercl M, Yilmaz T, Gedikoglu G. Tumor thickness as a predictor of cervical lymph node metastasis in squamous cell carcinoma of the lower lip. *Otolaryngol Head Neck Surg* 2000; 122:139–142. [https://doi.org/10.1016/S0194-5998\(00\)70162-8](https://doi.org/10.1016/S0194-5998(00)70162-8) PMID: 10629501
 47. Martinez-Gimeno C, Rodriguez EM, Vila CN, Varela CL. Squamous cell carcinoma of the oral cavity: a clinicopathologic scoring system for evaluating risk of cervical lymph node metastasis. *Laryngoscope* 1995; 105: 728–733. <https://doi.org/10.1288/00005537-199507000-00011> PMID: 7603278
 48. Williams JK, Carlson GW, Cohen C, Derose PB, Hunter S, Jurkiewicz MJ. Tumor angiogenesis as a prognostic factor in oral cavity tumors. *Am J Surg* 1994; 168:373–380. PMID: 7526718
 49. Rodolico V, Barresi E, Di Lorenzo R, Leonardi V, Napoli P, Rappa F, et al. Lymph node metastasis in lower lip squamous cell carcinoma in relation to tumour size, histologic variables and p27Kip1 protein expression. *Oral Oncol.* 2004; 40:92–98. PMID: 14662421
 50. Mohit-Tabatabai MA, Sobel HJ, Rush BF, Mashberg A. Relation of thickness of floor of mouth stage I and II cancers to regional metastasis. *Am J Surg* 1986; 152: 351–353. PMID: 3766862
 51. Shingaki S, Suzuki I, Nakajima T, Kawasaki T. Evaluation of histopathologic parameters in predicting cervical lymph node metastasis of oral and oropharyngeal carcinomas. *Oral Surg Oral Med Oral Pathol* 1988; 66: 683–688. PMID: 3205557
 52. Stein AL, Tahan SR. Histologic correlates of metastasis in primary invasive squamous cell carcinoma of the lip. *J CutanPathol* 1994; 21:16–21.
 53. Sparano A, Weinstein G, Chalian A, Yodul M, Weber R. Multivariate predictors of occult neck metastasis in early oral tongue cancer. *Otolaryngol Head Neck Surg* 2004; 131:472–476. <https://doi.org/10.1016/j.otohns.2004.04.008> PMID: 15467620
 54. O-charoenrat P, Pillai G, Patel S, Fisher C, Archer D, Eccles S, et al. Tumour thickness predicts cervical nodal metastases and survival in early oral tongue cancer. *Oral Oncol.* 2003; 39:386–390. PMID: 12676259
 55. Fukano H, Matsuura H, Hasegawa Y, Nakamura S. Depth of invasion as a predictive factor for cervical lymph node metastasis in tongue carcinoma. *Head Neck* 1997; 19: 205–210. PMID: 9142520
 56. Kurokawa H, Yamashita Y, Takeda S, Zhang M, Fukuyama H, Takahashi T. Risk factors for late cervical lymph node metastases in patients with stage I or II carcinoma of the tongue. *Head Neck* 2002; 24:731–736. <https://doi.org/10.1002/hed.10130> PMID: 12203797
 57. Asakage T, Yokose T, Mukai K, Tsugane S, Tsubono Y, Asai M, et al. Tumor thickness predicts cervical metastasis in patients with stage I/II carcinoma of the tongue. *Cancer* 1998; 82:1443–1448. PMID: 9554518
 58. Ambrosch P, Kron M, Fischer G, Brinck U. Micrometastases in carcinoma of the upper aerodigestive tract: detection, risk of metastasizing, and prognostic value of depth of invasion. *Head Neck.* 1995; 17:473–479. PMID: 8847205
 59. Gonzalez-Moles MA, Esteban F, Rodriguez-Archilla A, Ruiz-Avila I, Gonzalez-Moles S. Importance of tumour thickness measurement in prognosis of tongue cancer. *Oral Oncol.* 2002; 38:394–397. PMID: 12076706
 60. Morton RP, Ferguson CM, Lambie NK, Whitlock RM. Tumor thickness in early tongue cancer. *Arch Otolaryngol Head Neck Surg.* 1994; 120:717–720. PMID: 8018323
 61. Giacomarra V, Tirelli G, Papanikolla L, Bussani R. Predictive factors of nodal metastases in oral cavity and oropharynx carcinomas. *Laryngoscope* 1999; 109: 795–799. PMID: 10334233

62. Moore C, Kuhns JG, Greenberg RA. Thickness as prognostic aid in upper aerodigestive tract cancer. *Arch Surg* 1986; 121:1410–1414. PMID: [3789911](#)
63. Pentenero M, Gandolfo S, Carrozzo M. Importance of tumor thickness and depth of invasion in nodal involvement and prognosis of oral squamous cell carcinoma: a review of the literature. *Head Neck*. 2005; 27: 1080–91. Review. <https://doi.org/10.1002/hed.20275> PMID: [16240329](#).
64. Greenland S. The effect of misclassification in the presence of covariates. *American Journal of Epidemiology*. 1980; 112: 564–569. PMID: [7424903](#)
65. Loganathan P, Sayan A, Hsu DWK, Paraneetharan S, Ilankovan V. Squamous cell carcinoma of the anterior tongue: is tumour thickness an indicator for cervical metastasis? *Int J Oral Maxillofac Surg*. 2017; 46:407–412. <https://doi.org/10.1016/j.ijom.2016.11.003> PMID: [27919662](#)
66. Balasubramanian D, Ebrahimi A, Gupta R, Gao K, Elliott M, Palme CE, et al. Tumour thickness as a predictor of nodal metastases in oral cancer: comparison between tongue and floor of mouth subsites. *Oral Oncol*. 2014; 50:1165–8. <https://doi.org/10.1016/j.oraloncology.2014.09.012> Epub 2014 Oct 11. PMID: [25307875](#).
67. Sox, H., Higgins, M. and Owens, D. (2013). *Medical Decision Making*.
68. Siriwardena BSMS, Tilakaratne A, Amaratunga EAPD, Udagama MNGPK, Ikuko Ogawa I, Kudo Y, et al. Analysis of histopathological and immunohistochemical differences of oral squamous cell carcinoma in the young and the old patients in Sri Lanka. *J Oral Pathol Med*. 2007; 36:357–362. <https://doi.org/10.1111/j.1600-0714.2007.00548.x> PMID: [17559498](#)
69. StataCorp: *Stata Statistical Software: Release 15*. College Station, Texas: StataCorp LP; 2017.