



Contents lists available at [ScienceDirect](#)

## Trauma Case Reports

journal homepage: <http://www.journals.elsevier.com/trauma-case-reports/>



### Case Report

# Penetrating cardiac trauma and the use of emergent extracorporeal membrane oxygenation and therapeutic hypothermia: When cooler heads prevail

Nathaniel Lee <sup>\*</sup>, Daniel Tang, Sudha Jayaraman

Virginia Commonwealth University Department of Surgery, Richmond, VA, United States

#### ARTICLE INFO

##### Article history:

Accepted 19 October 2015

Available online 27 November 2015

##### Keywords:

Penetrating cardiac trauma

ECMO

Therapeutic hypothermia

Neuroprotection

#### ABSTRACT

This is a case of penetrating chest trauma with traumatic arrest from cardiac tamponade, right and left ventriculotomies, mitral valve injury and ventricular septal defect. Patient underwent resuscitative thoracotomy converted to clamshell thoracotomy for haemorrhage control. Ventriculotomies were repaired on initial damage control operation. Extracorporeal membrane oxygenation cannulation and therapeutic cooling bridged to definitive cardiac repair several days later. Patient was discharged to an inpatient rehabilitation facility in 16 days.

© 2015 The Authors. Published by Elsevier Ltd. This is an open access article under the CC BY-NC-ND license (<http://creativecommons.org/licenses/by-nc-nd/4.0/>).

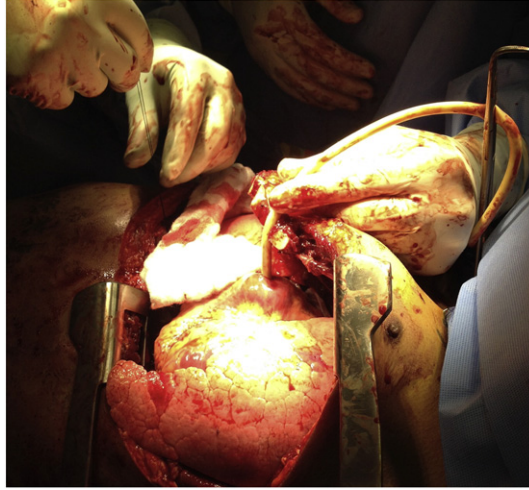
### Background and case

Whilst extracorporeal membrane oxygenation (ECMO) has been used for temporising patients with cardiac injuries, the most common indications for ECMO in the literature are lung injury and acute respiratory distress syndrome [1]. Therapeutic cooling for neuroprotection has become standard in the setting of cardiac arrest, but this practise has not expanded into patients after traumatic arrest [2]. This case describes an instance of major penetrating cardiac injury managed with ECMO and therapeutic cooling. (See Figs. 1–3.)

This 28 year old man was brought to a level one trauma centre after being stabbed in the chest. He was found in pulseless electrical activity and treated with 10 to 20 min of CPR and three rounds of epinephrine whilst en route. On trauma evaluation, he had a stab wound to the left chest with no pulse. A resuscitative thoracotomy and pericardiectomy were performed revealing minimal blood in the left chest, but a large amount of

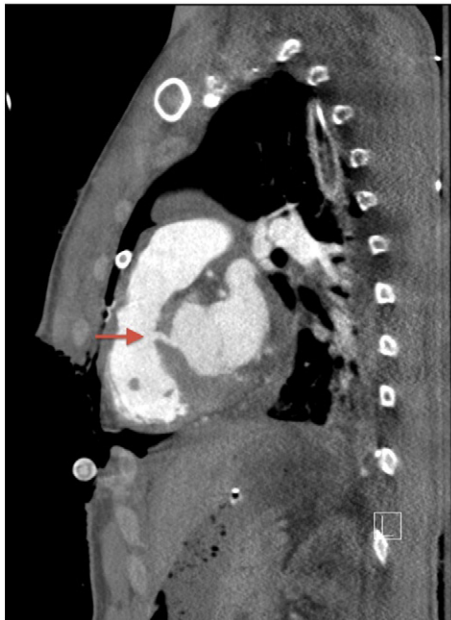<sup>\*</sup> Corresponding author at: VCU Dept of Surgery, P.O. Box 980135, Richmond, VA 23298-0454, United States.

E-mail address: [nathaniel.lee@vcuhealth.org](mailto:nathaniel.lee@vcuhealth.org) (N. Lee)

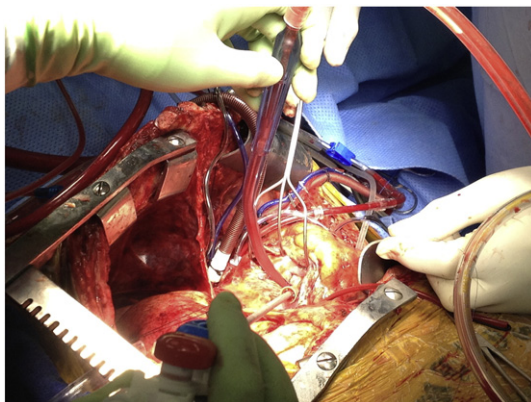


**Fig. 1.** Haemorrhage from the right ventriculotomy is controlled with gentle traction via a Foley catheter as the internal mammary arteries are ligated.

dark blood in the pericardium. The patient had return of spontaneous circulation. The incision was extended to a clamshell thoracotomy, allowing the identification of an actively haemorrhaging right ventricular injury. This was occluded with direct pressure until a Foley catheter was placed through the ventriculotomy and inflated (Fig. 1), allowing for haemostatic resuscitation and transfer to the operating room. Estimated downtime was approximately 20–25 min.



**Fig. 2.** CT angiogram demonstrates the ventricular septal defect prior to surgical repair.



**Fig. 3.** The ventricular septal defect and mitral valve injury are inspected through atriotomies prior to repair.

In the operating room, the right ventriculotomy was closed with pledgeted prolene sutures and the Foley was removed. At this time, the patient remained hypotensive. A transesophageal echo (TEE) revealed a traumatic ventricular septal defect (VSD) and mitral valve injury (Fig. 2). A cardiac surgeon was called into the case. A left ventriculotomy was identified and also repaired with pledgeted prolene. Immediate cardiac reconstruction was considered, however the patient was acidotic, coagulopathic, and hypothermic. His neurologic status was unclear and we could not be sure that he would physiologically tolerate a complex cardiac operation immediately. The patient was placed on veno-arterial ECMO via aortic root and femoral vein cannulation to rest the heart and give the patient time to declare survivability. His chest was packed and he was transferred to the cardiothoracic surgery intensive care unit (CSICU) for further resuscitation and ECMO therapy. At the conclusion of the case, the patient had lost an estimated 10 l of blood, and received 14 units of packed red cells, 10 units of plasma, and three doses of platelets.

In the CSICU, therapeutic hypothermia was initiated to support neurologic recovery. Over the following 24 h, he needed aggressive resuscitation with blood products, receiving a total of five units of packed red cells, five units of plasma, four doses of platelets, and five doses of cryoprecipitate. Considering this requirement, his chest was re-explored in the CSICU to control any surgical bleeding. Minor bleeding was noted from the chest wall musculature, but the right and left ventricle repairs were intact and haemostatic.

The patient stabilised enough to permit CT evaluation, which was obtained on post-operative day (POD) two. No additional injuries were identified on CT head, chest, and abdomen/pelvis. An EGD, performed to evaluate for esophageal injury, also revealed no abnormality. A continuous 24 hour EEG was performed which revealed generalised slowing, attributed to sedation. On POD three, the patient was able to follow simple commands during a sedation holiday.

Based on isolated cardiac wounds and reasonable neurologic function, definitive cardiac repair was planned. On POD four, the patient underwent repair of the ventricular septal defect, mitral valve, and pericardium, as well as ECMO decannulation. The 2.2 cm VSD in the perimembranous region was closed with prolene reinforced with autologous pericardium. The mitral valve was noted to have a 1.5 cm oblique defect that was repaired with prolene and reinforced with an A3–P3 commissuroplasty. Once the atriotomies were closed, the patient was rewarmed, reperfused, and weaned from bypass; TEE revealed normal systolic function, no apparent ventricular shunt, and adequate mitral function. The pericardium was then reconstructed with synthetic pericardial membrane (Fig. 3).

Postoperatively, he developed MSSA pneumonia with hypotension but was effectively treated with antibiotics. He was extubated on POD9/5 and transitioned to oral diet by POD 11/7. He was discharged to inpatient rehabilitation on POD 18/14 and was discharged home after four days. At the time of discharge home, he was cognitively intact (GCS 15) and independently completing activities of daily living and walking without assistive devices.

Two weeks after discharge, he denied any cognitive or motor difficulties, but did report paresthesias in bilateral fingers and toes. At four weeks, he again complained of paresthesias, but had no other complaints. After

four months, his finger paresthesias had resolved, though his toe paresthesias persisted. He had returned to work as a roofer without any limitations.

## Discussion

From the onset, the odds were against a favourable outcome for this patient. His mechanism alone put him at 35% risk of death [3]. Presenting in traumatic arrest increased this risk to approximately 80% [3]. Rapidly intervening with a resuscitative thoracotomy, relieving the pericardial tamponade and restoring circulation after 20 min left him at great risk of debilitating anoxic brain injury. In order to maximise the likelihood of a meaningful recovery, we elected to place him on ECMO and induce therapeutic hypothermia.

Our management strategy hinged on the availability and utilisation of ECMO, which allowed for delayed repair of the VSD and valvular injuries. This permitted us to ensure evidence of neurologic function and investigate for additional injuries whilst preventing cardiogenic shock. There have been very few reports of ECMO use for traumatic cardiac injuries [4] although, ARDS remains a well-recognised indication in trauma patients [1]. The most common complication associated with ECMO is bleeding, which occurs in up to 68% of patients [1], a risk that could be compounded by therapeutic hypothermia.

Induced hypothermia has slowly gained traction and become a standard practise for neuroprotection in cases of non-traumatic cardiac arrest, and has been incorporated into ACLS protocol [5]. Several studies have indicated significant outcome benefits including survival and increased likelihood of good neurologic recovery when used in the medical post-cardiac arrest setting [6]. Bernard et al. demonstrated that the likelihood of discharge to home or to rehab after therapeutic hypothermia was five times greater than without it [7]. However, there has been reluctance to adopt these manoeuvres in trauma patients, often citing the risks of hypothermic coagulopathy [2]. One ongoing clinical trial is evaluating use of rapid induction of hypothermia, resuscitative surgery and resuscitation with cardiopulmonary bypass in trauma patients, suggesting this attitude is evolving [8].

This case demonstrates the utility of ECMO and therapeutic hypothermia in maximising clinical outcomes in patients sustaining cardiac arrest from penetrating cardiac injury. This patient had excellent recovery because of the availability and immediate use of these interventions for a rare indication. However, the risks of haemorrhage are substantial and may be compounded with this approach, especially if it results in a neurologic “second-hit” for the patient which is associated with 150% increase in mortality in the setting of brain trauma [9]. Whilst more research is necessary to determine which patients may benefit from these interventions, this case demonstrates the feasibility of using ECMO and therapeutic hypothermia in patients having post-traumatic cardiac arrest.

## Conflict of interest

The authors of this case report have no conflicts of interest to disclose.

## References

- [1] T. Prankoff, R.B. Hirschl, C.N. Steimle, H.L. Anderson, R.H. Bartlett, Efficacy of extracorporeal life support in the setting of adult cardiorespiratory failure, *ASAIO J.* 40 (1994) M339–M343.
- [2] M.A. Tuma, L.G. Stansbury, D.M. Stein, K.A. McQuillan, T.M. Scalea, Induced hypothermia after cardiac arrest in trauma patients: a case series, *J. Trauma* 71 (2011) 1524–1527.
- [3] J.A. Asensio, J.D. Berne, D. Demetriades, L. Chan, J. Murray, A. Falabella, et al., One hundred five penetrating cardiac injuries: a 2-year prospective evaluation, *J. Trauma* 44 (1998) 1073–1082.
- [4] G. Gatti, G. Forti, A. Bologna, G. Segrati, G. Gustin, R. Korcova, et al., Rescue extracorporeal membrane oxygenation in a young man with a stab wound in the chest, *Injury* 45 (2014) 1509–1511.
- [5] M.A. Peberdy, C.W. Callaway, R.W. Neumar, R.G. Geocadin, J.L. Zimmerman, M. Donnino, et al., Part 9: post-cardiac arrest care: 2010 American Heart Association Guidelines for Cardiopulmonary Resuscitation and Emergency Cardiovascular Care, *Circulation* 122 (2010) S768–S786.
- [6] Group HaCAS, Mild therapeutic hypothermia to improve the neurologic outcome after cardiac arrest, *N. Engl. J. Med.* 346 (2002) 549–556.
- [7] S.A. Bernard, T.W. Gray, M.D. Buist, B.M. Jones, W. Silvester, G. Gutteridge, et al., Treatment of comatose survivors of out-of-hospital cardiac arrest with induced hypothermia, *N. Engl. J. Med.* 346 (2002) 557–563.
- [8] Pittsburgh Uo, Emergency preservation and resuscitation for cardiac arrest from trauma, *ClinicalTrials.gov* [Internet], National Library of Medicine (US), Bethesda (MD), 2002 [cited 2014 Mar 31]. Available from: <http://clinicaltrials.gov/show/NCT01042015>.
- [9] R.M. Chesnut, L.F. Marshall, M.R. Klauber, B.A. Blunt, N. Baldwin, H.M. Eisenberg, et al., The role of secondary brain injury in determining outcome from severe head injury, *J. Trauma* 34 (1993) 216–222.