

Case report

Paintball related ocular injuries: First case report in Saudi patients



Mohammad Al-Amry; Huda Al-Ghadeer*

Abstract

Paintball is a popular recreational sport. This case series describes three Saudi patients exposed to paintball ocular injuries with sever ocular trauma. Two patients developed hyphema and traumatic cataract and one patient had vitreous hemorrhage, choroidal detachment, commotio retinae and retinal tear. All patients require surgical intervention. Final best corrected visual acuity was 20/200, 20/30 and 20/50 respectively. Paintball related ocular injuries can result in severe visual loss and in most of the time requires surgical intervention. Most injuries occur in under-supervised settings and are easily preventable. Our main aim was to increase awareness among local ophthalmologists and eye professionals about this new game. Improved safety measures and appropriate public education could prevent such serious ocular injuries.

Keywords: Ocular, Trauma, Paintball, Eye injuries

© 2017 The Authors. Production and hosting by Elsevier B.V. on behalf of Saudi Ophthalmological Society, King Saud University. This is an open access article under the CC BY-NC-ND license (<http://creativecommons.org/licenses/by-nc-nd/4.0/>).
<http://dx.doi.org/10.1016/j.sjopt.2017.01.005>

Introduction

Paintball is a popular game played outdoors in an open field between two teams. Players try to eliminate the opposing team's players from the game by shooting them with paintballs from compressed CO² powered rifles, in order to capture their flag.¹

The first use of paintball guns and associated pellets started on 1950s when they were used by foresters to mark trees from a distance. Their use for recreational purposes did not become significant until the 1980s.²

Eye trauma due to paintball can range from mild to very severe ocular injuries which can lead to blindness.^{3,4} Up to date reported paintball injuries have increased, as a result of uncontrolled playing in which proper eye protection was not used.^{4,5}

We aimed in this case series to identify the type and severity of ocular injuries caused by paintball and to determine whether eye protective devices were used. We reported three cases presented to a single tertiary eye center to high-

light the severe visual morbidity and for our knowledge it is the first local and regional reported case series of such games causing ocular injury.

Case reports

Case 1

An 18-year-old male patient presented to Emergency Room at "blinded for peer review" with right eye (OD) injury by a paintball pellet resulted in sudden drop of his vision and lid laceration which was repaired elsewhere. He was not wearing protective goggles. The patient's previous medical and ocular histories were unremarkable.

At the initial examination his best corrected visual acuity BCVA was 20/400 right eye (OD) and 20/20 left eye (OS).

Right eye examination revealed sutured right upper lid laceration, full extra ocular muscles movements, conjunctival injection with subconjunctival hemorrhage, clear cornea, deep and quite anterior chamber, regular reactive pupil clear

Received 1 November 2016; received in revised form 16 January 2017; accepted 23 January 2017; available online 29 January 2017.

Department of Emergency, King Khaled Eye Specialist Hospital, Riyadh, Saudi Arabia

* Corresponding author at: Department of Emergency, King Khaled Eye Specialist Hospital, PO Box 7191, Riyadh 11462, Saudi Arabia.
e-mail address: hghadeer@kkesh.med.sa (H. Al-Ghadeer).



Peer review under responsibility of Saudi Ophthalmological Society, King Saud University



Production and hosting by Elsevier

Access this article online:
www.saudiophthaljournal.com
www.sciencedirect.com

lens, and fundus examination showed commotio retinae inferiorly involving the macula (Fig. 1) and minimal vitreous hemorrhage with no visible retinal breaks, documented further by Ultrasound B-Scan. Left eye examination was within normal limit.

On follow-up visit, gonioscopy of the right eye showed angle recession for about two hours with normal intraocular pressure and optic discs. The retinal findings were almost the same with noticed localized sub retinal hemorrhage and multiple choroidal breaks. The sclera depression examination showed operculated retinal break which was managed by laser retinopexy. At the last visit 3 months after the initial visit, the intraocular pressure was in the normal range with 20/200 vision secondary to the non-resolving commotio retinae.

Case 2

A 25-year-old male sustained trauma by paintball gun bullet to his left eye (OS) while he was playing a game with no safety goggles. Two days prior to presenting to the Emergency Room, he gave history of losing consciousness at the playing house.

On examination, his best corrected vision BCVA in right eye (OD) was 20/20 and light perception LP in left eye (OS), and intraocular pressure was 12 mmHg in both eyes. Slit lamp examination of right eye was unremarkable. Left eye examination showed lid swelling, subconjunctival hemorrhage, no signs of orbital fracture, full range of extra ocular muscles movements, and hyphema with ruptured sphincter muscles (Fig. 2A) with no clear view to the posterior segment. Ultrasound B-Scan was within normal.

Computed Scan (CT-Scan) for brain and orbits was done and was normal. He was started on hourly topical prednisolone acetate 1% drops and atropine 1% drops three times per day with complete bed rest.

Nine days later his vision improved to 20/70, with trace of microscopic hyphema and flat retina the topical prednisolone acetate 1% drops frequency reduced to every three hours and atropine stopped. He developed dense posterior and anterior sub-capsular cataract (Fig. 2B) dropped his vision to the range of 20/200 for which he underwent cataract extraction with posterior chamber intraocular lens with the final BCVA 20/30 and 15 mmHg IOP but with permanent pupil dilation.

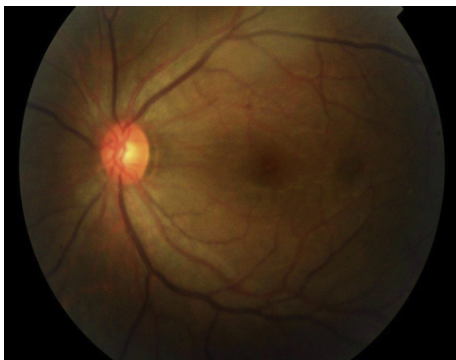

Figure 1. Fundus photography of the right eye showed commotio retinae inferiorly involving the macula was seen in case 1.

Case 3

A 12-year-old male presented to the Emergency Room after he sustained trauma to his right eye (OD) with paintball bullet.

He was not wearing the safety goggles. On examination, his best corrected visual acuity BCVA was 20/80 in right eye (OD) and 20/20 left eye OS, intraocular pressure was 23 mmHg OD and 24 mmHg OS. Left eye examination was within normal limit.

Slit lamp examination showed subconjunctival hemorrhage with sticky white matters, corneal epithelial defect and mild cornea haze with no signs of globe rupture. Anterior chamber was deep with dispersed hyphema, and the pupil was regular and reactive with no afferent pupil defect. Posterior segment was not clear because of cataract.

Ultrasound B-Scan showed no eye wall defects but mild choroidal detachment and flat retina.

The patient started on topical prednisolone acetate 1% 4 times a day for the first week and then it was tapered and topical cyclopentolate 1% drops 3 times a day was prescribed for the first 2 weeks, and requested to have complete bed rest. Two days later, his vision dropped which was due to corneal edema with Descemet's folds and the cataract changes. Iris showed sphincter ruptures, and Ultrasound B-Scan was repeated and confirmed flat retina. Six weeks later he was found to have corneal scar and dense cataract for which he underwent cataract examination and intraocular lens implantation with the final BCVA 20/50.

Discussion

Paintball sport is a recreational game utilizing a compressed gas-powered gun, gasses like propane, air or carbon dioxide had been used. These guns release a paint filled 17 mm diameter ball at speed ranging from 60 to 250 feet/s.⁵

Ocular injuries caused by paintball have similarities to those occurring after blunt trauma. The mechanism of globe injuries caused by paintball involves coup-counter coup trauma and anterior-posterior pressure to the globe.¹ This mechanism explains how choroidal rupture and iridodialysis occur.

Large objects that cause diffuse periorbital impact result in less injury to the eye because of the absorption of the shock by the orbital margin⁶ while serious ocular injury results from smaller and faster traveling objects.¹ Paintball projectiles from compressed CO² powered rifles are smaller in size and travel at very high speeds. These factors explain why paintballs are able to cause such serious ocular damage.¹

Zwaan et al.⁷ point out that since paintballs are designed to rupture on impact, there is no exist wound and all of the energy is released at the site of impact.

The most common anterior segment injuries are hyphema, dislocation of the crystalline lens, traumatic cataract, angle recession and iridodialysis.¹ In our report we found that all of our patients presented with painful immediate drop of vision, traumatic hyphema, iris sphincter rupture, and traumatic cataract in two patients.

The most common posterior segment injuries following paintball injuries include commotio retinae, choroidal rupture, retinal tear and dialysis, traumatic macular hole

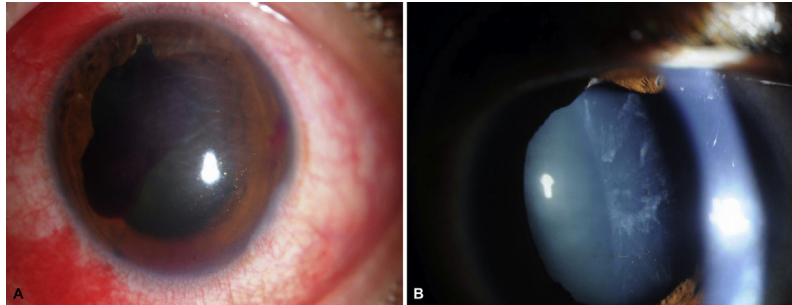


Figure 2. Slit lamp biomicroscopy of the left eye revealed clotted hyphema with ruptured sphincter muscles (A); slit lamp biomicroscopy of the left eye revealed posterior and anterior sub-capsular cataract (B).

and vitreous hemorrhage.¹ We observed one of our patient had non-resolved commotio retinae and one had peripheral retinal break in association with multiple choroidal ruptures at the posterior pole for which he received laser treatment. Two patients developed cataract for which they underwent phacoemulsification and intraocular lens implantation with improved visual acuity.

All of the patients in our series were male. Male patients are four times more likely than female to sustain ocular injuries many of which are sports related.¹

However the cataract can be extracted safely and the hyphemas often regress without consequence. The damage to vision from the retina injuries is usually long term.⁸

Paintball causes significant risk for devastating ocular trauma. Standard practice procedures for paintball field operation have been established by the American society for Testing and material (ASTM), which specify minimum safety requirements, including the presence of referees; required eye, ear and face protection and the use of gun barrel plugs that prevent inadvertent discharge of a paintball.^{9,10}

Wearing safety goggles is a must in such war games. Most of the reported injuries happened while the EPDs are off. But serious injury has been reported while wearing EPD not in consistent with the American Society for Testing and Material ASTM.^{9,10} Fogging was one of the reason the EPDs were removed by the players.² Two of our patients removed their EPDs to avoid fogging during the game.

In conclusion, additional strategies are needed to reduce the incidence of preventable paintball injuries including placing age limitation. We recommend strict regulation of sales of paintball guns and pellets to minors and an educational campaign for parents and guardians about the dangers associated with their use. Parents must not be allowed to conceptualize these dangerous guns as harmless toys.

The most important safety precautions in paintball are that EPDs must meet ASTM standards. Since it is impossible to prevent players from shooting after the game has ended, it is imperative that they do not remove their EPDs as long as they are in the playing field. Public education regarding the proper use of EPDs and increased adult supervision are necessary to decrease the incident of eye injuries.

Conflicts of interest

The authors declared that there is no conflict of interest.

References

- Keles S, Ondas O, Ekinci M, Sener MT, Erhan E, Sirinkan A, et al. Paintball related ocular trauma: paintball or painball? *Med Sci Monit* 2014;**20**:564–8.
- Fineman MS. Ocular paintball injuries. *Curr Opin Ophthalmol* 2001;**12**(3):186–90.
- Alliman KJ, Smiddy WE, Banta J, Qureshi Y, Miller DM, Schiffman JC. Ocular trauma and visual outcome secondary to paintball projectiles. *Am J Ophthalmol* 2009;**147**(2):239–42.
- Greven CM, Bashinsky AL. Circumstance and outcome of ocular paintball injuries. *Am J Ophthalmol* 2006;**141**(2):393.
- Fineman MS, Fischer DH, Jeffers JB, Buerger DG, Repke C. Changing trends in paintball sports-related to ocular injuries. *Arch Ophthalmol* 2000;**118**(1):60–4.
- Kay CN, Saunders TS, Pavan PR. Ocular injuries sustained in paintball trauma. *Graefes Arch Clin Exp Ophthalmol* 2010;**248**(3):331–2.
- Zwaan J, Bybee L, Casey P. Eye injuries during training exercises with paintballs. *Mil Med* 1996;**161**:720–2.
- Baath J, Ells AL, Kherani A, Williams RG. Severe retinal injuries from paintball projectiles. *Can J Ophthalmol* 2007;**42**:620–3.
- Tseng VL, Linakis JG, Mello MJ, Greenberg PB. Patterns of ocular injury from paintball trauma. *Eye (London)* 2014;**28**(10):1266–7.
- ASTM International, ASTM Standard F1776–10, “Standard Specification for eye protective Devices for Paintball Sports”. ASTM International: West Conshohocken, PA, USA, 2010; <http://dx.doi.org/10.1520/F1776-10>, <www.astm.org>.