

Open

Hybrid APC in Combination With Resection for the Endoscopic Treatment of Neoplastic Barrett's Esophagus: A Prospective, Multicenter Study

Mate Knabe, MD^{1,2,*}, Torsten Beyna, MD^{3,*}, Thomas Rösch, MD⁴, Jacques Bergman, MD⁵, Hendrik Manner, MD⁶, Andrea May, MD^{1,7}, Guido Schachschal, MD⁴, Horst Neuhaus, MD³, Jennis Kandler, MD^{3,8}, Bas Weusten, MD⁹, Oliver Pech, MD¹⁰, Siegbert Faiss, MD^{11,12}, Mario Anders, MD¹³, Michael Vieth, MD¹⁴, Susanne Sehner, MSc¹⁵, Raf Bisschops, MD¹⁶, Pradeep Bhandari, MD¹⁷, Christian Eil, MD¹ and Hanno Ehlken, MD⁴

INTRODUCTION: The current therapy of neoplastic Barrett's esophagus (BE) consists of endoscopic resection plus ablation, with radiofrequency ablation as the best studied technique. This prospective trial assesses a potential alternative, namely hybrid argon plasma ablation.

METHODS: Consecutive patients with neoplastic BE undergoing ablation after curative endoscopic resection (89.6%) or primarily were included into this prospective trial in 9 European centers. Up to 5 ablation sessions were allowed for complete eradication of BE (initial complete eradication of intestinal metaplasia [CE-IM]), by definition including BE-associated neoplasia, documented by 1 negative endoscopy with biopsies. The main outcome was the rate of initial CE-IM in intention-to-treat (ITT) and per-protocol (PP) samples at 2 years. The secondary end points were the rate of recurrence-free cases (sustained CE-IM) documented by negative follow-up endoscopies with biopsies and immediate/delayed adverse events.

RESULTS: One hundred fifty-four patients (133 men and 21 women, mean age 64 years) received a mean of 1.2 resection and 2.7 ablation sessions (range 1–5). Initial CE-IM was achieved in 87.2% of 148 cases in the PP analysis (ITT 88.4%); initial BE-associated neoplasia was 98.0%. On 2-year follow-up of the 129 successfully treated cases, 70.8% (PP) or 65.9% (ITT) showed sustained CE-IM; recurrences were mostly endoscopy-negative biopsy-proven BE epithelium and neoplasia in 3 cases. Adverse events were seen in 6.1%.

DISCUSSION: Eradication and recurrence rates of Barrett's intestinal metaplasia and neoplasia by means of hybrid argon plasma coagulation at 2 years seem to be within expected ranges. Final evidence in comparison to radiofrequency ablation can only be provided by a randomized comparative trial.

SUPPLEMENTARY MATERIAL accompanies this paper at <http://links.lww.com/AJG/C264>, <http://links.lww.com/AJG/C265>, and <http://links.lww.com/AJG/C266>

Am J Gastroenterol 2022;117:110–119. <https://doi.org/10.14309/ajg.000000000001539>

INTRODUCTION

The endoscopic treatment of neoplastic Barrett's esophagus (BE) has become standard in the care of these patients (1–5). Pre-conditions are a careful selection of patients with presumed low-

risk lesions (mainly maximum infiltration depth mucosal cancer, and grading G1/2), examination by high-quality endoscopy with multiple biopsies and possibly other staging examinations. The other parameters for low-risk lesions, namely absence of vascular

¹Departments of Internal Medicine II, Sana Hospital, Offenbach, Germany; ²Department of Gastroenterology and Hepatology, University Hospital Frankfurt, Frankfurt am Main, Germany; ³Department of Internal Medicine and Gastroenterology, Evangelisches Krankenhaus, Düsseldorf, Germany; ⁴Department of Interdisciplinary Endoscopy, University Hospital Hamburg-Eppendorf, Hamburg, Germany; ⁵Department of Gastroenterology and Hepatology, Amsterdam University Medical Centers, Location VUmc, Amsterdam, the Netherlands; ⁶Department of Gastroenterology, Frankfurt Hoechst Hospital, Frankfurt, Germany; ⁷Department of Gastroenterology, Hepatology, Oncology and Pneumology, Asklepios Paulinen Hospital, Wiesbaden, Germany; ⁸Department of Gastroenterology, University Hospital Düsseldorf, Düsseldorf, Germany; ⁹Department of Gastroenterology and Hepatology, St. Antonius Hospital, Nieuwegein, the Netherlands; ¹⁰Department of Gastroenterology and Hepatology, Krankenhaus Barmherzige Brüder, Regensburg, Germany; ¹¹Gastroenterology and Interventional Endoscopy, Asklepios Clinic Barmbek, Hamburg, Germany; ¹²Department of Internal Medicine I, Sana Hospital Lichtenberg, Berlin, Germany; ¹³Department of Gastroenterology and Interdisciplinary Endoscopy, Vivantes Auguste Viktoria Hospital, Berlin, Germany; ¹⁴Institute of Pathology, Klinikum Bayreuth, Bayreuth, Germany; ¹⁵Department of Medical Biometry and Epidemiology, University Hospital Hamburg-Eppendorf, Hamburg, Germany; ¹⁶Gastroenterology and Hepatology, University Hospital Leuven, Leuven Belgium; ¹⁷Department of Gastroenterology, Portsmouth Hospitals University NHS Trust, Portsmouth, UK.

Correspondence: Thomas Rösch, MD. E-mail: t.roesch@uke.de.

*Mate Knabe, MD, and Torsten Beyna, MD, contributed equally to this work.

Received March 8, 2021; accepted September 27, 2021; published online November 30, 2021

(V0) and lymphatic involvement (L0) in the submucosa and complete (R0) basal resection, can usually only be determined at the resection specimen. The current concept is based on a complete eradication of all BE epithelium, both neoplastic and nonneoplastic, mainly for preventing recurrence, which amounts to 20% or more over time when BE is left after endoscopic resection (6). This eradication is achieved with a combination of endoscopic resection (of visible lesions and/or mucosal cancer) and ablation of the remaining BE (7,8) plus reflux control (9).

Among the ablation therapies, radiofrequency ablation (RFA) has been the preferred method due to a substantial body of evidence (3,7,8,10–13) including a series of randomized trials (14–16). Argon plasma coagulation (APC) has also been used in older studies (12,17–23) including also quite a few mostly smaller randomized trials (24–31) and, more recently, another small randomized pilot trial of APC versus RFA (32). However, the techniques used and hence success rates have been variable. With the development of a combined injection and APC ablation technique, called hybrid APC (H-APC), this might change (33), and this technique could become a less costly and perhaps easier to use alternative, which may be more widely available and also have a lower rate of side effects. The present prospective multicenter study aims at systematically assessing the efficacy and safety of H-APC in the combined therapy of neoplastic BE (BE-N).

METHODS

The study was performed prospectively in 9 gastroenterology/endoscopy centers in Germany ($n = 7$) and the Netherlands ($n = 2$). All centers had sufficient experience in interventional BE therapy (>100 patients with BE-N treated). The study protocol was approved by the Hamburg Chamber of Physicians (PV4583), followed by the local IRBs of participating centers. The study was registered with German Clinical Trials Register (DRKS-ID: DRKS00003369).

Inclusion criteria

1. Patients aged >18 and <85 years with BE-N following curative endoscopic resection of visible lesions (histologically low risk, i.e., T1m, G1/2, L0 V0 R0 basal) with planned complete BE eradication or primary ablation for low-grade intraepithelial neoplasia (LGIN) or macroscopically invisible high-grade intraepithelial neoplasia (HGIN)
2. BE length $C \geq 1$ cm and ≤ 10 cm (Prague classification)
3. Informed consent

Exclusion criteria

1. Patients with BE without neoplasia
2. Patients with long BE ($C > 10$ cm) due to assumed long procedure times
3. Patients with high-risk BE cancer after resection
4. Patients without planned complete BE eradication
5. Patients with planned endoscopic resection as predominant therapy for BE eradication
6. Patients with insufficient endoscopic resection after 3 resections or more
7. Prolonged healing after endoscopic resection
8. Status after prior ablation therapy

9. Patients with high-grade stricture after endoresection not amenable to 3–4 dilatation sessions
10. Patients with noncuratively treated other cancers
11. Severe comorbidity and life expectancy of <1 year
12. Clotting disorders and esophageal varices
13. Pregnancy
14. Missing consent

Study procedures

Therapeutic aim in these patients was complete eradication of all BE-N plus remaining normal BE epithelium. Initial workup with high-resolution endoscopy was performed using staining (e.g., acetic acid) to identify and biopsy visible lesions, followed by 4 quadrant biopsies. Patients were then stratified according to visible lesions into an endoresection plus ablation vs ablation alone group, the latter with maximum histology of HGIN and no visible lesion.

Endoscopic resection (mostly endoscopic mucosal resection [EMR] with cap or ligation device or occasionally endoscopic submucosal dissection) was performed according to institutional standards and had to be performed in case of visible lesions. Only after histology of resection showing low-risk lesions, patients were included into the study; a maximum of 6 months was allowed as delay between resection and ablation to be included into the study. However, a recent endoscopy and biopsy evaluation of the remaining mucosa to be ablated had to be available either during the endoresection intervention or thereafter. Primary ablation of BE-N was only allowed with low grade dysplasia or HGD histology and strictly invisible lesions documented by state-of-the-art imaging (HD scope, extended imaging by NBI/BLI/iScan, and acetic acid staining). Six- to 12-week intervals were set between control or ablation sessions.

Argon plasma coagulation was performed using the H-APC probe after prior injection with saline using the same method as described before (33). After ablation with 60–70 W, the mucosa was cleaned with a transparent cap, and the remaining mucosa islets were treated with 40–50 W. Each time during follow-up, the distal esophagus was checked for remaining mucosal BE islands, which were then treated. It was attempted at one of the later sessions to ablate the esophagogastric junctional area about 1 cm into the cardia in a circumferential fashion. After therapy, proton pump inhibitors were administered 2–3 \times 40 mg for 2–3 weeks, followed by 1–2 \times 40 mg depending on the initial finding of additional reflux esophagitis; adherence was, however, not controlled in the protocol. The sessions were continued until the macroscopic impression on endoscopy suggested complete eradication, which was confirmed by biopsy. If biopsy was positive for BE, treatment was continued up to a maximum of 5 ablation sessions; afterward, the case was counted as a failure of the initial treatment series. If significant neoplasia (re)appeared (i.e., visible lesions, histology, or more) during the ablation course, the therapy was switched to endoresection (one more session was allowed, a total of 3) or, if required surgery. Resection treatments were usually performed as an inpatient basis, whereas ablation was performed in both settings, inpatient and outpatient, at the physicians' discretion and depending on the extent of ablation and patients' general condition (usually outpatient or day clinic after the first ablation). It was attempted to do repeat sessions at 6–12 weeks.

One follow-up endoscopy with negative biopsies (neo-Z line and neosquamous epithelium) was counted as evidence of

therapeutic success of the BE eradication therapy. After this endoscopy session, follow-up started with endoscopies with biopsies being performed after 3, 6, 12, and 24 months. If endoscopy suspected BE and was confirmed by positive biopsy or biopsy alone was positive for IM with normal/nearly normal, this was counted as recurrence (secondary end point reached) and therapy continued at the discretion of the endoscopist, but outside of the protocol.

Definitions

Complete eradication of intestinal metaplasia (CE-IM) was defined as absence of macroscopic and microscopic presence of specialized intestinal metaplasia including neoplasia; as a subgroup, results of complete eradication of neoplasia including low- and high-grade dysplasia (CE-N) were analyzed separately. CE-IM and CE-N were analyzed.

1. After completed treatment, defining treatment success (termed initial CE-IM including CE-N), which was the primary outcome (see below), as well as
2. After 2 years (termed sustained CE-IM including CE-N—or freedom of recurrence—at 2 years) defined as absence of recurrence at this time point (secondary outcome, see below).

For both initial and sustained CE-IM (including CE-N), per-protocol (PP) analysis was performed for those cases treated according to the protocol (or modified PP after adjustment following consultation with the scientific advisory board) as well as intention-to-treat (ITT) analysis with all cases treated in the denominator.

Endoscopic assessment of BE was performed according to standards (using Prague classification for any BE epithelium above proximal cardia folds), and for the assessment of residual/recurrent BE, a minimum tongue of 1 cm (\geq Prague C0M1) was assumed.

Biopsies were to be taken every 1–2 cm from all 4 quadrants as per guidelines. Follow-up protocol also included to take biopsies from neo-Z line and every 1–2 cm from neosquamous epithelium from all 4 quadrants.

On histology, performed by local experienced gastrointestinal histopathologists, BE was diagnosed whenever specialized intestinal metaplasia (with goblet cells) was present; in cases with LGIN or HGIN, a central second opinion was sought by a central histopathologist (M.V.). In case of discrepancy between endoscopy (e.g., suggesting 1 or several short remaining BE tongues or islands and inconclusive results) and histology (e.g., being negative in these cases or *vice versa*), the latter counted as gold standard. This was especially relevant for recurrences, which were diagnosed in case of positive histology irrespective whether the endoscopic aspect was positive, inconclusive, or negative. Specifically, if endoscopy and biopsy were discordant for the presence of residual (endoscopy +), but biopsies did not show BE epithelium, histopathology counted for definition of success or recurrence (biopsy –). Vice versa, in case of normal endoscopy (endoscopy –) but positive biopsies (biopsy +), histology prevailed again.

Adverse events (AEs) were recorded during hospital stays or by patient interviews at the next control or treatment appointment, such as significant pain requiring medication, fever, bleeding requiring interventions, perforation, or others. During the further course and at each subsequent visit, patients were asked for dysphagia, odynophagia, or any other chronic

esophageal complaints. Severe AEs (SAEs) were defined as those requiring extra interventions such as closure of perforations or extra interventions beyond APC for bleeding during the initial treatment or dilatation during or after H-APC therapy, that is, the requirement for reinterventions such as repeated endoscopy, surgery, ICU admission, and/or prolongation of hospital stay.

All case files were screened by 1 author (T.R.), and cases with some uncertainties (found in 29 instances) were discussed with an independent advisory board (R.B. or P.B.) and a final decision was made about classification of results and adherence to protocol. A professional CRO was involved in data monitoring.

Outcomes

The primary outcome was the rate of complete BE eradication (initial CE-IM including CE-N) determined by 1 negative follow-up endoscopy with negative biopsies. Patients with negative endoscopy but positive biopsy went back to ablation (if within allowed number of sessions). Follow-up started only after reaching the primary outcome; thus, treatment time/number of sessions could vary, but the follow-up period was 24 months in all cases (without dropouts).

The secondary outcomes were rate of patients without recurrence at 2 years (sustained CE-IM including CE-N), vice versa recurrence rates of IM and neoplasia, number of ablation sessions, and AEs (AE and SAE, immediate and late) of ablation therapy including measures (e.g., dilatation of strictures).

Statistical analysis

This study has a single-arm noncomparative setting. Therefore, and because of the explorative and descriptive nature of this study, no sample size calculation was performed. A patient number of 150 was aimed at, which was determined by feasibility within the gastroenterology/endoscopy centers. With this sample size of 150 patients as an example, the width of a Clopper-Pearson 95% confidence interval (CI) of a rate varies between 13% (in case of a lower success rate of 80%) and 8% (for a high success rate of 95%), which will result in a clinically sufficient precision. The primary and secondary outcome rates are reported descriptively with corresponding 95% CI to allow an assessment of the clinical relevance. A data management system was used with the software SecuTrial (iAS interActive Systems GmbH, Berlin, Germany). As far as possible, both PP and ITT analyses were performed; the latter were adapted after advisory board decisions.

RESULTS

During a 6-year study period (including a patient recruitment phase of 30 months), 154 patients were entered and underwent the intended therapy (patient details in Table 1 including techniques and histology of the primary endoresection procedures); the treatment course of these patients is shown in the flow sheet in Figure 1. As an example, Figure 2 shows details of the entire treatment series including H-APC in one of the study cases.

One hundred forty-eight patients (127 men and 21 women; mean age 64.2 years, range 42–84 years) reached the potential end of the BE eradication therapy, 129 of them successfully. In the ITT analysis, the treatment success (primary outcome) was therefore 83.7% (129/154; 95%: 77.0%–89.2%). Of the 129 successfully treated patients, 120 underwent the full 2-year follow-up (100 men and 20 women, mean age 63.3 years), and 85 did not experience recurrence. Thus, of the successfully treated cases, 65.9% (ITT analysis; 95% CI 57.0%–74.0%) or 70.8% (PP analysis; 95% CI 61.8%–78.8%) were considered recurrence free at 2 years

Table 1. Patients included into the study with initial histology of their BE lesion(s)

	N	%
Patients	154	—
Male:female	133:21	86.4%: 13.6%
Mean age (range)	64.07	Range 42–84
	N = 151 (no data from 3 pts.)	
BE length C (mean, range)	2.09	Range 0–13
BE length M (mean/range)	4.41	Range 0–13
% short (<C3 and/or M3)	22.52	—
Group 1: endoresection plus APC	140/154	90.91%
Technique of primary endoresection	140	100%
EMR ^a	131	93.6%
ESD	7	5.0%
EMR plus ESD	2	1.4%
Mean number of sessions	1.2	Range 1–3
Worst histology from endoresection	140	100%
Normal Barrett ^b	3	2.1%
LGIN	16	11.4%
HGIN	26	18.6%
T1 carcinoma, all but 2 low risk ^c	95	67.9%
Of those (N= 140), worst histology in the remaining BE before the first H-APC session		
Normal Barrett	94	67.1%
LGIN	26	18.6%
HGIN	11	7.9%
No biopsy taken	4	2.9%
No Barrett by histology	2	1.4%
Indefinite	3	2.1%
Group 2: H-APC as only endotherapy	14/154	9.09%
Of those (N = 14), worst histology	14	100%
Normal Barrett	1	7.1%
LGIN	12	85.7%
HGIN	1	7.1%

One hundred forty patients underwent endoscopic resection plus APC (group 1) and 14 APC only (group 2). Also see Figure 1.

APC, argon plasma coagulation; BE, Barrett’s esophagus; EMR, endoscopic mucosal resection; ESD, endoscopic submucosal dissection; H-APC, hybrid-argon plasma coagulation; HGIN, high-grade intraepithelial neoplasia; LGIN, low-grade intraepithelial neoplasia.

^a21.2% cap and 75.5% band ligation EMR; 3.5% both.

^bThree patients with a biopsy diagnosis of HGD (all confirmed by second opinion before endoresection, equivocal findings with regard to lesions), but resection specimens turned out to be negative. After ablation, biopsies from the remaining BE area also showed normal BE. Because these patients had confirmed invisible neoplasia, endoscopic BE therapy was completed by ablation after resection under the assumption of neoplastic BE.

^cIncluding 1 case with sm1 infiltration and 1 case with a G3 tumor (patient refusing surgery).

(secondary outcome, see Figure 1) following the strict criteria of recurrence as defined above.

Initial treatment success: primary outcome

Of the 148 patients with completed or attempted completed H-APC therapy within the protocol, 129 achieved the defined

treatment success (Figure 1), with a mean of 2.69 ablation sessions (range 1–5); 80.4% had 3 sessions or less. The session duration was a mean of 26 minutes (range 5–105 minutes; 48.7% 0–20 minutes, 32.5% 21–40 minutes, 18.8% > 40 minutes) for the first session and declined to a mean of 19.6 minutes (range 3–72 minutes). The variability between centers was limited (7/8 had a mean of 20–30 minutes of duration for the first session and 7/9 between 10 and 15 minutes for the last session). Of all 438 treatment sessions, all initial sessions were performed as inpatients due to local medicolegal and reimbursement conditions; later on, more ablation treatments were performed as outpatients (42.2% with last session). The duration of ablation therapy was a mean of 8 months (range 0–38 months; 0 = only 1 session). Overall, CE-N after the initial therapeutic sessions was reached in 98.0% (145/148) and CE-IM in 88.4% (129/146) of cases (PP analysis in Figure 1).

Seventeen patients were regarded as failures (3 of them neoplasia). Of these:

1. 4 were considered true failures because H-APC did not lead to a visible regression of BE despite several sessions: 1 patient had 4 sessions without measurable BE regression, 1 patient had 2 carcinoma recurrences after 2 H-APC sessions requiring 2 endoscopic resection sessions, 1 patient had widespread esophagitis/insufficient healing after the 2nd session so that the examiner decided to stop, and the last patient had vomiting and dysphagia after the third H-APC session and then refused further treatment.
2. 4 patients did not reach complete ablation by the macroscopic aspect (plus pos. biopsy) within the allowed 5 H-APC sessions and were treated with more sessions (6–7) and reached the aim but were considered as failures as per protocol.
3. 9 had positive biopsies (8 with normal endoscopy and 1 with questionable endoscopy showing a very short tongue), but had reached their limit of 5 allowed H-APC sessions. However, of the 9 positive biopsies, 1 was LGIN and 1 cancer.

No data were available from the remaining 2 patients (1 was lost to follow-up, and 1 died for unrelated reasons after a negative follow-up endoscopy without biopsy being taken).

Recurrence: secondary outcome

At the 2-year follow-up, of the 129 successfully treated patients (109 men and 20 women; mean age 63 years, range 42–79 years), 85 had a negative endoscopy and biopsy (including also negative results at the prior 6- and 12-month control). Thirty-five cases were diagnosed as recurrences at various time points until the 2-year follow-up. Of these recurrences, 13 were diagnosed on endoscopy and histology and 22 by biopsy only, with endoscopy being negative or inconclusive. Three cases were diagnosed with neoplasia (1 LGIN, 1 HGIN, and 1 cancer), 2 of them at early follow-up (Table 2).

The 2-year recurrence rate was therefore 34.1% (ITT analysis, 95% CI: 26.0%–43.0%) or 29.2% (PP analysis, 95% CI [21.2%–38.2%]) as shown in Figure 1. Vice versa, complete eradication (CE-IM) was reached in 85/129 cases (65.9%, 95% CI: 57.0%–74.0%) and CE-N in 126/129 cases (97.7%, 95% CI: 93.4%–99.5%) in the PP analysis, for the combined resection and ablation therapy. The 2-year rate of patients without remaining BE

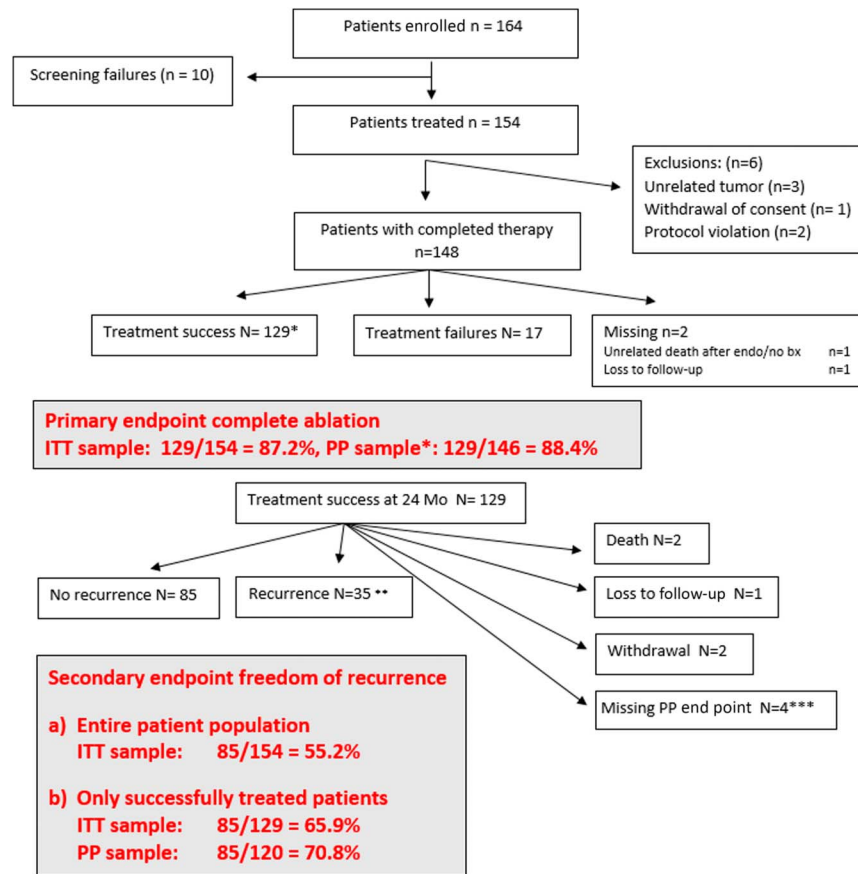


Figure 1. Flow sheet of patient inclusion and further course/outcome (see text). *SAB decisions (P. Bhandari, R. Bisschops): 3 cases did not have PP assessment of therapeutic success at 3 months after last H-APC therapy; 2 cases had endoscopy at 3 months but no biopsy, however negative biopsy at 6 months; 1 patient had his endoscopy with negative biopsy at 12 instead of 3 months. **Time course of recurrences: 6 months n = 16; 12 months n = 8; 23 months n = 11 (for details, see text). ***Twenty-four month endoscopy without biopsy n = 2 (patients so far not scheduled again due to COVID 19), 2 cases without follow-up (1 lost, and 1 reached but no endoscopy due to significant comorbidities). H-APC, hybrid argon plasma coagulation; ITT, intention-to-treat; PP, per-protocol; SAB, Scientific Advisory Board.

calculated by the entire patient population was 55.2%. Results for the 1-year follow-up are shown in the supplementary table (see Table S1, Supplementary Digital Content 1, <http://links.lww.com/AJG/C264>).

AEs: secondary outcome

The initial AE rates of H-APC per endoscopy and per patients are shown in Table 3. Complication rates were 0.5% per H-APC session and 6.1% per patient. Two of these complications could be considered significant (SAEs, 1.3%).

Strictures as the most important of delayed AEs can be specified as follows: Overall, 6 patients had to undergo dilatation after H-APC sessions, 3 of them more than once (Table 3). Details on patients reporting some form of dysphagia after the H-APC therapy without dilatation as well as cases with dilatation after endoscopic resection before H-APC treatment are shown in Supplementary Digital Content 1 (see Table S1, <http://links.lww.com/AJG/C264>). According to the ASGE American Society for Gastrointestinal Endoscopy lexicon of AEs from 2010 (34), none of the AEs was severe, and only the 6 stricture cases requiring dilatation would qualify as moderate (6/154 = 3.9%) because they required repeat endoscopy for an AE. The other AEs could be graded as mild.

Post hoc analyses

Results according to histology. Histology after endoresection before first ablation session: Primary success by subgroup was (in the group of 134 patients with endoresection plus ablation, 2 had normal BE after endoresection, see Table 1) as follows: 88.2% (82/93) in the mucosal cancer group and 88% (22/25) and 85.7% (12/14) in patients with high- and low-grade dysplasia. Fourteen patients had ablation only (see Table 1), most of them had low grade dysplasia.

With regard to histology of the remaining BE after endoresection in the combined treatment group (n = 134), histology was known or unequivocal in most cases; of those, 94 had normal remaining BE, and 27 some form of dysplasia (see Table 1). The primary success rates of cases were 96.8% and 100% in the normal and dysplastic BE groups, respectively.

Results according to BE length. In the 129 patients with initial treatment success (CE-IM including CE-N), the mean BE length was 4.18 cm (range: 1–11 cm), only slightly shorter than a mean of 5.05 cm (range 1–13 cm) in the 17 failure cases.

Altered outcome definitions by session numbers: When an altered definition of success and recurrences was assumed *post hoc*, namely 2 (instead of 1) negative endoscopies with biopsies to define initial treatment success of complete BE eradication, results would be 75.7% (initial success) and 83.9% (freedom of recurrence at 1 year).

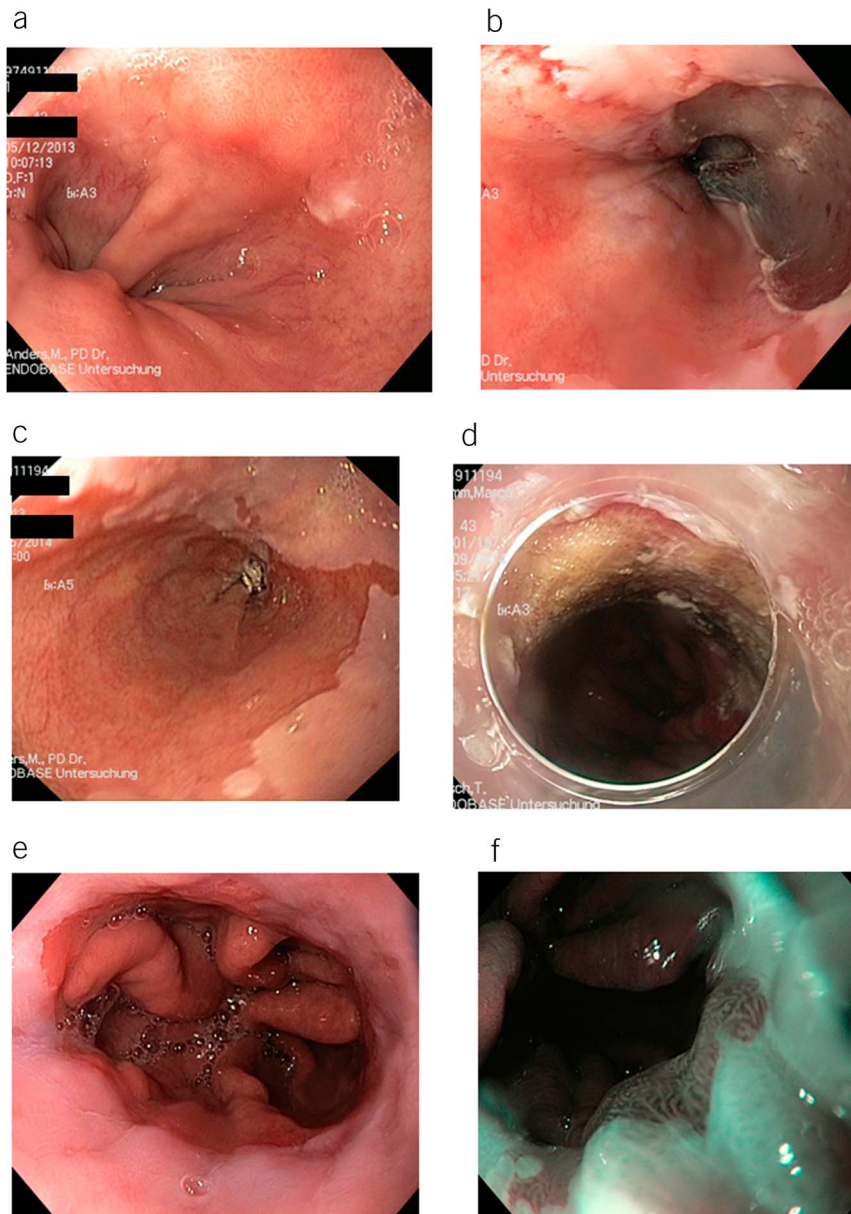


Figure 2. Example of the combined treatment in a patient with a neoplastic BE; a slightly irregular elevation is shown close to the GE junction between 12 and 3 hours (a). After EMR (b resection area), this area is now covered by neosquamous epithelium and some remaining BE on the contralateral side (c). (d) Shows the area after H-APC, and (e) (white light) and (f) (narrow band imaging) show the final result with a normal neo-Z line. BE, Barrett's esophagus; EMR, endoscopic mucosal resection; GE, gastroesophageal; H-APC, hybrid argon plasma coagulation.

Altered outcome definitions by counting positive biopsies despite negative endoscopies (see Table S3, Supplementary Digital Content 3, <http://links.lww.com/AJG/C266>): If no biopsy would have been taken from a normal-appearing Z line after therapy and a normal endoscopy would have counted as success, 7/17 initial failures would not have been recognized as such (see Table S2, Supplementary Digital Content 2, <http://links.lww.com/AJG/C265>), increasing the initial success rate from 87.2% (129/48) to 92.6% (136/148). Similarly, 22/35 recurrences were detected by biopsy only with a normal-appearing endoscopy (Table 2), not counting these would have decreased recurrence rate (PP sample; see Figure 1) from 29.1% (35/120) to 10.8% (13/120).

Results at 12-month follow-up. Of the 129 successfully treated cases, 102 were free of recurrence at 12 months; however, of those, 4 did not have biopsies during endoscopy at this time point; 12 months later, all 4 cases had negative endoscopy with negative biopsies. Thus, the rate of recurrence-free cases at 12 months is 76.0% (98/129; 95% CI: 67.9%–82.5%) in the PP analysis or 79.1% (102/129; 95% CI: 71.3%–85.2%) in a modified PP analysis, including 4 patients as success with negative endoscopy but no biopsy at 12 months with all 4 cases negative on endoscopy and biopsy at the 24-month follow-up.

Details on further follow-up of patients outside of the protocol. When patients did not reach the primary outcome of initial treatment success, or when they experienced recurrence, no

Table 2. Treatment results at 2 years: Details on the 35 recurrent cases after successful H-APC eradication (n = 129)

Follow-up interval	Endo+/histo+	Endo-/histo +	All cases
6 mo	6 IM 1 LGIN 1 HGIN	8 IM	16
12 mo	0	8 IM	8
24 mo	4 IM 1 carcinoma	6 IM	11
All cases	13	22	35
All cases neoplasia	3	0	3

The diagnosis of recurrence was based on a positive biopsy showing intestinal metaplasia or neoplasia; these were cases with either positive or negative endoscopy. Cases with endoscopically suspected recurrence but negative biopsy were not counted as recurrences and are not listed here (see text). Also see flowchart in Figure 1.

BE, Barrett's esophagus; H-APC, hybrid-argon plasma coagulation; HGIN, high-grade intraepithelial neoplasia/dysplasia; IM, intestinal metaplasia; LGIN, low-grade intraepithelial neoplasia/dysplasia.

further follow-up was included in the study protocol. However, most cases were followed at the same or similar intervals. Results are shown in Supplementary Digital Content 2 (see Table S2,

<http://links.lww.com/AJG/C265>) and, as expected, are quite diverse, especially because no standardized retreatment (mostly repeated H-APC) was available.

Of the 17 initial treatment failures, 1 had cancer and was not followed further in the study. Of the remaining 16, 12 had either more sessions than allowed or were followed in partially retreated. Under these mixed conditions, 8/11 finally became endoscopically and histologically negative, either spontaneously or after repeated H-APC.

Of the 35 recurrences occurring at different time points (Table 2), the further course is also shown in Table S2 (see Supplementary Digital Content 2, <http://links.lww.com/AJG/C265>). Of the 6- and 12-month recurrences, most were retreated and turned negative at least at the next follow-up.

Remarkably, the endoscopic aspect suggesting minor BE residues was overruled by a negative biopsy; during further follow-up, more recurrences were seen in the endoscopy and biopsy negative group (n = 24 with even 1 cancer diagnosed at 24-month follow-up) than when endoscopy was positive (n = 11) (see Table S2, Supplementary Digital Content 2, <http://links.lww.com/AJG/C265>).

DISCUSSION

This prospective multicenter study for the first time evaluates a new combination of H-APC and prior saline injection for ablation therapy of neoplastic BE. This technique could be considered

Table 3. Adverse events in the study

	N Patients/sessions	% per patient	% per session
Patients treated/H-APC sessions	154/438	—	—
Pain ^a			
Odynophagia	n = 16/18	10.4	4.1
Pain medication	n = 32/53	20.8	12.1
Fever			
Total	n = 10/10	6.5	2.3
Minor ≤ 24 hr	n = 10/10		2.3
Major >24 hr	n = 0/0	0	0
Bleeding			
Total	n = 6/6	3.9	1.4
Minor	n = 5/5	3.2	1.1
Major ^c	n = 1/1	0.65	0.2
Perforation ^c	n = 1/1	0.65	0.2
Total acute AE	n = 27/35	17.5	6.1
Of those, SAE	n = 2/2	1.3	0.5
Posttreatment stricture	n = 6/6	3.9	—
No. of dilations	9	—	—
Range	1–3	—	—

AE, adverse event; H-APC, hybrid argon plasma coagulation; SAE, severe AE.

^aThe majority were recorded during the first session (11/18 for pain and 31/50 for pain medication).

^bSummary of patient- and session-related complications; cases/events with more than 1 complication are counted only once. As for pain, odynophagia was counted (and not pain medication).

^cThe 2 SAEs consisted of treatment-related bleeding, which required an intervention (clipping) during the same session and treatment-related perforation (suspected small hole 1–2 mm, no clinical signs), which was also clipped during the same session.

as an alternative to RFA within the multimodal treatment of this condition, which consists of endoscopic resection of (visible) neoplasia, mostly HGIN and low-risk mucosal cancer, and ablation of the remaining BE. Results of primary ablation success and recurrence are well within the range known from RFA. The primary success rate was 87.2%, and 70.8% of them remained recurrence free in the PP analysis. The precise figures depending on the type of analysis are shown in Figure 1.

Although final conclusions can only come from a randomized comparison, the revitalized technique of APC (now combined with prior submucosal injection) has the potential to become more widely available due to lower costs and probably also lower training requirements than for competing techniques such as RFA and, more recently, cryoablation (35). Injection and APC ablation techniques have been within the skill sets of most endoscopists for a long time, so the need for training is likely to be reduced. We did not compare prospective data from these patients with our retrospective experience of RFA in the treatment of patients, which might be a limitation of the current article. However, some centers participated in previous RFA studies (15,36), where BE eradication results can be seen, mostly with >90% efficacy results in the PP analysis (36). Overall complications were seen in 25% in this series (8% stricture rate). Patient symptoms were not recorded, but a recent publication from the Dutch group comparing RFA with cryoablation report on a 70% rate of pain killers administered right after RFA (37). In our study, a recall bias may have underestimated (minor) symptoms because patients were asked only at the next follow-up visit, that is, at 3 months. Again, only a prospective randomized study can fully answer this question; a recent pilot randomized controlled trial found slightly more symptoms in the RFA compared with the (conventional) APC group (38).

In general, in patients with BE-N, the final outcome is currently considered a complete eradication of all BE tissue (called CE-IM), which of course also includes absence of any neoplasia (CE-N). This is achieved by a combination of techniques such as resection and ablation and for each step, several techniques are available. Therefore, the relative contribution of a specific ablation technique to the final success is not easy to analyze among all these parameters. It can be assumed that resection is predominant in achieving CE-N, whereas ablation leads to complete CE-IM and subsequently prevention of metachronous neoplasia; however, there is little solid evidence on which techniques are the best to achieve which goal. Starting with endoresection, EMR and endoscopic submucosal dissection have only been compared in a small randomized trial, which was not powered for oncologic outcome (39); it has furthermore been shown that the 2 available EMR techniques (cap and ligation) achieve similar results (40,41). RFA ablation in combination with resection (EMR) has been shown to lead to better results than resection alone, mainly due to a lower complication rate (15).

Our study followed current definitions and guidelines of treating neoplastic BE, but adopted very strict definitions of treatment success and recurrence. This is in some contrast to most other ablation series, where no clear definition of end points such as success and recurrence and the separation of the 2 is given; often, treatment is continued in a substantial proportion of patients during follow-up for recurrence, which means that no clear initial end point is reached or recurrences are not counted as such since being retreated. We also choose the 2-year follow-up results which—with a 30-month recruitment period—led to a 6-year duration of the study. A recent rigorous systematic review was left with only 8 articles, which had a

follow-up of 2 years and used stringent criteria for definition of treatment success and diagnosis of recurrence (42).

Thus, in our study, of the 17 cases that were considered as initial failures, 7 were only positive on biopsy. Of those, 4 turned negative during follow-up, partially due to retreatment; if these 4 cases would have been (incorrectly as PP) counted as final success with less stringent study criteria, success rate (initial CE-IM, PP analysis) would have been risen from 87% to nearly 90%. On the other hand, of the endoscopy-negative, biopsy cases, 2 had neoplasia at the next follow-up endoscopy, 1 with invisible low-grade dysplasia, and 1 with cancer. Thus, careful macroscopic and biopsy follow-up is necessary after a successfully completed BE eradication therapy. It is well known that sampling error can miss remaining BE and/or neoplasia when not or hardly visible. Whether this only happens early ($n = 2$ in our study) or also late ($n = 1$ cancer at 24 months in our study) cannot be concluded from this low case number.

Indeed, the posttreatment assessment of BE recurrence is still a matter of debate. Although most researchers agree on a combined endoscopic and histologic assessment for ascertaining initial treatment success, a normal Z line on high-definition endoscopy is considered as success during follow-up and biopsies are not (regularly) taken. A recent Dutch study has claimed that biopsy may not be necessary during follow-up if endoscopy is negative (43). In addition, some protocols use circular ablation in the distal esophagus 1–2 cm down into the cardia with the final treatment session to reduce recurrences (44). Further data are necessary, whether biopsy can be omitted in this setting, and also what the existence of some IM cells may mean for the final long-term outcome, perhaps similar to the existence of minimal residual disease in gastric lymphoma (45). Otherwise, if any IM on biopsy is considered a primary failure or later a recurrence, the patient is looping back to ablation endotherapy again. In our *post hoc* analysis, among the 35 recurrences after a negative biopsy (primary outcome for treatment success), an initial negative endoscopy was more frequent ($n = 24$) than a positive one ($n = 11$). In our study, with our strict definition of recurrence, we counted positive BE biopsies in a setting of endoscopically normal neo-Z line as recurrence (see Table S3, Supplementary Digital Content 3, <http://links.lww.com/AJG/C266>). If these cases were not considered or biopsy would not have performed as in other articles, recurrence rates could have been downplayed from 29.2% to 10.8% in the PP analysis. Not to forget that different definitions (ITT/PP) and thus different denominators lead to different end results, as shown for recurrence rates in Figure 1.

The operator dependency of H-APC as with any endoscopic intervention may also play a role in achieving good or excellent results. This starts with recognition of subtle remaining BE tissue and carefully treating and retreating these areas. It can be debated whether APC or H-APC is more operator dependent than other techniques, but a certain learning curve is to be assumed for all ablation techniques. In addition, what finally counts is the outcome in relation to number of sessions and also AEs. In all these respects, multicenter studies with multiple examiners may be more representative than single-center trials with 1 or few dedicated and very experienced endoscopists.

Finally, complication rates were quite low, with a 4% overall stricture rate. True comparative data with other ablative techniques can only come from a randomized trial. In a recent review looking at the combination of focal EMR and RFA (a combination similar to our study), bleeding and perforation rates were very low, and strictures ranged from 0% to 23.1% (8). A review from 2016 focusing on AEs found an overall stricture rate of 5.6% (11); pain with RFA has recently received more attention in comparison with cryoablation,

another candidate for BE ablative therapies (37,46): pain medication was administered 12% of all sessions (20% of cases on a patient basis), whereas the respective figures for RFA and cryotherapy were 61% vs 26% (46) or 70% vs 25% (37) or in the abovementioned 2 studies. Whether H-APC really has a lower postprocedural pain rate has to be determined in a randomized trial with equal patient and treatment characteristics in both arms.

Costs were another argument to reintroduce APC in its hybrid form into Barrett's therapy, with the combined APC and injection probe for H-APC being substantially cheaper than even the focal RFA devices.

In conclusion, our study suggests that H-APC seems to have a similar overall outcome as RFA. However, final evidence can only come from a prospective randomized comparative trial. In addition, we want to make a strong plea for using strict and clear definition in studies of initial treatment success (initial CE-IM including CE-N) as well as of absence of recurrence at defined follow-up time points (sustained CE-IM including CE-N, e.g., at 2 years). Finally, these end points should be clearly defined to include both negative endoscopy and negative 4-quadrant biopsies. Only then, study results would really be comparable.

CONFLICTS OF INTEREST

Guarantor of the article: Thomas Rösch, MD.

Specific author contributions: Original data were collected in all participating centers in a central database. Data analysis was done by Hartmut Hahn/Erbe under the guidance of T.R. Manuscript writing was one by T.R. with input from all co-authors. S.S. contributed to the statistics. All authors had access to the study data and had reviewed and approved the final manuscript.

Financial support: Study was supported by Erbe Co, Tübingen, Germany.

Potential competing interests: None to report.

Study Highlights

WHAT IS KNOWN

- ✓ Neoplastic Barrett's esophagus (BE) is commonly treated by a combination of endoscopic resection of visible and/or cancerous lesions and ablation of the residual BE epithelium.
- ✓ For ablation, thermal techniques are used in most cases, and of those, radiofrequency ablation is the technique with the most published evidence and is currently recommended.
- ✓ Argon plasma coagulation (APC) has been used in some previous studies, with mixed results.

WHAT IS NEW HERE

- ✓ APC has been developed further into a new technique combining APC with prior submucosal injection, called hybrid argon plasma coagulation.
- ✓ This is the first prospective multicenter series on 154 patients with a 2-year follow-up and a strict protocol, clearly differentiating initial and durable complete eradication of intestinal metaplasia including neoplasia.
- ✓ Initial and durable success rates at 2 years in a per-protocol analysis were 87.2% and 70.8%, respectively.
- ✓ Adverse events on a patient basis were seen in 6.1% including a stricture rate of 3.9% requiring a few dilatation sessions.
- ✓ Final and solid evidence can only come from a randomized comparative trial.

REFERENCES

1. Shaheen NJ, Falk GW, Iyer PG, et al. ACG clinical guideline: Diagnosis and management of Barrett's esophagus. *Am J Gastroenterol* 2016;111:30–51.
2. Clermont M, Falk GW. Clinical guidelines update on the diagnosis and management of Barrett's esophagus. *Dig Dis Sci* 2018;63:2122–8.
3. Wani S, Wani S, Qumseya B, et al. Endoscopic eradication therapy for patients with Barrett's esophagus-associated dysplasia and intramucosal cancer. *Gastrointest Endosc* 2018;87:907–931.e9.
4. Bennett C, Moayyedi P, Corley DA, et al. BOB CAT: A large-scale review and Delphi consensus for management of Barrett's esophagus with No dysplasia, indefinite for, or low-grade dysplasia. *Am J Gastroenterol* 2015; 110:662–83.
5. Weusten B, Bisschops R, Coron E, et al. Endoscopic management of Barrett's esophagus: European Society of Gastrointestinal Endoscopy (ESGE) position statement. *Endoscopy* 2017;49:191–8.
6. May A, Gossner L, Pech O, et al. Intraepithelial high-grade neoplasia and early adenocarcinoma in short-segment Barrett's esophagus (SSBE): Curative treatment using local endoscopic treatment techniques. *Endoscopy* 2002;34:604–10.
7. de Matos MV, da Ponte-Neto AM, de Moura DTH, et al. Treatment of high-grade dysplasia and intramucosal carcinoma using radiofrequency ablation or endoscopic mucosal resection + radiofrequency ablation: Meta-analysis and systematic review. *World J Gastrointest Endosc* 2019; 11:239–48.
8. Desai M, Saligram S, Gupta N, et al. Efficacy and safety outcomes of multimodal endoscopic eradication therapy in Barrett's esophagus-related neoplasia: A systematic review and pooled analysis. *Gastrointest Endosc* 2017;85:482–95.e4.
9. Komanduri S, Kahrilas PJ, Krishnan K, et al. Recurrence of Barrett's esophagus is rare following endoscopic eradication therapy coupled with effective reflux control. *Am J Gastroenterol* 2017;112:556–66.
10. Qumseya BJ, Wani S, Gendy S, et al. Disease progression in Barrett's low-grade dysplasia with radiofrequency ablation compared with surveillance: Systematic review and meta-analysis. *Am J Gastroenterol* 2017;112:849–65.
11. Qumseya BJ, Wani S, Desai M, et al. Adverse events after radiofrequency ablation in patients with Barrett's esophagus: A systematic review and meta-analysis. *Clin Gastroenterol Hepatol* 2016;14:1086–95.e6.
12. Krishnamoorthi R, Singh S, Ragnathan K, et al. Risk of recurrence of Barrett's esophagus after successful endoscopic therapy. *Gastrointest Endosc* 2016;83:1090–106.e3.
13. Orman ES, Li N, Shaheen NJ. Efficacy and durability of radiofrequency ablation for Barrett's esophagus: Systematic review and meta-analysis. *Clin Gastroenterol Hepatol* 2013;11:1245–55.
14. Phoa KN, van Vilsteren FG, Weusten BL, et al. Radiofrequency ablation vs endoscopic surveillance for patients with Barrett esophagus and low-grade dysplasia: A randomized clinical trial. *JAMA* 2014;311:1209–17.
15. van Vilsteren FG, Pouw RE, Seewald S, et al. Stepwise radical endoscopic resection versus radiofrequency ablation for Barrett's oesophagus with high-grade dysplasia or early cancer: A multicentre randomised trial. *Gut* 2011;60:765–73.
16. van Vilsteren FG, Phoa KN, Alvarez Herrero L, et al. A simplified regimen for focal radiofrequency ablation of Barrett's mucosa: A randomized multicenter trial comparing two ablation regimens. *Gastrointest Endosc* 2013;78:30–8.
17. Byrne JP, Armstrong GR, Attwood SE. Restoration of the normal squamous lining in Barrett's esophagus by argon beam plasma coagulation. *Am J Gastroenterol* 1998;93:1810–5.
18. Pereira-Lima JC, Busnello JV, Saul C, et al. High power setting argon plasma coagulation for the eradication of Barrett's esophagus. *Am J Gastroenterol* 2000;95:1661–8.
19. Schulz H, Miehlke S, Antos D, et al. Ablation of Barrett's epithelium by endoscopic argon plasma coagulation in combination with high-dose omeprazole. *Gastrointest Endosc* 2000;51:659–63.
20. Eisendrath P, Van Laethem JL, Devière J. Follow-up of Barrett's epithelium after ablation by endoscopic argon plasma coagulation. *Gastrointest Endosc* 2001;54:137–8.
21. Shand A, Dallal H, Palmer K, et al. Adenocarcinoma arising in columnar lined oesophagus following treatment with argon plasma coagulation. *Gut* 2001;48:580–1.
22. Van Laethem JL, Jagodzinski R, Peny MO, et al. Argon plasma coagulation in the treatment of Barrett's high-grade dysplasia and in situ adenocarcinoma. *Endoscopy* 2001;33:257–61.
23. Claydon PE, Ackroyd R. Argon plasma coagulation ablation of Barrett's oesophagus. *Scand J Gastroenterol* 2005;40:617–28.

24. Manner H, Rabenstein T, Pech O, et al. Ablation of residual Barrett's epithelium after endoscopic resection: A randomized long-term follow-up study of argon plasma coagulation vs. surveillance (APE study). *Endoscopy* 2014;46:6–12.
25. Bright T, Watson DI, Tam W, et al. Prospective randomized trial of argon plasma coagulation ablation versus endoscopic surveillance of Barrett's esophagus in patients treated with antisecretory medication. *Dig Dis Sci* 2009;54:2606–11.
26. Sie C, Bright T, Schoeman M, et al. Argon plasma coagulation ablation versus endoscopic surveillance of Barrett's esophagus: Late outcomes from two randomized trials. *Endoscopy* 2013;45:859–65.
27. Bright T, Watson DI, Tam W, et al. Randomized trial of argon plasma coagulation versus endoscopic surveillance for Barrett esophagus after antireflux surgery: Late results. *Ann Surg* 2007;246:1016–20.
28. Dulai GS, Jensen DM, Cortina G, et al. Randomized trial of argon plasma coagulation vs. multipolar electrocoagulation for ablation of Barrett's esophagus. *Gastrointest Endosc* 2005;61:232–40.
29. Kelly CJ, Ackroyd R, Brown NJ, et al. Endoscopic ablation of Barrett's oesophagus: A randomized-controlled trial of photodynamic therapy vs. argon plasma coagulation. *Aliment Pharmacol Ther* 2004;20:1289–96.
30. Ragnath K, Krasner N, Raman VS, et al. Endoscopic ablation of dysplastic Barrett's oesophagus comparing argon plasma coagulation and photodynamic therapy: A randomized prospective trial assessing efficacy and cost-effectiveness. *Scand J Gastroenterol* 2005;40:750–8.
31. Sharma P, Wani S, Weston AP, et al. A randomised controlled trial of ablation of Barrett's oesophagus with multipolar electrocoagulation versus argon plasma coagulation in combination with acid suppression: Long term results. *Gut* 2006;55:1233–9.
32. Peerially MF, Bhandari P, Ragnath K, et al. Radiofrequency ablation compared with argon plasma coagulation after endoscopic resection of high-grade dysplasia or stage T1 adenocarcinoma in Barrett's esophagus: A randomized pilot study (BRIDE). *Gastrointest Endosc* 2018;89:680–9.
33. Manner H, May A, Kouti I, et al. Efficacy and safety of Hybrid-APC for the ablation of Barrett's esophagus. *Surg Endosc* 2016;30:1364–70.
34. Cotton PB, Eisen GM, Aabakken L, et al. A lexicon for endoscopic adverse events: Report of an ASGE workshop. *Gastrointest Endosc* 2010;71:446–54.
35. Canto MI, Trindade AJ, Abrams J, et al. Multifocal cryoballoon ablation for eradication of Barrett's esophagus-related neoplasia: A prospective multicenter clinical trial. *Am J Gastroenterol* 2020;115:1879–90.
36. Phoa KN, Pouw RE, Bisschops R, et al. Multimodality endoscopic eradication for neoplastic Barrett oesophagus: Results of an European multicentre study (EURO-II). *Gut* 2016;65:555–62.
37. van Munster SN, Overwater A, Haidry R, et al. Focal cryoballoon versus radiofrequency ablation of dysplastic Barrett's esophagus: Impact on treatment response and postprocedural pain. *Gastrointest Endosc* 2018;88:795–803.e2.
38. Peerially MF, Bhandari P, Ragnath K, et al. Radiofrequency ablation compared with argon plasma coagulation after endoscopic resection of high-grade dysplasia or stage T1 adenocarcinoma in Barrett's esophagus: A randomized pilot study (BRIDE). *Gastrointest Endosc* 2019;89:680–9.
39. Terheggen G, Horn EM, Vieth M, et al. A randomised trial of endoscopic submucosal dissection versus endoscopic mucosal resection for early Barrett's neoplasia. *Gut* 2017;66:783–93.
40. Pouw RE, van Vilsteren FG, Peters FP, et al. Randomized trial on endoscopic resection-cap versus multiband mucosectomy for piecemeal endoscopic resection of early Barrett's neoplasia. *Gastrointest Endosc* 2011;74:35–43.
41. May A, Gossner L, Behrens A, et al. A prospective randomized trial of two different endoscopic resection techniques for early stage cancer of the esophagus. *Gastrointest Endosc* 2003;58:167–75.
42. Desai M, Rösch T, Sundaram S, et al. Systematic review with meta-analysis: The long-term efficacy of Barrett's endoscopic therapy-stringent selection criteria and a proposal for definitions. *Aliment Pharmacol Ther* 2021;54:222–33.
43. van Munster S, Nieuwenhuis E, Weusten B, et al. Long-term outcomes after endoscopic treatment for Barrett's neoplasia with radiofrequency ablation ± endoscopic resection: Results from the national Dutch database in a 10-year period. *Gut* 2021. [Epub ahead of print May 13, 2019.] (doi: 10.1136/gutjnl-2020-322615).
44. Belghazi K, Bergman J, Pouw RE. Endoscopic resection and radiofrequency ablation for early esophageal neoplasia. *Dig Dis* 2016;34:469–75.
45. Fischbach W, Dorlöchter C. Patients with gastric MALT lymphoma revealing persisting endoscopic abnormalities after successful eradication of *Helicobacter pylori* can be safely managed by a watch-and-wait strategy. *Z Gastroenterol* 2019;57:593–9.
46. Solomon SS, Kothari S, Smallfield GB, et al. Liquid nitrogen spray cryotherapy is associated with less postprocedural pain than radiofrequency ablation in Barrett's esophagus: A multicenter prospective study. *J Clin Gastroenterol* 2019;53:e84–90.

This is an open access article distributed under the terms of the Creative Commons Attribution-Non Commercial-No Derivatives License 4.0 (CCBY-NC-ND), where it is permissible to download and share the work provided it is properly cited. The work cannot be changed in any way or used commercially without permission from the journal.