

An Extremely Rare Complication of Ureteral Pigtail Stent Placement: A Case Report

Davood Arab,¹ Arash Ardestani Zadeh,¹ Rahimeh Eskandarian,^{2,*} Mehrshad Asaadi,³ and Kamran Ghods¹

¹Department of Surgery, Kowsar Hospital, Semnan University of Medical Sciences, Semnan, IR Iran

²Department of Cardiology, Kowsar Hospital, Semnan University of Medical Sciences, Semnan, IR Iran

³Pars Hospital, Tehran, IR Iran

*Corresponding author: Rahimeh Eskandarian, Department of Cardiology, Kowsar Hospital, Semnan University of Medical Sciences, Semnan, IR Iran. Tel: +98-9127312407, Fax: +98-2333448950, E-mail: are20935@gmail.com

Received 2016 January 22; Revised 2016 February 18; Accepted 2016 March 14.

Abstract

Double-J (DJ) stents are the main tools used in urological practice for prevention and treatment of obstruction. Stenting is also mandatory after complicated ureteroscopy or TUL (Transureteral Lithotripsy). Known complications are upper migration of DJ stents into the kidney and lower migration to the bladder. In a man with an impacted right lower ureteral stone, a DJ stent was placed because the ureteroscope was not passed from an intramural ureter. We reported a very rare complication of DJ ureteral stent placement with intravascular migration to the pulmonary arteries, which was removed percutaneously through the right femoral vein under fluoroscopic guidance.

Keywords: Renal Colic, Complication, Lower Ureteral Stone, Ureteral Pigtail Stent

1. Introduction

Double-J (DJ) stents are used to drain urine from the kidney to the bladder and are effective in managing and preventing upper urinary tract (UT) obstruction in various urological conditions (1). Ureteral stenting is a routine procedure in urological practice. The most common indication of stenting is to prevent and relieve upper UT obstruction (2, 3). The known complications of DJ stent include encrustation, fragmentation, proximal and distal migration, dysuria, and frequency (1). Most of these complications are self-limited and can be managed with suitable urologic interventions and supportive medical management (2-4). We reported a rare and serious case of vascular migration of a stent to the pulmonary artery, with a long-time remained. The available literature is scant regarding management of such situations. The diagnostic tools and management options in such cases are discussed.

2. Case Presentation

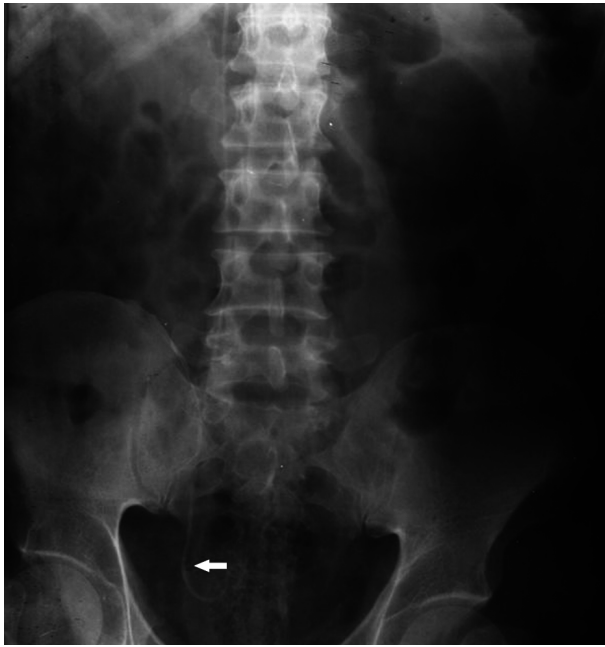The patient was a 47-year-old man with a history of long-lasting renal colic from four months before his admission. Ultrasonography and IVP showed a right lower ureteral stone with moderate hydronephrosis. Transurethral lithotripsy (TUL) was planned. The surgeon had difficulty passing the ureteroscope through

the intramural ureter and, with frequent manipulation, a 0.035 guidewire was passed through the intramural ureter, after which a DJ stent of 4.8F-30cm was inserted over the guidewire. The procedure was not performed under fluoroscopy control. KUB was performed after the procedure for control of the location of the DJ, but the resident did not diagnose abnormal pathway of the stent. The patient was discharged in good condition. He then developed gross hematuria for two days and, after passing a large clot in urine, the hematuria stopped, and he had no further urinary symptoms. Thirteen days after insertion of the DJ stent, he passed the urinary stone. After two weeks, he came to the clinic, and the surgeon planned to remove the DJ stent in the operating room by cystoscopy.

The patient was admitted for the planned cystoscopy and removal of the stent. The cystoscope was passed into the bladder, but the stent could not be visualized there. Migration of the stent to another anatomical position, such as the ureter or retroperitoneal, or vascular migration was suggested. The patient was referred to the radiology department, where KUB and chest X-ray (CXR) was performed. All X-rays after the DJ stent placement were reviewed. The stent had an abnormal pathway, probably entering into the inferior vena cava (Figure 1). In the recent KUB, there was no evidence of the DJ stent. CXR showed abnormal density that could have been the shadow of the stent (Figure 2). Consultation with the cardiologist and

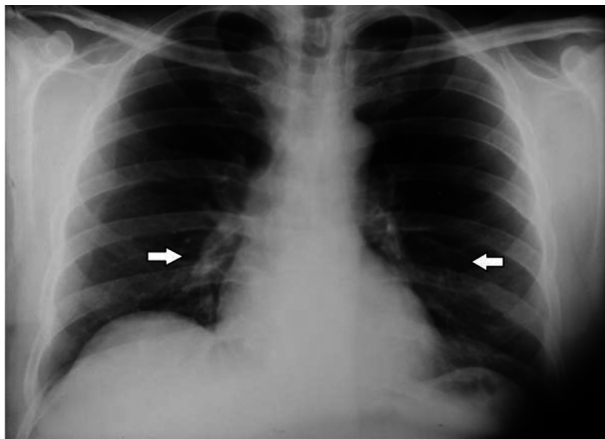
cardiac surgeon was requested.

Figure 1. KUB After Placement of DJ Stent in Right Ureter



The X-ray revealed an abnormal pathway of the double-J stent that probably entered into the inferior vena cava. The arrow shows the position of the ureteral stone, 8 × 6 mm in size, at the ureterovesical junction.

Figure 2. CXRAfter the DJ Stent was not Detected in the KUB



The arrows show the abnormal density, which was the shadow of the stent.

Beside echocardiography showed normal left and right ventricular size and function. Aortic, pulmonic, and mitral valves were normal. The tricuspid valve had mild tricuspid regurgitation. The patient was referred to the an-

giography department. In fluoroscopy, during pulmonary angiography, the DJ stent was seen completely in the pulmonary artery. The tip of the stent was fixed, which may have been due to wedging in the pulmonary artery branch, thrombus formation in this site, or other causes (Figure 3). Other laboratory data including CBC, BUN, ESR, CRP, and creatinine were normal. Blood culture was requested, and prophylactic antibiotic and anticoagulant therapies were performed for the patient. Further, the literature was reviewed for management in such situations. There are two methods to remove endovascular foreign bodies: open surgery and intravascular retrieval (5-9), and it was planned to remove the stent percutaneously. 10 French right femoral sheath was used, and pulmonary angiography was performed (Figure 4). A multipurpose 7F catheter was used to try to release the fixed left tip of the stent, but frequent manipulation was not successful. The right distal tip of the stent was captured by peripheral snare, and the stent was retrieved successfully without any complication. BUN and creatinine after angiography and procedure were normal. The patient was discharged in good condition. After six months follow-up, he had no symptoms.

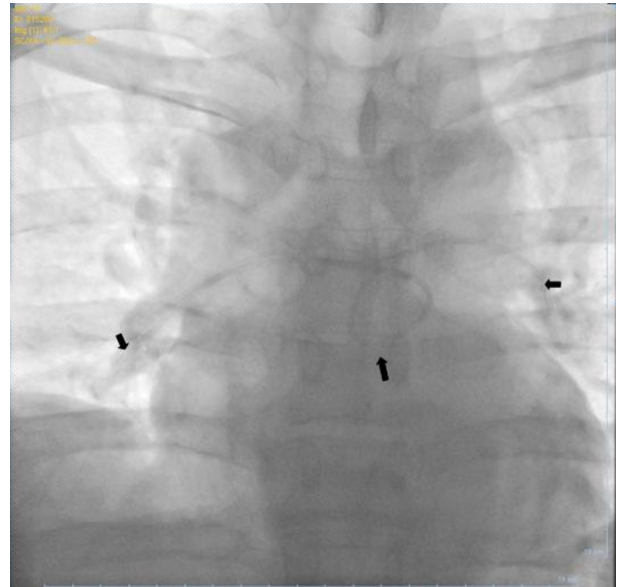
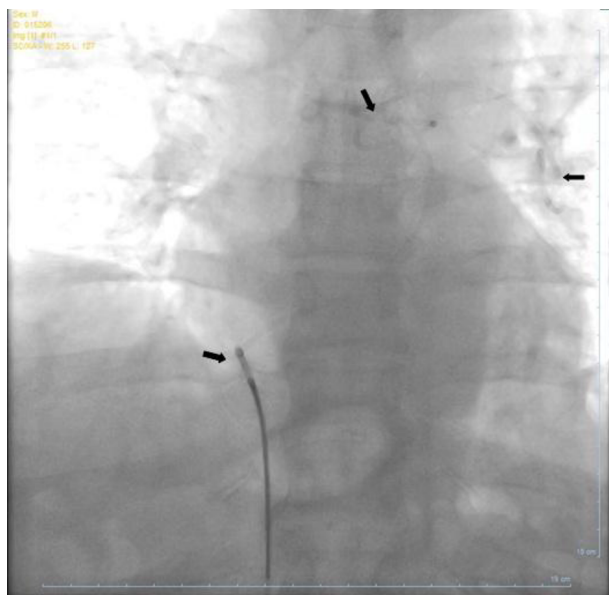

Figure 3. Fluoroscopic View of Pulmonary Angiography Showed that the DJ Stent was Completely in the Pulmonary Artery

3. Discussion

The common symptoms and probable complications following DJ stent insertion include lower UT symptoms, loin pain, hematuria, UT infection, vesicoureteral reflux

Figure 4. Fluoroscopic View of Chest

When the peripheral snare was introduced percutaneously from the femoral sheath, and the tip of the stent was captured by it.

(VUR), stent malposition, luminal obstruction, ureteral erosion or necrosis, stone formation, encrustation, fracture, and migration proximally and distally in the urinary system (4, 10).

The ureter is adjacent to the iliac vein and the vena cava. Stent placements can be prone to vessel erosion, and in rare situations, intravascular migration of the DJ stent has been reported (6, 10). Michalopoulos et al. reported pulmonary thromboembolism immediately after surgery from migration of a stent into the heart and left pulmonary arterial system after pyelolithotomy and antegrade insertion of a pigtail ureteral stent. The stent was removed percutaneously by using the femoral vein as an access site (7). Intravascular migration of a DJ stent into the inferior vena cava was reported. Percutaneous removal of the migrated stent was performed under fluoroscopic guide (5). However, in two other case reports, the stent was removed successfully via cardiopulmonary bypass (6, 8).

Although placement of a ureteral stent is easy, serious complications may occur during or after such a procedure (5-9).

In this case, the surgeon blindly passed a 0.035 guidewire through the intramural ureter, when it probably passed into the submucosa and then the iliac vessel. Several methods can help to reduce the risk of such migration. First, the guidewire should not be forced blindly through the ureter. Second, use of hydrophilic wire can

prevent passing the wire into the submucosal layer. Moreover, DJ stent insertion under fluoroscopic guide can reduce these complications. In the absence of fluoroscopy, postoperative X-ray should be considered. If abnormal position of the stent is suspected, other diagnostic methods, such as CT with IV contrast, can confirm or disprove the diagnosis. Finally, clinicians should pay attention to warning symptoms of the patient, such as significant hematuria and severe abdominal pain.

In this case, the stent was completely in the pulmonary arteries. Multiple treatment options can be used for this situation, such as percutaneous removal by snare catheter, when possible, and open surgery. Because of the good condition of the patient and available expertise for endovascular intervention, it was decided to remove the stent by the endovascular method with femoral access. If expertise for endovascular intervention is not available, open surgical removal is an alternative, safe method. Intravascular migration of DJ stents is a rare but serious complication. When there is doubt, complementary diagnostic procedures and early intervention are recommended. Percutaneous removal of a migrated stent under fluoroscopic guidance by snare catheter from femoral access is a safe and effective treatment.

Acknowledgments

We would like to thank the clinical research development unit of the Kowsar educational, research and therapeutic centers of Semnan University of Medical Sciences for providing facilities for this work.

Footnotes

Authors' Contribution: Davood Arab, study concept and design, acquisition of data, drafting of the manuscript; Arash Ardestani Zadeh, study concept and design, acquisition of data, drafting of the manuscript; Rahimeh Eskandarian, study concept and design, acquisition of data, drafting of the manuscript; Mehrshad Asaadi, acquisition of data, drafting of the manuscript; Kamran Ghods, drafting of the manuscript.

Funding/Support: Clinical research development unit of the Kowsar educational, Research and therapeutic centers of Semnan University of Medical Sciences.

References

1. Zafar MN. Urologic J.J stents: uses and complications. *J Pak Med Assoc.* 1993;43(8):146. [PubMed: 8264089].

2. Memon NA, Talpur A, Memon JM. Indications and complications of indwelling ureteral stenting at NMCH, Nawabshah. *Pak J of Surg.* 2007;**23**(3):187-91.
3. Kim JS, Lee DH, Suh HJ. Double-J stenting: initial management of injured ureters recognized late after gynecological surgery. *Int Urogynecol J.* 2010;**21**(6):699-703. doi: [10.1007/s00192-009-1092-6](https://doi.org/10.1007/s00192-009-1092-6). [PubMed: [20119690](https://pubmed.ncbi.nlm.nih.gov/20119690/)].
4. Singh I. Review Article-Indwelling JJ ureteral stents-A current perspective and review of literature. *Indian J Surgery.* 2003;**65**:405-12.
5. Falahatkar S, Hemmati H, Gholamjani Moghaddam K. Intracaval migration: an uncommon complication of ureteral Double-J stent placement. *J Endourol.* 2012;**26**(2):119-21. doi: [10.1089/end.2011.0469](https://doi.org/10.1089/end.2011.0469). [PubMed: [22192115](https://pubmed.ncbi.nlm.nih.gov/22192115/)].
6. Sabnis RB, Ganpule AP, Ganpule SA. Migration of double J stent into the inferior vena cava and the right atrium. *Indian J Urol.* 2013;**29**(4):353-4. doi: [10.4103/0970-1591.120125](https://doi.org/10.4103/0970-1591.120125). [PubMed: [24235801](https://pubmed.ncbi.nlm.nih.gov/24235801/)].
7. Michalopoulos AS, Tzoufi MJ, Theodorakis G, Mentzelopoulos SD. Acute postoperative pulmonary thromboembolism as a result of intravascular migration of a pigtail ureteral stent. *Anesth Analg.* 2002;**95**(5):1185-8. [PubMed: [12401589](https://pubmed.ncbi.nlm.nih.gov/12401589/)] table of contents.
8. Hastaoglu IO, Tokoz H, Kavlak E, Bilgen F. Double J ureteral stent displaced through the right ventricle. *Interact Cardiovasc Thorac Surg.* 2014;**18**(6):853-4. doi: [10.1093/icvts/ivu037](https://doi.org/10.1093/icvts/ivu037). [PubMed: [24632423](https://pubmed.ncbi.nlm.nih.gov/24632423/)].
9. Jayakumar S, Marjan M, Wong K, Bolia A, Ninan GK. Retrieval of proximally migrated double J ureteric stents in children using goose neck snare. *J Indian Assoc Pediatr Surg.* 2012;**17**(1):6-8. doi: [10.4103/0971-9261.91078](https://doi.org/10.4103/0971-9261.91078). [PubMed: [22279356](https://pubmed.ncbi.nlm.nih.gov/22279356/)].
10. Dyer RB, Chen MY, Zagoria RJ, Regan JD, Hood CG, Kavanagh PV. Complications of ureteral stent placement. *Radiographics.* 2002;**22**(5):1005-22. doi: [10.1148/radiographics.22.5.g02se081005](https://doi.org/10.1148/radiographics.22.5.g02se081005). [PubMed: [12235330](https://pubmed.ncbi.nlm.nih.gov/12235330/)].