

## REVIEW ARTICLE

## Pathophysiology of merkel cell

**Prashant Balasaheb Munde, Shubhangi P Khandekar, Alka M Dive, Aparna Sharma**

Departments of Oral and Maxillofacial Pathology, Vidya Shikshan Prasarak Mandal's Dental college and Research Centre, Nagpur, Maharashtra, India

**Address for correspondence:**

Dr. Prashant Balasaheb Munde,  
Departments of Oral and Maxillofacial  
Pathology, Vidya Shikshan Prasarak Mandal's  
Dental College and Research Centre, Nagpur,  
Maharashtra - 440 019, India.  
E-mail: pinkclimate@gmail.com

**ABSTRACT**

The objective of this review is to introduce Merkel cells (MCs), to provide a basic overview on the theoretical background of function, development and clinical importance of MCs. The origin of human MCs have been controversial. Some investigators believe that it is a neural crest derivate, whereas others have proposed that it is a differentiation product of the fetal epidermal keratinocytes. MCs are cells primarily localized in the epidermal basal layer of vertebrates and concentrated in touch-sensitive areas in glabrous, hairy skin and in some mucosa. In routine light microscopy, human MCs can hardly be identified. Cytokeratin 20 (CK20) is a reliable marker with highest degree of specificity. MCs can be also distinguished by electron microscopy. MC carcinoma (MCC) is an uncommon and often aggressive malignancy and found mainly in elderly patients. It occurs most frequently in the head and neck region. Diagnosis is based on typical histological presentation on hematoxylin and eosin (H and E) stained slides together with the results of immunohistochemistry. Histologically, MCC has been classified into three distinct subtypes: Trabecular, intermediate and small cell type.

**Key words:** Cytokeratin 20, merkel cells, merkel cell carcinoma

### INTRODUCTION

In 1875 Friedrich Sigmund Merkel, using a light microscope, discovered a peculiar cell type Merkel cell (MC) in the base of rete pegs of the epidermis of pig snout skin and called them 'Tastzellen' (touch cells). With the introduction of electron microscopy in the 1960s, numerous electron microscopic studies have been carried out and the ultrastructure and distribution of MCs have been extensively elucidated. The development and the functions of the MC are still enigmatic. As to its development, two ideas, that is, the neural crest origin hypothesis and the epidermal origin hypothesis have been postulated. Also, various possible functions have been proposed for the MCs. In 1972, a highly malignant type of skin cancer with cells resembling MCs was first described by Cyril Toker and called MC carcinoma (MCC). Thus this article covers the areas of origin, distribution, ultrastructure, staining, possible functions of MCs and MCC. It provides the current state of knowledge and thoughts for future investigations in these areas.<sup>[1]</sup>

### ORIGIN

There are two prevailing hypotheses concerning the developmental origin of MCs: (1) the neural crest origin hypothesis and (2) the epidermal origin hypothesis (Tachibana, 1995). Tweedle (1978) found MCs in the amphibian epidermis that had developed from embryos from which neural precursor tissues had been removed at early developmental stages. Moll *et al.*, (1990) also showed that MCs developed in human epidermis xenografted on the dermis of nude mice that had been deprived of nerve elements.<sup>[1-3]</sup> These findings seem to support the epidermal origin hypothesis. However, Halata *et al.*, (1990) and Grim and Halata (2000) have speculated, on the basis of results of their avian chimeric experiments, that MCs share their origin with neural elements.<sup>[4]</sup> Although the origin of MCs remains unclear, it seems likely that MCs are differentiated from stem cells in the epidermis, because differentiated MCs probably have no mitotic ability (Moll *et al.*, 1996; Tachibana *et al.*, 2000).<sup>[5]</sup> The neural crest theory is primarily based upon the observation that in the fetal dermis MCs are associated with unmyelinated small nerves and in some instances nerve-associated MCs were observed crossing the basal lamina.<sup>[6]</sup> The origin of MCs have been debated for over 20 years. Evidence from skin graft experiments in birds implies that they are neural crest derived, but experiments in mammals now demonstrate an epidermal origin.<sup>[7]</sup>

**Access this article online**

**Quick Response Code:**



**Website:**

www.jomfp.in

**DOI:**

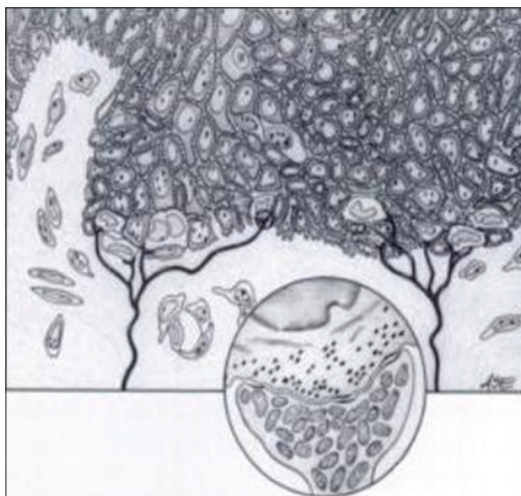
10.4103/0973-029X.125208

## DISTRIBUTION

MCs are found in the skin and some parts of the mucosa of all vertebrates. In mammalian skin, they are clear cells found in the stratum basale of the epidermis approximately 10  $\mu\text{m}$  in diameter.<sup>[3]</sup> It has nerve tissue immediately subjacent and is presumed to be a specialized neural pressure sensitive receptor cell [Figure 1]. They are commonly seen in masticatory mucosa, but are usually absent in lining mucosa. MCs differ from other non-keratinocytes in that they are not dendritic.<sup>[4]</sup> MCs are concentrated in eccrine glandular ridges of glabrous skin and in Haarscheiben of hairy skin, within belt-like clusters of hair follicles and in certain mucosal tissues.<sup>[8]</sup> There is a great site variation in the density of MCs. The palmar aspect of hands, the feet and plantar aspects of the toes, has a far higher density than any other part of the body.<sup>[9]</sup> MCs are found in high numbers in the lip, anterior hard palate and gingiva.<sup>[10]</sup> The regions richer in MCs are involved in tactile perception, emphasizing the presumed sensory receptor function of MCs. MCs are more numerous in the sun-exposed skin than in covered skin.<sup>[11]</sup>

## STAINING

Using routine light microscopy of hematoxylin and eosin (H and E) stained human skin the MCs can be hardly identified. MCs can be distinguished from other cells of epidermis by electron microscopy. The dense-core granules stain positively for the neuroendocrine markers chromogranin A, neuron-specific enolase and synaptophysin; these markers may be useful as diagnostic adjuncts. Vasoactive intestinal polypeptide, serotonin and substance P show variable positivity. At the light microscopic level, anti-cytokeratin 20 (anti-CK20) provides the highest degree of specificity.<sup>[10]</sup> Other methods of their identification with light microscopy are based on incorporation of fluorescent dyes into the MCs. Live



**Figure 1:** Merkel's cell located in the region of the stratum basale, associated with nerve axon (lower arrow). (Courtesy: James K Avery; Nancy Avery; Pauline F Steele, editors. Oral Development and Histology. New York: Stuttgart: Thieme Medical Publishers, 2002)

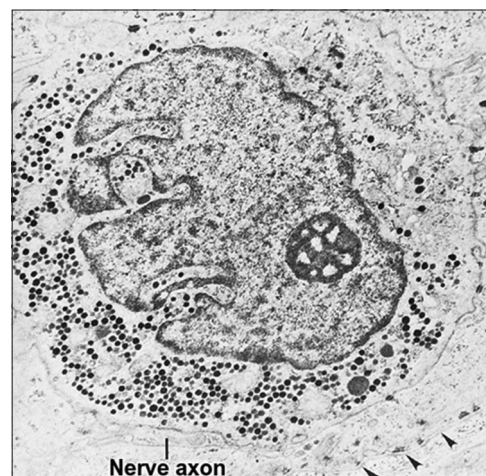
MCs are known to incorporate quinacrine,<sup>[11]</sup> which fluoresces a light under ultraviolet (UV) illumination.<sup>[12]</sup>

By electron microscopy, the uranaffin reaction has been applied to identify mammalian intraepithelial MCs. Uranaffin reaction was introduced as an ultrastructural stain for the localization of adenine nucleotide in organelles storing biogenic amines.<sup>[13]</sup>

## ULTRASTRUCTURE

The surface of MCs appears to be attached to the basement membrane separating the epidermis from the dermis and hemidesmosomes can be observed with neurites located just below the basal lamina. MCs shows lobulations or spine-like protrusions sometimes called microvilli. These structures (up to 50 in MCs) may measure up to 2.5  $\mu\text{m}$  in length (Moll *et al.*, 2005).<sup>[8]</sup> The spine-like protrusions of highly variable length attached to the neighboring keratinocytes by relatively few, small desmosomes located on the cell body and occasionally on the dendritic processes. The ultrastructural characteristics of MCs are the dense-core secretory granules that are accumulated near the nerve fiber junction [Figure 2]. These granules have an electron-dense core, surrounded by a clear halo and a simple membrane. MCs' granules measures about 80-120 nm (Winkelmann and Breathnach, 1973) or 100-140 nm in diameter.<sup>[11]</sup> The cytoplasm has low microscopic density and contains loosely arranged intermediate filament cytoskeleton.<sup>[14]</sup>

The MC possesses a characteristic intranuclear rodlet and is usually associated with all types of known organizations of sensory nerve endings in the skin and possesses characteristic enzyme reactions in relation to the nerve endings.<sup>[15]</sup> Some of the MCs make contact with nerve terminals to form MC-neurite complexes.<sup>[16]</sup> The chemical synaptic contact at the



**Figure 2:** Electron micrograph of Merkel cell in the basal layer of oral epithelium. The cytoplasm of this cell is filled with small, dense vesicles situated close to an adjacent unmyelinated nerve axon. Arrowheads point to the site of the basal lamina. (Courtesy: Antonio Nanci Tencate's Oral histology- Development, Structure and function, 7 th ed. St. Louis: Missouri Mosby an imprint of Elsevier; 2008)

presynaptic membrane in the MC-axon-complexes emphasizes the receptor function of the MC.<sup>[17]</sup> Intermediate-type junctions have been observed between terminal axons and MCs (Watanabe, 2004).<sup>[18]</sup> It should be noted that a number of MCs are not associated with the nerve axon. Finally, MCs are attached to neighboring keratinocytes by a few small desmosomes and contain melanosomes similar to keratinocytes. The melanosomes are not produced in the MC, but are taken from the melanocytes like in keratinocytes.<sup>[19]</sup>

## POSSIBLE FUNCTIONS

Various possible functions have been proposed for the MC. Because of its intimate anatomical relationship with the sensory nerve; their involvements in mechanical transduction; secretory function of the cell; various kinds of neuropeptides and neuron-specific proteins have been localized in the MC. In addition; recent immunohistochemical (IHC) studies suggest that the MCs may have trophic or inductive functions in the development of peripheral nerves and epidermal anlagen.<sup>[1]</sup>

### Somatosensation

MCs complex with somatosensory afferents to form slowly adapting touch receptors; it is unclear, however, whether mechanosensory transduction occurs in the MCs, the somatosensory afferent or both. A classic anatomical result suggests that MCs are sensory cells that transduce mechanical stimuli and then communicate with sensory afferents via neurotransmission. These findings support the hypothesis that MCs are sensory receptor cells; a definitive demonstration that MCs are necessary and sufficient to transduce touch awaits future studies.<sup>[7]</sup>

### Endocrine function

The MCs have been considered to be a member of the amine precursor uptake and decarboxylation (APUD) system. This system is defined as a series of cells that have endocrine functions since they secrete a variety of small amine or polypeptide hormones. They store the hormones in cytoplasmic small dense-core membrane-bound granules that are visible by electron microscopy. It was hypothesized that the morphology of the dense-core granules was similar to the secretory granules of endocrine cells (Hartschuh and Grube, 1979).<sup>[9]</sup>

### Chemosensation

MCs may have a possible chemosensitive function, in particular nociceptive function, which are mediated by free nerve endings. However, no specialized sensory cells have been identified to underlie the sensations of irritation. Pain is also transmitted by free nerve endings in human glabrous and hairy skin (Reznik, 1996). Substance P and calcitonin gene-related peptide (CGRP) released from rat and monkey MCs-neurite complexes are consistent with a response to

physical or chemical irritation (Tachibana *et al.*, 2001). They are well-known to be the main active mediators for transferring nociceptive information.<sup>[11]</sup>

### Merkel cell carcinoma

MCC is an uncommon and often aggressive malignancy that has a poor prognosis. MCC is rarely suspected clinically at the time of presentation. It most commonly presents as a blue or red, firm, solitary, nontender, dome-shaped nodule and may have a plaque-like appearance or a subcutaneous mass without epidermal changes. Although the overlying skin may be ulcerated, it is frequently intact. The clinical differential diagnosis may include basal cell carcinoma, cyst, squamous cell carcinoma (SCC), pyogenic granuloma, melanoma, lymphoma cutis or lipoma. Diagnosis is based on typical histology representation on H and E stained slides together with the results of immunohistochemistry. Histologically, the tumor commonly involves the full thickness of the dermis and frequently extends into the subcutaneous fat and adjacent skeletal muscle.<sup>[20]</sup>

It was first described as a trabecular cancer of the dermis with high lymphatic metastatic risk and was found mainly in elderly patients. Most reported cases have occurred in white subjects. The mortality rate is approximately 25%. It occurs most frequently in the head and neck region, on the extremities and has a predilection for the periocular region.<sup>[21-23]</sup>

These potentially lethal tumors are composed of small, round malignant cells containing neurosecretory type cytoplasmic granules. Pathologists must be aware of this rare primary skin tumor since it may closely resemble metastatic small cell carcinoma from lung or certain lymphomas that spread to the dermis.<sup>[24]</sup> MCC often has typical histopathologic and IHC features. MCC tends to show classic histological features of a neuroendocrine carcinoma and is often positive for CK20. This previously unrecognized paranuclear dot-like expression of CD99 may be of use in differentiating MCC from other cutaneous malignancies, especially when CK20 expression is limited or absent. Sometimes the diagnosis is missed because of atypical histological or aberrant IHC findings. Review of the literature shows other examples of MCC with basal cell carcinoma-like features. Various other histopathologic differentiations of MCC include those that demonstrate squamous cell and eccrine carcinoma features and those that show melanocytic, lymphomatous, sarcomatous, muscular and atypical fibroxanthoma-like features.<sup>[25]</sup>

MCC in most cases, is caused by a virus MC polyomavirus (MCV) discovered by scientists at the University of Pittsburgh in 2008.<sup>[26]</sup> It is also known as primary neuroendocrine carcinoma of the skin, primary small cell carcinoma of the skin and trabecular carcinoma of the skin.<sup>[27]</sup> Approximately 80% of MCC are caused by MCV. The virus is clonally integrated into the cancer cells. In

addition, the virus has a particular mutation only when found in cancer cells, but not when it is detected in healthy skin cells. On the other hand, many studies have also indicated that approximately 20% of MCC are not likely to be associated with the virus. Tumors with and without the virus have been shown to be significantly different in prognosis, oncogene expression and histologic appearance; suggesting that they have different etiologies.<sup>[28]</sup>

Histologically, MCC has been classified into three distinct subtypes [Figure 3].<sup>[29-31]</sup>

#### Trabecular type

Cells are arranged in distinctly dense clusters and trabeculae with occasional ribbons, individual cells are round to polygonal in shape and are compactly arranged, the tumor cell cytoplasm is comparatively abundant and often well-defined, mitosis are few to moderate in number, this type of tumor is usually found adjacent to skin adnexal structures, particularly hair follicles and it is the least frequent histological pattern identified.<sup>[29]</sup>

#### Intermediate type

Shows a solid and diffuse growth pattern, cells are less compactly arranged and the cytoplasm is less abundant than in the trabecular type, mitoses and focal areas of necrosis are frequently seen, these tumors also arise adjacent to adnexa, but may invade the epidermis, this is the most frequent histological subtype identified, tumors of this type may behave in a clinically more aggressive manner than those of the trabecular type.<sup>[30]</sup>

#### Small cell type

Closely mimics small cell tumors of other sites, the tumors arise in the dermis and appear as solid sheets and clusters of cells, areas of necrosis and “crushing” artifact are frequently seen, the clinical behavior of this subtype appears to be as aggressive as that of the intermediate subtype.<sup>[31]</sup>

MCC tends to show classic histological features of a neuroendocrine carcinoma and is often positive for CK20, but non-classic cytological findings and unusual immunophenotypes may be observed and can lead to a diagnostic confusion. MCC needs to be distinguished from other primary cutaneous tumors with a small cell appearance and metastatic tumors. Wide surgical excision is the primary

mode of treatment for non-metastatic disease and sentinel lymph node biopsy may aid in the staging. Adjuvant radiation therapy at 45-50 Gy to the primary site and involved lymph nodes can prevent local recurrences and may improve survival. Chemotherapy, based on regimens for small-cell lung cancer, leads to tumor regression in up to 70% of cases with metastatic disease, but has no established role in the adjuvant setting.<sup>[32]</sup>

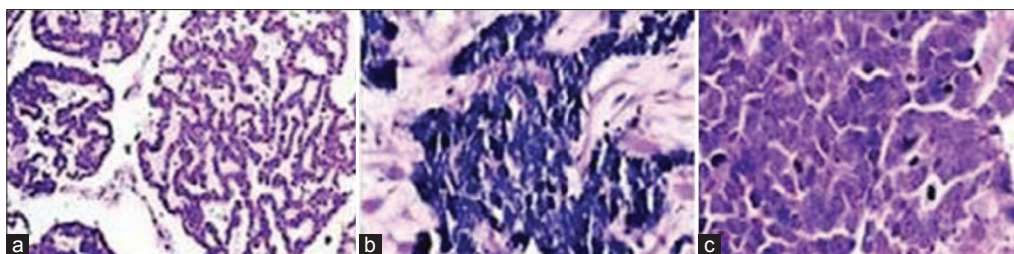
The discovery of the MCV by Feng *et al.*, and the subsequent work of Touze *et al.*, which showed high antibody titers against the Merkel cell Polyoma Virus (anti-MCPyV) correlating to improved survival have provided us with new data with which the disease can be targeted. Work in viral detection and protein expression continues to further elucidate the role of the virus in the genesis of MCC. The development of viral vaccines and targeted agents for the treatment of MCC is ongoing.<sup>[33]</sup>

## CONCLUSION

Although the MCs have been described as early as in 1875, their nature as neuroendocrine cells became only evident 100 years later by electron microscopy. MCs are located in the basal layer of the epidermis and characterized by dense-core granules. Nowadays most studies focus on suggested neuroendocrine functions of MCs and their possible malignant transformation into MCC. Patients with MCC are at high risk for multiple malignancies and should be closely examined at the time of diagnosis for other possible tumors. Compared to other non-melanoma skin cancers, MCC is aggressive and frequently deadly. Yet the dissemination of information about this tumor remains inadequate even among specialists.

Management of MCC is challenging, as therapy is different in nature than for other skin malignancies and is controversial within the literature. Pathologists must be aware of this rare primary skin tumor since nonspecific characteristics of MCC lead to a lengthy differential diagnosis that includes basal cell carcinoma, SCC, keratoacanthoma, amelanotic melanoma, epidermal cysts, lymphoma and metastatic carcinoma of the skin.

The number of studies focusing on the development of new targeted anticancer therapy is steadily rising, and thus there is hope that new drug regimes for patients with distant and systemic MCC disease will be available in the near future. In



**Figure 3:** The histologic variants of Merkel cell carcinoma are shown: (a) Trabecular type (H&E stain, ×100), (b) Intermediate type (H&E stain, ×400) and Small cell type (H&E stain, ×400). (Courtesy: Goessling W, McKee PH, Mayer RJ. Merkel cell carcinoma. *J Clin Oncol* 2002;20:588)

particular, many study groups are looking for new strategies to target the MCV either to prevent infection or to inhibit viral-induced carcinogenesis.

## REFERENCES

- Tachibana T. The Merkel cell: Recent findings and unresolved problems. *Arch Histol Cytol* 1995;58:379-96.
- Tweedle CD. Ultrastructure of Merkel cell development in aneurogenic and control amphibian larvae (ambystoma). *Neuroscience* 1978;3:481-6.
- Moll I, Lane AT, Franke WW, Moll R. Intra epidermal formation of Merkel cell in xenografts of human foetal skin. *J Invest Dermatol* 1990;94:359-64.
- Grim M, Halata Z. Developmental origin of avian Merkel cell. *Anat Embryol (Berl)* 2000;202:401-10.
- Halata Z, Grim M, Christ B. Origin of spinal cord meninges sheaths of peripheral nerves, and cutaneous receptors including Merkel cell. An experimental and ultrastructural study with avian chimeras. *Anat Embryol (Berl)* 1990;182:529-37.
- Gollard R, Weber R, Kosty MP, Greenway HT, Massullo V, Humberson C. Merkel cell carcinoma: Review of 22 cases with surgical, pathologic, and therapeutic considerations. *Cancer* 2000;88:1842-51.
- Halata Z, Gim M, Baumann KI. Friedrich sigmund Merkel and his "Merkel cell", morphology, development and physiology: Review and new results. *Anat Rec A Discov Mol Cell Evol Biol* 2003;271:225-39.
- Moll I, Roessler M, Brandner JM, Eispert AC, Houdek P, Moll R. Human Merkel cells—aspects of cell biology, distribution and functions. *Eur J Cell Biol* 2005;84:259-71.
- Hartschuh W, Grube D. The Merkel cell: A member of the APUD cell system. Fluorescence and electron microscopic contribution to the neurotransmitter function of the Merkel cell granules. *Arch Dermatol Res* 1979;265:115-22.
- Boot PM, Rowden G, Walsh N. The distribution of Merkel cells in human fetal and adult skin. *Am J Dermatopathol* 1992;14:391-6.
- Lucarz A, Brand G. Current considerations about Merkel cell. *Eur J Cell Biol* 2007;86:243-51.
- Yiengpruksawan A, Coit DG, Thaler HT, Urmacher C, Knapper WK. Merkel cell carcinoma: Prognosis and management. *Arch Surg* 1991;126:1514-9.
- Goepfert H, Remmler D, Silva E, Wheeler B. Merkel cell carcinoma (endocrine carcinoma of the skin) of the head and neck. *Arch Otolaryngol* 1984;110:707-12.
- Polakovicova S, Seidenberg H, Mikusova R, Polak S, Pospisilova V. Merkel cells--review on developmental, functional and clinical aspects. *Bratisl Lek Listy* 2011;112:80-7.
- Winkelman RK. The Merkel cell system and a comparison between it and the neurosecretory or APUD cell system. *J Invest Dermatol* 1977;69:41-6.
- Winkelman RK, Breathnach AS. The Merkel cell. *J Invest Dermatol* 1973;60:2-15.
- Hartschuh W, Weihe E. Fine structural analysis of the synaptic junction of Merkel cell-axon-complexes. *J Invest Dermatol* 1980;75:159-5.
- Watanabe IS. Ultrastructures of mechanoreceptors in the oral mucosa. *Anat Sci Int* 2004;79:55-61.
- Toyoshima K, Seta Y, Nakashima T, Shimamura A. Occurrence of melanosome-containing Merkel cell in mammalian oral mucosa. *Acta Anat (Basel)* 1993;147:145-8.
- Goessling W, McKee PH, Mayer RJ. Merkel cell carcinoma. *J Clin Oncol* 2002;20:588-98.
- Scott MP, Helm OF. Cytokeratin 20: A marker for diagnosing Merkel cell carcinoma. *Am J Dermatopathol* 1999;21:16-20.
- Linjawi A, Jamison WB, Meterissian S. Merkel cell carcinoma: Important aspects of diagnosis and management. *Am Surg* 2001;67:943-7.
- Hill AD, Brady MS, Coit DG. Intraoperative lymphatic mapping and sentinel lymph node biopsy for Merkel cell carcinoma. *Br J Surg* 1999;86:518-1.
- Al-Ghazal SK, Arora DS, Simpson RH, Saxby P. Merkel cell carcinoma of the skin. *Br J Plast Surg* 1996;49:491-6.
- Succaria F, Radfar A, Bhawan J. Merkel Cell Carcinoma (Primary Neuroendocrine Carcinoma of Skin) Mimicking Basal Cell Carcinoma With Review of Different Histopathologic Features. *Am J Dermatopathol* 2013.
- Feng H, Shuda M, Chang Y, Moore PS. Clonal Integration of a polyomavirus in human merkel cell carcinoma. *Science* 2008;319:1096-100.
- Hitchcock CL, Bland KI, Laney RG. Neuroendocrine (Merkel cell) carcinoma of the skin. Its natural history, diagnosis, and treatment. *Ann Surg* 1988;207:201.
- Shuda M, Feng H, Kwun HJ, Rosen ST, Gjoerup O, Moore PS, et al. T antigen mutations are a human tumor-specific signature for Merkel cell polyomavirus. *Proc Natl Acad Sci U S A* 2008;105:16272-7.
- Toker C. Trabecular carcinoma of the skin. *Arch Dermatol* 1972;105:107-10.
- Ratner D, Nelson BR, Brown MD, Johnson TM. Merkel cell carcinoma. *J Am Acad Dermatol* 1993;29:143-56.
- Gould VE, Moll R, Moll I, Lee I, Franke WW. Neuroendocrine (Merkel) cells of the skin: Hyperplasias, dysplasias, and neoplasms. *Lab Invest* 1985;52:334-53.
- Pulitzer MP, Amin BD, Busam KJ. Merkel cell carcinoma: Review. *Adv Anat Pathol* 2009;16:135-44.
- Miles BA. Merkel Cell Carcinoma of the Head and Neck: Challenges in Diagnosis and Therapy. *J Skin Cancer*. 2013;2013: 1. Article ID 427984 Available from: <http://www.hindawi.com/journals/jsc/2013/427984/> [Last accessed on 2013 Jun 26].

**How to cite this article:** Munde PB, Khandekar SP, Dive AA, Sharma A. Pathophysiology of merkel cell. *J Oral Maxillofac Pathol* 2013;17:408-12.

**Source of Support:** Nil. **Conflict of Interest:** None declared.