

Successful optical coherence tomography-guided treatment in a 19-year-old patient with ST-segment elevation myocardial infarction caused by plaque erosion

Journal of International Medical Research
49(8) 1–6

© The Author(s) 2021

Article reuse guidelines:

sagepub.com/journals-permissions

DOI: 10.1177/03000605211039794

journals.sagepub.com/home/imr



Xuelian Song , Fan Wang , Feifei Zhang ,
Xiaoyong Qi and Yi Dang

Abstract

ST-segment elevation myocardial infarction is a type of coronary atherosclerotic heart disease, and its pathophysiological mechanism is formation of lipid plaques. We report a 19-year-old patient with ST-segment elevation myocardial infarction caused by plaque erosion, but he did not have any common traditional risk factors of lipid plaques. His treatment was guided by optical coherence tomography. He received successful treatment and had a good prognosis. Optical coherence tomography can be used to help understand the pathogenesis of myocardial infarction and visualize the real lumen.

Keywords

ST-segment elevation myocardial infarction, optical coherence tomography, plaque erosion, thrombus, coronary angiography, lipid

Date received: 19 April 2021; accepted: 26 July 2021

Introduction

Coronary thrombosis is the main cause of acute coronary syndrome. Aspiration thrombectomy in a timely manner is necessary in selected patients for reperfusion, although routine aspiration is

Department of Cardiovascular Disease Center, Hebei General Hospital, Shijiazhuang, Hebei, China

Corresponding author:

Yi Dang, Department of Cardiovascular Disease Center, Hebei General Hospital, No. 348 Heping West Road, Shijiazhuang, Hebei Province 050051, China.
Email: dangyimail@126.com



Creative Commons Non Commercial CC BY-NC: This article is distributed under the terms of the Creative Commons Attribution-NonCommercial 4.0 License (<https://creativecommons.org/licenses/by-nc/4.0/>) which permits non-commercial use, reproduction and distribution of the work without further permission provided the original work is attributed as specified on the SAGE and Open Access pages (<https://us.sagepub.com/en-us/nam/open-access-at-sage>).

recommended as class III in the recent guidelines.¹ Plaque rupture is the most frequent cause of coronary thrombus and plaque erosion is the second most frequent cause. Intravascular imaging, especially optical coherence tomography (OCT), can be helpful for understanding the pathogenesis and providing clinical decision support after a thrombus is removed. We report here a case of a 19-year-old patient with ST-segment elevation myocardial infarction (STEMI) caused by plaque erosion who did not have any common traditional risk factors. Successful treatment of this patient was guided by OCT.

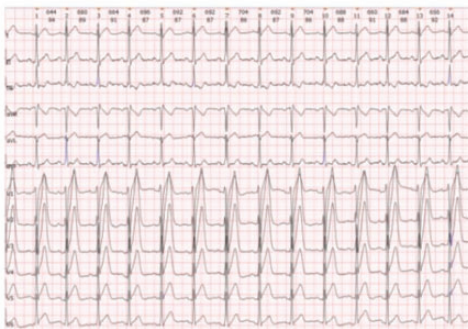Case report

A 19-year-old man was admitted to the emergency room with persistent substernal chest pain for 3 hours after staying up late for 1 week. He had been in good health without hypertension, hyperlipemia, or other related diseases.

An electrocardiogram showed a normal sinus rhythm with ST-segment elevation and towering T waves in the V1 to V6 leads (Figure 1a) and the cardiac troponin

level was 0.248 ng/L (upper limit of normal: 0.1 ng/L). His left ventricular ejection fraction was 55% and glycated hemoglobin level was 5.0%. The patient's lipid levels were as follows: total cholesterol, 3.67 mmol/L; total triglycerides, 1.53 mmol/L; high-density lipoprotein cholesterol, 0.91 mmol/L; and low-density lipoprotein cholesterol, 2.42 mmol/L. He was diagnosed with acute anterior myocardial infarction. His vital signs on presentation were stable with a pulse of 88 beats/minute, blood pressure of 145/85 mmHg, respiratory rate of 18 breaths/minute, arterial blood oxygen saturation of 99% on room air, and temperature of 36.2°C. The current evidence did not support the diagnosis of aortic dissection, acute pericarditis, acute pulmonary embolism, pneumothorax, or digestive tract diseases. Therefore, we carried out follow-up treatment after obtaining the patient's consent. After he received aspirin 300 mg, ticagrelor 180 mg, and a bolus of 3000 units of intravenous heparin, he underwent emergency coronary angiography (CAG). CAG showed thrombosis in the proximal left anterior descending artery (pLAD), and Thrombolysis in

(a)



(b)

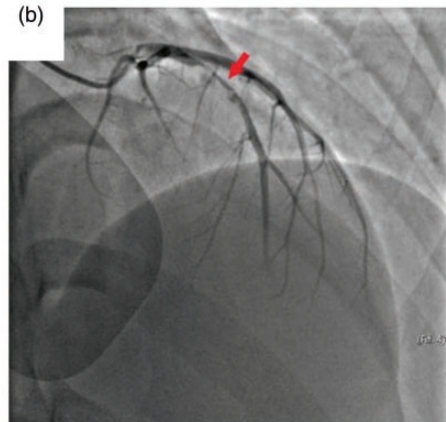


Figure 1. (a) Electrocardiogram before primary percutaneous coronary intervention. (b) Initial angiography shows a large thrombus in the proximal left anterior descending coronary artery with Thrombolysis in Myocardial Infarction grade I distal flow

Myocardial Infarction (TIMI) thrombus grade 4 and TIMI grade 1 distal flow (Figure 1b), but a normal circumflex artery and right coronary artery. A bolus of heparin (3500 IU) and a glycoprotein IIb/IIIa antagonist (tirofiban) was administered, and a 6F BL3.5 guide catheter (Terumo, Tokyo, Japan) was inserted, followed by repeated manual thrombus aspiration. Subsequent CAG showed TIMI grade 3 flow (Figure 2). After taking into consideration the patient's age, intracoronary OCT was performed to assess whether more interventions were essential. OCT showed a residual red and white thrombus and plaque erosion in the pLAD. The minimal lumen diameter of the pLAD was 1.92 mm, the area was 2.95 mm², and the area of stenosis was 48% (Figure 2a–d). Accordingly, stent implantation was avoided for the patient. He was discharged with optimal medical therapy, which comprised aspirin, ticagrelor, metoprolol, and a statin, for 12 months as recommended by guidelines for prevention of secondary coronary events. CAG and OCT 1 month after

primary percutaneous coronary intervention showed that an organized thrombus remained in the pLAD and that a lipid plaque was under the endomembrane with an unbroken fibrous cap and no plaque rupture (Figure 3). Cholesterol crystals and microphage infiltration were detected. The patient has remained asymptomatic and no adverse events were observed during 6 months of follow-up.

Discussion

Coronary thrombosis can cause acute coronary syndrome. Over the last few decades, most physicians have believed that coronary thrombosis results from rupture of a vulnerable plaque, which is characterized by a thin fibrous cap overlying a large necrotic core and massive inflammatory cell infiltration.² However, a major portion of thrombotic lesions are associated with plaque erosion. Previous studies have shown that plaque rupture is the most common substrate for coronary occlusive thrombosis in nearly 60% of patients with

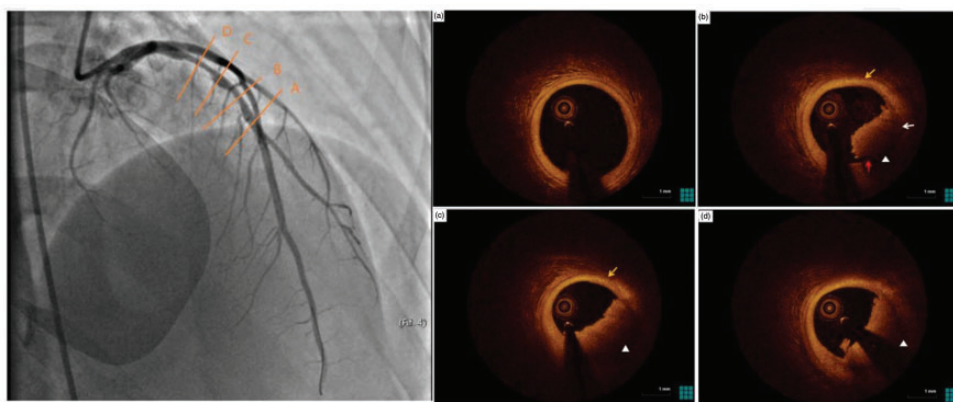


Figure 2. Coronary angiography shows mild obstructive lesions remaining in the proximal left anterior descending coronary artery and improvement of Thrombolysis in Myocardial Infarction flow after thrombus aspiration. (a–d) Representative cross-sectional optical coherence tomography images of the proximal left anterior descending coronary artery. The yellow arrow indicates a cholesterol crystal, the white arrow indicates a white thrombus, the red arrow indicates a red thrombus, and the white triangle indicates plaque erosion with a mixed thrombus

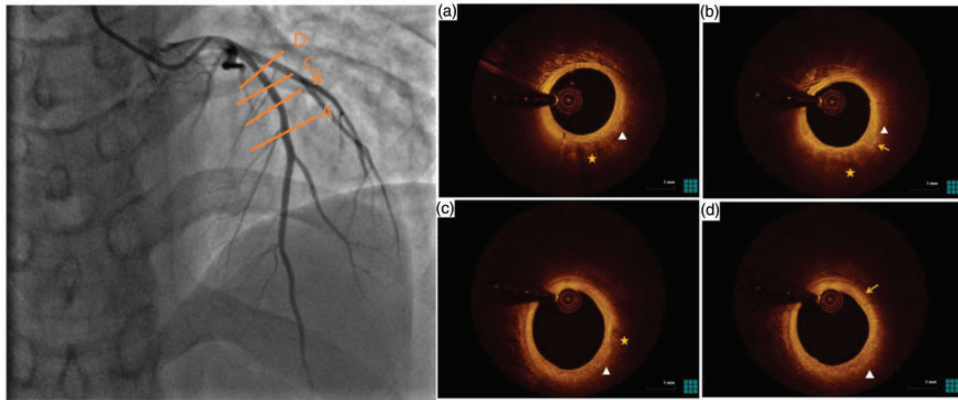


Figure 3. Coronary artery angiography shows no obstructive lesions in the left anterior descending coronary artery at 1 month of follow-up. (a–d) Representative cross-sectional optical coherence tomography images of the proximal left anterior descending coronary artery. The yellow arrow indicates a cholesterol crystal, the white triangle indicates a lipid plaque with a $>180^\circ$ arc, and the yellow star indicates macrophage infiltration

acute coronary syndrome.³ Additionally, plaque erosion is responsible for coronary thrombosis in 22% to 44% of patients.⁴ OCT, which is an intravascular imaging modality with extremely high resolution, is useful for understanding the pathogenesis and enabling visualization of the real lumen. Erosion shown by OCT is defined and categorized according to the absence of fibrous cap disruption and the presence of thrombus, and is divided into definite OCT-defined erosion and probable OCT-defined erosion.⁵ Plaque erosion is a distinct entity that is primarily caused by endothelial erosion and plaque rupture is caused by inflammation.⁶ The mechanisms underlying plaque erosion are currently poorly defined, but appear to be related to apoptosis of endothelial cells and loss of endothelial contact with the underlying extracellular matrix. This process is promoted by several triggers, such as coronary spasm. In pathological evaluation of sudden death cases, plaque erosion is associated with more late-stage thrombus (versus early stage, <1 -day-old thrombus for plaque rupture) and more frequent

distal embolization than plaque rupture.⁷ In our patient, OCT showed a luminal thrombus overlying an intact and visualized plaque. This finding was highly suggestive of a definite OCT-defined erosion.

Plaque erosion is likely to involve young patients, especially premenopausal women, it has the major risk factor of smoking and stenosis is not severe, and is typically encountered with non-STEMI.^{8,9} In a previous study, anti-thrombotic therapy without stent implantation effectively reduced the thrombus volume and enlarged the flow area without re-occlusion of the culprit lesion at 1 month in predominantly young Chinese men.¹⁰ The majority (92.5%) of patients remained free of major adverse cardiovascular events for ≤ 1 year.¹⁰ Our patient had been in good health, without hypertension, hyperlipemia, or other related diseases, and had no history of smoking or drinking. He was not overweight and had no family history of related disease. The only possible risk factor is that he stayed up late to play video games for 1 week. We speculate that continuous sympathetic excitement may have caused the

coronary artery spasm. The combined effect of this sympathetic response and the presence of an atherosclerotic plaque may have promoted the formation of the thrombus. With the assistance of OCT, our patient with STEMI caused by plaque erosion avoided stent implantation and a range of possible complications, such as no/slow reflow phenomenon, stent thrombosis, stent restenosis, and others.¹¹ However, this patient had large lipid erosion with a >180° arc, which indicated that the lipid plaque had affected more than half of the lumen perimeter. Therefore, he needed a low-fat diet to maintain a normal blood lipid level, to develop regular living habits, and to stop staying up late to prevent further plaque progression.

The reporting of this study conforms to the CARE guidelines.¹²

Ethics statement

No ethical approval was required. The authors obtained written informed consent for publication of this case report from the patient.

Declaration of conflicting interest


The authors declare that there is no conflict of interest.

Funding

This research received no specific grant from any funding agency in the public, commercial, or not-for-profit sectors.

ORCID iDs

Xuelian Song  <https://orcid.org/0000-0001-9784-0572>

Fan Wang  <https://orcid.org/0000-0001-6856-875X>

Feifei Zhang  <https://orcid.org/0000-0003-0750-4263>

References

1. Ibanez B, James S, Agewall S, et al. 2017 ESC Guidelines for the management of acute myocardial infarction in patients

- presenting with ST-segment elevation: The Task Force for the management of acute myocardial infarction in patients presenting with ST-segment elevation of the European Society of Cardiology (ESC). *Eur Heart J* 2018; 39: 119–177.
2. Jia H, Kubo T, Akasaka T, et al. Optical Coherence Tomography Guidance in Management of Acute Coronary Syndrome Caused by Plaque Erosion. *Circ J* 2018; 2: 302–308.
3. Falk E, Nakano M, Bentzon JF, et al. Update on acute coronary syndromes: The pathologists' view. *Eur Heart J* 2013; 34: 719–728.
4. White SJ, Newby AC and Johnson TW. Endothelial erosion of plaques as a substrate for coronary thrombosis. *Thromb Haemost* 2016; 115: 509–519.
5. Jia H, Abtahian F, Aguirre AD, et al. In vivo diagnosis of plaque erosion and calcified nodule in patients with acute coronary syndrome by intravascular optical coherence tomography. *J Am Coll Cardiol* 2013; 62: 1748–1758.
6. Libby P and Pasterkamp G. Requiem for the “vulnerable plaque.” *Eur Heart J* 2015; 36: 2984–2987.
7. Tamis-Holland JE, Jneid H, Reynolds HR, et al. Contemporary Diagnosis and Management of Patients With Myocardial Infarction in the Absence of Obstructive Coronary Artery Disease: A Scientific Statement From the American Heart Association. *Circulation* 2019; 139: e891–e908.
8. Saia F, Komukai K, Capodanno D, et al. Eroded versus ruptured plaques at the culprit site of STEMI: in vivo pathophysiological features and response to primary PCI. *JACC Cardiovasc Imaging* 2015; 8: 566–575.
9. Dai J, Xing L, Jia H, et al. In vivo predictors of plaque erosion in patients with ST-segment elevation myocardial infarction: a clinical, angiographical, and intravascular optical coherence tomography study. *Eur Heart J* 2018; 39: 2077–2085.
10. Jia H, Dai J, Hou J, et al. Effective anti-thrombotic therapy without stenting: intravascular optical coherence tomography-based management in plaque erosion (the

- EROSION study). *Eur Heart J* 2017; 38: 792–800.
11. Dai J, Lyu SZ, Chen YD, et al. Stenting versus non-stenting treatment of intermediate stenosis culprit lesion in acute ST-segment elevation myocardial infarction: a multicenter randomized clinical trial. *J Geriatr Cardiol* 2017; 14: 108–117.
 12. Gagnier JJ, Kienle G, Altman DG, et al. The CARE guidelines: consensus-based clinical case reporting guideline development. *J Med Case Rep* 2013; 7: 223.