

N-acetylcysteine ameliorates contrast-induced kidney injury in rats with unilateral hydronephrosis

QIANG XIA¹, CHUNXIAO LIU² and XIA ZHENG³

¹Department of Urology, Wuxi Ninth People's Hospital, Wuxi, Jiangsu 214062; ²Department of Urology, Zhujiang Hospital of Southern Medical University, Guangzhou, Guangdong 510280; ³Department of Comparative Medicine, Guangdong Medical Laboratory Animal Center, Foshan, Guangdong 528248, P.R. China

Received February 8, 2017; Accepted September 21, 2017

DOI: 10.3892/mmr.2017.8122

Abstract. The aim of the present study was to investigate the protective effects of N-acetylcysteine (NAC) on contrast-induced acute kidney injury in rats with unilateral hydronephrosis. Eighty-two male Sprague Dawley rats were randomized to undergo sham operation (n=14) or unilateral ureteral obstruction (UUO) (n=68). After 3 weeks, the UUO animals were randomized to three groups: NAC gastric perfusion, UUO+iohexol+NAC (n=24); normal saline perfusion, UUO+iohexol (n=24); and controls, UUO (n=20). After 3 days, UUO+iohexol+NAC and UUO+iohexol rats were injected with iohexol. One day after contrast, half of the rats were sacrificed to assess the pathological changes to the kidneys, serum creatinine, serum neutrophil gelatinase-associated lipocalin (NGAL), renal cell apoptosis rate and expression of apoptosis regulators Bcl-2/Bax. The remaining rats underwent obstruction relief and were analyzed 3 weeks later. Compared with the controls, serum NGAL levels were high in UUO+iohexol rats 1 day following injection and 3 weeks after obstruction relief, but UUO+iohexol+NAC rats exhibited lower serum NGAL levels compared with UUO+iohexol rats (all $P < 0.05$). Following modeling, UUO+iohexol rats exhibited a significantly higher apoptosis rate of renal tubular cells, higher expression of Bax mRNA, and lower ratio of Bcl-2/Bax (all $P < 0.05$). Three weeks after obstruction relief, UUO+iohexol+NAC rats exhibited a lower apoptosis rate, lower Bax mRNA expression, higher expression of Bcl-2 mRNA and higher ratio of Bcl-2/Bax (all $P < 0.05$) compared with day 1 following drug administration. The prophylactic use of NAC reduced the apoptotic rate of renal tubular cells following contrast exposition, which was accompanied by changes in the expression of Bcl-2/Bax mRNA.

Introduction

Hydronephrosis is the distension of the renal pelvis and calyces due to the obstruction of the free flow urine out of the kidney. If left untreated, it leads to the progressive atrophy of the kidney and decreased kidney function, ultimately leading to kidney failure (1,2). One of the methods of choice for diagnosing hydronephrosis is computed tomography (CT) scan. However, 1-2% of individuals with normal renal function will suffer from contrast-induced acute kidney injury (CI-AKI) after the use of contrast medium (3-5), and this proportion is even higher for individuals with renal dysfunction (6,7). CI-AKI is the acute deterioration of renal function within 3 days after the use of a contrast agent, without any other identifiable cause (5).

The pathogenesis of CI-AKI is unclear, but three mechanisms have been suggested (5). Contrast agents induce renal vasoconstriction, leading to renal medulla ischemia (8). Hypoxia can lead to increased amounts of secreted reactive oxygen species (ROS), aggravating organ injury when the oxidative stress overwhelms the antioxidative capacities of the organ (9,10). Contrast agents may also have direct kidney toxicity that leads to mitochondrial dysfunction and apoptosis (10,11).

Clinically, there is no effective way to treat AKI; therefore, prevention should be the best choice. N-acetylcysteine (NAC) has strong antioxidant effects and it is currently recognized as a protective drug against contrast medium induced renal damage (12). Previous studies have shown that NAC could be useful to prevent renal damage in a rat model of kidney obstruction (13), and to prevent CI-AKI in patients with normal or impaired kidney function undergoing CT scan (14,15). However, the effect of NAC on CI-AKI in complete unilateral ureteral obstruction (UUO) has not been reported.

Therefore, the present study aimed to investigate the protective effects of NAC on CI-AKI in rat models of unilateral hydronephrosis. The results of this study could provide new ways of preventing CI-AKI in patients with impaired kidney function.

Materials and methods

Experimental animals. Male Sprague-Dawley (SD) rats (n=82, body weight of 250-290 g) of specific pathogen-free (SPF)

Correspondence to: Dr Qiang Xia, Department of Urology, Wuxi Ninth People's Hospital, 999 Liangxi Road, Wuxi, Jiangsu 214062, P.R. China
E-mail: xq8558@126.com

Key words: N-acetylcysteine, hydronephrosis, contrast medium, apoptosis, Bcl-2/Bax

grade were provided by the Animal Center of the Guangdong Medical Laboratory (Foshan, China; quality certificate no. 0113875). SD rats were kept in the SPF animal house of the Guangdong Provincial Medical Experimental Animal Center (license number for experimental animals: SYXK (Guangdong) 2008-0002). All animals were quarantined for 3 days. During the period, animals were inspected once in a day, and unhealthy rats were removed immediately if found. Only healthy rats were used in the experiment. All animal experiments were performed according to the animal experimental guide of the Ethics Committee of the Southern Medical University. All experimental procedures were approved by this committee.

Animal model. The model of UO was induced as previously described (16). Briefly, the rats were adapted to their new environment for 1 week. Rats were fasted for 12 h before modeling, but they had free access to water. After anesthesia with injection of 3% pentobarbital sodium, the middle abdomen was shaved, disinfected, and incised to expose the conjunction of the left renal pelvis and ureter (UPJ). Then, the abdomen of the 14 rats in the sham-operated group was closed. For the remaining 68 rats in the model group, a 1.8-cm plastic epidural catheter for anesthesia was folded into a 'V-shape' with a plastic catheter, gently sheathed within the ureter to obtain a dissociative ureter with 5 mm in length at 1 cm below UPJ. The ends of the V tube were ligated with no. 1 silk thread leading to occlusion of the ureteral lumen. Care was taken to keep the distance between the end of the line and the knot to only 1-2 mm in all animals. Animals were placed in the lateral position after operation and kept one animal/cage. Penicillin (8×10^4 U/rat) was injected for 3 days to prevent infection.

Grouping and treatments. Fig. 1 presents the study design and grouping. The model was considered ready after 3 weeks, and 68 rats were randomly divided into three groups: The NAC gastric perfusion group (UO+iohexol+NAC, n=24), which was administered with NAC by gavage for 3 days [H20090620, 600 mg/kg/day (Zambon Co., SpA, Bresso, Italy), according to Pattharanitima and Tasanarong (5), a 6.3 coefficient was used to convert the NAC human dose to rats]; the normal saline (NS) gastric perfusion group (UO+iohexol, n=24), which was administered with the same amount of NS by gavage for 3 days; and the control group (UO, n=20), which was not administered by gavage and was caged under the same conditions as the other groups.

After 3 days, the UO+iohexol+NAC and UO+iohexol rats were injected with contrast medium via the tail vein [iohexol (Yangtze River Pharmaceutical Group Co., Ltd., Taizhou, China), H10970326, 300 mg/ml/kg, according to Efrati *et al* (17)]. Rats in the UO group were not injected with contrast medium but the same amount of NS. Fourteen sham-operated rats were not treated by gavage administration as well as any drug. One day after injection, half of the rats in each group were randomly selected to collect serum and kidney samples.

Release of obstruction. The remaining animals underwent laparotomy under anesthesia on the same day (1 day after

contrast administration). After exposing the obstruction part, the V tube was found, and the ligation line was cut, resulting in obstruction relief. Finally, the suture was removed. For sham-operated rats, all of them underwent sham operation. Postoperatively, penicillin (8×10^4 U/rat) was injected for 3 days to prevent infection.

Sample collection. Three weeks after obstruction relief, 5 ml of blood was taken from the abdominal aorta, and centrifuged at 4°C and 3,000 rpm for 10 min to obtain serum. The rats were sacrificed by cervical dislocation and both kidneys were taken.

Renal morphology and pathology. Length, width, and height of the kidney were measured to calculate the volume of the kidney [size = (length x width x height) x 0.523]. The kidney was cut along the dorsal longitudinal section to release the hydronephrosis completely. Then, the thickness of the renal parenchyma (the average of the thickest and thinnest values) was measured after the kidney was dried with tissue paper. Kidney sections were analyzed by H&E staining.

Serum creatinine. An automatic biochemical analyzer (AEROSSET; Abbott Laboratories, Abbott Park, IL, USA) was used to detect serum creatinine (Creatinine Assay kit; Sigma-Aldrich, St. Louis, MO, USA).

Serum neutrophil gelatinase-associated lipocalin (NGAL). The Rat NGAL kit (Alpco, Salem, NH, USA) was used to test for NGAL levels. Microplates were read on a Bio-Rad plate reader (Bio-Rad Laboratories, Inc., Hercules, CA, USA).

Apoptosis detection in kidney tissues. A TUNEL apoptosis detection kit (TdT-mediated dUTP nick end labeling, #12156792910; Roche Applied Science, Penzberg, Germany) was used to detect the apoptosis of renal tubular cells. The number of apoptotic cells and the total number of cells were counted to calculate apoptosis index (AI; AI = number of apoptotic cells/total number of cells x 100%). Each sample was measured with three fields of view, and the average value was calculated.

Real-time Qpcr. A PCR kit (PikoReal; Thermo Fisher Scientific, Inc., Waltham, MA, USA) was used to detect the expression of Bcl-2 mRNA and Bax mRNA in left kidney tissues. TRIzol was used to extract total RNA [(Invitrogen, Inc., Carlsbad, CA, USA); fluorescence quantitative PCR kit (Takara Bio, Inc., Otsu, Japan); cellulose nitrate membrane (Millipore Corp., Billerica, MA, USA)] according to the manufacturer's instructions. After RNA extraction, UV spectrophotometry was used to measure the OD values at 260 and 280 nm. The RNA sample was stored at -80°C for later use.

Reverse transcription of RNA to cDNA was performed according to the instructions of the reverse transcription kit. RNAase-free water was used to dilute the product 10 times. For fluorescence quantitative PCR amplification, the Livak method ($2^{-\Delta\Delta C_t}$) was used for relative quantitation (β -actin as control). Bcl-2 gene was amplified with: Forward, 5'-GTG GTGGAGGAAGCTTCAGGGATG-3' and reverse, 5'-GGT CTCAGAGACAGCCAGGAGAAATC-3' (226 bp); Bax

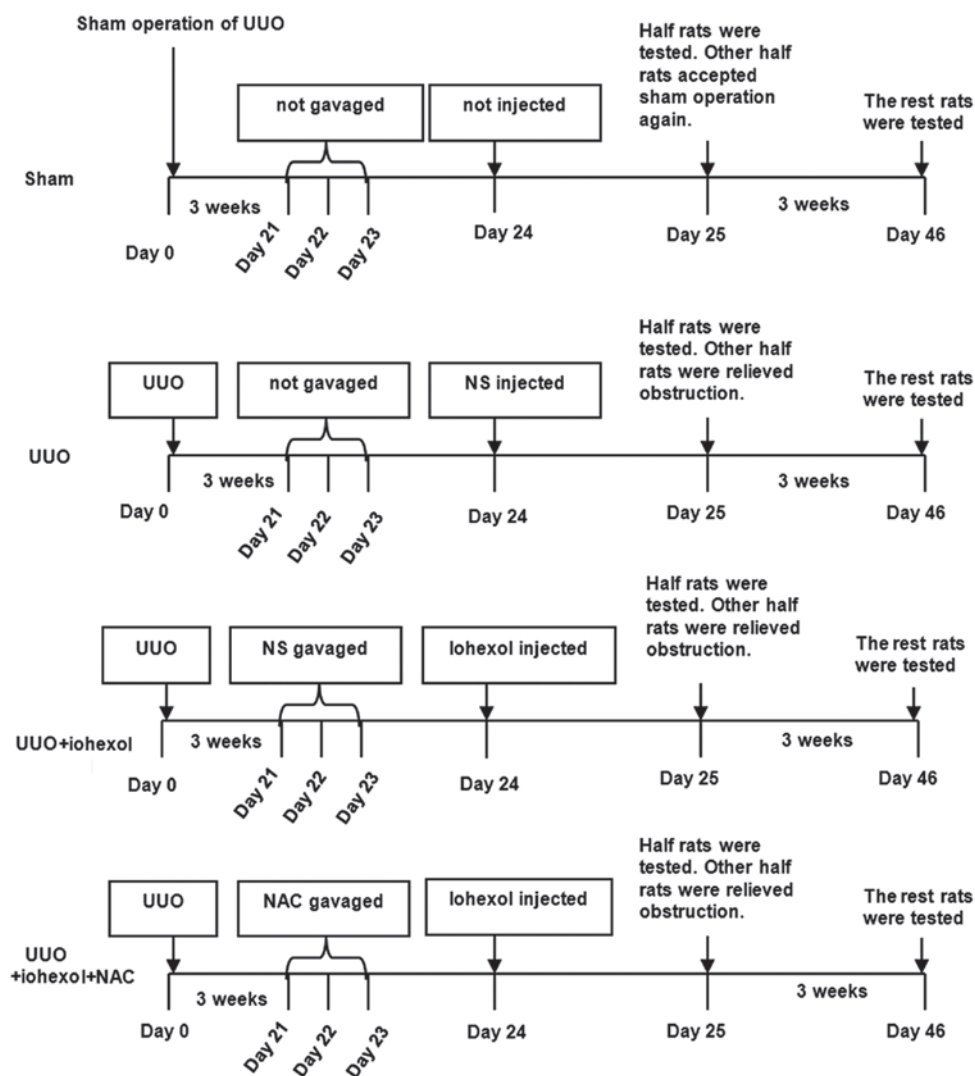


Figure 1. Schematic picture of the study design. UUO, unilateral ureteral obstruction; NS, normal saline; NAC, N-acetylcysteine; Sham, sham operation group.

gene was amplified with: Forward, 5'-GGGTTTCATCCA GGATCGAGCAG-3' and reverse, 5'-GAGTCCGTGTCCACG TCAGCAAT-3' (288 bp); and β -actin gene was amplified with: Forward, 5'-ATGTGGCCGAGGACTTTGATT-3' and reverse, 5'-AGTGGGGTGGCTTTTAGGATG-3' (107 bp).

Western blotting. Western blotting was used to detect the expression of Bcl-2 and Bax proteins in the left kidney tissues (Invitrogen Inc.). FlourChem V2.0 gel imaging analysis software (Alpha Innotech, San Leandro, CA, USA) was used for analysis. The grayscale values of targeted bands and β -actin band were used to quantify the relative expression of targeted proteins.

Statistical analysis. Data are represented as mean \pm standard deviation. Effect of contrast medium on the rats among the different groups and different time points was determined by the factorial variance analysis method. Single effect analysis was based on the results of mean LSD correction after factorial analysis. The Welch test was used when the variance was not homogeneous. SPSS 21.0 (IBM Corp., Armonk, NY, USA) was used for all statistical analyses. Two-sided P-values <0.05 were considered statistically significant.

Results

Morphological changes of kidney in rats. No significant abnormalities were found in renal section from sham-operated rats (Fig. 2A). In the model rats, the left kidney showed thinner parenchyma, glomeruli atrophy, and lower number of glomeruli (Fig. 2B). Furthermore, expansion of some part of the left renal tubular, flattened tubular epithelia, tubular protein casts, and cellular casts in some renal tubular; collapse of some renal tubular lumen, renal tubular vacuolation; infiltrated renal interstitial inflammatory cell, and severe renal interstitial fibrosis were found in rats from the UUO+iohexol group (Fig. 2C). The UUO+iohexol+NAC showed less damage (Fig. 2D).

Except for the sham-operated group, the left kidney volume of the rats in each group was significantly increased compared with the right kidney 1 day after obstruction (Fig. 2E). Similarly, the parenchyma thickness of the left kidney was significantly thinner than that of the right kidney (Fig. 2F), indicating that the model was successful and reliable. Except for the sham-operated rats, the left kidney volume of the rats in each group was significantly decreased 3 weeks after obstruction relief, indicating that relief of obstruction was successful.

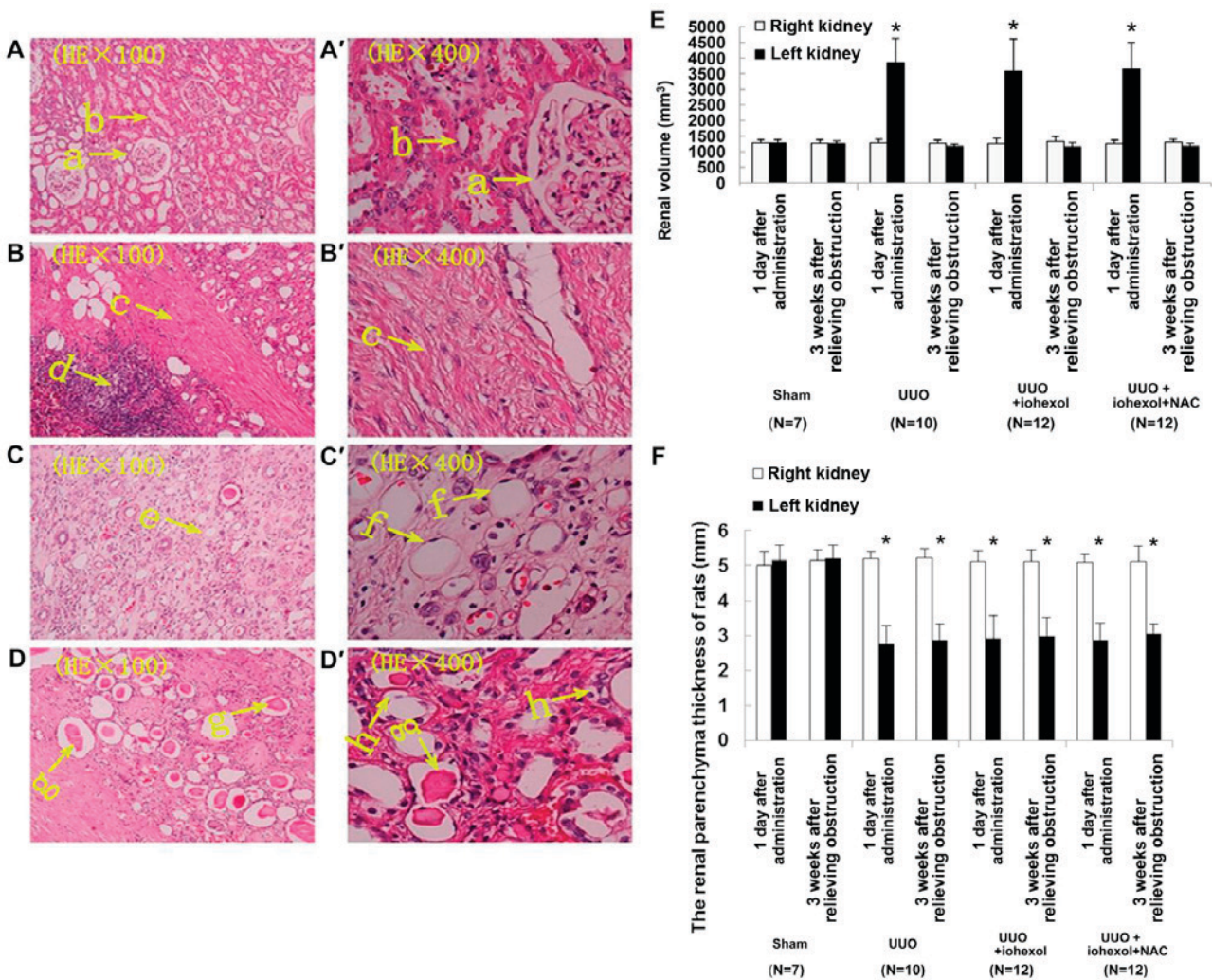


Figure 2. Histological sections of the left kidneys (1 day after contrast administration) of the sham-operated group (n=7) (A) the UUO group (n=10), (B) the UUO+iohexol group (n=12), (C) and the UUO+iohexol+NAC group (n=12), (D) (H&E, x100). (A'-D') show (A-D) at higher magnification (H&E, x400). 'a' indicates normal glomeruli, 'b' indicates normal tubules, 'c' indicates renal interstitial fibrosis, 'd' indicates infiltrated renal interstitial inflammatory cells, 'e' indicates dilated renal tubules, 'f' indicates flattened tubular epithelia, 'g' indicates cellular casts in some renal tubules, and 'h' indicates renal tubular vacuolation. (E) Renal volume of the rat models of UUO. (F) Cortical thickness of the rat models of UUO. Data are presented as mean ± standard deviation. *P<0.05 vs. right kidney. UUO, unilateral ureteral obstruction; NAC, N-acetylcysteine.

Changes of kidney function after modeling. No significant differences were found in the serum creatinine and NGAL levels of the four groups on the day after drug administration and 3 weeks after relieving obstruction (Fig. 3), suggesting that unilateral obstruction and contrast medium-mediated injury did not significantly affect the overall renal function due to the compensation of the healthy kidney.

Renal tubular cell apoptosis. Fig. 4A-D shows the renal tubular cell apoptosis detected by TUNEL assay 3 weeks after relieving obstruction in the left kidneys of the sham-operated group (n=7) (Fig. 4A), the UUO group (n=10) (Fig. 4B), the UUO+iohexol group (n=12) (Fig. 4C), and the UUO+iohexol+NAC group (n=12) (Fig. 4D). As shown in Fig. 4E, except for the sham-operated group, there were differences in apoptosis rates of the left and right kidney renal tubular cells in rats of the three UUO groups on the two time points (1 day after drug administration and 3 weeks after relief of obstruction, P<0.001). The apoptosis rate of the left renal tubular cells of the sham-operated rats was significantly lower

than that of the other three groups 1 day after drug administration (P<0.001), but there was no significant difference in the other three groups. The apoptosis rate of left renal tubular cells in UUO+iohexol rats increased 3 weeks after relief of obstruction compared with 1 day after drug administration and it was also higher than that of CG rats (both P<0.05). The apoptosis rate of left renal tubular cells in UUO+iohexol+NAC rats 3 weeks were decreased after obstruction relief compared with 1 day after drug administration; it was also lower than that of UUO+iohexol rats (P<0.05) (Fig. 4E).

Changes of Bcl-2/Bax expression. Bax mRNA expression in the left kidney tissues of SOG rats at two time points (1 day after drug administration and 3 weeks after relief of obstruction) was significantly lower than in the three UUO groups (Fig. 5A). The ratio of Bcl-2 mRNA expression and Bcl-2/Bax expression was significantly higher than in the three UUO groups (Fig. 5A). For the three UUO groups 1 day after drug administration, there were no significant differences between the groups. Three weeks after relief of obstruction, Bcl-2

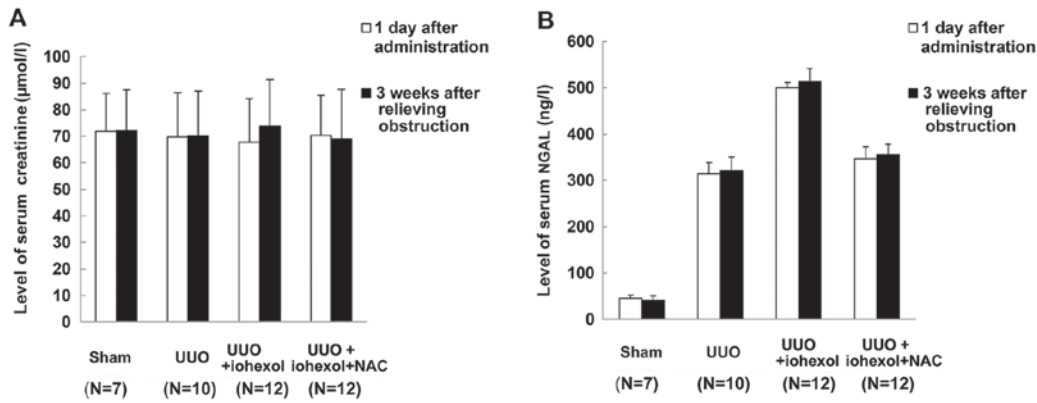


Figure 3. (A) Changes of serum creatinine levels 1 day after contrast administration and 3 weeks after relieving obstruction. (B) Changes of serum NGAL levels 1 day after contrast administration and 3 weeks after relieving obstruction. Data from the sham-operated group (n=7), the UUO group (n=10), the UUO+iohexol group (n=12), and the UUO+iohexol+NAC group (n=12) are presented as mean ± standard deviation. NGAL, neutrophil gelatinase-associated lipocalin; UUO, unilateral ureteral obstruction; NAC, N-acetylcysteine.

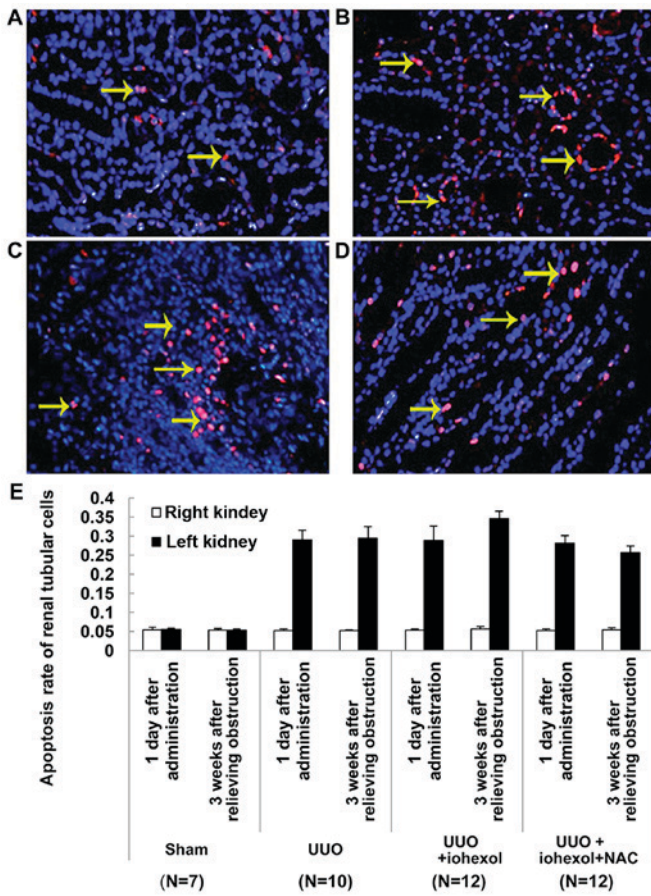


Figure 4. Renal tubular cell apoptosis detected by TUNEL assay (3 weeks after relieving obstruction) in the left kidneys of (A) the sham-operated group (n=7) (B) the UUO group (n=10), (C) the UUO+iohexol group (n=12), and (D) the UUO+iohexol+NAC group (n=12) (x200). The arrows indicate TUNEL-positive apoptotic cells. (E) Quantification of the apoptosis rates of the four groups. Data are presented as mean ± standard deviation. UUO, unilateral ureteral obstruction; NAC, N-acetylcysteine.

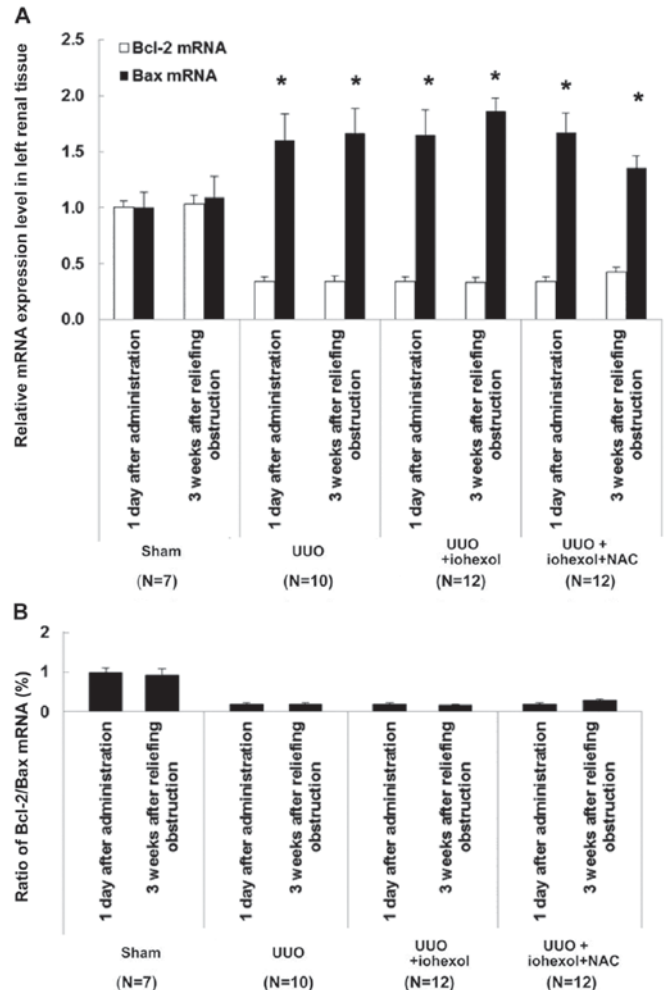


Figure 5. (A) Relative Bcl-2/Bax mRNA expression in the four groups. *P<0.05 vs. the sham group. (B) Ratio of Bcl-2/Bax mRNA in the four groups. UUO, unilateral ureteral obstruction; NAC, N-acetylcysteine.

mRNA expression of the left kidney tissues in UUO+iohexol rats was slightly increased, but without significant difference, while the expression of Bax mRNA was decreased remarkably, represented by decreased ratio of Bcl-2/Bax (Fig. 5B). The Bax mRNA expression of the left kidney tissues in

UUO+iohexol+NAC rats was decreased (Fig. 5A), but the expression of Bcl-2 mRNA and ratio of Bcl-2/Bax were increased (Fig. 5).

Western blotting results of Bcl-2/Bax in the left kidney tissues in each group of rats are shown in Fig. 6A-C. Results

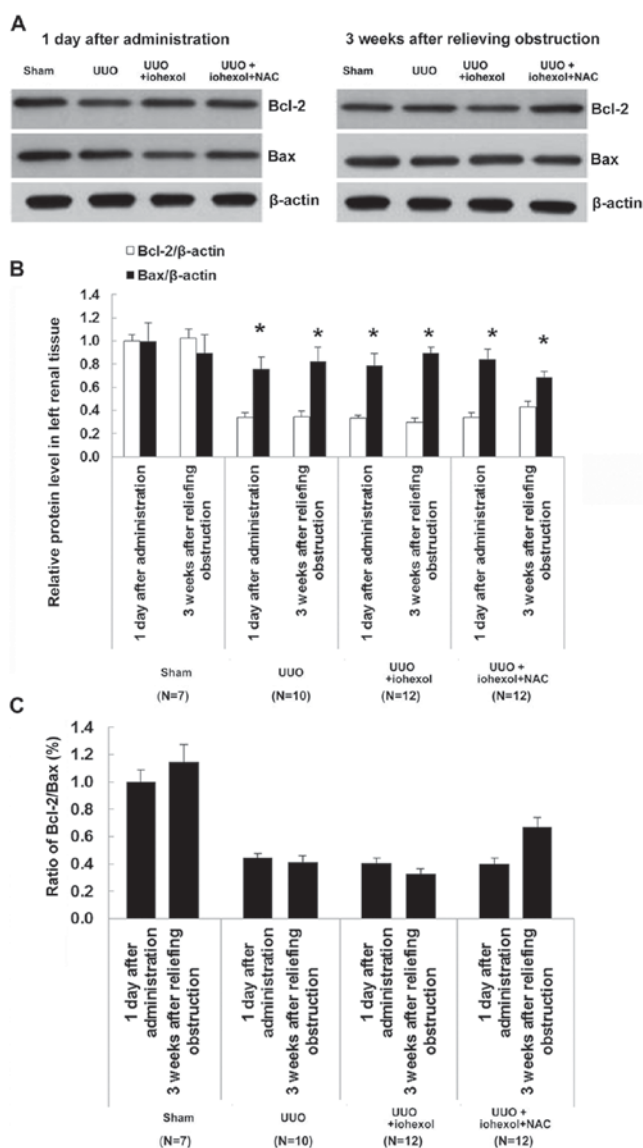


Figure 6. (A) Representative western blot of Bcl-2 and Bax in the four groups. (B) Relative Bcl-2/Bax protein expression in the four groups. (C) Ratio of Bcl-2/Bax protein in the four groups. Data from the sham-operated group (n=7), the UUO group (n=10), the UUO+iohexol group (n=12), and the UUO+iohexol+NAC group (n=12) are presented as mean \pm standard deviation. * P <0.05 vs. the sham group. UUO, unilateral ureteral obstruction; NAC, N-acetylcysteine.

showed that Bcl-2 protein expression was decreased in all three UUO groups 1 day after drug administration. Compared with 1 day after drug administration, the Bcl-2/Bax ratio decreased in the UUO+iohexol group at 3 weeks after obstruction relief, while the ratio was increased in the UUO+iohexol+NAC group.

Discussion

The objective of this study was to investigate the protective effects of NAC on CI-AKI in rats with unilateral hydronephrosis. Results showed that compared with controls, serum NGAL levels were high in UUO+iohexol rats 1 day after injection and 3 weeks after obstruction relief, but UUO+iohexol+NAC rats had lower serum NGAL levels compared with UUO+iohexol rats. After modeling, UUO+iohexol rats had significantly

higher apoptosis rate of renal tubular cells, higher expression of Bax mRNA (P <0.05), and lower ratio of Bcl-2/Bax. Three weeks after obstruction relief, UUO+iohexol+NAC rats had lower apoptosis rate, lower Bax mRNA expression, higher expression of Bcl-2 mRNA, and higher ratio of Bcl-2/Bax when compared with day 1 after drug administration. Only one previous study showed a role of NAC in preventing renal impairment in a model of kidney obstruction (18), but the animal model was different from the present study, which used rats instead of mice. In addition, the study by Shen *et al* (18) focused on the protective effect of NAC on renal fibrosis, while the present study focused on the protective role of NAC on the apoptosis of renal cells. Therefore, we explored different mechanisms of the protective effects of NAC.

When the ureters are obstructed, urine renal excretion are blocked, resulting in increase of intrarenal pressure, expansion of renal pelvis and calyx, renal interstitial edema, infiltration of focal inflammatory cell, fibrosis of renal tubular, renal vasoconstriction, renal parenchymal hypoxia ischemia, impaired renal function, and progressive atrophy of renal parenchyma (3). Even if the upper urinary tract obstruction is relieved, some cases are still suffering from renal atrophy, which was also observed in the present study. A number of studies have indicated that ROS-mediated apoptosis is involved in the renal pathological changes after urinary tract obstruction (5,19). In the present study, the apoptosis rate of the left renal tubular cells in the UUO rats was increased, and the Bcl-2 expression decreased while the expression of Bax increased. Renal tubular cell apoptosis may be the main cause of obstructive renal atrophy, which is consistent with the conclusions of other studies (5,19).

NGAL, also known as Lipocalin-2, is encoded by a gene on chromosome 9q34. NGAL is one of the main inducer genes in the early stage of ischemic renal injury. The increase of NGAL mRNA expression and NGAL protein secretion in the rat kidney with early ischemic injury can be detected in urine and blood, and is directly proportional to the level and duration of ischemia (20). In the present study, serum NGAL levels of UUO rats were higher than in sham-operated rats, suggesting that ureteral obstruction caused kidney injury. NGAL levels did not decrease after obstruction relief. Taken together, these data suggest that the ureteral obstruction-caused kidney injury is not significant in the early stage only due to the compensation of the healthy side kidney, and the injury does not significantly affect the overall renal function, confirmed by the absence of difference in serum creatinine levels.

In clinical practice, enhanced CT is one of the main imaging modalities for urinary tract obstruction examination. Currently, iodine contrast agents are widely used for enhanced CT. Adverse reactions are often observed with the use of contrast agents, including allergic reaction and neurotoxicity, vascular toxicity and renal toxicity; among them, allergic reaction is the most common and renal toxicity is the most serious (21). The mechanism of acute renal injury induced by iodine contrast agent has not been fully clarified. Most authors believe that the process includes at least three cascades of pathophysiological processes. First, the contrast agent induce renal vascular contraction, resulting in renal medullary ischemia (22). Second, ischemia and hypoxia can cause increase of ROS, which further aggravates the injury of ischemic kidney.

When organ injury occurs, ROS produced by inadequate tissue perfusion overwhelm the antioxidant reserves (10). Third, contrast agent-mediated renal tubular toxicity leads to mitochondrial dysfunction, producing reactive oxygen and cell apoptosis (10). The incidence and severity of renal injury are correlated with the level of renal dysfunction before contrast agent injection (23). For individuals with unilateral urinary tract obstruction, overall renal function is normal. However, there are some injuries to the renal function of the obstructed side that can lead to decreased glomerular filtration rate (24), and infusion of contrast agent at this time increases the risk for injuries of renal ischemia and direct toxicity. In the present study, NGAL levels of UUO+iohexol rats were increased significantly 1 day after injection of the contrast agent, which was an acute reaction resulting in renal injury. Cell apoptosis is a time-dependent process, and cell apoptosis rate was not changed at this time. Three weeks later, although the obstruction was relieved, the apoptosis rate of renal tubular cells was significantly increased, suggesting CI-AKI.

There is no known treatment for CI-AKI, but interventions that could decrease ischemia and/or oxidative damage have been suggested to prevent CI-AKI. Animal models and clinical trials have studied a variety of prevention methods (6,11,14,15,17). Researches mainly focus on anti-vasoconstriction, enhancing renal blood flow, or preventing ROS damage. Because ROS play an important role in CI-AKI (25), removing ROS has become one of the most promising ways to prevent CI-AKI. NAC, as an antioxidant, has become a commonly recognized protective drug for kidney injury induced by contrast agents (6,11,14,15,17). Presently, NAC has been used in several studies to prevent CI-AKI (26-28). NAC contains a thiol group (-SH) that can deactivate ROS, and plays the role in antioxidant directly (29). Second, NAC can promote glutathione synthesis, and through glutathione, plays an indirect role in antioxidation (29). Third, through NO and S-nitrosothiols, NAC can play roles in vascular dilation, inhibiting the generation of angiotensin-converting enzyme, and stabilizing NO to reduce the effect of contrast agents on renal functions (29). A study used NAC to prevent kidney damage induced by obstruction (13). The present study showed that the NGAL serum levels of UUO+iohexol+NAC rats were significantly lower than in UUO+iohexol rats, which supports that NAC could reduce CI-AKI.

Low levels of ROS can promote cell proliferation to some extent, but relatively high levels of ROS can induce cell apoptosis, and even higher levels of ROS might directly cause cell necrosis (30). An important regulatory mechanism of apoptosis activation by oxidative stress is the imbalance of Bcl-2 and Bax expression (31,32), but the exact mechanisms remain unclear. NAC-induced decreased oxidative stress is accompanied by reduced renal apoptosis (5,24), which is represented by changes in the expression of Bcl-2 and Bax. Bcl-2 and Bax are anti-apoptosis and pro-apoptosis proteins, respectively (19). Bcl-2 is an anti-apoptotic protein and inhibits membrane permeability and blocks the destruction of cellular components by oxidation by stabilizing the mitochondrial membrane (33). Bax is a regulator of Bcl-2 activity, and the ratio of Bcl-2 to Bax determines the occurrence of apoptosis (33). In the present study, in the obstructed kidney of the UUO+iohexol+NAC rats, the Bcl-2/Bax ratio was significantly higher after obstruction relief than before, resulting that the

apoptosis rate of renal tubular cells was decreased. Taken together, it suggests that the antioxidant effect of NAC upregulates the expression of Bcl-2 mRNA and down-regulates the expression of Bax mRNA, showing the protective effect of NAC against CI-AKI.

Of course, the present study is not without limitations. It was performed in animal models and clinical trials are necessary to confirm these results. In addition, the mechanisms of ROS leading to apoptosis through changes in the Bcl-2/Bax ratio remain unclear. The present study was not designed to comprehensively assess the Bcl-2/Bax pathway and additional studies are necessary to shed light on these mechanisms.

In conclusion, the prophylactic use of NAC reduced the apoptotic rate of renal tubular cells after contrast exposition, which was accompanied by change in the expression of Bcl-2/Bax mRNA.

Acknowledgements

The authors acknowledge the help of Dr Zhiyong Zhong from Comparative Medical Laboratory of Guangdong Medical Laboratory Animal Center and Dr Hua Yuan from Wuxi Maternal and Child Health-Care Hospital.

References

1. Kumar V, Fausto N and Abbas AK: Robbins and Cotran Pathologic Basis of Disease. 7th edition. Elsevier Saunders, Philadelphia, 2005.
2. Chevalier RL: Pathophysiology of obstructive nephropathy in the newborn. *Semin Nephrol* 18: 585-593, 1998.
3. Rudnick MR, Goldfarb S and Tumlin J: Contrast-induced nephropathy: Is the picture any clearer? *Clin J Am Soc Nephrol* 3: 261-262, 2008.
4. Berg KJ: Nephrotoxicity related to contrast media. *Scand J Urol Nephrol* 34: 317-322, 2000.
5. Pattharanitima P and Tasanarong A: Pharmacological strategies to prevent contrast-induced acute kidney injury. *Biomed Res Int* 2014: 236930, 2014.
6. Gurm HS, Smith DE, Berwanger O, Share D, Schreiber T, Moscucci M and Nallamothu BK; BMC2 (Blue Cross Blue Shield of Michigan Cardiovascular Consortium): Contemporary use and effectiveness of N-acetylcysteine in preventing contrast-induced nephropathy among patients undergoing percutaneous coronary intervention. *JACC Cardiovasc Interv* 5: 98-104, 2012.
7. Tepel M, Aspelin P and Lameire N: Contrast-induced nephropathy: A clinical and evidence-based approach. *Circulation* 113: 1799-1806, 2006.
8. Persson PB, Hansell P and Liss P: Pathophysiology of contrast medium-induced nephropathy. *Kidney Int* 68: 14-22, 2005.
9. Brezis M and Rosen S: Hypoxia of the renal medulla-its implications for disease. *N Engl J Med* 332: 647-655, 1995.
10. Tumlin J, Stacul F, Adam A, Becker CR, Davidson C, Lameire N and McCullough PA; CIN Consensus Working Panel: Pathophysiology of contrast-induced nephropathy. *Am J Cardiol* 98: 14K-20K, 2006.
11. Romano G, Briguori C, Quintavalle C, Zanca C, Rivera NV, Colombo A and Condorelli G: Contrast agents and renal cell apoptosis. *Eur Heart J* 29: 2569-2576, 2008.
12. Kelly AM, Dwamena B, Cronin P, Bernstein SJ and Carlos RC: Meta-analysis: Effectiveness of drugs for preventing contrast-induced nephropathy. *Ann Intern Med* 148: 284-294, 2008.
13. Sunay M, Karakan T, Aydin A, Koca G, Borcek P and Ögüş E: Do montelukast sodium and N-acetylcysteine have a nephroprotective effect on unilateral ureteral obstruction? A placebo controlled trial in a rat model. *J Urol* 194: 1132-1137, 2015.
14. Inda-Filho AJ, Caixeta A, Manggini M and Schor N: Do intravenous N-acetylcysteine and sodium bicarbonate prevent high osmolar contrast-induced acute kidney injury? A randomized controlled trial. *PLoS One* 9: e107602, 2014.
15. Rehman T, Fought J and Solomon R: N-acetylcysteine effect on serum creatinine and cystatin C levels in CKD patients. *Clin J Am Soc Nephrol* 3: 1610-1614, 2008.

16. Chaabane W, Praddaude F, Buleon M, Jaafar A, Vallet M, Rischmann P, Galarreta CI, Chevalier RL and Tack I: Renal functional decline and glomerulotubular injury are arrested but not restored by release of unilateral ureteral obstruction (UUO). *Am J Physiol Renal Physiol* 304: F432-F439, 2013.
17. Efrati S, Berman S, Ilgiyev I, Siman-Tov Y, Averbukh Z and Weissgarten J: Differential effects of N-acetylcysteine, theophylline or bicarbonate on contrast-induced rat renal vasoconstriction. *Am J Nephrol* 29: 181-191, 2009.
18. Shen Y, Miao NJ, Xu JL, Gan XX, Xu D, Zhou L, Xue H, Zhang W and Lu LM: N-acetylcysteine alleviates angiotensin II-mediated renal fibrosis in mouse obstructed kidneys. *Acta Pharmacol Sin* 37: 637-644, 2016.
19. Liapis H, Yu H and Steinhardt GF: Cell proliferation, apoptosis, Bcl-2 and Bax expression in obstructed opossum early metanephroi. *J Urol* 164: 511-517, 2000.
20. Skott M, Nørregaard R, Sorensen HB, Kwon TH, Frøkiaer J and Nielsen S: Pre-existing renal failure worsens the outcome after intestinal ischaemia and reperfusion in rats. *Nephrol Dial Transplant* 25: 3509-3517, 2010.
21. Goldenberg I and Matetzky S: Nephropathy induced by contrast media: Pathogenesis, risk factors and preventive strategies. *CMAJ* 172: 1461-1471, 2005.
22. Devrim E, Cetin M, Namuslu M, Ergüder IB, Cetin R and Durak I: Oxidant stress due to non ionic low osmolar contrast medium in rat kidney. *Indian J Med Res* 130: 433-436, 2009.
23. Nicholson T and Downes M: Contrast nephrotoxicity and iso-osmolar contrast agents: Implications of NEPHRIC. *Clin Radiol* 58: 659-660, 2003.
24. Yeh CH, Chiang HS, Lai TY and Chien CT: Unilateral ureteral obstruction evokes renal tubular apoptosis via the enhanced oxidative stress and endoplasmic reticulum stress in the rat. *Neurourol Urodyn* 30: 472-479, 2011.
25. Weisbord SD and Palevsky PM: Prevention of contrast-induced nephropathy with volume expansion. *Clin J Am Soc Nephrol* 3: 273-280, 2008.
26. Baliga R, Ueda N, Walker PD and Shah SV: Oxidant mechanisms in toxic acute renal failure. *Am J Kidney Dis* 29: 465-477, 1997.
27. Tepel M, van der Giet M, Schwarzfeld C, Laufer U, Liermann D and Zidek W: Prevention of radiographic-contrast-agent-induced reductions in renal function by acetylcysteine. *N Engl J Med* 343: 180-184, 2000.
28. Shyu KG, Cheng JJ and Kuan P: Acetylcysteine protects against acute renal damage in patients with abnormal renal function undergoing a coronary procedure. *J Am Coll Cardiol* 40: 1383-1388, 2002.
29. Kay J, Chow WH, Chan TM, Lo SK, Kwok OH, Yip A, Fan K, Lee CH and Lam WF: Acetylcysteine for prevention of acute deterioration of renal function following elective coronary angiography and intervention: A randomized controlled trial. *JAMA* 289: 553-558, 2003.
30. Li H, Chen J, Xiong C, Wei H, Yin C and Ruan J: Apoptosis induction by the total flavonoids from *Arachniodes exilis* in HepG2 cells through reactive oxygen species-mediated mitochondrial dysfunction involving MAPK activation. *Evid Based Complement Alternat Med* 2014: 906941, 2014.
31. Yuan Y, Wang Y, Hu FF, Jiang CY, Zhang YJ, Yang JL, Zhao SW, Gu JH, Liu XZ, Bian JC and Liu ZP: Cadmium activates reactive oxygen species-dependent AKT/mTOR and mitochondrial apoptotic pathways in neuronal cells. *Biomed Environ Sci* 29: 117-126, 2016.
32. Gao H, Li LY, Zhang M and Zhang Q: Inactivated Sendai virus induces apoptosis mediated by reactive oxygen species in murine melanoma cells. *Biomed Environ Sci* 29: 877-884, 2016.
33. Jiang H, Zhao PJ, Su D, Feng J and Ma SL: Paris saponin I induces apoptosis via increasing the Bax/Bcl-2 ratio and caspase-3 expression in gefitinib-resistant non-small cell lung cancer *in vitro* and *in vivo*. *Mol Med Rep* 9: 2265-2272, 2014.



This work is licensed under a Creative Commons Attribution-NonCommercial-NoDerivatives 4.0 International (CC BY-NC-ND 4.0) License.