

Intraoperative optical coherence tomography-guided management of post-laser-assisted *in situ* keratomileusis epithelial ingrowth

Manpreet Kaur, Sridevi Nair, Saima A Mazumdar, Jeewan S Titiyal

We describe a modified technique of intraoperative optical coherence tomography (iOCT)-guided removal of post-laser-assisted *in situ* keratomileusis (LASIK) epithelial ingrowth with interface ethyl alcohol and mitomycin C application to prevent a recurrence. Epithelial ingrowth was visualized as hyperreflective deposits in the interface on iOCT, and the location and extent were noted at the beginning of the procedure. A simple dimple-down maneuver was performed to help identify the circumference of the LASIK flap. iOCT helped to delineate the flap edge and ensure dissection in the correct plane with complete removal of epithelial cell nests. Real-time visualization of the interface helped in on-table decision making regarding the extent of lifting the flap to encompass the entire region of hyperreflective epithelial ingrowth, as well as the need for additional interventions to ensure complete flap apposition at the end of surgery. All patients gained an uncorrected visual acuity of 20/20–20/25 with no recurrence.

Key words: Epithelial ingrowth, intraoperative optical coherence tomography, laser-assisted *in situ* keratomileusis

Epithelial ingrowth is a relatively uncommon complication that may be observed in up to 3.9% of cases after laser-assisted *in situ* keratomileusis (LASIK), with a significantly higher incidence in cases undergoing flap lift and retreatment.^[1-3] Additional risk factors include trauma, intraocular surgeries, excessive instrumentation and interface manipulation, hyperopia, and increased patient age.^[4,5] Timely diagnosis and management are essential to prevent permanent visual loss and adverse long-term sequelae. Definitive treatment requires relifting the flap and complete removal of all interface epithelial cell nests.^[5,6]

Optical coherence tomography (OCT) allows *in vivo* optical biopsy of the corneal tissue and has emerged as a useful adjunct in the preoperative diagnosis and treatment planning, intraoperative decision making, and postoperative monitoring of various corneal pathologies.^[7,8] Anterior segment OCT (ASOCT) has been used to delineate the location and extent of epithelial ingrowth and the architecture of the overlying flap and corneal stroma; however, the utility of intraoperative OCT (iOCT) in the surgical management of epithelial ingrowth has not been described.^[9] We herein report our technique of iOCT-guided management of epithelial ingrowth after LASIK.

Surgical Technique

We performed our technique of microscope-integrated iOCT [Zeiss RESCAN 700, Carl Zeiss Meditec, Germany]-guided

removal of the epithelial ingrowth in cases with significant epithelial ingrowth involving the visual axis. Ethyl alcohol and mitomycin C (MMC) were applied to the interface as adjuncts to prevent a recurrence. Written informed consent was obtained from all patients. We adhered to the tenets of the declaration of Helsinki.

The procedure was performed under topical anesthesia. Epithelial ingrowth was visualized as hyperreflective deposits in the interface on iOCT, and the location and extent were noted at the beginning of the procedure [Fig. 1a].

The corneal surface was dried using a Merocel sponge. The edge of the previous LASIK flap was highlighted by a dimple-down procedure, which involved pressing the center of the cornea inward with a blunt instrument such as the reverse side of the merocel sponge [Fig. 1b]. This maneuver emphasizes the circumferential edge of the previous LASIK flap and helps avoid inadvertent misdissection while identifying the LASIK interface.

A LASIK flap-lifter (Seibel IntraLase Flap Lifter and Retreatment Spatula, Rhein Medical, Inc., USA) was used to cleave the flap edge inferiorly and lift a limited area of the LASIK flap overlying the involved area with epithelial ingrowth [Fig. 1c and 1d]. iOCT was used to confirm entry into the correct corneal plane while lifting the flap [Fig. 1c]. The flap overlying the uninvolved corneal stroma was not lifted to minimize unnecessary interface disturbances. iOCT helped

Access this article online

Website:

www.ijo.in

DOI:

10.4103/ijo.IJO_1173_21

Quick Response Code:



Cornea, Cataract and Refractive Surgery Services, Dr. Rajendra Prasad Centre for Ophthalmic Sciences, All India Institute of Medical Sciences, New Delhi, India

Correspondence to: Dr. Jeewan S Titiyal, Cornea, Cataract and Refractive Surgery Services, Dr. Rajendra Prasad Centre for Ophthalmic Sciences, All India Institute of Medical Sciences, New Delhi - 110 029, India. E-mail: titiyal@gmail.com

Received: 11-May-2021

Revision: 20-Aug-2021

Accepted: 24-Aug-2021

Published: 23-Dec-2021

This is an open access journal, and articles are distributed under the terms of the Creative Commons Attribution-NonCommercial-ShareAlike 4.0 License, which allows others to remix, tweak, and build upon the work non-commercially, as long as appropriate credit is given and the new creations are licensed under the identical terms.

For reprints contact: WKHLRPMedknow_reprints@wolterskluwer.com

Cite this article as: Kaur M, Nair S, Mazumdar SA, Titiyal JS. Intraoperative optical coherence tomography-guided management of post-laser-assisted *in situ* keratomileusis epithelial ingrowth. Indian J Ophthalmol 2022;70:288-91.

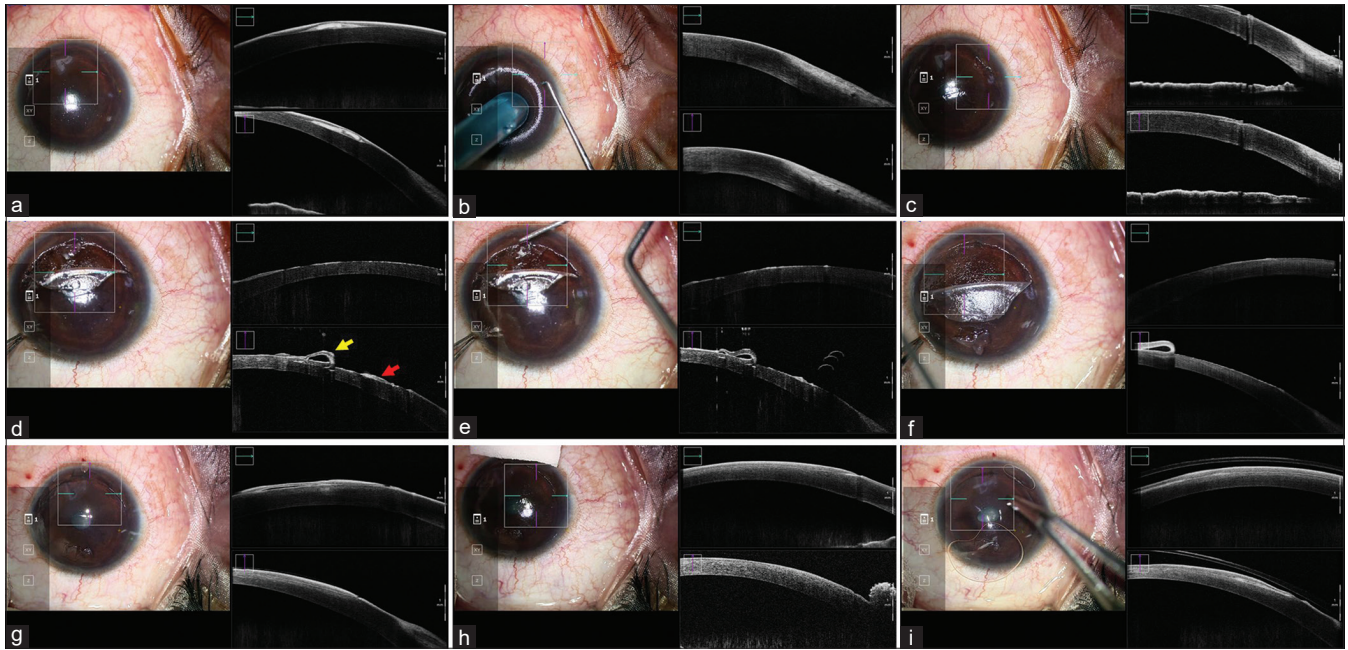


Figure 1: Intraoperative OCT-Guided Management of Post-LASIK Epithelial Ingrowth. (a). iOCT-assisted intraoperative delineation of the LASIK flap and the extent of epithelial ingrowth. (b). Dimple-down maneuver to highlight the LASIK flap edge. (c). Flap lifter used to lift a localized area of LASIK flap overlying the ingrowth. iOCT helps to confirm the correct plane of dissection. (d). Epithelial cell nest on the underside of the flap (yellow arrow) and interface (red arrow) visualized on iOCT. (e). Epithelial cell nests scraped off with a blunt dissector, followed by application of ethyl alcohol and MMC 0.02%. (f). Complete removal of epithelial cell nests confirmed on iOCT. (g). Interface space observed on iOCT after repositioning the flap, necessitating further corneal massage. (h). Complete flap apposition confirmed at end of surgery on iOCT. (i). Bandage contact lens applied

in on-table decision making regarding the extent of lifting the flap to encompass the entire region of hyperreflective epithelial ingrowth as visualized on iOCT.

The epithelial ingrowth was scraped off from the stromal bed as well as the overlying flap using a blunt iris spatula (Appasamy Associates, India) [Fig. 1d and 1e]. The completion of removal of the epithelial cell nests was confirmed on iOCT [Fig. 1f]. Then, 20% ethyl alcohol was applied on the stromal bed and underside of the flap for 30 s to loosen the epithelial cells, followed by further blunt dissection to ensure complete removal of epithelial cells. After scraping off the epithelial ingrowth, MMC 0.02% was applied to the stromal bed and underside of the flap for 30 s each to ensure destruction of any residual viable epithelial cells. The interface was irrigated with balanced salt solution and the flap was gently repositioned. Interface fluid was observed on iOCT after repositioning the flap, which necessitated the need for further corneal massage to appose the graft [Fig. 1g]. Optimal apposition of the flap and regularity of the interface was confirmed on iOCT at the end of surgery [Fig. 1h]. A bandage contact lens (BCL) was applied at the end of the procedure [Fig. 1i].

Postoperatively, the patients were prescribed topical antibiotics (moxifloxacin 0.5% three times a day for four weeks), steroids (prednisolone phosphate 1% four times a day in tapering doses), and lubricants (carboxymethylcellulose 0.5% four times a day) for one month.

Results

We performed our technique in three eyes with post-microkeratome-assisted LASIK epithelial ingrowth

[Fig. 2a and 2b]. On postoperative day (POD) 1, the UDVA ranged from 20/60 to 20/40. Localized flap edema was observed in the area overlying the epithelial ingrowth in all cases. Mild flap scarring was observed on the underside of the flap on slit-lamp examination in one case and confirmed on ASOCT. A regular interface was observed with no detectable residual epithelial cell nests on ASOCT in all cases.

At 1 month, all eyes had improvement in UDVA ranging from 20/25 to 20/20 with a clear cornea on slit-lamp examination. Minimal fibrosis was observed in the LASIK flap in the area overlying the epithelial ingrowth on ASOCT [Fig. 2c and 2d].

There was no recurrence of epithelial ingrowth till 7–10 months of follow-up in any case.

Discussion

Epithelial ingrowth is a rare but potentially sight-threatening complication that may be observed beneath the LASIK flap as the interface provides a potential space for proliferation of epithelial cell nests. Surgical management is indicated in cases with progressive ingrowth encroaching the visual axis.^[4]

The key to successful surgery is the complete removal of the epithelial cell nests. A recurrence of epithelial ingrowth may be observed due to remnant interface epithelial cell nests, migration of new surface epithelial cells due to interface manipulations, or the creation of fistulous tracks connecting the surface to the interface.^[4] Simple mechanical debridement of epithelial ingrowth may be associated with a recurrence in as high as 36% of cases, and various adjunctive methods have been described to prevent recurrence, including use of ethyl

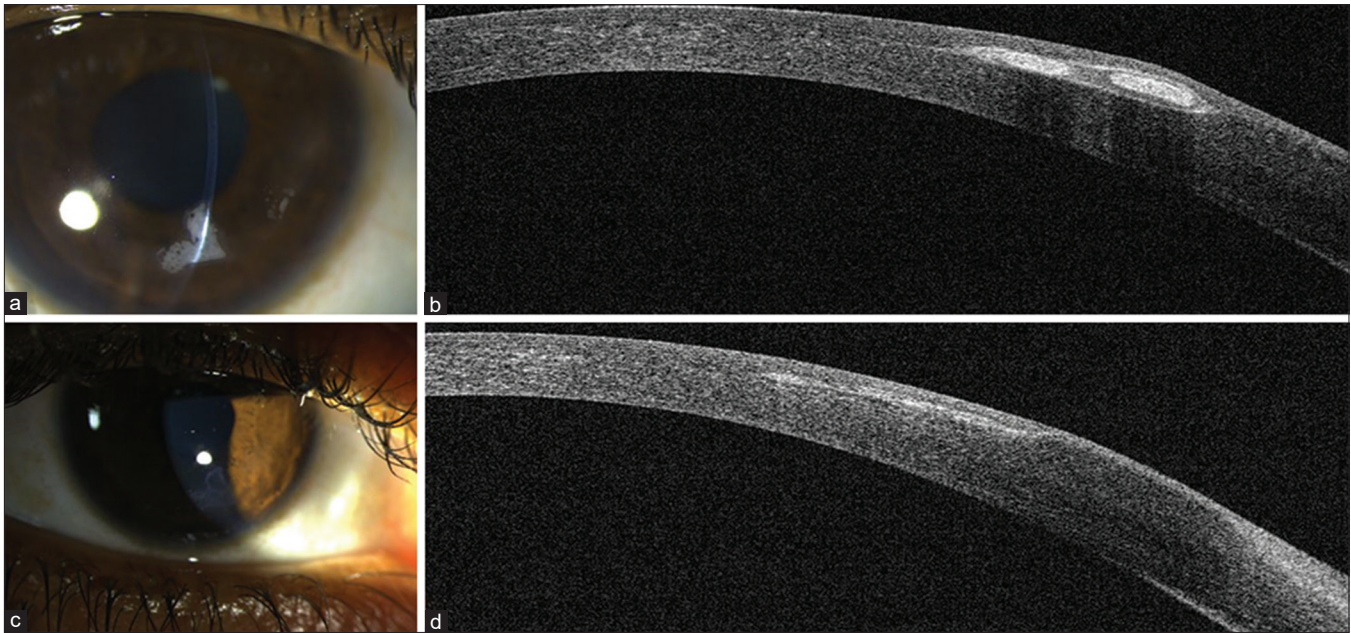


Figure 2: A case of post-LASIK Epithelial Ingrowth managed with iOCT guided removal. (a). Preoperative Slit-lamp image showing interface epithelial cell nests encroaching the visual axis at 5–6 o'clock. (b). Preoperative ASOCT showing LASIK flap with epithelial cell nests in the interface. (c). Postoperative 1-month slit-lamp photograph showing minimal fibrosis at the underside of the LASIK flap with a clear interface and underlying stroma. (d). Postoperative ASOCT showing no residual epithelial cell nests

alcohol and mitomycin C as cytotoxic agents as well as fibrin glue or sutures to promote flap apposition.^[6,10] The completion of removal of the proliferative ingrowth is conventionally assessed clinically on-table and using an ASOCT in the postoperative period.^[9]

We described an iOCT-guided modified surgical technique for management of epithelial ingrowth to minimize intraoperative manipulations and interface disturbances. Identification of previous LASIK flap edge and interface delineation is a crucial step to ensure entry into the correct corneal plane. The flap edge is often not clearly visible under an operating microscope. Excessive surgical manipulations in an attempt to delineate the flap edge may result in the creation of peripheral stromal damage and localized epithelial defects, which in itself are a risk factor for future recurrence of epithelial ingrowth.^[5] Preoperative slit-lamp marking of the flap edge or intraoperative retroillumination in a dilated pupil may help to delineate the circumference of the LASIK flap during surgery. We describe a simple dimple-down procedure that helps to delineate the LASIK flap edge without damaging the surrounding stroma or epithelium. iOCT provides real-time guidance in entering the correct corneal plane beneath the LASIK flap and prevents inadvertent creation of false stromal passages. The flap was lifted only in a localized region without disturbing the remaining interface. Intraoperative OCT helped in the visualization of real-time surgical dynamics, and we could directly observe the removal of epithelial cells in the correct plane with minimal collateral damage of the underlying stroma or underside of the flap. The flap apposition was confirmed with an iOCT, and the presence of interface fluid necessitated further corneal massage and smoothing of the flap to ensure complete apposition. iOCT aids in decision making regarding the need for additional interventions after removal of epithelial ingrowth, including corneal massage,

sutures, or tissue adhesives, in order to ensure complete apposition and closure of any potential tracks. We did not suture the flap as a well-apposed flap without any potential interface space was observed after corneal massage. iOCT helps prevent unnecessary interventions and helps modify the iatrogenic factors associated with a recurrence of ingrowth. We did not observe any recurrence till over seven months of follow-up.

One of the limitations of the technique is the lack of widespread availability of microscope-integrated iOCT systems and their prohibitive cost. Nd: YAG laser is a noninvasive method for management of epithelial ingrowth; however, it has limited applicability in cases with localized peripheral ingrowth, and its therapeutic efficacy as compared with conventional management techniques needs to be further evaluated.

Conclusion

To conclude, our technique of iOCT guided management of post-LASIK epithelial ingrowth enables real-time dynamic monitoring of intraoperative surgical steps, aids in decision making regarding completion of ingrowth removal, and allows precise surgical dissection with minimal intraoperative manipulations. Optimal visual and anatomical outcomes may be achieved with the complete removal of epithelial cell nests. iOCT helps to minimize the modifiable risk factors associated with the development of epithelial ingrowth and may help to decrease the incidence of recurrence.

Financial support and sponsorship

Nil.

Conflicts of interest

There are no conflicts of interest.

References

1. Schallhorn SC, Venter JA, Hannan SJ, Hettinger KA, Teenan D, et al. Flap lift and photorefractive keratectomy enhancements after primary laser *in situ* keratomileusis using a wavefront-guided ablation profile: Refractive and visual outcomes. *J Cataract Refract Surg* 2015;41:2501-12.
2. Caster AI, Friess DW, Schwendeman FJ. Incidence of epithelial ingrowth in primary and retreatment laser *in situ* keratomileusis. *J Cataract Refract Surg* 2010;36:97-101.
3. Mohamed TA, Hoffman RS, Fine IH, Packer M. Post-laser assisted *in situ* keratomileusis epithelial ingrowth and its relation to pretreatment refractive error. *Cornea* 2011;30:550-52.
4. Ting DSJ, Srinivasan S, Danjoux J-P. Epithelial ingrowth following laser *in situ* keratomileusis (LASIK): Prevalence, risk factors, management and visual outcomes. *BMJ Open Ophthalmol* 2018;3:e000133.
5. Wang MY, Maloney RK. Epithelial ingrowth after laser *in situ* keratomileusis. *Am J Ophthalmol* 2000;129:746-51.
6. Henry CR, Canto AP, Galor A, Vaddavalli PK, Culbertson WW, Yoo SH. Epithelial ingrowth after LASIK: clinical characteristics, risk factors, and visual outcomes in patients requiring flap lift. *J Refract Surg* 2012;28:488-92.
7. Titiyal JS, Kaur M, Nair S, Sharma N. Intraoperative optical coherence tomography in anterior segment surgery. *Surv Ophthalmol* 2021;66:308-26.
8. Ehlers JP, Goshe J, Dupps WJ, Kaiser PK, Singh RP, Gans R, et al. Determination of feasibility and utility of microscope-integrated optical coherence tomography during ophthalmic surgery: The DISCOVER Study RESCAN Results. *JAMA Ophthalmol* 2015;133:1124-32.
9. Venkateswaran N, Galor A, Wang J, Karp CL. Optical coherence tomography for ocular surface and corneal diseases: A review. *Eye Vis* 2018;5:13.
10. Wilde C, Messina M, Dua HS. Management of recurrent epithelial ingrowth following laser *in situ* keratomileusis with mechanical debridement, alcohol, mitomycin-C, and fibrin glue. *J Cataract Refract Surg* 2017;43:980-4.