

Contents lists available at [ScienceDirect](http://www.sciencedirect.com)

International Journal of Surgery Case Reports

journal homepage: www.casereports.com

Karydakis flap for post-proctectomy perineal sinus: A case series and review

S. Au^{a,*}, L.H. Moyes^a, J.R.C. Telfer^b, J.H. Anderson^a^a Department of Colorectal Surgery, Glasgow Royal Infirmary, 84 Castle Street, Glasgow G4 0SF, United Kingdom^b Department of Plastic Surgery, Glasgow Royal Infirmary, 84 Castle Street, Glasgow G4 0SF, United Kingdom

ARTICLE INFO

Article history:

Received 21 March 2016

Accepted 19 April 2016

Available online 21 April 2016

Keywords:

Karydakis procedure

Perineal sinus

Perineal wound

Crohn's disease

Case series

ABSTRACT

INTRODUCTION: Persistent perineal sinus (PPS) may occur in up to 38% of patients undergoing proctectomy. The available therapeutic options range from simple but ineffective to relatively successful but complex. The Karydakis procedure is a straightforward day-case operation, commonly performed by general surgeons in the treatment of pilonidal disease, a not dissimilar pathology to PPS. This report is the first in the literature describing the use of Karydakis procedure in patients who developed PPS after proctectomy for Crohn's disease.

PRESENTATION OF CASE: Two patients, both of whom suffered from Crohn's disease and a PPS, underwent a Karydakis procedure as first-line treatment for PPS. Case 1 had a relatively superficial PPS while Case 2 had a deeper, more complex and longstanding PPS. Both patients had no post-operative complications and were discharged on the same day. They achieved complete healing in eight weeks and eight months respectively. The follow up range was 8–16 months.

DISCUSSION: Various techniques, including complex myocutaneous flap reconstruction, have been described in the literature to treat PPS. In contrast to these complex techniques, Karydakis operation is a simple day case procedure that was successful in treating PPS in our patients. While there is robust data regarding low recurrence rates following a Karydakis flap for pilonidal disease, there is no existing data for the indication outlined in this report.

CONCLUSION: While it requires further assessment, the Karydakis operation has potential as a simple, safe and effective first-line treatment in selected patients with PPS while not precluding more complex operative options in the future.

© 2016 The Authors. Published by Elsevier Ltd. on behalf of IJS Publishing Group Ltd. This is an open access article under the CC BY-NC-ND license (<http://creativecommons.org/licenses/by-nc-nd/4.0/>).

1. Introduction

A persistent perineal sinus (PPS) is a perineal wound that fails to heal more than six months after proctectomy [1]. Its incidence can be as high as 33% and it is more prevalent in inflammatory bowel disease (IBD), especially in Crohn's disease [2,3].

Currently, a plethora of treatments are employed in the management of PPS. These range from simple therapies, such as wound care and curettage, to complex procedures, such as abdominoperineal excision of sinus with coccygectomy and myocutaneous flap reconstruction. Simple procedures may fail to excise the sinus or obliterate dead space and tend to lack efficacy. In contrast, the more invasive options can be complicated by significant morbidity and prolonged recovery: outcome is variable (Table 1). Indeed, there is little progress in the management of this troublesome condition.

In the management of pilonidal sinus, a not dissimilar pathology, the most recent Cochrane review has acknowledged that primary healing is enhanced by off-midline closure and flattening the natal cleft utilising techniques such as the Karydakis flap [10]. To date, Karydakis flap has not been reported as a treatment for PPS. We describe the use of a Karydakis flap to treat two patients, both of whom suffered from Crohn's disease and a PPS.

2. Cases

2.1. Case 1

DO was diagnosed with Crohn's disease in 1979 (aged 15) and underwent a subtotal colectomy and end-ileostomy for acute colitis in 2003 (aged 39). He developed anal stenosis requiring proctectomy in 2014 (aged 49). He then developed a PPS in the middle of his perineal wound. EUA showed that the sinus was 1 cm deep and did not involve other structures.

A Karydakis procedure was performed three months after proctectomy according to the method described in Karydakis' original

* Corresponding author.

E-mail address: stephanieau@gmail.com (S. Au).

Table 1
Previous series on different treatments of persistent perineal sinuses published in the last 10 years.

Treatment	Author	Year of Publication	No. of patients	Complete healing rate	Follow up period
10% metronidazole ointment	Maeda et al. [4]	2007	4	25%	2 months
Cleft closure	Branagan et al. [5]	2006	8	88%	mean: 43.9 months
Rectus abdominis muscle/myocutaneous flap	Collie et al. [6]	2005	11	100%	3 months
Rectus abdominis flap and hyperbaric oxygen therapy	Menon et al. [7]	2005	2	50%	2 years
Gracilis transposition	Chan et al. [8]	2014	4	100%	median:2.5 months
Gluteus maximus flap	Collie et al. [6]	2005	5	20%	3 months
	Menon et al. [7]	2005	7	58%	2 years
	Maeda et al. [7]	2011	18	61%	median:64 months
Omental transposition	Prudhomme et al. [9]	2006	4	100%	median: 100 months
	Menon et al. [7]	2005	8	88%	2 years

**Series yielded on Pubmed with the keywords “persistent perineal sinus”.

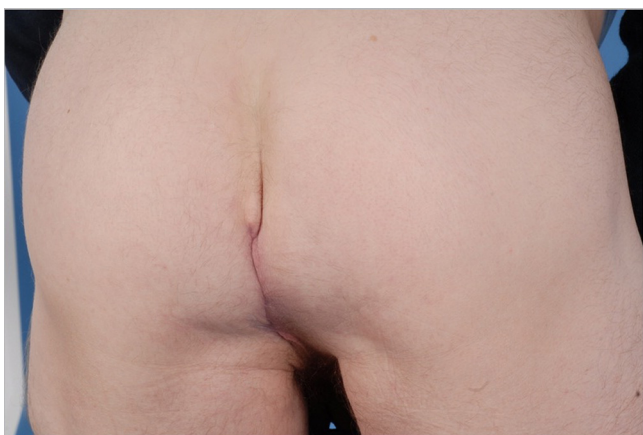


Fig. 1. Wound of case one eight-week post-operation.

paper [11]. The sinus was excised by an elliptical incision measuring 7 cm long and 4.4 cm wide. The wound was closed with a 2 cm wide and 1 cm thick Karydakias flap, moving the wound 2 cm to the left of midline. There were no post-operative complications and he was discharged the same day. His wound was completely healed at eight weeks after surgery (Fig. 1) and he was discharged from clinic. He was asymptomatic with no recurrence on review 16 months post-operation.

Table 2
Patient characteristics and results.

	Case 1–DO	Case 2–RA
Primary diagnosis	Crohn’s disease	Crohn’s disease
Age at diagnosis	15	16
Age at proctectomy	49	21
Age at sinus development	49	21
Any previous sinus surgery	No	No
Age at Karydakias	49	26
Dimension of sinus/sinus complex	2 cm long, 1 cm deep	8 cm long, deep to tip of coccyx
Dimension of excision	7 cm long × 4.4 cm wide ellipse	14 cm long × 5 cm wide ellipse
Anaesthesia	General	General
Prophylactic antibiotics on induction	single shot of co-amoxiclav	single shot of co-amoxiclav
Duration of operation	2 hours	2 hours
Length of hospital stay	1 day (day case)	1 day (day case)
Results	Complete healing on 8 week review and discharged from clinic. No recurrence on review 16 months post-operation	Complete healing on 8 month review and discharged from clinic

2.2. Case 2

RA (aged 16) had an ileoanal pouch with loop-ileostomy performed for IBD in 2004. Subsequent pathology demonstrated Crohn’s disease. Five years later he developed a pouch-urethral fistula requiring excision of pouch, proctectomy and end-ileostomy. He was then troubled with persistent discharge from multiple PPS for five years. Clinical examination revealed four PPS extending over 8 cm. MRI confirmed that the sinus was superficial and there was no urethral fistula recurrence.

A Karydakias procedure was performed as described in Karydakias’ original paper [11]. The sinuses was found extended down to the coccyx and a 14 cm (length) by 5 cm (width) ellipse centred 2 cm to the left of the midline was excised. This was performed without complication and he was discharged on the same day. At eight week clinic review, his wound had healed apart from a 1 mm opening with no associated inflammation. His wound was completely healed at eight month and he was discharged from clinic (Table 2).

3. Discussion

A recent systemic review on management of PPS with myocutaneous flaps reported healing rates of 64% for gracilis flaps and 84% for rectus flaps [12]. However, rectus flaps involve a combined abdominoperineal approach which results in longer operating times and may make further abdominal operations in young patients with IBD more challenging. Abdominal wall may be weakened, leading to the development of incisional hernia [7].

3.1. Application of Karydakis procedure

In contrast to these complex techniques, the Karydakis operation is a straightforward day case procedure. Not only can it be a successful first-line treatment for superficial sinuses as in Case 1, but it may also be effective in deeper, more complex and longstanding sinuses as in Case 2. In both cases, it may have been feasible to perform radical excision and primary closure, but the healing rate would have been poor at 38% [13]. Another advantage of using a Karydakis flap is that anatomical planes are not disturbed, so the availability of other treatments, such as myocutaneous flaps, is not restricted should the sinuses persist or recur.

To our knowledge, this is the first report in the literature where a Karydakis flap has successfully treated a PPS in patients with IBD. While there is robust data regarding low recurrence rates following a Karydakis flap for pilonidal disease, there is no existing data for the indication outlined in this report [14].

It is relevant to note that a case series of eight patients who underwent modified cleft closure for PPS reported encouraging results [5]. All wounds in the case series eventually healed, although one required a second cleft closure. In contrast to the Karydakis technique, the cavity was not excised in cleft closure. Therefore, it is uncertain whether cleft closure would be as successful when applied onto deep sinuses, though there is no evidence that directly compare the efficacy of both techniques in the treatment of pilonidal sinuses.

Both of the patients in the present report had a relatively superficial sinus. Some PPS can extend deep into the pelvis and may be adherent to the sacrum and in proximity to intestine. Whether a Karydakis flap would be appropriate for such challenging patients has not been determined.

In the quest for the best treatment of PPS, studies with longer follow-up and larger numbers are undoubtedly required. However, this would be difficult as the numbers going through an individual unit are often small with the largest series comprising 48 patients only [15]. Further, follow-up probably requires to be at least 5 years to capture recurrence [14] whereas the majority of the series published currently has a follow-up period of less than three years, and thus preliminary reports are valuable.

4. Conclusion

The two cases illustrated in this report show that the Karydakis procedure, which is simple and widely performed, can be used to treat complex PPS with success. Although more robust evidence needs to be gathered, it is a safe surgical option to perform as first-line management and, where it should fail, it does not preclude more complex operative options.

Consent

Written informed consent was obtained from all the patient for publication of this case report and accompanying images. A copy of the written consent is available for review by the Editor-in-Chief of this journal on request.

Conflicts of interest

None.

Funding

None.

Ethical approval

None.

Author contribution

SA performed literature review and wrote the paper. JHA performed the procedures. All authors reviewed final submission.

Guarantor

John Anderson.

References

- [1] J. Watts, F. Dombal, J. Goligher, Long-term complications and prognosis following major surgery for ulcerative colitis, *Br. J. Surg.* 53 (12) (1966) 1014–1023.
- [2] V. Lohsirwat, Persistent perineal sinus: incidence, pathogenesis, risk factors and management, *Surg. Today* 39 (3) (2009) 189–193.
- [3] M. Corman, M. Veidenheimer, J. Collier, V. Ross, Perineal wound healing after proctectomy for inflammatory bowel disease, *Dis. Colon Rectum* 21 (3) (1978) 155–159.
- [4] Y. Maeda, V. Lohsirwat, S. Clark, Effects of topical administration of 10% metronidazole ointment on long-standing persistent perineal sinus: a pilot study, *Colorectal Dis.* 9 (suppl. 3) (2007) 55.
- [5] G. Branagan, M. Thompson, A. Senapati, Cleft closure for the treatment of unhealed perineal sinus, *Colorectal Dis.* 4 (2006) 314–317.
- [6] M. Collie, M. Potter, D. Bartolo, Myocutaneous flaps promote perineal healing in inflammatory bowel disease, *Br. J. Surg.* 92 (6) (2005) 740–741.
- [7] A. Menon, M. Clark, T. Shatari, C. Keh, M. Keighley, Pedicled flaps in the treatment of non-healing perineal wounds, *Colorectal Dis.* 7 (2005) 441–444.
- [8] X. Chan, C. Koh, M. Glover, P. Bryson, S. Travis, N. Mortensen, Healing under pressure: hyperbaric oxygen and myocutaneous flap repair for extreme persistent perineal sinus after proctectomy for inflammatory bowel disease, *Colorectal Dis.* 16 (3) (2014) 186–190.
- [9] M. Prudhomme, N. Dehni, R. Dozois, E. Turet, R. Parc, Causes and outcomes of pouch excision after restorative proctocolectomy, *Br. J. Surg.* 93 (1) (2006) 82–86.
- [10] I.J.D. McCallum, P.M. King, J. Bruce, Healing by primary versus secondary intention after surgical treatment for pilonidal sinus, *Cochrane Database Syst. Rev.* 4 (2007) (CD006213).
- [11] G. Karydakis, New approach to the problem of pilonidal sinus, *Lancet* 2 (7843) (1973) 1414–1415.
- [12] T.R. Wilson, H. Welbourn, P. Standley, J. Hartley, The success of rectus and gracilis muscle flaps in the treatment of chronic pelvic sepsis and persistent perineal sinus: a systemic review, *Colorectal Dis.* 16 (10) (2014) 751–759.
- [13] T. Yamamoto, I. Bain, R. Allan, M. Keighley, Persistent perineal sinus after proctocolectomy for Crohn's disease, *Dis. Colon Rectum* 42 (1) (1999) 96–101.
- [14] T. Allen-Mersh, Pilonidal sinus: finding the right track for treatment, *Br. J. Surg.* 77 (2) (1990) 123–132.
- [15] R. Anderson, R.J. Turnbull, Grafting the unhealed perineal wound after coloproctectomy for Crohn disease, *Arch. Surg.* 111 (4) (1976) 335–338.

Open Access

This article is published Open Access at sciendoirect.com. It is distributed under the [IJSCR Supplemental terms and conditions](#), which permits unrestricted non commercial use, distribution, and reproduction in any medium, provided the original authors and source are credited.