

Case Report

Fibromyalgia and arachnoiditis presented as an acute spinal disorder

Zamzuri Idris^{1,2}, Faizul H. Ghazali², Jafri M. Abdullah^{1,2}

¹Center for Neuroscience Service and Research, ²Department of Neurosciences, School of Medical Sciences, Universiti Sains Malaysia, Kubang Kerian, 16150 Kelantan, Malaysia

E-mail: *Zamzuri Idris - neuroscienceszamzuri@yahoo.com, Faizul H. Ghazali - dr_leyz@yahoo.com, Jafri M. Abdullah - brainsciences@gmail.com

*Corresponding Author

Received: 26 March 14 Accepted: 27 June 14 Published: 21 October 14

This article may be cited as:

Idris Z, Ghazali FH, Abdullah JM. Fibromyalgia and arachnoiditis presented as an acute spinal disorder. *Surg Neurol Int* 2014;5:151.

Available FREE in open access from: <http://www.surgicalneurologyint.com/text.asp?2014/5/1/151/143364>

Copyright: © 2014 Idris Z. This is an open-access article distributed under the terms of the Creative Commons Attribution License, which permits unrestricted use, distribution, and reproduction in any medium, provided the original author and source are credited.

Abstract

Background: Adhesive arachnoiditis is a chronic, insidious condition that causes debilitating intractable pain and a range of other neurological problems. Its pathophysiology is not well understood. This manuscript discusses its presentations, which can mimic an acute spinal disorder, its hypothetical pathophysiology, treatment, and its relationship with fibromyalgia.

Case Description: The authors present a case of a 47-year-old female who presented with clinical features mimicking an acute spinal disorder but later found to have an adhesive arachnoiditis. She was admitted following a trauma with complaints of back pain and paraplegia. On examination, there was marked tenderness over thoracolumbar spine with lower limbs upper motor neuron weakness. An urgent magnetic resonance imaging (MRI) of the spine revealed multiple lesions at her thoracic and lumbar spinal canals, which did not compress the spinal cord. Therefore, conservative management was initiated. Despite on regular therapies, her back and body pain worsened and little improvement in her limbs power was noted. Laminectomy was pursued and found to have spinal cord arachnoiditis. Subsequently, she was operated by other team members for multiple pelvic masses, which later proved to be benign. After gathering all the clinical information obtained at surgery and after taking detailed history inclusive of cognitive functions, diagnosis of an adhesive arachnoiditis syndrome was made. Currently, she is managed by neuropsychologist and pain specialist.

Conclusion: This case report highlights the importance of knowing an adhesive arachnoiditis syndrome – a rarely discussed pathology by the neurosurgeon, which discloses a significant relationship between immune and nervous systems.

Key Words: Arachnoiditis, autoimmune disease, fibromyalgia, greater limbic system, spinal disorder, spinal trauma

Access this article online

Website:

www.surgicalneurologyint.com

DOI:

10.4103/2152-7806.143364

Quick Response Code:



INTRODUCTION

An acute spinal disorder commonly presents as an emergency. Examples of acute spinal disorders are fractured

trauma, intraspinal hematomas, and abscess.^[12,16,19,23] Those normally require urgent surgery to decompress the pathology. Rarely, accidental trauma can aggravate the preexisting disease such as chronic adhesive arachnoiditis

syndrome and mimic an acute traumatic spinal disorder. We report an interesting case who presented to us with an acute spinal disorder and later found to suffer from chronic adhesive arachnoiditis syndrome. Currently, limited publications only available in the literature regarding adhesive arachnoiditis syndrome and involvement of the central nervous system (CNS) or/and immune system.^[11,17,24] In regard to its pathophysiology, we propose a hypothetical model that includes: (a) Brain, spinal cord, and nerve endings; (b) immune, and (c) visceromusculoskeletal system, which is based on the current literatures and findings from our patient.

CASE REPORT

A 47-year-old female with background history of heavy consumption of alcohol at younger age initially presented to us with an acute back pain at the lower thoracic and upper lumbar spines, which was associated with an acute onset of paraparesis with Medical Research Council (MRC) power of 1, paraesthesia and discomfort at voiding following a traumatic event during travelling on a speed boat to an island at a time of heavy waves season. The urgent magnetic resonance imaging (MRI) of the thoracolumbar spine disclosed an abnormal sizeable mixed hypo- and hyperintensed lesions on T1 and T2 [Figure 1a-c] at multiple spinal levels. Eccentrically, the lesions did not seem to cause compressive effect onto the spinal cord. The conservative management was opted after noting the harmless looking lesions on the MRI. Two weeks of regular analgesia and physiotherapy in neurointensive care were given, but the lower limbs weakness recovered partially to grade 3 with more intense pain at the back. She remained bed bound and was unable to urinate and therefore was catheterized. At the same time she started to complain of right subcostal and lower pelvic pain, which were tender; further investigation revealed two cystic lesions in the liver and her ovaries.

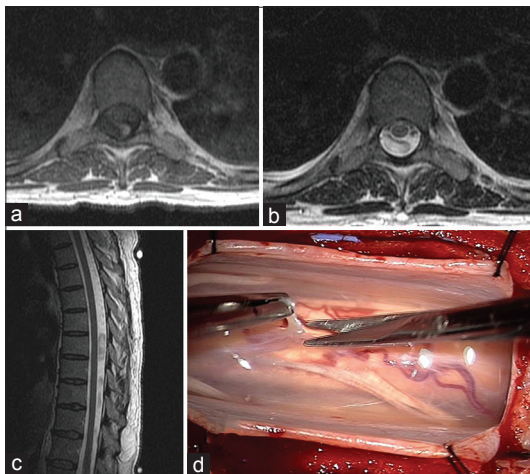


Figure 1: (a-c) The mixed hypo- and hyperintensed signals of multiple lesions inside the spinal canal. (d) An intraoperative finding of an arachnoiditis

Our initial provisional diagnosis was either a traumatic or vascular malformation-induced spinal hematoma, or spinal metastases. Nonetheless, history did not favor the second provisional diagnosis. Since the recovery was partial and the diagnosis was doubtful, we decided to proceed with laminectomy at lesional site of T9-T11.

Laminectomy was completed from T9 to T11 and the intraoperative finding is shown in Figure 1d. The histopathological diagnosis was arachnoiditis. The surgery was uneventful and she was discharged home with regular follow-ups. One month after the spinal surgery, the abdominal and pelvic pain became more frequent and tenderness was noted mainly at pelvic area. She was operated endoscopically by the gynecologist and biopsy was taken from her cysts. The histopathological results were benign cysts. After her second surgery, her back pain subsided but she became ataxic with positive Romberg's test (she did have normal serum vitamin B12 and iron), experience muscles tenderness, and pain from her neck down. The pain was particularly severe at pelvic, buttocks, and flanks of abdomen. Further questioning, revealed her other significant symptoms, which prompted us to make a final diagnosis of adhesive arachnoiditis syndrome, those additional symptoms were forgetfulness, problems with concentration, fatigue, cystitis-like symptoms, dyspareunia, pain and stiffness in the joints, dry mouth and skin, inadequate sleep, and recurrent headache. The MRI, inclusive of diffusion tensor imaging (DTI) and tractography of the brain, was done after laminectomy surgery, which revealed no brain lesion but marked increment in fractional anisotropy (FA) and fibers density in both thalamus when compared with a healthy control [Figure 2] and abnormal signal densities in the basal arachnoid spaces. Currently, she is being treated by neuropsychologist and pain specialist.

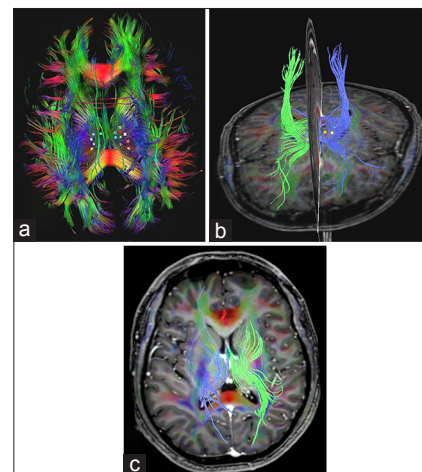


Figure 2: (a and b) Patient's diffusion tensor imaging and tractography disclosed marked increased in fibers density and also fractional anisotropy (FA values) at both thalamus when compared with a healthy subject of nearly similar age (c). The mean FA values for right and left thalamus for the patient were 0.450 and 0.457, whereas for the control were 0.391 and 0.395, respectively

DISCUSSION

This is a complex and confusing case in such a way that neurosurgeons hardly have much exposure on clinical syndrome called ‘an adhesive arachnoiditis syndrome’. Pain is such a common presentation for this condition, but when it is associated with focal neurological deficits, such as limbs weakness and bladder disturbances, urgent imaging is often indicated. However, musculoskeletal and spinal imagings can be misleading to the clinicians who are ignorant of adhesive arachnoiditis syndrome. In this patient, the spinal neuroimaging (MRI) obviously did not show any compressive effect onto the spinal cord and there was no bony fracture or abnormality, therefore the initial conservative management should have been continued despite slow improvements in muscles power. Lack of knowledge in arachnoiditis syndrome among the clinicians is an obvious reason for her to have multiple surgeries. More diffused and global pain with marked muscles tenderness (misinterpreted as guarding) should have alerted the clinicians toward more chronic pain pathology and neurosurgeon should have been aware and able to correlate the initial histopathological spinal arachnoiditis findings with adhesive arachnoiditis syndrome. Obviously, this case is not a simple case because clinical features of persistent pelvic and abdominal pain and tenderness as well as cystitis-like syndrome with abnormal radiological findings of multiple cystic lesions in the liver and ovaries and abnormal spinal MRIs had also misled the managing teams to proceed with an endoscopic surgery. Unnecessary surgeries though could have been avoided if all the involved clinicians were aware and had sufficient knowledge in this syndrome; in fact, unnecessary spinal surgery in an arachnoiditis patient can cause exacerbation of the condition via activation of already abnormal nociception and peripheral nerve transmission.

Adhesive arachnoiditis syndrome: What is it

The pathophysiology for chronic adhesive arachnoiditis is not completely understood. Arachnoiditis is chronic inflammation of the arachnoid layer of the meninges. Agents that trigger inflammation include direct inoculation such as dye, medications for spinal procedures, blood during the surgery or after subarachnoid hemorrhage, and possibly systemic inoculation via body toxin overload.^[9,10,21,25] This chronic red-alert situation then seems to trigger autoimmune problems presumably via neuroimmunomodulation. These abnormal immune responses (resulted from direct and systemic inoculation for arachnoiditis) may cause various body dysfunctions, such as disturbance in autonomic-hormonal system via its linked cytokines (e.g, blood) with hypothalamic-pituitary and sympathetic nervous systems or via alterations in signals for ascending and descending tracts or via alteration in cerebrospinal fluid (CSF) flow and chemical

contents.^[21] An acute trauma (a common trigger event) may lead to a ‘shock syndrome’ that causes outpouring of the entire autonomic nervous system, and via its connections with greater limbic system (via blood or CSF-note that the greater limbic system is actually surrounded by the CSF ventricular and arachnoidal spaces, which consists of thalamus, hypothalamus, amygdala, hippocampus, basal forebrain nuclei, and classical reticular system), central sensitization process can take place and lead to various neurocognitive symptoms.^[5,6,14,15] Besides blood and CSF, these central sensitization processes (in the brain) are also thought to be originating from a disruption of the pain ascending and descending systems and involving the pain transmission pathways and also the immune system-particularly the microglia and cytokines.^[2,3,20] Microglia are immune cells inside the brain and spinal cord, they can be in one of three states: Resting, hypersensitive, or activated. In healthy people, the microglia are in default state of resting, but in arachnoiditis, the microglia are hypothesized to be in a hypersensitive and easily activated states. Their activation would produce proinflammatory or neurotoxic factors such as cytokines (interleukins 6, 8) and substance P that lead to various clinical manifestations and even clinical syndromes such as Sjogren’s syndrome, Hashimoto’s thyroiditis, and arachnoiditis and thus seem to manifest as a vicious circle and can be fluctuating in severity of the symptoms.^[21] As in our presented case, trauma and possibly subsequent spinal surgery (laminectomy) and adhesive arachnoiditis may have some correlations-the physical and psychological injury could lead to activated states of already abnormal nociceptors and peripheral nerves (possibly due to compressive or ischemic effects of already presence chronic arachnoiditis). Indeed, trauma or surgery has been observed to spark the progression of this disease.^[1,18] Progression of the disease involves not only the peripheral nervous system but also the centrally located cores and paracores of the brain structures or better known as the greater limbic system as discussed above. Interestingly, abnormalities were noted at the thalamus on our patient’s DTI and tractography [Figure 2] when compared with a healthy control. This finding could support a notion that the thalamus (part of the greater limbic networks) is involved in central sensitization and amplification for adhesive arachnoiditis syndrome.^[7,8]

Regarding arachnoiditis in our patient, it seems unlikely that acute trauma (direct inoculation of noxious agent) is causing the arachnoiditis (secondary arachnoiditis). The MRI done within one day of trauma did not favor acute blood clots because of their signals, multiple and inside the arachnoid spaces, which did not cause cord compression. Therefore, theory of resolving acute hematomas that leads to arachnoiditis cannot be entertained. The arachnoiditis seems likely to have been existing long before the history of boat trauma. The

etiology for this spontaneous or primary arachnoiditis is unknown. This is possibly related to an autoimmune disorder that links it (via blood) with chronic arachnoiditis (i.e., systemic inoculation-toxin overload). Noteworthy that some patients who suffer from autoimmune disorders such as Sjogren's syndrome, systemic lupus erythematosus do have clinical features associated with this syndrome or fibromyalgia.^[21] Our intraoperative findings of diffused spontaneous arachnoiditis [Figure 1d] covering the spinal cord is in agreement with current hypothesis regarding the etiology for this syndrome, which could encompass a 'more global pathophysiology'.^[21] Figure 3 shows our hypothetical model for adhesive arachnoiditis syndrome that portrayed involvement of three important systems: Central nervous (greater limbic system via central sensitization and amplification), immune systems (hypersensitized microglia, cytokines, neurotoxic factors), and visceromusculoskeletal system (painful/tender areas).

Treatment for adhesive arachnoiditis syndrome and its relationship with fibromyalgia

Managing adhesive arachnoiditis syndrome requires multidisciplinary approach.^[13,21,28] Treatment encompasses pharmacological, behavioral, cognitive and physical therapies, hormonal, nutritional, acupuncture, and rarely surgery such as adhesiolysis, shunting or nerve, cord, or brain stimulation surgery. The pharmacological treatment can be low-dose naltrexone (2-6 mg nightly), which is thought to prevent microglia activation. Pregabalin (Lyrica) is another option but it tends to cause weight gain and water retention side effects. Other medications are duloxetine (Cymbalta), milnacipran (Savella), and amitriptyline, which can potentiate the analgesic effect of opioids. Behavioral and relaxation therapies such as hypnosis or meditation were found useful in alleviating chronic neuropathic pain.

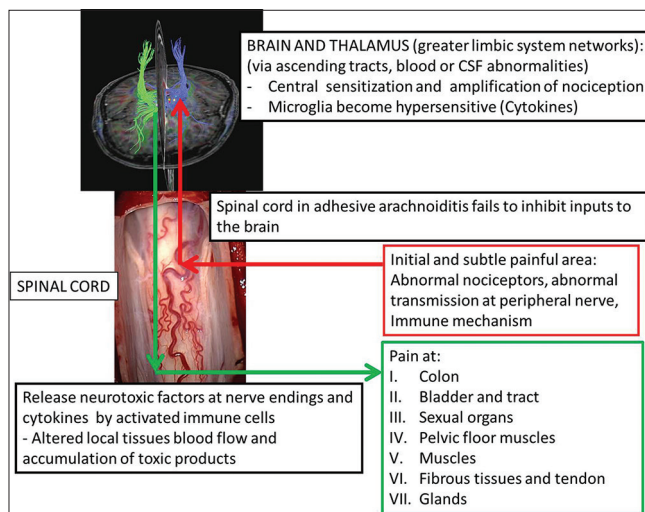


Figure 3: A hypothetical model for adhesive arachnoiditis syndrome, which involves the central nervous, immune and visceromusculoskeletal systems

Physiotherapy may not be good to the patient because of the muscles tenderness and pain involving some joints. Other relevant methods include transcutaneous electrical nerve stimulation, chemical adhesiolysis, change in lifestyles (stopping smoking, by planning, or reducing the stressors) and diet (omega-3 oils, herbs, supplements), symptomatic treatment (such as oxybutynin for sexual and bladder functions) and finally spinal cord or brain stimulation with low energy current is used to block the transmission of pain signals.

Currently, 'adhesive arachnoiditis syndrome' is rarely being discussed among clinicians. This is not because of its rarity but possibly because of ignorance, lack of extensive research for this condition and possibly wrong labeling of the patients suffering from 'adhesive arachnoiditis syndrome' with other clinical conditions such as fibromyalgia, failed back surgery syndrome, failed back syndrome, or chronic spinal meningitis. Fibromyalgia is also known as fibrositis. The term fibromyalgia is widely used nowadays and means pain in muscles and fibrous tissues. The pain has specific feature that is global or widespread in nature and often associated with marked muscles or tendon tenderness. Additional sources of pain are abdominal (muscles and colon), pelvic organs (pelvic girdles, urinary, and sexual organs), headache, eye pain, and sore throat. Chronic and widespread pain of muscle origin are reflected in the American College of Rheumatology (ACR) criteria to properly diagnose fibromyalgia.^[26,27] The ACR criteria requires that: (a) Symptoms have been present for at least 3 months; and (b) 11 sites of a specified 18 sites be tender (but the extent of muscle tenderness may vary over time and could be less than 11 at certain point in time). Fibromyalgia is also commonly associated with a number of other symptoms such as disturbance in memory, concentration, mood and sleep, fatigue, depression, cystitis-like symptoms, irritable bowel syndrome, dyspareunia, morning stiffness, dry mouth and skin, and headache.^[4,22] Features highlighted above are also features of 'adhesive arachnoiditis syndrome.' Dr. Sarah Smith, a patron for the arachnoiditis support group did an extensive review on this syndrome in 2003 and stated "fibromyalgia, which is a non-specific condition, could indeed be part of the arachnoiditis syndrome."^[21] Therefore for those labeling patient as suffering from fibromyalgia may in fact suffer from chronic 'adhesive arachnoiditis syndrome.'

CONCLUSION

Adhesive arachnoiditis syndrome is a chronic disease, which implicates nervous, immune, and visceromusculoskeletal systems as important entities in its pathophysiology. Interestingly, its presentation can mimic an acute spinal disorder. Therefore, treating neurosurgeon should be more aware of this syndrome;

and practice taking detailed clinical history, do thorough physical examination, and caution in interpreting results of neuroinvestigations.

REFERENCES

- Austin JW, Afshar M, Fehlings MG. The relationship between localized subarachnoid inflammation and parenchymal pathophysiology after spinal cord injury. *J Neurotrauma* 2012;29:1838-49.
- Behm FG, Gavin IM, Karpenko O, Lindgren V, Gaitonde S, Gashkoff PA, et al. Unique immunologic patterns in fibromyalgia. *BMC Clin Pathol* 2012;12:25.
- Cavanaugh JM. Neural mechanisms of lumbar pain. *Spine (Phila Pa 1976)* 1976;20:1804-9.
- Clauw DJ, Arnold LM, McCarberg BH. The science of fibromyalgia. *Mayo Clinic Proc* 2011;86:907-11.
- Desmeules J, Chabert J, Rebsamen M, Rapiti E, Piguat V, Besson M, et al. Central Pain Sensitization, COMT Val158Met Polymorphism, and Emotional Factors in Fibromyalgia. *J Pain* 2014;15:129-35.
- Desmeules JA, Cedraschi C, Rapiti E, Baumgartner E, Finckh A, Cohen P, et al. Neurophysiologic evidence for a central sensitization in patients with fibromyalgia. *Arthritis Rheum* 2003;48:1420-9.
- Gracely RH, Petzke F, Wolf JM, Clauw DJ. Functional magnetic resonance imaging evidence of augmented pain processing in fibromyalgia. *Arthritis Rheum* 2002;46:1333-43.
- Hampson JP, Reed BD, Clauw DJ, Bhavsar R, Gracely RH, Haefner HK, et al. Augmented central pain processing in vulvodynia. *J Pain* 2013;14:579-89.
- Hayashi K, Nagano J, Hattori S. Adhesive arachnoiditis after percutaneous fibrin glue treatment of a sacral meningeal cyst. *J Neurosurg Spine* 2014;20:763-6.
- Kochany JZ, Tran ND, Sarria JE. Increasing back and radicular pain 2 years following intrathecal pump implantation with review of arachnoiditis. *Pain Med* 2013;14:1658-63.
- Koerts G, Rooijackers H, Abu-Serieh B, Cosnard G, Raftopoulos C. Postoperative spinal adhesive arachnoiditis presenting with hydrocephalus and cauda equina syndrome. *Clin Neurol Neurosurg* 2008;110:171-5.
- Kreppel D, Antoniadis G, Seeling W. Spinal hematoma: A literature survey with meta-analysis of 613 patients. *Neurosurg Rev* 2003;26:1-49.
- Mitsuyama T, Asamoto S, Kawamata T. Novel surgical management of spinal adhesive arachnoiditis by arachnoid microdissection and ventriculo-subarachnoid shunting. *J Clin Neurosci* 2011;18:1702-4.
- Nieuwenhuys R, Voogd, Huijzen CV. Greater limbic system. 4th ed. Wurzburg: Springer-Verlag; Berlin: Heidelberg; 2008.
- Nieuwenhuys R, Veening JG, van Domburg P. Core and paracores; some new chemoarchitectural entities in the mammalian neuraxis. *Acta Morphol Neerl Scand* 1988;26:131-63.
- O'Phelan KH, Bunney EB, Weingart SD, Smith WS. Emergency neurological life support: Spinal cord compression (SCC). *Neurocrit Care* 2012;17 Suppl 1:S96-101.
- Petty PG, Hudgson P, Hare WS. Symptomatic lumbar spinal arachnoiditis: Fact or fallacy? *J Clin Neurosci* 2000;7:395-9.
- Ramli N, Merican AM, Lim A, Kumar G. Post-traumatic arachnoiditis: An unusual cause of Brown-Sequard syndrome. *Eur Radiol* 2001;11:2011-4.
- Reihnsaus E, Waldbaur H, Seeling W. Spinal epidural abscess: A meta-analysis of 915 patients. *Neurosurg Rev* 2000;23:175-204.
- Rodriguez-Pinto I, Agmon-Levin N, Howard A, Shoenfeld Y. Fibromyalgia and cytokines. *Immunol Lett* 2014; Jan 23. pii: S0165-2478(14)00013-3. doi: 10.1016/j.imlet.2014.01.009. [Epub ahead of print].
- Sarah S. The Adhesive Arachnoiditis Syndrome. Patron of The Arachnoiditis Support Group, Knowsley (UK), COFWA, USA, ASAMS, New Zealand and CIAASA, Australia; October 2003. Available from: <http://www.cofwa.org/AASYNDROME-10-03.pdf>.
- Smith HS, Barkin RL. Fibromyalgia syndrome: A discussion of the syndrome and pharmacotherapy. *Am J Ther* 2010;17:418-39.
- Stein DM, Roddy V, Marx J, Smith WS, Weingart SD. Emergency neurological life support: Traumatic spine injury. *Neurocrit Care* 2012;17 Suppl 1:S102-11.
- Vaughan D, Bolger C, O'Brien DF. An interesting case of primary spinal arachnoiditis. *Br J Neurosurg* 2012;26:555-7.
- Whetstone KE, Crane DA. Cauda equina syndrome resulting from lumbar arachnoiditis after intracranial subarachnoid hemorrhage: A case report. *PM R* 2013;5:539-41.
- Wolfe F, Clauw DJ, Fitzcharles MA, Goldenberg DL, Katz RS, Mease P, et al. The American College of Rheumatology preliminary diagnostic criteria for fibromyalgia and measurement of symptom severity. *Arthritis Care Res* 2010;62:600-10.
- Wolfe F, Hauser W. Fibromyalgia diagnosis and diagnostic criteria. *Ann Med* 2011;43:495-502.
- Younger J, Mackey S. Fibromyalgia symptoms are reduced by low-dose naltrexone: A pilot study. *Pain Med* 2009;10:663-72.

Commentary

The discussion of this case presentation indicates that the patient's symptoms progressed from low back pain with lower extremity neurological symptoms to more widespread pain associated with multiple areas of muscle tenderness. The earlier symptom complex is consistent with the diagnosis, ultimately made, of adhesive arachnoiditis and the latter syndrome is clearly more consistent with the diagnosis of fibromyalgia. The earlier symptoms were limited to the back and lower extremities and not associated with multiple muscular tender points. Her past medical and psychosocial histories are not given, so the origin of an inflammatory condition of the spinal canal, such as prior bacterial, tubercular or fungal infection is not ruled out and a psychological source for some of her symptoms also remains specifically undiagnosed, although she did

have a prior history of excess alcohol use, which could play a role. The later syndrome with multiple muscle pain and tenderness is quite consistent with the diagnosis of fibromyalgia in which psychosocial issues have become notably prominent. She came under the care of a neuropsychologist so such issues were likely considered and accounted for during treatment. In such a circumstance past history, such as abuse during childhood often plays a major role and her gender is consistent with the fibromyalgia disorder.

As the authors suggest, a multidisciplinary approach to the patient's condition wherein the various surgeons treating her case regularly conferenced with the neuropsychologist and pain specialist also treating her may have reduced the number of operations she had carried out, and may have impacted on the ultimate

clinical outcome of her case. [1,2] So, the “take away” of the article is that awareness, especially on the part of surgical specialists, is essential to preparedness!

REFERENCES

1. Lempp HK(1), Hatch SL, Carville SF, Choy EH. Patients experiences of living with and receiving treatment for fibromyalgia syndrome: a qualitative

- study. *BMC Musculoskelet Disord.* 2009 Oct 7;10:124. doi: 10.1186/1471-2474-10-124.
2. Petzke F. CNS processing of pain in functional somatic syndromes. Article in *German Schmerz.* 2010;24:146-55. doi: 10.1007/s00482-010-0903-5.

Ron Pawl

Department of Neurosurgery, University of Illinois, Chicago, IL, USA
E-mail: Ron Pawl - ron@pawl.com