

## CASE REPORT

# Spontaneous intramedullary hematoma in a patient with COVID-19 infection: A case report

Masih Sabouri<sup>1</sup> | Majid Rezvani<sup>1</sup> | Bahram Aminmansour<sup>1</sup> | Arman Sourani<sup>1</sup>  |  
Sadegh Baradaran Mahdavi<sup>2</sup>

<sup>1</sup>Department of Neurosurgery, School of Medicine, Isfahan University of Medical Sciences, Isfahan, Iran

<sup>2</sup>Department of Physical Medicine and Rehabilitation, School of Medicine, Student Research Committee, Child Growth and Development Research Center, Research Institute for Primordial Prevention of Non-Communicable Disease, Isfahan University of Medical Sciences, Isfahan, Iran

## Correspondence

Arman Sourani, Department of Neurosurgery, School of Medicine, Isfahan University of Medical Sciences, Isfahan, Iran.

Email: armansourani@gmail.com

Sadegh Baradaran Mahdavi, Department of Physical Medicine and Rehabilitation, School of Medicine, Student Research Committee, Child Growth and Development Research Center, Research Institute for Primordial Prevention of Non-Communicable Disease, Isfahan University of Medical Sciences, Isfahan, Iran.

Email: sadegh.b.mahdavi@gmail.com

## Funding information

Not applicable

## Abstract

A 73-year-old man experienced four limb paresthesia and weakness following severe COVID-19 pneumonia. EMG-NCS showed inflammatory demyelinating polyneuropathy pattern while cervicothoracic imaging showed hematomyelia. The patient underwent laminectomy and hematoma evacuation. Neurological status improved to ASIA score C, postoperatively.

## KEYWORDS

COVID-19, hematomyelia, intramedullary hematoma, SARS-CoV-2, spinal cord diseases, spine surgery

## 1 | INTRODUCTION

Spontaneous intramedullary hematoma, also known as hematomyelia, is a rare clinical picture. Vascular malformations, tumors, using anticoagulants, bleeding disorders, and idiopathic etiologies are associated with this clinical condition.<sup>1-4</sup> Depending on the site and extension of the hematoma, major clinical manifestations include

sensory problems, paralysis, Brown-Sequard syndrome, sphincter dysfunction, or other neurological findings.<sup>2,4-6</sup>

Novel coronavirus 2019 (COVID-19) pandemic is a severe worldwide concern. Major clinical presentations of this virus are related to the respiratory system.<sup>7,8</sup> However, extrapulmonary manifestations are also common.<sup>9</sup> There are emerging reports of neurological associations of COVID-19 virus, including anosmia, ageusia,

Arman Sourani and Sadegh Baradaran Mahdavi contributed equally as corresponding authors.

Masih Sabouri considered as first author.

This is an open access article under the terms of the Creative Commons Attribution-NonCommercial-NoDerivs License, which permits use and distribution in any medium, provided the original work is properly cited, the use is non-commercial and no modifications or adaptations are made.

© 2022 The Authors. *Clinical Case Reports* published by John Wiley & Sons Ltd.

encephalitis, Guillen–Barre syndrome, and cerebrovascular diseases such as stroke.<sup>10</sup> In addition, there are recent reports of intracranial hemorrhage in patients with COVID-19 as well.<sup>11,12</sup> However, according to a literature review, intramedullary hematoma (hematomyelia) in the context of COVID-19 infection, has not been reported so far. In this case study, as the world first report, we describe an old man with the COVID-19 infection followed by hematomyelia and quadriplegia to underscore the importance of early diagnosis and treatment of patients with a similar clinical picture.

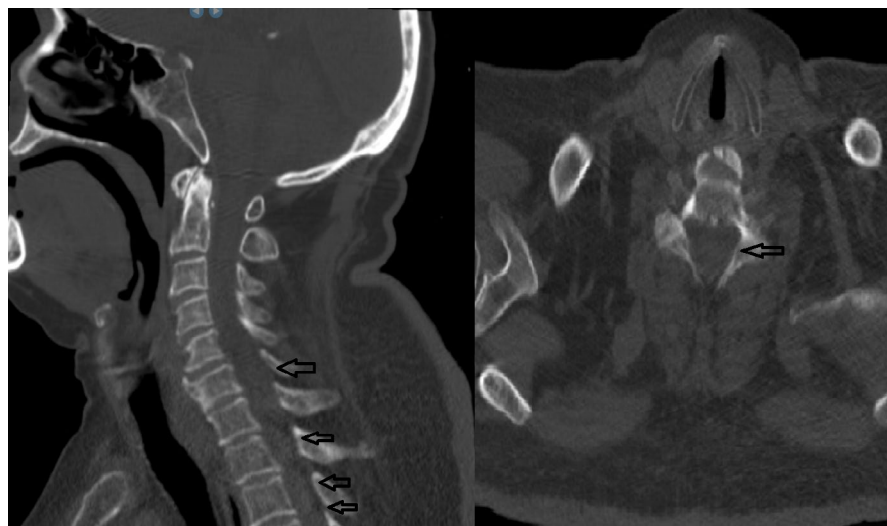## 2 | CASE PRESENTATION

A 73-year-old man presenting with cough, fever, and confusional state was admitted to the emergency department of Al-Zahra Hospital, current COVID-19 referral center of Isfahan City, Iran, in October 2020. He had controlled end-stage renal disease, controlled epilepsy, and hepatitis C (HCV) in his past medical history records. The patient was not an active or passive smoker. In the initial evaluation, altered consciousness level (Glasgow Coma Scale of 14) with low-grade fever, respiratory distress, and decreased O<sub>2</sub> saturation level (85%) were detected. Physical examination revealed no other specific findings. The patient's level of consciousness returned to normal after receiving supplementary oxygen at the emergency department. Brain computed tomography scan (CT) showed no acute intracranial lesion. According to the current pandemic of COVID-19 infection regional protocols, the patient underwent the lung high-resolution computed tomography scan (HRCT), typical for COVID-19 pneumonia. Positive RT-PCR for the COVID-19 virus from the nasopharynx specimen confirmed the diagnosis. Due to the severity of pneumonia, the patient was transferred to the hospital's

intensive care unit to receive the standard available treatment. Intravenous dexamethasone, crystalloid fluids, supplemental oxygenation, mucolytic, cough alleviating drugs, prophylactic subcutaneous heparin (5000 IU every 12 h), and routine ICU cares for COVID-19 were initiated. On day 20 of hospitalization in the ward, he reported paresthesia and weakness in the distal of his left and right lower limbs, aggravated within 48 h. Early general physical examination, including vital signs, had no new specific findings. Neurological examination at this time revealed decreased sensation at upper and lower extremities with decreased deep tendon reflexes (DTR). In addition, manual muscle power was 3/5, 2/5, and 4/5 in the proximal legs, distal legs, and upper limbs, respectively. Lab tests, including coagulation profiles (PT, PTT, INR, and BT), were in an acceptable range. To investigate the differential diagnoses of quadriparesis, electro-myography and nerve-conduction study (EMG-NCS) was performed. The results were not consistent with inflammatory demyelinating polyneuropathies but were in favor of an acute, mostly axonal sensory-motor polyneuropathy.

After 2 days of conservative treatment, rapid progression in the clinical presentation occurred. Physical examination showed complete paraplegia, fecal and urinary incontinency, and a sensory level deficit correlated with the T4 dermatome. The muscle power of the upper limbs was 3/5 in proximal and 2/5 in distal parts. Upper and lower extremities deep tendon reflexes (DTR) were diminished and absent, respectively.

Cervical CT scan images showed suspicious round and iso-dense lesions in the cervical spinal canal posterior to C5–T2 vertebral bodies (Figure 1). A whole-spine magnetic resonance imaging (MRI) was taken. Cervical spine MRI images revealed CSF blockage in cervical region myelography. There was a mixed intensity core in the context of hypo/hyperintense signal change extending from C3



**FIGURE 1** Cervical spine MDCT. Round intracanal iso-dense lesions were suspected behind C5–T2 (arrow heads). These lesions are not like intracranial hematoma (which are hyper dense) and this feature makes it more tricky to detect

to T3 vertebral bodies. In lumbar spine MRI, there were degenerative canal stenosis changes that were not compatible with the clinical picture of the patient (Figure 2). The above findings, along with the clinical scenario, were in favor of spontaneous intramedullary cervicothoracic hematoma.

The patient was prepared for an emergent posterior cervicothoracic laminectomy. In the prone position, from C3 to T3, paraspinal muscles were stripped. An extensive laminectomy from C3 to T3 was performed, and the dural sac was opened. The myelotomy was accomplished through the posterior median raphe plane. There were dark and thick blood clots within the cord that were removed carefully (Figure 3). Meticulous hemostasis was performed. Then the dural sac was repaired, and a subfascial drain was inserted. The paraspinal muscles and skin were sutured in anatomic layers. Pathologic examination of specimens revealed blood clots with no specific vascular malformations or tumoral tissues.

Immediate post-operation neurological examination showed significant resolution of T4 sensory level. Urinary and fecal incontinence, sensory deficits in both lower and upper extremities, and motor power of the lower limbs were improved until 1-month post-operation (ASIA score C). 1-year follow-up investigation showed no significant change in neurological status of the patient.

### 3 | DISCUSSION

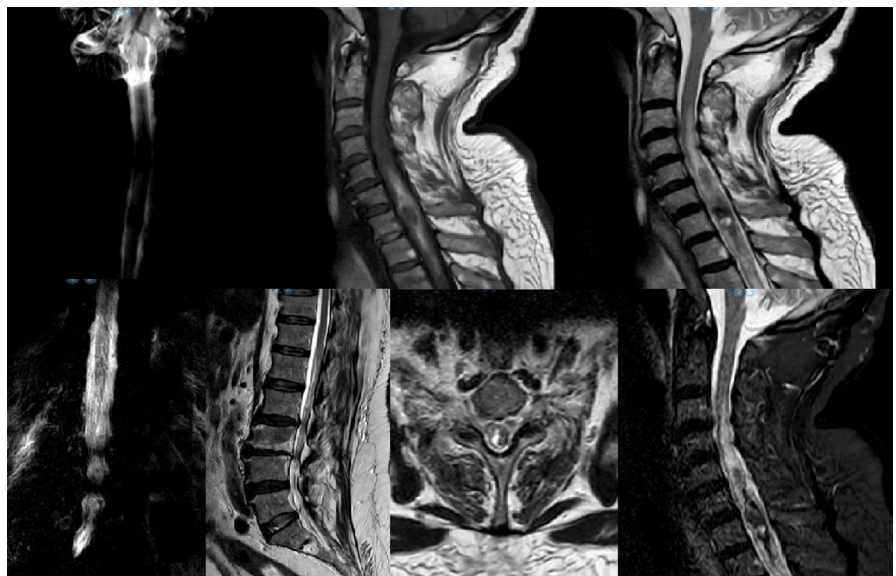Spontaneous intramedullary hematoma (hematomyelia) is a rare medical condition that has been reported in correlation with viral infections (e.g., dengue fever), tumors, vascular lesions, bleeding disorders such as hemophilia or dysfibrinogenemia, and the use of anticoagulants.<sup>4-6,13-15</sup>

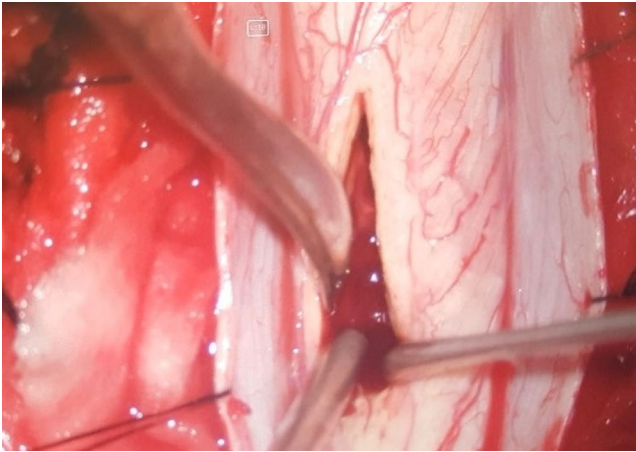
In some instances, the main reason for hematomyelia is not known (idiopathic), and further investigations disclose no more etiology. Due to limited scientific reports, its incidence is not established yet. Our case was a prior ESRD patient on prophylactic anticoagulant therapy, but laboratory findings, including coagulation profile, were in an acceptable range regarding the patient's underlying diseases.

The COVID-19 pandemic is a major global concern that primarily affects the respiratory system. COVID-19 virus can also involve extrapulmonary organs such as the gastro-intestinal and cardiovascular system, skin, blood, and bone marrow.<sup>9</sup> COVID-19 virus can also invade the nervous system and cause multiple neurological manifestations, including headache, dizziness, stroke, encephalopathy, encephalitis, and Guillain-Barré syndrome.<sup>9,16,17</sup> The possible underlying pathophysiology for nervous system involvement in COVID-19 infection may be microangiopathic changes and inflammatory responses.<sup>9,10</sup> Intracerebral hemorrhage (ICH) has also been reported in COVID-19 patients.<sup>11,12</sup> There is no consensus on proposed pathogenesis in the development of ICH in COVID-19 patients, but disruption of the renin-angiotensin system (RAS), cytokine storm, vascular inflammation, disruption of endothelial bed, and use of anticoagulants are suggested.<sup>18,19</sup> Besides, polyneuropathies are documented in COVID-19 patients in some studies.<sup>20,21</sup>

In our case, the primary neurological manifestation was polyneuropathy, which was confirmed by EMG-NCS. Within 2 days, it transformed into acute flaccid paralysis with a discriminated sensory level that triggered a high index of suspicion to an acute cord hematoma. It was unclear whether the primary quadriplegia resulted from an insidious small cervical cord hematoma or a clinical manifestation of concurrent neuropathy. This clinical picture

**FIGURE 2** Cervical and lumbar spine MRI images of the patient. CSF block is noticeable. Long extensive cervical lesion originating from C3 to T3 with multiple signaling features is highly suggestive for hemorrhagic lesions. Different intensity lesions suggest bleeding at various times. Incidental lumbosacral canal stenosis was detected which was not correlated with clinical picture





**FIGURE 3** Intraoperative photograph shows surgical field. Blood clots were removed through a small myelotomy in the cervical cord on posterior median raphe plane

transformation may warrant the physicians that every neurological sign in COVID-19 infection should be carefully monitored, and immediate actions should be taken if there are any changes in the neurological status of the patients.

In the review of the literature, both medical and surgical treatments for hematomyelia have been suggested. Surgical intervention includes emergent decompression of the cord and evacuation of the hematoma. Surgical intervention seems to be more effective and has a better clinical response.<sup>2,13,14,22</sup> Choi et al.<sup>1</sup> reported a duraplasty with artificial dura mater, which may improve cerebrospinal fluid dynamics and provide more decompression of the cord. In this case, extensive laminectomy from C3 to T3 vertebral bodies and hematoma evacuation were performed, and duraplasty was not required. The patient was paraplegic after 2 weeks post-operation but after 1 month regained slight motor power in proximal and distal muscles of the lower limbs. The sensory level was resolved post-operation immediately. After 1 month of follow-up, the patient gained some degrees of the bladder and anal sphincter control. Furthermore, sensory deficits in both upper and lower limbs were improved to some extent.

This is the world's first report about coincidence of COVID-19 with hematomyelia. According to previous research, although the development of intramedullary hematoma in our patient may be, in part, due to mechanisms linked with COVID-19 infection, further investigation is warranted to elucidate clear associations between these two medical conditions. We suggest that every new neurological sign in patients with COVID-19 infection should prompt a meticulous investigation according to the clinical picture. Incorporating cervical imaging into standard workup for COVID-19 patients with acute

neurological symptoms may be of clinical importance to choose the best treatment plan for the patients as soon as possible.

### ACKNOWLEDGEMENTS

The authors would like to dedicate this work to deceased Professor Mahmoud Nourian who taught us how to be a caregiver neurosurgeon and, at last, sacrificed his life to save more lives in the COVID-19 pandemic. He lives in our hearts. The authors would like to thank the patient and his family for their cooperation.

### CONFLICT OF INTEREST

The authors declare no conflict of interest.

### AUTHOR CONTRIBUTIONS

MS and BS contributed to patient treatment, manuscript revision, final approval of the manuscript and agreed to be accountable for all aspects of the work. MR contributed to the conception of the work, data search, patient treatment, manuscript preparation, manuscript revision, final approval of the manuscript and agreed to be accountable for all aspects of the work. AS(co-corr) contributed to the conception of the work, data search, data gathering, patient treatment, manuscript preparation, manuscript revision, final approval of the manuscript and agreed to be accountable for all aspects of the work. SBM (co-corr) contributed to the data search, manuscript preparation, manuscript revision, final approval of the manuscript and agreed to be accountable for all aspects of the work.

### ETHICAL APPROVAL

All procedures performed were under the institutional and/or national research committee's ethical standards and the 1964 Helsinki Declaration and its later amendments or comparable ethical standards. This report was supervised and approved by Isfahan University neurosurgery department board members on behalf of the Ethical Committee of Isfahan University of Medical Sciences.

### CONSENT TO PARTICIPATE

Informed consent was obtained from all individual participants included in the study.

### CONSENT

An informed written consent was obtained from the patient.

### DATA AVAILABILITY STATEMENT

Data and original images in the current study are available from the corresponding author on reasonable request. Authors can confirm that all relevant data are included in the article and/or its supplementary information files.

## ORCID

Arman Sourani  <https://orcid.org/0000-0002-8998-9446>

## REFERENCES

1. Choi BS, Lee S. Idiopathic spontaneous intramedullary hemorrhage: a report of a rare case of repeated intramedullary hemorrhage with unknown etiology. *Korean J Spine*. 2015;12(4):279-282.
2. Akpınar A, Celik B, Canbek I, Karavelioğlu E. Acute paraplegia due to thoracic hematomyelia. *Case Rep Neurol Med*. 2016;2016:3138917.
3. Guy LO, Barnes W, George M. Spontaneous hematomyelia and angiomas of the spinal cord. *J Neurosurg*. 1957;14(2):192-202.
4. Kumar MS, Srinanthini KR, Gopal S. A report of quadriplegia in dengue fever due to hematomyelia. *Neurol India*. 2019;67(2):530-531.
5. Toda H, Okamoto T, Nishida N, Yuba Y, Iwasaki K. Idiopathic hematomyelia as a rare cause of epiconus syndrome. *Clin Neurol Neurosurg*. 2014;125:75-77.
6. Matsumura A, Ayuzawa S, Doi M, et al. Chronic progressive hematomyelia: case reports and review of the literature. *Surg Neurol*. 1999;51(5):559-563.
7. Bchetnia M, Girard C, Duchaine C, Laprise C. The outbreak of the novel severe acute respiratory syndrome coronavirus 2 (SARS-CoV-2): a review of the current global status. *J Infect Public Health*. 2020;13(11):1601-1610.
8. Guo YR, Cao QD, Hong ZS, et al. The origin, transmission and clinical therapies on coronavirus disease 2019 (COVID-19) outbreak - an update on the status. *Mil Med Res*. 2020;7(1):11.
9. Gupta A, Madhavan MV, Sehgal K, et al. Extrapulmonary manifestations of COVID-19. *Nat Med*. 2020;26(7):1017-1032.
10. Ellul MA, Benjamin L, Singh B, et al. Neurological associations of COVID-19. *Lancet Neurol*. 2020;19(9):767-783.
11. Gogia B, Fang X, Rai P. Intracranial hemorrhage in a patient with COVID-19: possible explanations and considerations. *Cureus*. 2020;12(8):e10159.
12. Sharifi-Razavi A, Sedaghat Z, Baziboroun M, Karimi N. COVID-19 accompanied with intracerebral hemorrhage: a case series. *Arch Clin Infect Dis*. 2020;15(4):1-4.
13. Aulakh R, Panigrahi I, Naranje K, Sharda S, Marwaha RK. Spontaneous hematomyelia in a child with hemophilia A: a case report. *J Pediatr Hematol Oncol*. 2009;31(10):766-767.
14. Madhusudhan BK, Javali M, Mangalore DS, Rohan M, Srinivasa R. Hematomyelia as a cause of brown-sequard's syndrome in a hypofibrinogenemic patient. *Neurology India*. 2014;62(4):467.
15. Li Y, Takayasu M, Takagi T, Yoshimoto M, Mitsui Y, Yoshida J. Intramedullary spinal cord metastasis associated with hemorrhage: a case report. *No Shinkei Geka*. 2000;28(5):453-457.
16. Niazkar HR, Zibae B, Nasimi A, Bahri N. The neurological manifestations of COVID-19: a review article. *Neurol Sci*. 2020;41(7):1667-1671.
17. Sedaghat Z, Karimi N. Guillain Barre syndrome associated with COVID-19 infection: a case report. *J Clin Neurosci*. 2020;76:233-235.
18. Benger M, Williams O, Siddiqui J, Sztrihla L. Intracerebral haemorrhage (ICH) and COVID-19: clinical characteristics from a case series. *Brain Behav Immun*. 2020;88:940-944.
19. Melmed KR, Cao M, Dogra S, et al. Risk factors for intracerebral hemorrhage in patients with COVID-19. *J Thromb Thrombolysis*. 2020;51(4):953-960.
20. Zhao H, Shen D, Zhou H, Liu J, Chen S. Guillain-Barré syndrome associated with SARS-CoV-2 infection: causality or coincidence? *Lancet Neurol*. 2020;19(5):383-384.
21. Khatoon F, Prasad K, Kumar V. Neurological manifestations of COVID-19: available evidences and a new paradigm. *J Neurovirol*. 2020;26(5):619-630.
22. Kumar S, Handa A, Tiwari R. Spontaneous cervical intramedullary hematoma. *J Neurol Neurosci*. 2017;8:1-2.

**How to cite this article:** Sabouri M, Rezvani M, Aminmansour B, Sourani A, Baradaran Mahdavi S. Spontaneous intramedullary hematoma in a patient with COVID-19 infection: A case report. *Clin Case Rep*. 2022;10:e05387. doi:[10.1002/ccr3.5387](https://doi.org/10.1002/ccr3.5387)