

A Novel Tube-Drainage Technique of Negative Pressure Wound Therapy for Fistulae after Reconstructive Surgery

Hiroki Umezawa, MD, PhD*
 Takeshi Matsutani, MD, PhD†
 Kazuhiko Yokoshima, MD, PhD‡
 Munenaga Nakamizo, MD, PhD‡
 Rei Ogawa, MD, PhD, FACS*

Background: Patients with head and neck or esophageal cancer who undergo resection and reconstructive surgery sometimes develop fistulae that exhibit delayed wound healing. We developed a novel negative pressure wound therapy (NPWT) that employs a Penrose drain. This case series report describes its effect on the wound healing and treatment duration of cancer patients with postoperative fistulae.

Methods: This consecutive case series consisted of all patients from February 2014 to February 2017 who underwent resection and reconstruction for head and neck or esophageal cancer and who then developed a fistula that was treated with either NPWT or a second flap that did not resolve the fistula or led to fistula recurrence and was then treated with NPWT. A Penrose drainage tube was inserted into the fistula, and a NPWT device was applied.

Results: Eleven patients (10 males, 1 female; mean age, 67.4 years) underwent NPWT for fistulae that arose after tumor resection and reconstruction (n = 6) or after fistula reconstruction (n = 5). The resection was for esophageal (n = 4), laryngeal (n = 3), oral (n = 2), and hypopharyngeal (n = 2) cancer. In 9 cases, 1 week of NPWT led to rapid and complete wound healing. In 2 cases, complete healing occurred after 3–4 weeks of NPWT.

Conclusions: Our NPWT applies continuous negative pressure inside the fistula only and dramatically promoted fistula healing. This approach may work by cleaning the fistula and promoting mucosal surface adhesion. It is particularly effective when the tissue surrounding the fistula is soft due to fresh tissue transfer. (*Plast Reconstr Surg Glob Open* 2018;6:e1885; doi: 10.1097/GOX.0000000000001885; Published online 6 August 2018.)

INTRODUCTION

Head and neck surgery, thoracic surgery, and abdominal surgery, among other surgeries, sometimes generate refractory skin fistulae that connect the gastrointestinal

tract or mediastinum to the skin/cutaneous wound. Such fistulae are very difficult to manage, even when free tissue is transferred to correct them. As a result, they significantly prolong the duration of treatment for the patient.

If there is extensive necrosis of the transferred tissue or the fistula is huge, reconstruction may be considered.^{1–4} Regardless of the treatment that is employed, it can take several weeks or months before esophagocutaneous and pharyngocutaneous fistulae resolve. This largely reflects the neck to chest anatomy and patient characteristics: this region associates with complex 3-dimensional structures, surrounding hard tissues, swallowing pressure, saliva inflow, lymphorrhoea, poor general condition, chemotherapy, and radiotherapy, all of which hamper the healing of wounds in this region.

In 2013, Yang et al.⁵ reported that complications associated with head and neck reconstruction can be managed successfully by applying a conventional negative pressure wound therapy (NPWT) system. Moreover, NPWT is

From the *Department of Plastic, Reconstructive and Aesthetic Surgery, Nippon Medical School, Tokyo, Japan; †Department of Gastrointestinal and Hepato-Biliary-Pancreatic Surgery, Nippon Medical School, Tokyo, Japan; and ‡Department of Otolaryngology, Head and Neck Surgery, Nippon Medical School, Tokyo, Japan.

Received for publication February 14, 2018; accepted June 13, 2018.

Presented at the 9th Annual Meeting of the Japanese Society for Surgical Wound Care. This study won the best topic award at the meeting.

Copyright © 2018 The Authors. Published by Wolters Kluwer Health, Inc. on behalf of The American Society of Plastic Surgeons. This is an open-access article distributed under the terms of the Creative Commons Attribution-Non Commercial-No Derivatives License 4.0 (CCBY-NC-ND), where it is permissible to download and share the work provided it is properly cited. The work cannot be changed in any way or used commercially without permission from the journal.

DOI: 10.1097/GOX.0000000000001885

Disclosure: The authors have no financial interest to declare in relation to the content of this article. The Article Processing Charge was paid for by the authors.

effective for treating refractory skin or soft-tissue ulcers.^{6,7} Although it is suggested that NPWT is contraindicated for sites at which malignant tumors are present because it may encourage metastasis, there is actually no direct evidence for this.⁸

In this case series study, we show that our novel NPWT approach employing a Penrose drain significantly reduces the closure time for patients with prolonged small fistulae, the diameter of which was less than 1 cm.

PATIENTS AND METHODS

Informed consent to undergo fistula treatment with our novel approach was obtained from all patients. The study was conducted according to the principles of the Declaration of Helsinki and its revisions and approved by the Institutional Review Board of Nippon Medical School Hospital (approval number, 29-01-883).

The case series consisted of all consecutive patients from February 2014 to February 2017 who underwent resection and reconstruction for head and neck or esophageal cancer and who then developed a small fistula (the diameter of which was less than 1 cm) that was treated with either our NPWT method or a second flap transfer that did not resolve the fistula or led to fistula recurrence and was then treated with our NPWT method.

NPWT Method with a Penrose Drain

After reconstructive surgery with soft-tissue transfer is completed, the fistula site is closed off with an adhesive film. A hole is made in the film, and the 6 mm Penrose drain, which is a split soft drainage tube, is inserted into the fistula. The drainage tube is then wrapped by a split sponge foam that is placed on the film overlying the fistula. A hole is made in another piece of adhesive film, after which the Penrose drain is threaded through the hole, and the film is adhered to the sponge foam and the surrounding skin. A conventional NPWT device (V.A.C., KCI USA, Inc., San Antonio, Tex.) is then placed over the film such that it places negative pressure on the Penrose drain

(Fig. 1). The Penrose drain must be replaced every 3 days. At each change, the Penrose drain should be inserted less deeply into the fistula. This treatment should be continued for 1–2 weeks.

RESULTS

In total, 203 patients underwent head and neck or esophageal reconstruction surgery during the study period. Of these, 11 patients with an esophagocutaneous or pharyngocutaneous fistula underwent our novel NPWT using a Penrose drain. The patients consisted of 10 males and 1 female, and their average age was 67.4 years. All patients underwent complete resection of esophageal cancer ($n = 4$), laryngeal cancer ($n = 3$), oral cancer ($n = 2$), or hypopharyngeal cancer ($n = 2$). All fistulae were less than 2 cm in diameter and from 1 to 15 cm in length. In 6 cases, our NPWT was used to resolve fistulae that arose after tumor resection and reconstruction. In the remaining 5 cases, the patients developed a fistula after resection and reconstruction and the surgeon decided to repair it with a second flap transfer. However, the second flap transfer either did not resolve the fistula or the fistula recurred. Consequently, our NPWT was applied. All patients who underwent a second flap transfer received a pectoral major muscle cutaneous flap. The same flap was also used in 2 of the 6 patients who developed a fistula after resection. The remaining 4 patients received an anterolateral thigh flap, a free jejunum flap, a fibula osteocutaneous flap, and a forearm flap, respectively (Table 1).

The total duration of NPWT per patient was between 7 and 28 days (average, 10.2 days). In 9 of the 11 patients (81.8%), NPWT was stopped after 1 week and the fistula healed completely with external treatments 2–4 days later (ie, 9–11 days after NPWT started). The fistulae of the remaining 2 patients were refractory and recurred after being apparently resolved by the NPWT. As a result, NPWT was repeated. It took 21 and 28 days of NPWT in total before these fistulae healed. Thus, healing was only observed 43 and 62 days after NPWT started. The only adverse event

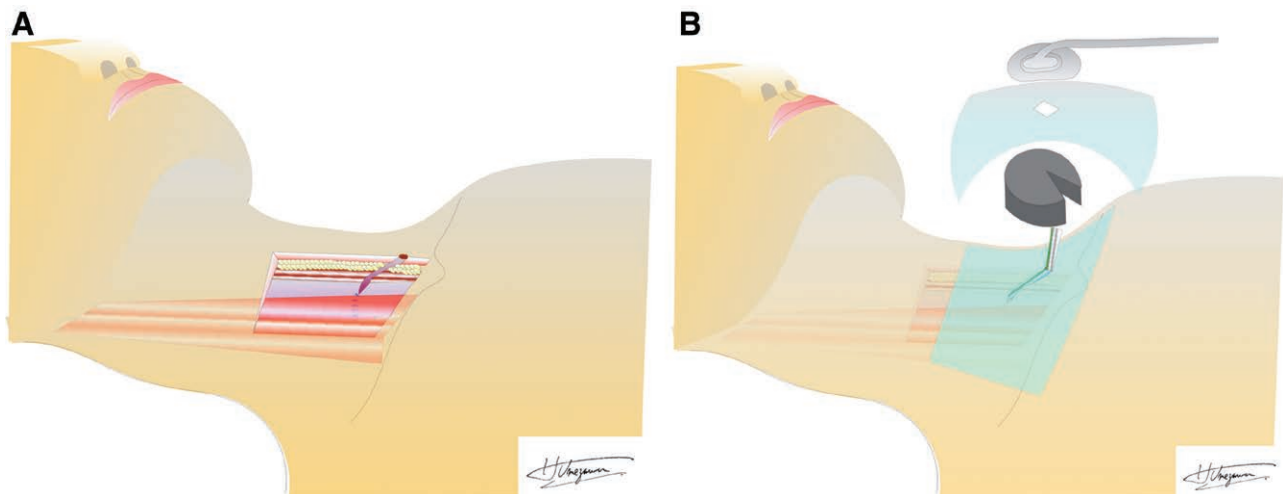


Fig. 1. A, Schematic depiction of an esophagocutaneous fistula. The swallowing pressure and continuous saliva leakage inhibit complete wound healing. B, NPWT using a Penrose drain that is placed into the fistula.

Table 1. Patient Characteristics, Flap Used for Reconstruction before NPWT, Use of Radiotherapy, NPWT Duration, NPWT-related Complications, and Total Healing Time after Starting NPWT

Patient No.	Age (y)/ Sex	Disease	Flap Used for Reconstruction before NPWT	RT Before Surgery (Gy)	The Fistula Arose/Relapsed after*	NPWT Treatment Duration (d)	Complication	Total Time to Complete Healing after Starting NPWT (d)
1	59/M	Buccal mucosa cancer	ALT	60	Resection and reconstruction	7	—	10
2	70/M	Esophageal cancer	PMMC	70	Fistula reconstruction	7	Contact dermatitis	11
3	69/M	Esophageal cancer	PMMC, FJ	70	Fistula reconstruction	7	—	10
4	62/M	Laryngeal cancer	PMMC	60	Fistula reconstruction	7	—	10
5	60/M	Laryngeal cancer	PMMC	—	Fistula reconstruction	7	—	9
6	76/M	Esophageal cancer	FJ	—	Resection and reconstruction	7	—	10
7	73/F	Esophageal cancer	PMMC	—	Resection and reconstruction	21	Contact dermatitis	45
8	75/M	Laryngeal cancer	PMMC	70	Resection and reconstruction	28	Contact dermatitis	62
9	68/M	Pharyngeal cancer	PMMC	60	Fistula reconstruction	7	—	10
10	67/M	Lower gingival cancer	Fibula OC	—	Resection and reconstruction	7	—	9
11	62/M	Pharyngeal cancer	Forearm	—	Resection and reconstruction	7	—	11

ALT, anterolateral thigh flap; F, female; Fibula OC, fibula osteocutaneous flap; FJ, free jejunum transfer; Forearm, forearm flap; M, male; PMMC, pectoral major muscle cutaneous flap; RT: radiotherapy.

*Six patients developed a fistula after tumor resection and reconstruction with soft-tissue transfer that was treated conservatively only. The remaining 5 patients also developed a fistula after tumor resection and reconstruction with soft-tissue transfer but then underwent a second soft-tissue transfer to treat the fistula. However, this treatment did not resolve the fistula or the fistula relapsed.

that was observed was contact dermatitis due to tape (3 cases) (Table 1).

All patients were able to ingest food after complete wound healing was achieved.

At the last follow-up more than 6 months after tumor resection, 9 patients were still alive, and there was no evidence of disease. The remaining 2 patients (patients 6 and 7) have died from the disease.

CASE PRESENTATION

Case 1

A 68-year-old man underwent resection of hypopharyngeal cancer after chemoradiotherapy. A free jejunal and delto-pectoral flap was transferred. Seven days after surgery, a fistula between the cervical area to under the delto-pectoral flap was detected (Fig. 2A). Standard treatments such as washing were performed for 7 days. Our NPWT method was then performed for 7 days (Fig. 2B, C). The fistula exhibited complete healing 3 days after NPWT finished. The patient was then able to restart oral ingestion. Six months after NPWT finished, fistula recurrence was not observed (Fig. 2D).

Case 2

A 67-year-old man underwent resection of a lower gingiva carcinoma followed by reconstruction with a fibula osteocutaneous flap. After reconstruction, a fistula from inside the oral cavity to the skin developed (Fig. 3A). Standard conservative treatment, such as topical medication and washing, was implemented for 4 months but improvements were not observed. Thus, we applied our NPWT method for 7 days (Fig. 3B). Two days after NPWT was completed, the wound had healed completely (Fig. 3C). The fistula did not recur.

DISCUSSION

Free or pedicled soft-tissue transfer after head and neck or esophageal cancer resection is now a standard surgical procedure. Moreover, if a huge fistula occurs in this area, the surgeon may again consider using a free or pedicled soft-tissue flap to correct it. However, all these procedures can be complicated by the development of small fistulas that are often difficult to manage and, depending on the individual case, may require several months of conservative treatment to resolve.^{9,10}

Our recent case series study suggests that free or pedicled soft-tissue transfer associates with a relatively low rate of fistula formation in cancer patients who require esophageal reconstruction.¹¹ Similarly, a review and a case-control study showed that compared with primary closure, which associates with fistula formation rates of 20–50%, vascularized tissue transfer reduces fistula formation to 15–20%.^{12,13} However, if a fistula does develop and flap surgery is performed again to repair it, the risk of complications increases: these complications include infection, donor-site mobility, and flap necrosis, as well as formation of another fistula or relapse of the original fistula.¹⁴ Indeed, McLean et al.¹⁵ reported that reconstruction surgery for fistula formation associates with high rates (35.3%) of fistula relapse.

Poor nutritional status, the use of adjuvant chemoradiotherapy, and various anatomical aspects of this area of the body contribute to development of refractory fistulae. If there is some tissue necrosis and/or the digestive tube suture exhibits some dehiscence, saliva will leak into the surrounding wounds and out through the cutaneous wound. The pressure of swallowing will then expand the fistula and further exacerbate saliva leakage.

Saliva leakage and swallowing pressure also prevent the wound from closing. In addition, the tendency to

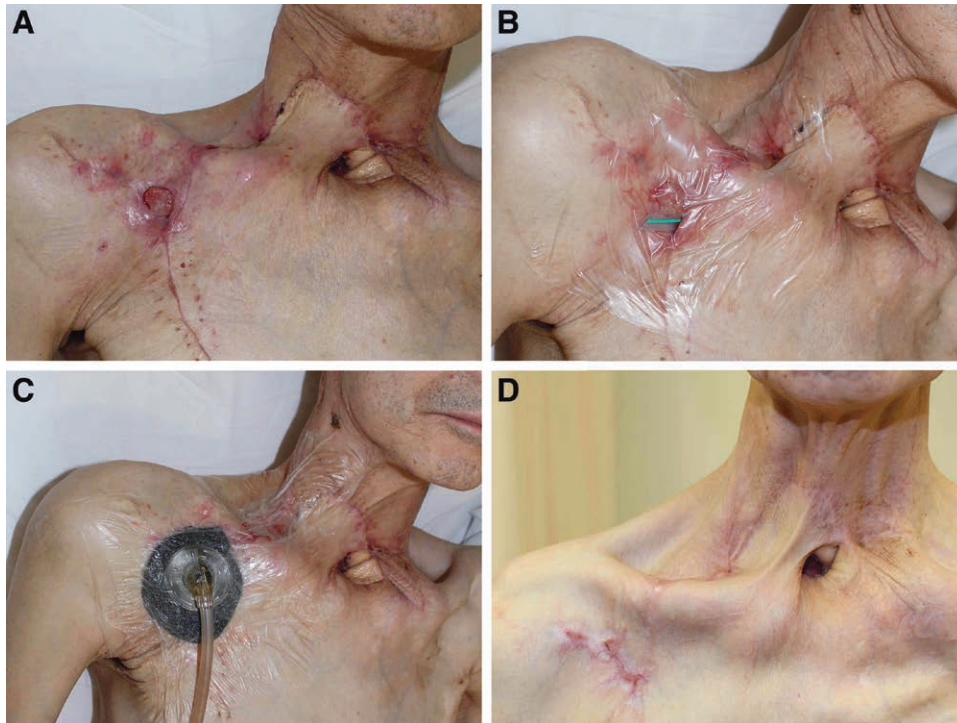


Fig. 2. A, After reconstruction, a fistula that connected the cervical area to the skin developed. B, The Penrose drain was inserted into the fistula through a hole in the adhesive film. C, The Penrose drain was wrapped with a split sponge foam, after which the drain was threaded through a hole in another adhesive film that was then adhered to the sponge and the surrounding skin. An NPWT device was then applied. This was performed for 7 days. D, No fistula recurrence was observed 6 months after the end of NPWT.

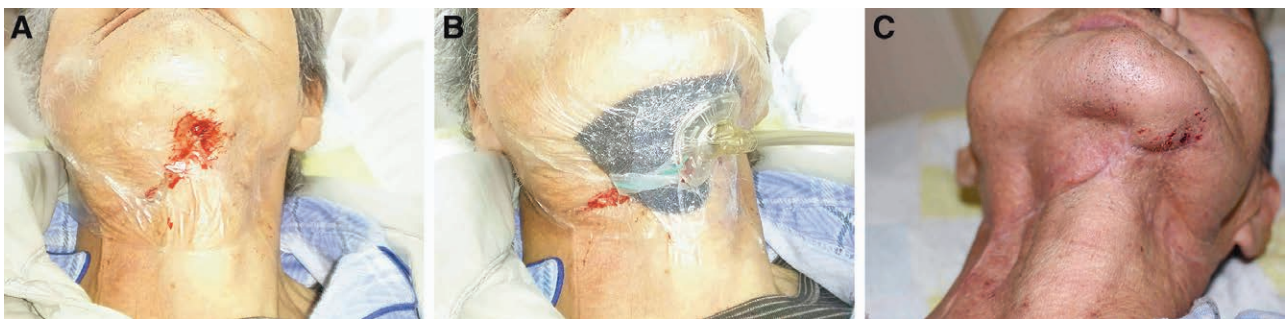

Fig. 3. A, An adhesive film was placed over the fistula, and (B) the NPWT method was performed for 7 days. C, No fistula recurrence was observed 4 months after the end of NPWT.

ward infection and the frequent swallowing pressure mean that using simple sutures to repair the digestive tube often fails. Thus, to ensure complete wound healing, it is necessary to prevent saliva leakage and induce wound adhesion that can withstand the swallowing pressure.

In 1997, Argenta and Morykwas^{6,7} introduced the concept of using NPWT to manage complicated wounds. Since NPWT greatly promotes wound healing, this breakthrough method is now widely used all over the world in many specialties, including plastic surgery, general surgery, and orthopedics.¹⁶⁻¹⁹ Recently, incisional NPWT was introduced as a new tool for promoting the healing of high-risk surgical-site wounds.²⁰

Two small studies reported that NPWT had good outcomes when it was applied to 13 patients with complicated wounds (including wounds complicated by fistula) after resection of head and neck cancer followed by flap transfer.^{5,21} Thus, in head and neck or esophageal cancer surgery, regardless of whether free soft tissue transfer is or is not performed, the treatment options for patients who develop a fistula after tumor resection include conservative treatment (which may take 2 or 3 months to induce complete wound healing) or transfer of free or pedicled transplants of fresh, soft, and uninfected tissues (which, if successful, resolves the fistula immediately). If the new tissue transfer does not immediately resolve the fistula or the fistula recurs, NPWT can be applied (Fig. 4).

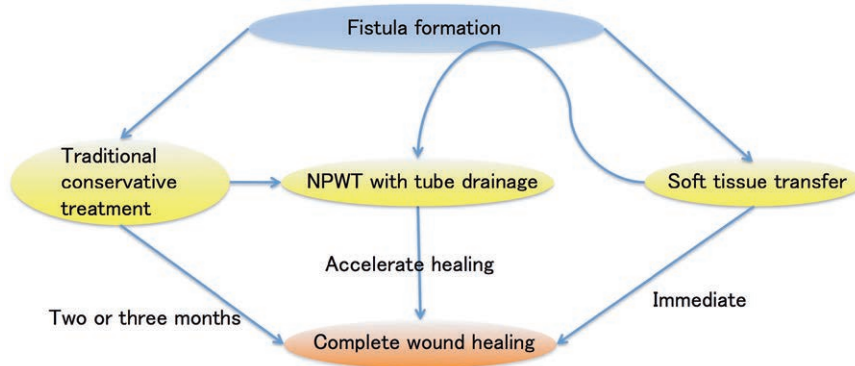


Fig. 4. Treatment protocol for fistula after head and neck or esophageal cancer resection. For each option, the expected duration of treatment that is needed to obtain complete wound healing is indicated.

However, the normal NPWT method has some problems with respect to treating small fistula. First, it is difficult to speculate that high pressure accurately effects deep and small fistula. Second, when removing the NPWT system, care should be taken that the fragment of NPWT sponge-form does not remain within small fistula. Such a foreign body presents additional problems, such as infection or granulation.

We showed here that our new NPWT method with the Penrose drain effectively resolved the small fistulae that developed after head and neck or esophageal tumor resection followed by free tissue transfer. It also resolved the fistulae in the patients whose small postresection fistula was not resolved by or recurred after a second flap transfer. Moreover, in most cases, the NPWT drastically shortened the time spent waiting for the fistula to heal: in 9 of our 11 cases, the fistula healed completely 9–11 days after NPWT was started.

In this setting, it is likely that NPWT promotes and accelerates wound healing by increasing the granulation of the engrafted tissue and the discharge of saliva and accu-

mulated fluid. The negative pressure probably also helps to force the mucosal tissues together (crimping) and reduces the dead space (Fig. 5).

It should be noted that, in our method, a split sponge was wrapped around the Penrose drain and then placed on top of a film overlying the fistula. In other words, the sponge was not placed directly into the fistula opening. Consequently, when the NPWT device was placed over the wound, only the inside of the wound was subjected to a constant negative pressure that was applied by the soft Penrose drainage tube. This setup eliminates the possibility that the NPWT aspirates important tissue components such as blood vessels.

The Penrose drain was first introduced in 1890. We chose it for our NPWT system because it effectively applies negative pressure. This ability is caused by its fine grooves, which prevent the tube from collapsing completely under negative pressure.²²

We chose to use the V.A.C. (KCI USA, Inc., San Antonio, Tex.) NPWT system to generate the negative pressure because it applies the same pressure continuously and associates with good control over the intensity of pressure. We did not use a conventional silicon Blake drain with a portable suction reservoir because, even if this setup could be adapted to our purposes, it is hard to get this device to continuously apply the same negative pressure. There was also concern that the medical staff may apply the wrong negative pressure release time by mistake.

In 2 of 11 patients, complete healing was only achieved after applying our NPWT method twice. This may have been due to difficulties in applying the tape due to anatomical and structural reasons, the onset of cervical skin erosion due to the saliva from the fistula, and the inhibition of adhesion on the mucosal side due to excessive insertion of the Penrose drain. Thus, our NPWT method may not be suitable for patients in whom the fistula is close to a tracheostomy or when the skin around the fistula exhibits erosion due to saliva leakage or radiotherapy.

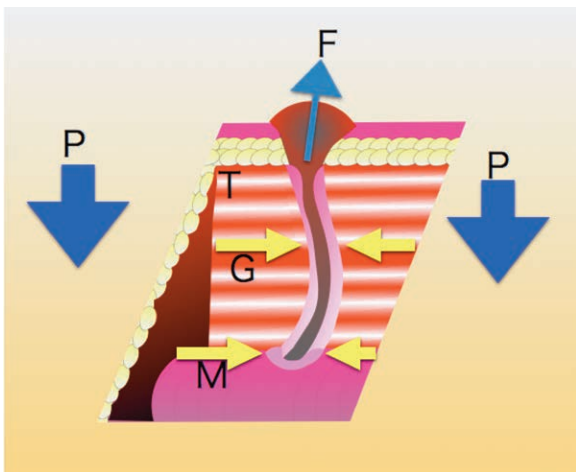


Fig. 5. Mechanism by which NPWT using a Penrose drain promotes healing. The negative pressure (P) forces the mucosal tissues together (M), encourages granulation (G) and adhesion of the transferred soft tissue (T), reduces dead space, and promotes fluid discharge (F).

CONCLUSIONS

Our NPWT system with a Penrose drain effectively shortened the time spent waiting for fistulae to heal after

head and neck or esophageal cancer surgery. The usefulness of this method for other diseases warrants further investigation.

Hiroki Umezawa, MD, PhD

Department of Plastic, Reconstructive and Aesthetic Surgery
Nippon Medical School Hospital
1-1-5 Bunkyo-ku, Sendagi
Tokyo 113-8603, Japan
E-mail: s8013@nms.ac.jp

REFERENCES

- Berry SM, Fischer JE. Classification and pathophysiology of enterocutaneous fistulas. *Surg Clin North Am.* 1996;76:1009-1018.
- Markou KD, Vlachtsis KC, Nikolaou AC, et al. Incidence and predisposing factors of pharyngocutaneous fistula formation after total laryngectomy. Is there a relationship with tumor recurrence? *Eur Arch Otorhinolaryngol.* 2004;261:61-67.
- Smith TJ, Burrage KJ, Ganguly P, et al. Prevention of postlaryngectomy pharyngocutaneous fistula: the Memorial University experience. *J Otolaryngol.* 2003;32:222-225.
- Tomkinson A, Shone GR, Dingle A, et al. Pharyngocutaneous fistula following total laryngectomy and post-operative vomiting. *Clin Otolaryngol Allied Sci.* 1996;21:369-370.
- Yang YH, Jeng SF, Hsieh CH, et al. Vacuum-assisted closure for complicated wounds in head and neck region after reconstruction. *J Plast Reconstr Aesthet Surg.* 2013;66:e209-e216.
- Fleischmann W, Strecker W, Bombelli M, et al. [Vacuum sealing as treatment of soft tissue damage in open fractures]. *Unfallchirurg.* 1993;96:488-492.
- Argenta LC, Morykwas MJ. Vacuum-assisted closure: a new method for wound control and treatment: animal studies and basic foundation. *Ann Plast Surg.* 1997;38:553-562.
- Cai SS, Gowda AU, Alexander RH, et al. Use of negative pressure wound therapy on malignant wounds—a case report and review of literature. *Int Wound J.* 2017;14:661-665.
- Keereweer S, Sewnaik A, Kerrebijn J, et al. Salvage or what follows the failure of a free jejunum transfer for reconstruction of the hypopharynx? *J Plast Reconstr Aesthet Surg.* 2010;63:976-980.
- Umezawa H, Matsutani T, Ogawa R, et al. Immediate free jejunum transfer for salvage surgery of gastric tube necrosis. *Case Rep Gastrointest Med.* 2014;2014:327549.
- Umezawa H, Nakao J, Matsutani T, et al. Usefulness of the Clavien-Dindo classification in understanding the limitations and indications of larynx-preserving esophageal reconstruction. *Plast Reconstr Surg Glob Open.* 2016;4:e1113.
- Hanasono MM, Lin D, Wax MK, et al. Closure of laryngectomy defects in the age of chemoradiation therapy. *Head Neck.* 2012;34:580-588.
- Withrow KP, Rosenthal EL, Gourin CG, et al. Free tissue transfer to manage salvage laryngectomy defects after organ preservation failure. *Laryngoscope.* 2007;117:781-784.
- Wu CC, Lin PY, Chew KY, et al. Free tissue transfers in head and neck reconstruction: complications, outcomes and strategies for management of flap failure: analysis of 2019 flaps in single institute. *Microsurgery.* 2014;34:339-344.
- McLean JN, Nicholas C, Duggal P, et al. Surgical management of pharyngocutaneous fistula after total laryngectomy. *Ann Plast Surg.* 2012;68:442-445.
- Argenta LC, Morykwas MJ. Vacuum-assisted closure: a new method for wound control and treatment: clinical experience. *Ann Plast Surg.* 1997;38:563-576; discussion 577.
- Andrews BT, Smith RB, Chang KE, et al. Management of the radial forearm free flap donor site with the vacuum-assisted closure (VAC) system. *Laryngoscope.* 2006;116:1918-1922.
- Mouës CM, Heule F, Hovius SE. A review of topical negative pressure therapy in wound healing: sufficient evidence? *Am J Surg.* 2011;201:544-556. doi: 10.1016/j.amjsurg.2010.04.029.
- Benech A, Arcuri F, Poglio G, et al. Vacuum-assisted closure therapy in reconstructive surgery. *Acta Otorhinolaryngol Ital.* 2012;32:192-197.
- Horch RE. Incisional negative pressure wound therapy for high-risk wounds. *J Wound Care.* 2015;24:21-28.
- Teixeira S, Costa J, Bartosch I, et al. Management of pharyngocutaneous fistula with negative-pressure wound therapy. *J Craniofac Surg.* 2017;28:e364-e367.
- Penrose CB. Drainage in abdominal surgery. *JAMA.* 1890;XIV(8): 264-266.