



ELSEVIER

Contents lists available at ScienceDirect

## Respiratory Medicine Case Reports

journal homepage: [www.elsevier.com/locate/rmcr](http://www.elsevier.com/locate/rmcr)

## Case report

Impact of lung cancer surgery on comorbid *Mycobacterium avium* complex lung disease—A case seriesAtsuhisa Tamura<sup>a,\*</sup>, Masahiro Kawashima<sup>a</sup>, Junko Suzuki<sup>a</sup>, Akira Yamane<sup>a</sup>, Yuta Inoue<sup>b</sup>, Takeshi Fukami<sup>b</sup>, Masashi Kitani<sup>c</sup>, Fumiaki Takahashi<sup>d</sup><sup>a</sup> Department of Respiratory Diseases, National Hospital Organization Tokyo National Hospital, Kiyose, Tokyo, 204-8585, Japan<sup>b</sup> Department of Chest Surgery, National Hospital Organization Tokyo National Hospital, Kiyose, Tokyo, 204-8585, Japan<sup>c</sup> Department of Pathology, National Hospital Organization Tokyo National Hospital, Kiyose, Tokyo, 204-8585, Japan<sup>d</sup> Department of Information Science, Iwate Medical University, Yahaba, Iwate, 028-3694, Japan

## ARTICLE INFO

## Keywords:

Case report

Lung cancer surgery

*Mycobacterium avium* complex Lung disease

Comorbidity

Exacerbation

Rifampicin

Ethambutol

And clarithromycin therapy

## ABSTRACT

The number of cases with *Mycobacterium avium* and *Mycobacterium intracellulare* lung diseases (*Mycobacterium avium* complex lung disease [MACLD]) are increasing globally. Lung cancer can sometimes present as a comorbidity with MACLD; however, the clinical presentation and outcomes of comorbid MACLD following lung cancer resection remain unclear. Therefore, we retrospectively assessed 17 patients with MACLD undergoing lung cancer resection to determine the impact of lung cancer surgery on comorbid MACLD. Of the 17 patients, *Mycobacterium avium* and *Mycobacterium intracellulare* were present in 15 and 2 patients, respectively; 14 patients had stage I lung cancer and underwent lobectomy. Ten patients were postoperatively observed for MACLD without any further intervention, five patients underwent additional resection for conspicuous MACLD lesions, and the remaining two patients underwent complete resection for MACLD and lung cancer within the same lobe followed by rifampicin, ethambutol, and clarithromycin (RECAM) therapy. Seven patients exhibited postoperative MACLD exacerbation, six of whom developed exacerbation in the operated ipsilateral residual lobes. Six of these seven patients received RECAM, three of whom (43%) subsequently exhibited improvement. Attention should be paid to MACLD exacerbation during postoperative follow-up, especially in ipsilateral lobes. Although RECAM therapy may be beneficial in alleviating MACLD exacerbation, further investigation is warranted to validate these results.

## 1. Introduction

Recently studies have shown an increase in the worldwide incidence of nontuberculous *Mycobacterium* (NTM)-associated lung disease (NTMLD), particularly *Mycobacterium avium* and *Mycobacterium intracellulare* lung diseases (*Mycobacterium avium* complex lung disease [MACLD]) [1,2]. The clinical practice guidelines for the treatment of NTMLD treatment were recently updated [3]. Treatment success rates for MACLD have been estimated to be approximately 60%, with 12% of patients defaulting on treatment [4]. With the

\* Corresponding author. Department of Respiratory Diseases National Hospital Organization, Tokyo National Hospital, 3-1-1 Takeoka, Kiyose, Tokyo, 204-8585, Japan.

E-mail addresses: [tamura.atsuhisa.py@mail.hosp.go.jp](mailto:tamura.atsuhisa.py@mail.hosp.go.jp) (A. Tamura), [kawashima.masahiro.wr@mail.hosp.go.jp](mailto:kawashima.masahiro.wr@mail.hosp.go.jp) (M. Kawashima), [suzuki.junko.fv@mail.hosp.go.jp](mailto:suzuki.junko.fv@mail.hosp.go.jp) (J. Suzuki), [yamane.akira.yu@mail.hosp.go.jp](mailto:yamane.akira.yu@mail.hosp.go.jp) (A. Yamane), [inoue.yuta.ry@mail.hosp.go.jp](mailto:inoue.yuta.ry@mail.hosp.go.jp) (Y. Inoue), [fukami.takeshi.ej@mail.hosp.go.jp](mailto:fukami.takeshi.ej@mail.hosp.go.jp) (T. Fukami), [kitani.masashi.ge@mail.hosp.go.jp](mailto:kitani.masashi.ge@mail.hosp.go.jp) (M. Kitani), [ftakahas@iwate-med.ac.jp](mailto:ftakahas@iwate-med.ac.jp) (F. Takahashi).

<https://doi.org/10.1016/j.rmcr.2022.101664>

Received 11 January 2022; Received in revised form 28 March 2022; Accepted 29 April 2022

Available online 4 May 2022

2213-0071/© 2022 The Authors. Published by Elsevier Ltd. This is an open access article under the CC BY-NC-ND license (<http://creativecommons.org/licenses/by-nc-nd/4.0/>).

increase in MACLD cases, growing attention has been placed on MACLD comorbidity among patients with lung cancer [5,6]. Several reports from Japan have indicated a relationship between NTMLD/MACLD and lung cancer, with NTMLD having been implicated as a risk factor for lung cancer [7]. Approximately 2%–3% of MACLD cases present with lung cancer, whereas 1% of lung cancer cases test positive for MACLD [8–10]. Moreover, MACLD has been detected concurrently with and/or after lung cancer resection [5–10]. Considering the unclear clinical presentation and outcomes of comorbid MACLD after lung cancer resection, we retrospectively assessed the 5-year follow-up data of patients who developed comorbid MACLD following lung cancer resection.

## 2. Methods

The lung cancer database of Tokyo National Hospital, Tokyo, Japan was used to identify consecutive lung cancer resection cases between January 1999 and December 2018. The hospital's *Mycobacterium* database was subsequently surveyed for the presence of *Mycobacterium avium* and *Mycobacterium intracellulare* among those who underwent resection. Background information, mycobacterial data, computed tomography findings, and MACLD medication were obtained through medical records. MACLD was diagnosed based on the official statement by the American Thoracic Society and Infectious Diseases Society of America [11].

All respiratory samples were cultured using *Mycobacterium* growth indicator tubes (BACTEC MGIT 960: Becton, Dickinson and Company, Franklin Lakes, NJ, USA). Until June 2018, mycobacterial species were identified using DNA–DNA hybridization (DDH, Kyokuto Seiyaku, Tokyo, Japan) based on the quantitative microdilution plate hybridization method that can clearly distinguish between *Mycobacterium avium* and *Mycobacterium intracellulare* [12]. Thereafter, matrix-assisted laser desorption-ionization time-of-flight mass spectrometry (MALDI-TOF MS, LSI Medience, Tokyo, Japan) was used. MACLD exacerbation was defined as worsening based on radiographic imaging and an increase in cough/sputum accompanied by *Mycobacterium*-positive cultures from respiratory samples. Patients who underwent lung cancer resection were followed-up as outpatients for 5 years after surgery, during which all pulmonary distresses were treated. Data were analyzed using Wilcoxon rank-sum test and Fisher's exact test using the R statistical software Package "cmprsk" (<https://www.r-project.org>), with P values < 0.05 indicating statistical significance.

This case report has been reported in line with the CARE checklist [13]. This retrospective study was approved by the Ethics Committee of the National Hospital Organization Tokyo National Hospital (approval no. 345/2017) and was conducted according to the principles of the Declaration of Helsinki.

## 3. Results

Among a total of 1275 lung cancer resection cases were reviewed, 17 cases (1.3%) with comorbid MACLD were assessed and divided into two groups: those whose lung cancer was detected after MACLD (MACLD-preceding; 7 cases) and those with concurrent diagnoses (MACLD-concurrent; 10 cases). The characteristics of these patients are summarized in Table 1. Women accounted for the majority of cases [13 cases; median age, 71 years (range: 40–80 years); median body mass index, 21.1 (range: 18.6–26.5)]. Six patients had a history of smoking, one patient had previous tuberculosis, and another one had chronic obstructive pulmonary disease (COPD).

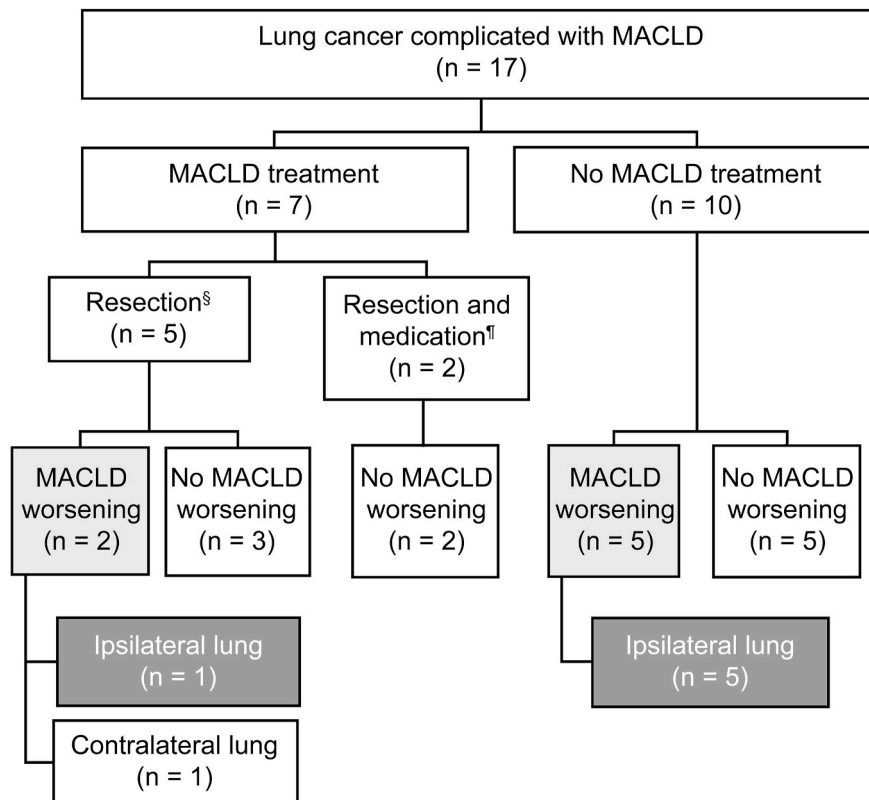
**Table 1**  
Patient characteristics.

Factors	MACLD-preceding (n = 7)	MACLD-concurrent (n = 10)	Total (n = 17)	P
<b>Background</b>				
Female	6 (86%)	7 (70%)	13	0.6029
Median age	72 (67–75)	69 (40–80)	71 (40–80)	0.7320
BMI	21.1 (18.6–23.6)	21.2 (18.8–26.5)	21.1 (18.6–26.5)	0.9623
Smoking	1 (14%)	5 (50%)	6	0.3043
Pulmonary diseases	1 (14%)	1 (10%)	2	1.0000
<b>MACLD at lung cancer surgery</b>				
Sputum smear-positive	2 (29%)	3(30%)	5	1.0000
Species	7 (100%)	8 (80%)	15	0.4853
<i>Mycobacterium avium</i>				
<b>CT findings</b>				
Multi-lobes lesions	7 (100%)	7 (70%)	14	0.2279
Bronchiectasis	7 (100%)	9 (90%)	16	1.0000
Cavity	2 (29%)	3 (30%)	5	1.0000
Resection for MACLD	3 (43%)	2 (20%)	5	0.5928
ECG in resected materials	5 (71%)	7 (70%)	12	1.0000
<b>Lung cancer</b>				
Histologic type				
Adenocarcinoma	6 (86%)	7 (70%)	13	0.6029
Site				
Lower lobe	4 (57%)	5 (50%)	9	1.0000
Resection				
Lobectomy	5 (71%)	10 (100%)	15	0.1544
Pathologic stage				
Stage I	5 (71%)	9 (90%)	14	0.5368

BMI, body mass index; MACLD, *Mycobacterium avium* complex lung disease; ECG, epithelioid cell granuloma.

*Mycobacterium avium* was present in 15 cases identified using DDH or MALDI-TOF MS, and *Mycobacterium intracellulare* was identified using DDH in the remaining two cases. MACLD-related computed tomography findings showed that multi-lobed lesions (14 cases) and bronchiectasis (16 cases) were more predominant over cavities (5 cases). Among the included cases, 16 had nodular bronchiectasis-type MACLD, whereas only one had fibro-cavitary-type MACLD. The histologic types of lung cancer were adenocarcinoma, squamous cell carcinoma, and carcinoid in 13, 3, and 1 case, respectively. The sites of cancer were lower, upper, and middle lobes in 9, 5, and 3 cases, respectively. The surgery types were lobectomy, segmentectomy, and partial resection in 15, 1, and 1 case, respectively. The pathological stages were IA and IB in 9 and 5 cases, respectively, whereas stage IIB, IIIA, and IVA lung cancer were present in one case each. No differences in background, MACLD, and lung cancer were noted between the MACLD-preceding and -concurrent groups. In the MACLD-preceding group, the median duration from MACLD to lung cancer diagnosis was 51 months (range: 18–152 months). Two MACLD-preceding cases had a history of treatment with MACLD medication [rifampicin, ethambutol, and clarithromycin (RECAM)]. However, upon lung cancer diagnosis, bronchoscopic specimens showed positive results for *Mycobacterium avium*. None of the 17 cases had a history of thoracic surgery before lung cancer resection.

The management and course of MACLD after lung cancer surgery is shown in Fig. 1. Accordingly, 7 (41%) patients exhibited postoperative MACLD exacerbation, with no difference in frequency between MACLD-preceding (3 of 7, 43%) and -concurrent cases (4 of 10, 40%). Among the 10 cases whose treatment consisted of only surgery (median: 38 months; range: 11–60 months), 5 exhibited MACLD exacerbation within a median period of 12 months post-surgery (range: 3–42 months). The other five patients with conspicuous MACLD lesions underwent additional resection for MACLD volume reduction in the ipsilateral lung (partial resection of the middle lobe, three patients; partial resection of the right S6, one patient; and lingulectomy, one patient) together with lung cancer surgery. None of the five patients received postoperative RECAM therapy during follow-up (median: 60 months; range: 26–60 months). MACLD exacerbation was observed in two of these patients at 5 and 24 months. The remaining two cases developed lung cancer and MACLD exclusively in the same lobe, both of whom underwent complete resection through a lobectomy, followed by RECAM therapy for 2 years. No MACLD exacerbation was detected until 60 months post-resection. None of the patient's experienced serious adverse respiratory events during the perioperative period had respiratory dysfunction after surgery (except for one patient who had COPD). MACLD exacerbation was found in five of the nine patients who underwent lower lobectomy and in two of the five patients who



§: Additional conspicuous resection (volume reduction) for MACLD,

¶: Complete resection for both lung cancer and MACLD localized in the same lobe, followed by administration of rifampicin, ethambutol, and clarithromycin

Fig. 1. Clinical course of lung cancer and *Mycobacterium avium* complex lung disease (MACLD). Flow diagram for MACLD treatment in patients who underwent lung cancer resection complicated with MACLD.

underwent upper lobectomy. Mycobacterial species was found to be *Mycobacterium avium* in all seven patients with exacerbation. During the study observation period, three patients received anticancer treatment after surgery. Two patients received anticancer medication immediately after the surgery, including one patient who received erlotinib for stage IVA cancer and one patient who received adjuvant carboplatinum plus paclitaxel for stage IIIA cancer. Both patients experienced MACLD exacerbation. The remaining one patient received osimertinib after recurrence (bone metastasis). MACLD exacerbation occurred at the time of recurrence; however, treatment for MACLD was not initiated. Six of the seven cases who developed MACLD exacerbation did so in the operated ipsilateral residual lobes (Fig. 2). The patient showing contralateral exacerbation underwent left lower lobectomy for lung cancer with additional lingulectomy for MACLD. Thus, the residual left upper lobe no longer displayed substantial MACLD lesions. To evaluate the likelihood of exacerbation in the lung ipsilateral/contralateral to the resection, a binomial test was performed. Accordingly, no significant tendency for ipsilateral exacerbation was found ( $P = 0.125$ , 95% CI: 42.1%–99.6%). However, MACLD exacerbation could likely be possible in the ipsilateral residual lobes, especially in cases that underwent only lung cancer surgery.

Given the lack of a standard treatment strategy for the treatment of comorbid MACLD in patients who underwent lung cancer resection, MACLD treatment was decided through individual consultation. RECAM therapy was introduced in six of the seven cases who developed exacerbation. Among these patients, four completed a 2-year RECAM therapy regimen, of whom three (43%) showed improvement in both symptoms and radiographic findings. Among the 17 cases, 4 experienced lung cancer recurrences during the follow-up period with two lung cancer-related deaths not associated with MACLD.

#### 4. Discussion

This has been the first study to examine the effects of lung cancer surgery in patients with lung cancer and comorbid MACLD. Accordingly, our findings showed that MACLD exacerbation was mostly observed in the residual lobe of the operated ipsilateral lung, although differences were not significant.

Risk factors for NTMLD/MACLD include impairment in systemic and local immunity, such as that during malignancies, thoracic deformities, and pre-existing structural pulmonary diseases (COPD and bronchiectasis) [14]. Apart from the reduced immunological situation accompanying lung cancer surgery with or without anticancer treatment, thoracic deformations caused by the surgery, such as ipsilateral intercostal narrowing, diaphragm elevation, and shift of the mediastinum [15], may be associated with MACLD exacerbation. Sequelae after lung cancer surgery may include fibrobullous changes in the ipsilateral residual lobes where NTM or *Aspergillus* infections can occur [16]. We had previously identified that pre-existing lung diseases, such as COPD, were risk factors for chronic pulmonary aspergillosis (CPA) after lung cancer surgery and that postoperative re-expansion was often linked to CPA development in the residual lobes [17]. Although non-smoking women accounted for most of the cases include herein, re-expanded residual lobes accompanied by pre-existing MACLD may generate a local condition similar to that associated with MACLD susceptibility in COPD. Studies have shown that MACLD has a very long course, with an exacerbation rate of 22% after 5 years [18]. As such, early MACLD exacerbation in the current study (median: 12 months post-surgery) may be related to impaired immune function as mentioned earlier.

Surgery for NTMLD is typically performed as an adjuvant therapy along with NTMLD medication, with segmentectomy and/or lobectomy having been associated with favorable outcomes [18,19]. One study showed that postoperative drug therapy for NTMLD may be unnecessary when complete or partial resection of a solitary nodule of NTMLD is performed [20]. In this study, five patients

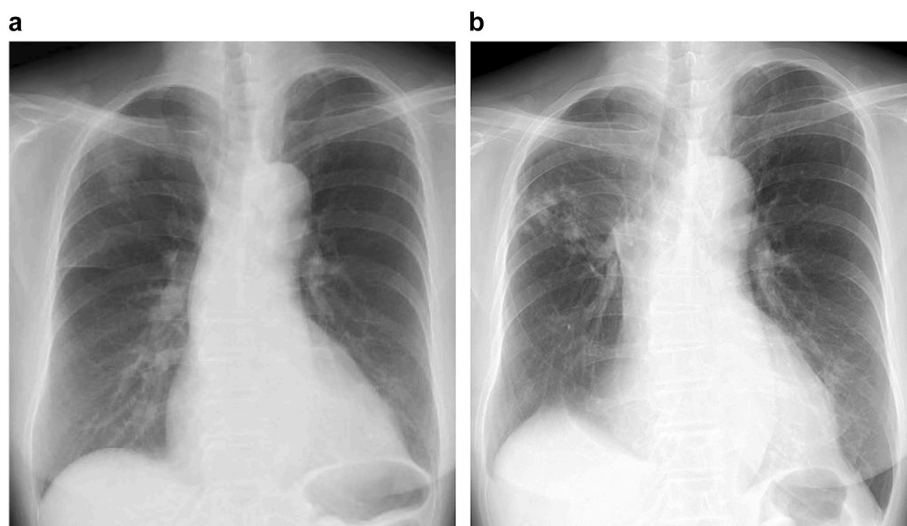


Fig. 2. *Mycobacterium avium* complex lung disease worsening after lung cancer surgery.

(a) Chest X-ray of a patient before right upper lobectomy for the treatment of stage I lung cancer. *Mycobacterium avium* was detected in the sputum and bronchoscopic samples from the right main bronchus, with minute inflammatory changes observed in the middle lung fields. (b) Chest X-ray of the patient 15 months after lobectomy. Infiltrative and nodular shadows appeared in the right residual lobes. Bronchoscopy revealed positive smear and culture results for *Mycobacterium avium*.

underwent volume reduction for MACLD without medication, among whom two presented with MACLD exacerbation from remnant MACLD lesions. As such, the significance of additional resection for MACLD in combination with lung cancer surgery warrants further assessment.

Meier et al. reported that 6 of 13 (46%) patients with MACLD previously treated for lung cancer showed improvement with MACLD medication [5]. In the current study, only 3 of 7 (43%) patients showed MACLD improvement with RECAM therapy, which can be considered relatively poor compared to current treatment outcomes for MACLD [1]. The course of lung cancer may interfere with RECAM therapy, with such a therapy appearing to have no benefit when MACLD exacerbation occurs.

The current study has several limitations worth noting. First, this was a single-center, retrospective study, with a small sample size of mostly older females with early adenocarcinoma. Second, no clear criteria for the additional resection of MACLD or for assessing RECAM therapy are available. Third, MACLD therapy was performed individually, and the time for assessing MACLD exacerbation was limited to 5 years after surgery.

## 5. Conclusion

In conclusion, lung cancer resection in cases with comorbid MACLD may exacerbate MACLD over a relatively short period of time, particularly in the ipsilateral residual lobes. Although limited information has been available regarding the significance of MACLD treatment, RECAM therapy may be appropriate in cases developing MACLD exacerbation. Nonetheless, further large-scale prospective investigations on patients with comorbid MACLD who had undergone lung cancer resection are warranted.

## Funding

This research did not receive any specific grant from funding agencies in the public, commercial, or not-for-profit sectors.

## Ethical approval

This study was approved by the Ethics Committee of the National Hospital Organization Tokyo National Hospital (approval no. 345/2017).

## Declarations of interest

The authors declare no potential conflicts of interest.

## Consent

Written informed consent was obtained from all patients at surgery.

## Availability of data and materials

All data relevant to the study are included in the article.

## Authors' contributions

Conceptualization: TA; Data curation: KM, SJ, IY, KM; Formal analysis: TF; Funding acquisition: TA; Investigation: TA, KM, IY, KM; Methodology: TA, YA, FT, KM; Project administration: TA; Resources: TA, KM, FT, KM; Software: TA, TF; Supervision: TA, YA; Validation: TA, SJ, IY, KM, TF; Visualization: TA, FT. All authors have read and approved the manuscript.

## Acknowledgements

Not applicable.

## List of abbreviations

COPD	Chronic obstructive pulmonary disease
CPA	Chronic pulmonary aspergillosis
MACLD	<i>Mycobacterium avium</i> complex lung disease
NTM	Nontuberculous Mycobacterium
NTMLD	Nontuberculous Mycobacterium-associated lung disease
RECAM	Rifampicin, ethambutol, and clarithromycin

## References

- [1] C.H. Weiss, J. Glassroth, Pulmonary disease caused by nontuberculous mycobacteria, *Expet Rev. Respir. Med.* 6 (2012) 597–612, <https://doi.org/10.1586/ers.12.58>.
- [2] S. Simons, J. van Ingen, P.R. Hsueh, N. Van Hung, P.N. Dekhuijzen, M.J. Boeree, et al., Nontuberculous mycobacteria in respiratory tract infections, eastern Asia, *Emerg. Infect. Dis.* 17 (2011) 343–349, <https://doi.org/10.3201/eid1703.100604>.
- [3] C.L. Daley, J.M. Iaccarino, C. Lange, E. Cambau, R.J. Wallace Jr., C. Andrejak, et al., Treatment of nontuberculous mycobacterial pulmonary disease: an official ATS/ERS/ESCMID/IDSA clinical practice guideline, *Clin. Infect. Dis.* 71 (2020) e1–e36.
- [4] N. Kwak, J. Park, E. Kim, C.H. Lee, S.K. Han, J.J. Yim, Treatment outcomes of *Mycobacterium avium* complex lung disease: a systematic review and meta-analysis, *Clin. Infect. Dis.* 65 (2017) 1077–1084, <https://doi.org/10.1093/cid/cix517>.
- [5] L. Lande, D.D. Peterson, R. Gogoi, G. Daum, K. Stampfer, R. Kwait, et al., Association between pulmonary *Mycobacterium avium* complex infection and lung cancer, *J. Thorac. Oncol.* 7 (2012) 1345–1351, <https://doi.org/10.1097/JTO.0b013e31825abd49>.
- [6] E. Meier, K. Pennington, A. Gallo de Moraes, P. Escalante, Characteristics of *Mycobacterium avium* complex (MAC) pulmonary disease in previously treated lung cancer patients, *Respir. Med. Case Rep.* 22 (2017) 70–73, <https://doi.org/10.1016/j.rmcr.2017.06.012>.
- [7] T. Kusumoto, T. Asakura, S. Suzuki, S. Okamori, H. Namkoong, H. Fujiwara, et al., Development of lung cancer in patients with nontuberculous mycobacterial lung disease, *Respir. Investig.* 57 (2019) 157–164, <https://doi.org/10.1016/j.resinv.2018.11.004>.
- [8] C. Hosoda, E. Hagiwara, T. Shinohara, T. Baba, R. Nishihira, S. Komatsu, et al., Clinical characteristics of pulmonary *Mycobacterium avium* complex infection complicated with lung cancer, *Kekkaku* 89 (2014) 691–695 [Article in Japanese].
- [9] A. Tamura, A. Hebisawa, K. Kusaka, T. Hirose, J. Suzuki, A. Yamane, et al., Relationship between lung cancer and *Mycobacterium avium* complex isolated using bronchoscopy, *Open Respir. Med. J.* 10 (2016) 20–28, <https://doi.org/10.2174/1874306401610010020>.
- [10] T. Tsuji, K. Tsuyuguchi, K. Tachibana, Y. Kimura, T. Kobayashi, S. Minomo, et al., Analysis of the impact of lung cancer treatment on nontuberculous mycobacterial lung diseases, *Respir. Investig.* 55 (2017) 45–50, <https://doi.org/10.1016/j.resinv.2016.08.002>.
- [11] D.E. Griffith, T. Aksamit, B.A. Brown-Elliott, A. Catanzaro, C. Daley, F. Gordin, et al., ATS mycobacterial diseases subcommittee, American thoracic society, infectious disease society of America ATS mycobacterial diseases subcommittee, an official ATS/IDSA statement: diagnosis, treatment, and prevention of nontuberculous mycobacterial diseases, *Am. J. Respir. Crit. Care Med.* 175 (2007) 367–416, <https://doi.org/10.1164/rccm.200604-571ST>.
- [12] S. Kusunoki, T. Ezaki, M. Tamesada, Y. Hatanaka, K. Asano, Y. Hashimoto, et al., Application of colorimetric microdilution plate hybridization for rapid genetic identification of 22 *Mycobacterium* species, *J. Clin. Microbiol.* 29 (1991) 1596–1603.
- [13] J.J. Gagnier, G. Kienle, D.G. Altman, D. Moher, H. Sox, D. Riley, The CARE guidelines: consensus-based clinical case reporting guideline development, *BMJ Case Rep.* (2013), bcr2013201554, <https://doi.org/10.1136/bcr-2013-201554>.
- [14] P. Sexton, A.C. Harrison, Susceptibility to nontuberculous mycobacterial lung disease, *Eur. Respir. J.* 31 (2008) 1322–1333, <https://doi.org/10.1183/09031936.00140007>.
- [15] S. Bommart, J.P. Berthet, G. Durand, B. Ghaye, J.L. Pujol, C. Marty-Ané, et al., Normal postoperative appearances of lung cancer, *Diagn. Interv. Imaging* 97 (2016) 1025–1035, <https://doi.org/10.1016/j.diii.2016.08.014>.
- [16] H. Tanaka, A. Matsumura, M. Ohta, N. Ikeda, N. Kitahara, K. Iuchi, Late sequelae of lobectomy for primary lung cancer: fibrobullous changes in ipsilateral residual lobes, *Eur. J. Cardio. Thorac. Surg.* 32 (2007) 859–862, <https://doi.org/10.1016/j.ejcts.2007.09.012>.
- [17] A. Tamura, J. Suzuki, T. Fukami, H. Matsui, S. Akagawa, K. Ohta, et al., Chronic pulmonary aspergillosis as a sequel to lobectomy for lung cancer, *Interact. Cardiovasc. Thorac. Surg.* 21 (2015) 650–656, <https://doi.org/10.1093/icvts/ivv239>.
- [18] S. Kitada, T. Uenami, K. Yoshimura, Y. Tateishi, K. Miki, M. Miki, et al., Long-term radiographic outcome of nodular bronchiectatic *Mycobacterium avium* complex pulmonary disease, *Int. J. Tubercul. Lung Dis.* 16 (2012) 660–664, <https://doi.org/10.5588/ijtld.11.0534>.
- [19] Y. Shiraishi, N. Katsuragi, H. Kita, A. Hyogotani, M.H. Saito, K. Shimoda, et al., Adjuvant surgical treatment of nontuberculous mycobacterial lung disease, *Ann. Thorac. Surg.* 96 (2013) 287–291, <https://doi.org/10.1016/j.athoracsur.2013.03.008>.
- [20] N. Ose, H. Maeda, Y. Takeuchi, Y. Susaki, Y. Kobori, S. Taniguchi, et al., Solitary pulmonary nodules due to non-tuberculous mycobacteriosis among 28 resected cases, *Int. J. Tubercul. Lung Dis.* 20 (2016) 1125–1129, <https://doi.org/10.5588/ijtld.15.0819>.