

Ramp Lesions of the Medial Meniscus in Patients Undergoing Primary and Revision ACL Reconstruction

Prevalence and Risk Factors

George C. Balazs,^{*†} MD, Harry G. Greditzer IV,[‡] MD, Dean Wang,[§] MD, Niv Marom,[†] MD, Hollis G. Potter,[‡] MD, Robert G. Marx,[†] MD, Scott A. Rodeo,[†] MD, and Riley J. Williams III,[†] MD
Investigation performed at the Hospital for Special Surgery, New York, New York, USA

Background: Ramp lesions are peripheral tears of the posterior horn of the medial meniscus that involve the meniscocapsular attachments or red-red zone and typically occur in conjunction with anterior cruciate ligament (ACL) ruptures.

Purpose: To identify the prevalence of, and risk factors for, ramp lesions in a large cohort of patients undergoing primary and revision ACL reconstruction.

Study Design: Case series; Level of evidence, 4.

Methods: We queried our institutional registry of patients who underwent primary or revision surgical treatment for an ACL injury. Those who underwent preoperative magnetic resonance imaging (MRI) at our facility were included in the study. Clinical details were extracted and verified using electronic records. All preoperative MRI scans were reviewed by a musculoskeletal radiologist for the presence of a ramp lesion. Stable ramp lesions were defined as a peripheral posterior horn medial meniscal tear identified on MRI but either not identifiable with viewing and probing from the anterior portals or, if identified, not displaceable with anteriorly directed probing. Unstable ramp lesions were defined as peripheral posterior horn medial meniscal tears at the meniscocapsular junction that were identifiable at the time of surgery and displaced into the medial compartment with probing. The prevalence of stable and unstable ramp lesions was calculated. Demographic, injury, and imaging parameters were determined using univariate statistics.

Results: A total of 372 patients were included. The overall prevalence of ramp lesions was 42% (155/372). Unstable ramp lesions were present in 73 (20%) patients, and stable ramp lesions were present in 82 (22%) patients. The presence of any ramp lesion (stable or unstable) was associated with bone marrow edema of the posteromedial tibia on MRI (odds ratio [OR], 3.0; $P < .0001$), a contact injury mechanism (OR, 1.8; $P = .02$), and a concurrent lateral meniscal tear (OR, 1.7; $P = .02$). No demographic, injury, surgical, or radiological variable was associated with a stable versus unstable ramp lesion.

Conclusion: The overall prevalence of a ramp lesion in patients treated for ACL ruptures at our institution was 42%. The presence of bone marrow edema of the posteromedial tibia, a contact injury mechanism, or a lateral meniscal tear should alert surgeons to the potential presence of a medial meniscal ramp lesion.

Keywords: ACL; meniscus; knee; ramp lesion

Meniscal tears occur frequently in the setting of anterior cruciate ligament (ACL) ruptures, with rates reported as high as 79% after an acute injury.⁷ Medial meniscal injuries are particularly concerning because the posterior horn of the medial meniscus has been shown to be an important secondary stabilizer against anterior tibial translation.^{17,18} The repair of unstable posterior horn meniscal lesions is recommended, when possible, to preserve both the

secondary stabilizing role of the meniscus and its function in load transmission to the articular surface.⁴

Strobel²² described “a special type of meniscal injury [involving] the peripheral attachment of the posterior horn of the medial meniscus” occurring in conjunction with an ACL injury. While various authors have differing definitions of what constitutes a “ramp lesion,” most include meniscocapsular separation and meniscosynovial tears, with variable inclusion of tears of the red-red zone of the peripheral posterior horn or junction of the posterior horn and body. Meniscocapsular separation in the absence of an ACL injury has also been described as a cause of medial knee

pain,⁸ although the term “ramp lesion” is generally reserved for cases of concurrent ACL ruptures. Thaumat et al²³ classified these tears as types 1 through 5, distinguished by the anatomic location of the tear and layer(s) involved. Types 1 and 2 represent stable tears that do not displace with probing, while types 3 and 4 are typically unstable and displace with probing. The stability of type 5 lesions (“double tears”) is not specified in their original work. Several authors have argued that direct visualization of the posterior compartment through the intercondylar notch, accompanied by probing through a posteromedial portal, is necessary to adequately diagnose and treat these ramp lesions.^{1,20}

The prevalence of ramp lesions has been estimated to be 9.3% to 40% of patients undergoing ACL reconstruction.^{3,6,13,20} However, these studies often fail to distinguish stable lesions (which are difficult to diagnose using standard 2-portal arthroscopic surgery) from unstable lesions (which displace into the joint with anterior probing). This distinction is of particular interest to arthroscopic surgeons because there is evidence that stable tears of the posterior horn may heal in the setting of ACL ruptures without formal repair.^{14,25}

The purpose of this study was 2-fold. First, we sought to identify the prevalence of both stable and unstable meniscal ramp lesions among patients surgically treated at our facility for ACL ruptures. Second, we wished to evaluate whether specific demographic or injury variables are associated with stable and/or unstable ramp lesions among patients undergoing ACL reconstruction at our facility.

METHODS

Patient Cohort

Patients for this cohort were identified using the Hospital for Special Surgery ACL Registry, which prospectively registered patients from 2009 to 2013. All registered patients were treated at our facility for an ACL injury and underwent surgery for the same. After registration, all patients completed a preoperative baseline questionnaire including demographic information and circumstances of the injury.

Data collection for this registry was approved by our local institutional review board, and all participating patients signed an informed consent document at the time of registration. Data extraction from the registry and the collection of additional information from electronic medical records were approved by our institutional review board in a supplemental application.

Patients were included if they consented to inclusion in our institutional registry, underwent preoperative magnetic resonance imaging (MRI) of the affected knee performed at our facility, and underwent surgery for their ACL rupture at our facility. We elected to include patients who had sustained either a rupture of their native ACL or a rerupture of a previously reconstructed ACL. We also included patients with prior ipsilateral knee surgery for non-ACL reasons. We are not aware of any prior reports of the rates of ramp lesions in patients undergoing revision ACL reconstruction and felt that this information might be of value to practicing clinicians.

Patients were excluded if they did not have preoperative MRI scans available in our system or had MRI performed at another institution. This was to ensure that a standardized imaging protocol was available to our blinded radiology reviewer.

Radiographic Evaluation

All preoperative MRI scans were obtained utilizing a standard clinical 3.0-T MRI scanner (GE Healthcare). All images were obtained with a standardized quadrature or 8-channel knee coil (Invivo). The MRI pulse sequences at the time of the initial evaluation included a standardized cartilage-sensitive protocol with a moderate echo time (TE) using the fast spin echo (FSE) technique: repetition time (TR), 3500-6500 milliseconds; TE, 28-36 milliseconds (effective); and matrix, 512 × 384 (sagittal), 512 × 256-288 (coronal), and 512 × 256-288 (axial) at 2 excitations. Standardized FSE cartilage imaging provided an in-plane resolution of 253-312 × 338-416 μm. An additional sagittal, frequency-selective, fat-suppression pulse sequence was performed: TR, 4000-6000 milliseconds; TE, 40-50 milliseconds (effective); and matrix, 256 × 224 at 2 excitations. The slice thickness for the sagittal non-fat suppression sequence was 3.5 mm with no gap and for the fat-suppression sequence was 4.0 mm with no gap; coronal images were obtained with a 3.5-mm slice thickness without a gap, as were axial images.

All MRI scans were evaluated by the same board-certified musculoskeletal radiologist (H.G.G.) with over 8 years' experience in MRI interpretation. The radiologist was blinded to any clinical data. The images were evaluated for the presence of a ramp lesion, defined on MRI by vertically oriented signal hyperintensity of the posterior horn of the medial meniscus at the meniscocapsular junction on sagittal, frequency-selective, fat-suppression pulse

*Address correspondence to George C. Balazs, MD, Sports Medicine and Shoulder Service, Hospital for Special Surgery, 535 East 70th Street, New York, NY 10021, USA (email: gcbalazs@gmail.com).

†Sports Medicine and Shoulder Service, Hospital for Special Surgery, New York, New York, USA.

‡Department of Radiology and Imaging, Hospital for Special Surgery, New York, New York, USA.

§Department of Orthopaedic Surgery, University of California, Irvine, Irvine, California, USA.

One or more of the authors has declared the following potential conflict of interest or source of funding: H.G.P. has received research support from GE Healthcare and the National Basketball Association, is a consultant for Ortho RTI, and has received hospitality payments from DePuy. S.A.R. is a consultant for JRF and has stock/stock options in Ortho RTI. R.G.M. receives royalties from Springer and Demos Health. R.J.W. is a consultant for Aperion, Arthrex, Histogenics, and JRF; has stock/stock options in CyMedica, Gramercy Extremity Orthopedics, Pristine Surgical, and RecoverX; receives royalties from Arthrex and Springer; and has received hospitality payments from Stryker. AOSSM checks author disclosures against the Open Payments Database (OPD). AOSSM has not conducted an independent investigation on the OPD and disclaims any liability or responsibility relating thereto.

Ethical approval for this study was obtained from the Hospital for Special Surgery Institutional Review Board.

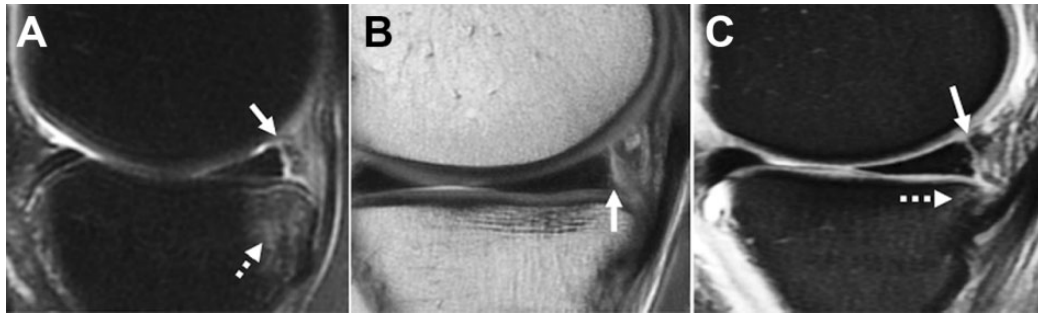


Figure 1. Magnetic resonance imaging of a ramp lesion in the sagittal plane. (A) Ramp lesion (arrow) defined as vertically oriented fluid signal intensity undermining the posterior horn of the medial meniscus at the meniscocapsular junction. Note the bone marrow edema pattern (dotted arrow). (B) Ramp lesion (arrow) on proton density imaging demonstrating intact medial compartment cartilage (modified Noyes score 0). (C) Subtle ramp lesion (arrow) with a faint bone marrow edema pattern (dotted arrow).

sequences.²⁶ The MRI scans were further evaluated for the modified Noyes cartilage score of the lateral tibial plateau, lateral femoral condyle, medial femoral condyle, medial tibial plateau, trochlea, and patella.¹⁰ The bone marrow edema pattern was assessed and quantified as absent or present over the posteromedial tibial plateau. Examples are shown in Figure 1.

Clinical and Intraoperative Data Collection

Registry data for all patients were extracted and included the date of surgery, affected side, surgeon, demographic variables (age, sex, height/weight, level of activity, smoking status), circumstances of the injury, and details of previous ipsilateral knee surgery. Standing coronal-plane alignment and patellar alignment were recorded. Intraoperative data were also extracted to include the type of ACL tear (partial or complete), presence of other intra-articular injuries and their location, details of ACL treatment (graft type, single vs double bundle, graft fixation technique, femoral drilling technique), and details of any associated procedures performed. In cases where data were missing from the registry, existing electronic medical records were searched to fill in missing variables.

Within our registry, meniscal tear location is reported using the terminology defined by Cooper et al.⁵ Tears in the A0/AB0 region (meniscosynovial/meniscocapsular tears of the posterior horn and/or junction with the body) and A1/AB1 region (peripheral tears within 2-3 mm of the capsule at the posterior horn and/or junction with the body) were classified as ramp lesions. This is consistent with the classification scheme proposed by Thaunat et al.²³ Tears of the medial meniscus occurring outside these regions were noted during data collection but were not classified as ramp lesions.

We subcategorized identified ramp lesions into unstable versus stable tears. Unstable tears were those that were identified at the time of surgery by their ability to be displaced into the medial compartment of the knee with anteriorly directed probing. Stable tears were those that were

identified on a blinded MRI review but that could not be displaced into the medial compartment at the time of surgery.

Surgical Technique

Details of the entire cohort contained in the Hospital for Special Surgery ACL Registry have been previously described.¹⁶ Surgical procedures were performed by 19 surgeons. A variety of ACL treatment techniques were utilized, and a number of secondary procedures were performed depending on preoperative imaging and intraoperative examination findings. All patients were positioned supine on the operating room table, with most receiving neuraxial anesthesia, unless the presence of medical comorbidities precluded this. An examination under anesthesia was performed to include the Lachman test and pivot-shift maneuver.

As verified by intraoperative records, all patients underwent a standard 2-portal arthroscopic examination of the knee. No patient had a posteromedial or posterolateral portal placed. An arthroscopic probe was used to manipulate the meniscus to determine stability. Although the determination of stability and the need for repair were ultimately a subjective decision made by the surgeon, in general, the meniscus was deemed stable if it could not be displaced into the medial compartment. Meniscal injuries were addressed either through repair, debridement, or abrasion to stimulate local vascularity. In general, meniscal tears were repaired with the all-inside suture technique when the meniscus was displaceable with probing, as discussed above. The remaining tears were either debrided, abraded, or left untreated.

ACL reconstruction techniques varied between patients and included single-bundle and double-bundle reconstructions using an autograft (bone–patellar tendon–bone, hamstring, or quadriceps) or allograft. Femoral tunnels were drilled utilizing a transtibial approach, an accessory anteromedial portal, or the standard medial portal. Aperture or suspensory fixation was employed in all patients, and “hybrid” fixation techniques utilizing backup fixation methods were sometimes utilized. No patient underwent graft

fixation using femoral transfixion pins. Two patients underwent arthroscopic surgery without ACL reconstruction because of an intact ligament that took up adequate tension on intraoperative testing.

Statistical Analysis

Cohort features are reported descriptively using counts, means, and ranges. The primary variables were the presence or absence of any type of ramp lesion or the type of ramp lesion sustained. Univariate associations between the primary outcomes and candidate risk factors were assessed using the chi-square (for nondichotomous variables) or Fisher exact test (for dichotomous variables), and the Mann-Whitney *U* test was used for continuous variables. All analyses were performed using SPSS Statistics for Mac (v 25; IBM).

RESULTS

Cohort Characteristics

A total of 372 patients met the inclusion criteria. There was a slight predominance of male patients and right-sided injuries. Most patients were white (80%), had sustained noncontact injuries (75%), and had no prior ipsilateral knee surgery (85%). The demographic characteristics of the study population are summarized in Table 1.

MRI and Surgical Assessment

All 372 preoperative MRI scans were reviewed in a blinded fashion as specified above. The majority of patients sustained a complete ACL rupture (94%), with the remainder having a high-grade partial tear on MRI, which was subsequently confirmed to be a full tear at surgery. Bone marrow edema of the posteromedial tibia was present in 41% of patients. Most patients had normal or near-normal chondral surfaces, with >94% having a cartilage score of $\leq 2A$ (articular cartilage loss <50% of native cartilage thickness) in the patellofemoral joint and medial compartment. A higher proportion of patients had a cartilage score of $\geq 2B$ (articular cartilage loss >50% of native cartilage thickness) in the lateral compartment, but the overall number of patients with degenerative changes on the chondral surfaces was low (11%). Additional clinical, surgical, and imaging findings are summarized in Table 2.

Ramp Lesions

Overall, 155 patients (42%) had a ramp lesion of the medial meniscus. Patients were significantly more likely to have a ramp lesion if they sustained a contact injury to the knee (odds ratio [OR], 1.8; $P = .02$), had bone marrow edema of the posteromedial tibia (OR, 3.0; $P < .0001$), or had a concurrent lateral meniscal tear (OR, 1.7; $P = .02$). No other demographic, clinical, surgical, or radiological

TABLE 1
Demographic Profile^a

Age, y	
Mean (range)	31 (13-61)
Median	29
BMI (n = 343), kg/m ²	
Mean (range)	24.2 (15.8-39.5)
Median	23.8
BMI group (n = 343)	
<25 kg/m ²	215 (63)
≥ 25 kg/m ²	128 (37)
Sex	
Male	216 (58)
Female	156 (42)
Race (n = 344)	
White	275 (80)
Nonwhite	69 (20)
Smoking status (n = 345)	
Smoker	19 (6)
Nonsmoker	326 (94)
Mechanism of injury	
Contact	93 (25)
Noncontact	279 (75)
Sports level of play (n = 362)	
Recreational	271 (75)
High school	63 (17)
Collegiate	23 (7)
Professional	5 (1)
Affected side	
Right	190 (51)
Left	182 (49)
Prior ipsilateral knee surgery (for any reason)	
Yes	56 (15)
No	316 (85)
Prior ipsilateral ACL reconstruction	
Yes	41 (11)
No	331 (89)
Prior ipsilateral meniscal surgery	
Yes	25 (7)
No	347 (93)

^aData are reported as n (%) unless otherwise indicated. ACL, anterior cruciate ligament; BMI, body mass index.

parameter was associated with the presence or absence of a ramp lesion.

Of the 155 patients with a ramp lesion, 82 (53%) were classified with an unstable tear, and 73 (47%) were classified with a stable tear. When compared with patients without a ramp lesion, patients with an unstable ramp lesion were more likely to have bone marrow edema of the posteromedial tibia (OR, 2.3; $P < .01$). When compared with patients without a ramp lesion, patients with a stable ramp lesion were more likely to have sustained a contact injury to the knee (OR, 2.0; $P = .03$), have bone marrow edema of the posteromedial tibia (OR, 4.1; $P < .0001$), and have a concurrent lateral meniscal tear (OR, 1.9; $P = .02$). When comparing patients with a stable versus unstable ramp lesion, there was no difference in the proportion with bone marrow edema of the posteromedial tibia (63% vs 49%, respectively; $P = .10$), a lateral meniscal tear (48% vs 41%, respectively;

TABLE 2
Clinical, Imaging, and Surgical Findings^a

	n (%)
Standing alignment	
Neutral	350 (94)
Varus	13 (4)
Valgus	9 (2)
Bone marrow edema on MRI	
Yes	154 (41)
No	218 (59)
ACL tear type on MRI	
Complete	349 (94)
Partial	23 (6)
Modified Noyes score	
Patella ^b	
≤2A	351 (94)
≥2B	20 (6)
Trochlea ^b	
≤2A	358 (96)
≥2B	13 (4)
Medial femoral condyle	
≤2A	359 (96)
≥2B	13 (4)
Medial tibial plateau	
≤2A	358 (96)
≥2B	14 (4)
Lateral femoral condyle	
≤2A	331 (89)
≥2B	41 (11)
Lateral tibial plateau	
≤2A	336 (90)
≥2B	36 (10)
Lateral meniscal tear at arthroscopic surgery	
Yes	140 (38)
No	232 (62)
Ramp lesion	
Yes	155 (42)
No	217 (58)
Ramp lesion type ^c	
Unstable	73 (20)
Stable	82 (22)
No ramp lesion	217 (58)

^aACL, anterior cruciate ligament; MRI, magnetic resonance imaging.

^bImaging for one patient not scored due to MRI artifact obscuring assessment of compartment.

^cUnstable = positive MRI finding, displacement into compartment with probing; stable = positive MRI finding, no displacement with probing; no ramp lesion = negative MRI finding, no displacement with probing.

$P = .51$), or a contact injury mechanism (33% vs 30%, respectively; $P = .73$).

Among patients with prior ipsilateral knee surgery, 19 of 56 (34%) had a ramp lesion, of which 9 (47%) were unstable and 10 (53%) were stable. Among patients with prior ACL reconstruction, 15 of 41 (37%) had a ramp lesion. Six (40%) were unstable, and 9 were stable (60%).

No demographic, clinical, surgical, or radiological parameter was associated with a stable versus unstable ramp lesion. A greater proportion of patients with a stable ramp

lesion had bone marrow edema of the posteromedial tibia compared with patients with an unstable ramp lesion (63% vs 49%, respectively), but this did not reach statistical significance ($P = .10$). The breakdown of variables by ramp lesion classification is summarized in Table 3.

DISCUSSION

In this study, we identified ramp lesions in 42% of patients undergoing ACL reconstruction, of which approximately half (47%) were unstable (displaced into the medial compartment with probing) and the other half (53%) were stable (identified on MRI but did not displace at the time of surgery). A contact injury mechanism, the presence of bone marrow edema of the posteromedial tibia on MRI, or a concurrent lateral meniscal tear were all associated with the presence of a ramp lesion.

Although first described in the 1980s,²² ramp lesions have received renewed interest in the orthopaedic sports medicine literature.^{8,9,11,15} The posterior horn of the medial meniscus is recognized as an important secondary stabilizer against anterior tibial translation, and recent biomechanical work has identified significantly increased stress on the reconstructed ACL in the setting of a ramp lesion.^{18,21} These data, coupled with multiple studies that suggest difficulty in diagnosing and treating ramp lesions using standard anterolateral and anteromedial arthroscopic portals, have led to a flurry of epidemiological and clinical studies related to ramp lesions over the past 5 years.¹¹

There does not appear to be a consensus on the definition of a ramp lesion, beyond a tear of the far periphery of the posterior horn of the medial meniscus. Arner et al² defined a ramp lesion as “findings of posterior medial meniscocapsular separation.” Keyhani et al⁹ defined it as “a longitudinal tear or detachment of the peripheral rim around the [posterior horn of the medial meniscus].” This is similar to the definition of DePhillipo et al.⁶ In contrast, Liu et al¹³ chose to include peripheral intrasubstance tears of the meniscus, but also limited their size, defining a ramp lesion as “a tear of the peripheral attachment of the posterior horn of the medial meniscus (synovial-meniscal junction or red-red zone), a longitudinal tear less than 2.5 cm in length.” This closely mirrors the comprehensive classification system proposed by Thaunat et al,²³ who subdivided ramp lesions of the peripheral meniscocapsular junction and red-red zone based on tear pattern and location. We elected to employ the definition of Thaunat et al²³ because of our belief that a far peripheral tear of the substance of the meniscus will have the same biomechanical consequences as meniscocapsular separation.

Prior epidemiological studies have found a ramp lesion prevalence of 9.3% to 40%^{3,6,13,20} among patients undergoing primary ACL reconstruction, and this seems to vary depending on the definition of a ramp lesion employed and the method of diagnosis. Bollen³ found a 9.3% prevalence of

¹¹References 2, 6, 9, 11, 12, 14, 19, 20, 23–25.

TABLE 3
Demographic, Radiographic, and Surgical Variables by Ramp Lesion Classification^a

	Unstable Ramp Lesion	Stable Ramp Lesion	No Ramp Lesion
Age, mean (range), y	31 (14-55)	29 (13-57)	29 (13-57)
BMI (n = 343), mean (range), kg/m ²	24.2 (15.8-39.5)	24.8 (17.6-37.4)	24.1 (18.1-34.3)
<25	37 (58)	50 (66)	129 (64)
≥25	27 (42)	26 (34)	74 (36)
Sex			
Male	46 (63)	47 (57)	123 (57)
Female	27 (37)	35 (43)	94 (43)
Race (n = 344)			
White	45 (71)	62 (82)	168 (82)
Nonwhite	18 (29)	14 (18)	37 (18)
Smoking status (n = 345)			
Smoker	3 (5)	4 (5)	12 (6)
Nonsmoker	61 (95)	73 (95)	192 (94)
Mechanism of injury			
Contact	22 (30)	27 (33)	44 (20)
Noncontact	51 (70)	55 (67)	173 (80)
Prior ipsilateral ACL reconstruction			
Yes	6 (8)	9 (11)	26 (12)
No	67 (92)	73 (89)	191 (88)
Prior meniscal surgery			
Yes	3 (4)	6 (7)	16 (7)
No	70 (96)	76 (93)	201 (93)
Bone marrow edema on MRI			
Yes	36 (49)	52 (63)	66 (30)
No	37 (51)	30 (37)	151 (70)
Modified Noyes score			
Patella ^b			
≤2A	70 (97)	76 (93)	205 (95)
≥2B	2 (3)	6 (7)	12 (5)
Trochlea ^b			
≤2A	70 (97)	78 (95)	210 (97)
≥2B	2 (3)	4 (5)	7 (3)
Medial femoral condyle			
≤2A	72 (99)	82 (100)	205 (95)
≥2B	1 (1)	0 (0)	12 (5)
Medial tibial plateau			
≤2A	71 (97)	81 (99)	206 (95)
≥2B	2 (3)	1 (1)	11 (5)
Lateral femoral condyle			
≤2A	63 (86)	72 (88)	196 (90)
≥2B	10 (14)	10 (12)	21 (10)
Lateral tibial plateau			
≤2A	64 (88)	75 (92)	197 (91)
≥2B	9 (12)	7 (8)	20 (9)
Standing alignment			
Varus	2 (3)	1 (1)	10 (5)
Neutral	68 (93)	80 (98)	202 (93)
Valgus	3 (4)	1 (1)	5 (2)
ACL tear type on MRI			
Partial	3 (4)	2 (2)	18 (8)
Complete	70 (96)	80 (98)	199 (92)
Concurrent lateral meniscal tear			
Yes	30 (41)	39 (48)	71 (33)
No	43 (59)	43 (52)	146 (67)

^aData are reported as n (%) unless otherwise indicated. ACL, anterior cruciate ligament; BMI, body mass index; MRI, magnetic resonance imaging.

^bImaging for one patient not scored due to MRI artifact obscuring assessment of compartment.

meniscocapsular separation by externally rotating the tibia and viewing the posterior meniscocapsular junction. This author did not include intrasubstance injuries of the red-red zone. DePhillipo et al⁶ and Liu et al¹³ both found that 16.6% of their patients had ramp lesions. While they did include patients with intrasubstance tears in the red-red zone, their diagnostic strategy involved only probing and manipulation, but not dissection, of the posteromedial meniscocapsular junction. Kim et al¹¹ found a 26.6% prevalence in adults, and Malatray et al¹⁵ found a 23.2% prevalence in adolescents, using a similar definition and technique. The highest reported prevalence in the literature is by Sonnery-Cottet et al.²⁰ As part of their diagnostic technique, the superficial layer of tissue over the meniscocapsular junction is gently debrided using an arthroscopic shaver to facilitate visualization. These authors have previously argued that an assessment of the deeper layers near the junction is necessary because of the existence of type 3 “hidden” lesions, which may not be readily visible through a superior view even with probing. We would argue that this region is easily seen on preoperative MRI performed with appropriate spatial resolution.

Despite using a different diagnostic method, the prevalence in our series is very close to that of Sonnery-Cottet et al²⁰ (42% vs 40%, respectively). We did not employ additional measures to directly view and probe/dissect the posteromedial meniscocapsular junction because we believe that stable ramp lesions will heal without treatment in the inflammatory milieu of the knee after ACL reconstruction. We do not feel that it is necessary to routinely visualize through the notch or create accessory posteromedial portals to assess the medial meniscus.

In this series, we utilized MRI to determine whether a ramp lesion was present. MRI has been shown to have >92% specificity for the detection of these lesions when compared with arthroscopic surgery with posteromedial probing.² Thus, while our methodology differs somewhat from other studies in this area, we believe that the existing literature supports our approach. Sonnery-Cottet et al²⁰ argued that, in the absence of superficial dissection of soft tissues in the posteromedial knee, other authors may be missing ramp lesions that they identify arthroscopically and we identify through MRI.²⁴ We feel that the use of MRI obviates the need to dissect the synovial tissue over the meniscocapsular junction to identify “hidden lesions” because MRI allows visualization through the entire thickness of the meniscus and capsule. In cases where MRI does identify a ramp tear, if the meniscal lesion is stable to probing, we feel that repair is not necessary.

We identified a contact injury mechanism, the presence of bone marrow edema of the posteromedial tibia, and a concurrent lateral meniscal tear as associated with the presence of a ramp lesion. It may be that ramp lesions occur in the setting of higher energy injuries. This would be consistent with the observation of Bollen³ that ramp lesions are associated with mild anteromedial rotatory subluxation. Liu et al¹³ also found a higher prevalence of ramp lesions in male

patients and patients younger than 30 years, who are more likely to sustain high-energy trauma. We did not find sex or age to be risk factors for ramp lesions.

Liu et al¹³ also found an association between the presence of a ramp lesion and delay to surgery. This is presumably because of attritional ruptures of the meniscocapsular junction with the loss of ACL restraint limiting anterior tibial translation and is consistent with prior works showing increased rates of meniscal injuries with delayed ACL reconstruction. In the present series, we were unable to examine the relationship between time to surgery and ramp lesion prevalence because the date of injury was not included in our registry.

There are several limitations to this study. The most important limitation is the lack of standardization of the intraoperative assessment of stability of a ramp lesion. This determination was ultimately made by the treating surgeon based on the length of the tear and the magnitude of displacement. However, this limitation is present in all studies that based decision making on a direct surgical assessment.

Second, this was a retrospective review of prospectively collected data that were supplemented by an examination of existing medical and imaging records. As with all retrospective studies, we have risks of error and bias that are inherent to our methodology. We attempted to mitigate the problem of missing or inaccurate information in our registry by correlating the data with operative reports. Nonetheless, the review of these patients from the registry did provide a control group with which both the stable and unstable ramp lesion groups could be compared.

Third, our results represent our experience as a tertiary referral center in a specific geographic region. Our study population was 80% white, the majority participated in at least recreational athletics, and 63% had a body mass index that was considered normal. Other studies of ramp lesions have examined populations from France,²⁰ South Korea,¹¹ and China,¹³ which have even more divergent demographic profiles. Our findings may not be generalizable to other patient populations.

Fourth, we are unable to say with certainty whether the ramp lesions seen in patients with prior ipsilateral knee surgery were the result of the most recent injury or were residual from the prior injury/injuries. We suspect that they were not residual, as the prevalence of ramp lesions in this subpopulation was very close to that of the entire cohort. However, because of a lack of preinjury imaging, we cannot say this with certainty.

Finally, by relying on MRI to diagnose stable ramp lesions, we potentially underestimated their prevalence. While the specificity of MRI for these injuries is extremely high, the reported sensitivity ranges from 0% to 77%.⁴ Thus, despite our relatively high prevalence of identified ramp lesions, the actual prevalence may potentially be even higher. Our MRI protocol, however, provides higher in-plane and through-plane resolution compared with many standard protocols used for the knee, and this protocol was standardized throughout this cohort. Furthermore, because

our experience demonstrates that stable intrasubstance tears in this area can often be left alone, it is likely that further detection of occult lesions would not change management in any way. It is worth noting that we utilized a 3.0-T MRI scanner, and thus, our results may not be generalizable to surgeons employing the more common 1.5-T magnets.

CONCLUSION

In our cohort of 372 patients with ACL injuries treated operatively, we identified a 42% prevalence of meniscal ramp lesions. Approximately half of these lesions were unstable, and half were stable. Subsequent work will examine differences in the treatment and clinical outcomes of these lesions.

REFERENCES

- Ahn JH, Kim SH, Yoo JC, Wang JH. All-inside suture technique using two posteromedial portals in a medial meniscus posterior horn tear. *Arthroscopy*. 2004;20(1):101-108.
- Arner JW, Herbst E, Burnham JM, et al. MRI can accurately detect meniscal ramp lesions of the knee. *Knee Surg Sports Traumatol Arthrosc*. 2017;25(12):3955-3960.
- Bollen SR. Posteromedial meniscocapsular injury associated with rupture of the anterior cruciate ligament: a previously unrecognized association. *J Bone Joint Surg Br*. 2010;92(2):222-223.
- Chahla J, Dean CS, Moatshe G, et al. Meniscal ramp lesions: anatomy, incidence, diagnosis, and treatment. *Orthop J Sports Med*. 2016;4(7):2325967116657815.
- Cooper DE, Arnoczky SP, Warren RF. Arthroscopic meniscal repair. *Clin Sports Med*. 1990;9(3):589-607.
- DePhillipo NN, Cinque ME, Chahla J, Geeslin AG, Engebretsen L, LaPrade RF. Incidence and detection of meniscal ramp lesions on magnetic resonance imaging in patients with anterior cruciate ligament reconstruction. *Am J Sports Med*. 2017;45(10):2233-2237.
- Hagino T, Ochiai S, Senga S, et al. Meniscal tears associated with anterior cruciate ligament injury. *Arch Orthop Trauma Surg*. 2015;135(12):1701-1706.
- Hetsroni I, Lillemoë K, Marx RG. Small medial meniscocapsular separations: a potential cause of chronic medial-side knee pain. *Arthroscopy*. 2011;27(11):1536-1542.
- Keyhani S, Ahn JH, Verdonk R, Soleymanha M, Abbasian M. Arthroscopic all-inside ramp lesion repair using the posterolateral transseptal portal view. *Knee Surg Sports Traumatol Arthrosc*. 2017;25(2):454-458.
- Kijowski R, Blankenbaker DG, Davis KW, Shinki K, Kaplan LD, De Smet AA. Comparison of 1.5- and 3.0-T MR imaging for evaluating the articular cartilage of the knee joint. *Radiology*. 2009;250(3):839-848.
- Kim SH, Lee SH, Kim KI, Yang JW. Diagnostic accuracy of sequential arthroscopic approach for ramp lesions of the posterior horn of the medial meniscus in anterior cruciate ligament-deficient knee. *Arthroscopy*. 2018;34(5):1582-1589.
- Li WP, Chen Z, Song B, Yang R, Tan W. The Fast-Fix repair technique for ramp lesion of the medial meniscus. *Knee Surg Relat Res*. 2015;27(1):56-60.
- Liu X, Feng H, Zhang H, Hong L, Wang XS, Zhang J. Arthroscopic prevalence of ramp lesion in 868 patients with anterior cruciate ligament injury. *Am J Sports Med*. 2011;39(4):832-837.
- Liu X, Zhang H, Feng H, Hong L, Wang XS, Song GY. Is it necessary to repair stable ramp lesions of the medial meniscus during anterior cruciate ligament reconstruction? A prospective randomized controlled trial. *Am J Sports Med*. 2017;45(5):1004-1011.
- Malatray M, Raux S, Peltier A, Pfirmann C, Seil R, Chotel F. Ramp lesions in ACL deficient knees in children and adolescent population: a high prevalence confirmed in intercondylar and posteromedial exploration. *Knee Surg Sports Traumatol Arthrosc*. 2018;26(4):1074-1079.
- McCarthy M, Mallett K, Abola M, Vassallo S, Nguyen J. Hospital for Special Surgery ACL Registry: 2-year outcomes suggest low revision and return to OR rates. *HSS J*. 2017;13(2):119-127.
- Papageorgiou CD, Gil JE, Kanamori A, Fenwick JA, Woo SL, Fu FH. The biomechanical interdependence between the anterior cruciate ligament replacement graft and the medial meniscus. *Am J Sports Med*. 2001;29(2):226-231.
- Peltier A, Lording T, Maubisson L, Ballis R, Neyret P, Lustig S. The role of the meniscotibial ligament in posteromedial rotational knee stability. *Knee Surg Sports Traumatol Arthrosc*. 2015;23(10):2967-2973.
- Song GY, Liu X, Zhang H, et al. Increased medial meniscal slope is associated with greater risk of ramp lesion in noncontact anterior cruciate ligament injury. *Am J Sports Med*. 2016;44(8):2039-2046.
- Sonnery-Cottet B, Conteduca J, Thauinat M, Gunepin FX, Seil R. Hidden lesions of the posterior horn of the medial meniscus: a systematic arthroscopic exploration of the concealed portion of the knee. *Am J Sports Med*. 2014;42(4):921-926.
- Stephen JM, Halewood C, Kittl C, Bollen SR, Williams A, Amis AA. Posteromedial meniscocapsular lesions increase tibiofemoral joint laxity with anterior cruciate ligament deficiency, and their repair reduces laxity. *Am J Sports Med*. 2016;44(2):400-408.
- Strobel M. *Manual of Arthroscopic Surgery*. New York: Springer; 2002.
- Thauinat M, Fayard JM, Guimaraes TM, Jan N, Murphy CG, Sonnery-Cottet B. Classification and surgical repair of ramp lesions of the medial meniscus. *Arthrosc Tech*. 2016;5(4):e871-e875.
- Thauinat M, Jan N, Fayard JM, et al. Repair of meniscal ramp lesions through a posteromedial portal during anterior cruciate ligament reconstruction: outcome study with a minimum 2-year follow-up. *Arthroscopy*. 2016;32(11):2269-2277.
- Yang J, Guan K, Wang JZ. Clinical study on the arthroscopic refreshing treatment of anterior cruciate ligament injury combined with stable medial meniscus ramp injury. *J Musculoskelet Neuronal Interact*. 2017;17(2):108-113.
- Yeo Y, Ahn JM, Kim H, et al. MR evaluation of the meniscal ramp lesion in patients with anterior cruciate ligament tear. *Skeletal Radiol*. 2018;47(12):1683-1689.