

# A novel classification for atypical Hangman fractures and its application

## A retrospective observational study

Guangzhou Li, MD, Dejun Zhong, MD, Qing Wang, MD\*

### Abstract

Atypical Hangman fractures (AHF) were first formally reported and considered to be more often associated with neurologic deficit in 1993. However, there is a paucity of literature focusing on these fractures. The purpose of the retrospective study was to introduce a new classification scheme for AHF and its application.

Sixty-two patients with Hangman fractures were identified. There were 46 (74.2%, 46/62) AHF patients, including 29 type I, 9 type II, 5 type IIa, and 3 type III fractures (Levine–Edwards classification). Based on fracture patterns, incidence, and their impact on neurologic status, a primary classification for AHF was devised. The clinical features of AHF were observed, and a new classification was introduced. The appropriate treatment strategy of AHF was discussed.

Of 46 AHF patients, 27 underwent surgical treatment (24 with posterior approach with screw-rod fixation and fusion, 1 with anterior approach by C2/3 discectomy and fusion, and 2 with anterior and posterior approach), and the remaining 19 patients underwent nonoperative treatment. No patient complained severe neck pain at final follow-up. Neurologic status improved 1 to 2 grade in 12 cases with neurologic deficit. All patients achieved bony fusion within the follow-up period.

AHF should be recognized as a distinct fracture subtype. The new classification for AHF is based on the feature of fracture patterns, injury mechanism, incidence, and their impact on neurologic deficit. And the new classification is complementary to Levine–Edwards.

**Abbreviations:** AHF = atypical Hangman fractures, ASIA = American Spinal Injury Association scale, CT = computed tomography, LSR = Lag screw-rod.

**Keywords:** atypical, classification, Hangman fractures, surgical strategy, technique

## 1. Introduction

Starr and Eismont reported that 6 cases were atypical Hangman fractures (AHF) in their series of 19 Hangman fractures, and AHF was more often accompanied by paralysis (33%) in 1993.<sup>[1]</sup> There is a paucity of literature directly focusing on these fractures. The true incidence, neurologic status, and proper treatment strategy of AHF have not been addressed until now.

The Levine and Edwards classification is most widely accepted categorization for Hangman fractures.<sup>[1,2]</sup> However, it usually aims at bilateral pars fractures of C2 (typical Hangman fractures), and for AHF with fractures involving the posterior

cortex of C2 on one or both sides, the treatment strategy remains controversial.<sup>[1–5]</sup> We conducted the retrospective study to introduce a new classification scheme for AHF and its application.

## 2. Materials and methods

The study enrolled patients with Hangman fractures between May 2005 and March 2015. We reviewed all the medical records in our prospectively maintained database. Inclusion criteria were all patients with Hangman fractures, and there were no exclusion. This study was undertaken in the Affiliated Hospital of Southwest Medical University, and it was approved by the local institutional review board at the authors' affiliated institution.

The diagnosis was confirmed with the combination of X-rays and 3-dimensional computed tomography (CT) scans of bony structures, and MRI images of the cervical spine. AHF was defined as traumatic spondylolisthesis of the axis with fractures occurring through the posterior cortex of C2 on one or both sides.<sup>[1]</sup> Hangman fractures with a bilateral pars interarticularis fractures were defined as typical. Hangman fractures were divided into 4 types by Levine–Edwards classification.<sup>[2]</sup> Then, the incidence rate and distribution of AHF in Levine–Edwards 4 types were observed. The surgical strategy of AHF was also analyzed.

### 2.1. Patient population

Clinical data were collected on 62 consecutive patients with Hangman fractures. There were 46 (74.2%, 46/62) patients with

Editor: Bernhard Schaller.

GL and DZ contributed equally to this work.

The authors have no conflicts of interest to disclose.

Department of Spine Surgery, the Affiliated Hospital of Southwest Medical University, Luzhou Sichuan, China.

\* Correspondence: Qing Wang, Department of Spine Surgery, the Affiliated Hospital of Southwest Medical University, No. 25 Taiping St., Luzhou, Sichuan 646000, China (e-mail: jzkw2010@163.com).

Copyright © 2017 the Author(s). Published by Wolters Kluwer Health, Inc. This is an open access article distributed under the terms of the Creative Commons Attribution-Non Commercial-No Derivatives License 4.0 (CCBY-NC-ND), where it is permissible to download and share the work provided it is properly cited. The work cannot be changed in any way or used commercially without permission from the journal.

Medicine (2017) 96:28(e7492)

Received: 24 April 2017 / Received in final form: 19 June 2017 / Accepted: 20 June 2017

<http://dx.doi.org/10.1097/MD.0000000000007492>

**Table 1****Demographic and baseline characteristics of patients with AHF.**

No	Age, y/sex	Cause of injury	Fracture type according to two classification system		ASIA	Treatment options	Complications
			Levine–Edward	Li–Wang			
1	47/M	Fall	II	A2	C	P2–3	None
2	26/F	MVA	I	B1	E	P2–3	None
3	43/M	Fall	I	A1	E	Non	None
4	55/M	Fall	I	A1	E	Non	None
5	52/M	Fall	II	A1	E	P2–3	None
6	29/M	Fall	I	A1	E	Non	None
7	28/M	Fall	I	A2	D	P2–3	None
8	57/M	Fall	II	A1	E	P1,3	None
9	70/F	Fall	I	B1	E	Non	None
10	48/M	Fall	I	A2	E	P2–3	None
11	36/M	Other	Ila	A1	D	P1,3	None
12	66/M	MVA	I	A2	E	Non	None
13	40/M	Fall	I	A2	D	P2–3	None
14	40/F	Fall	I	A1	D	P2–3	None
15	38/M	Fall	I	A1	E	Non	None
16	72/M	Fall	II	A1	E	P2–3	lung infection
17	29/F	Other	II	A1	D	P2–3	None
18	58/M	MVA	II	B2	E	P2–3	None
19	50/M	Other	I	A2	D	P2–3	None
20	70/M	Fall	I	A1	E	Non	None
21	56/M	Other	I	A1	E	Non	None
22	46/F	MVA	I	A1	E	Non	None
23	75/M	Other	I	B1	E	Non	None
24	56/F	Fall	Ila	A1	D	P1,3	urinary infection
25	55/M	Other	II	A2	D	P2–3	None
26	34/M	Fall	III	A2	C	A2–3+P2	esophageal perforation
27	57/M	MVA	I	B1	B	Non	None
28	60/F	MVA	I	A1	E	Non	None
29	43/M	Fall	III	B1	D	P1,3	None
30	42/M	Fall	I	A1	E	P2–3	TCA
31	74/M	Fall	III	A1	E	P2–3	None
32	38/F	Fall	I	A1	A*	P2–3	None
33	54/M	Fall	I	A2	E	Non	None
34	54/M	Fall	Ila	A2	E	P2–3	None
35	30/M	Fall	Ila	A1	C†	P2–3	None
36	40/M	Fall	I	A2	E	Non	None
37	48/M	Fall	I	A2	E	Non	None
38	34/M	Other	Ila	A1	E	P2–3	None
39	23/M	MVA	I	A1	E	Non	None
40	42/M	Fall	II	B2	E	A2–3+ P2–3	None
41	25/M	MVA	I	A1	E	Non	None
42	15/F	Other	II	A1	E	P2–3	None
43	39/M	MVA	I	A1	E	P2–3	None
44	42/M	Fall	I	A1	E	A2–3	None
45	56/M	Other	I	A1	E	Non	None
46	48/F	MVA	I	A1	E	Non	None

Non, non-operation; A2–3, anterior cervical discectomy and fusion (ACDF) at C2–C3 level; P1,3, posterior C1 and C3 screw fixation; P2,3, posterior C2 and C3 screw fixation. AHF = atypical Hangman fractures, ASIA = American Spinal Injury Association scale, Li–Wang = the new classification devised in the study, MVA = motor vehicle accident, TCA = transient cerebellar ataxia.

\* ASIA A caused by C6/7 injury.

† ASIA C caused by L1 vertebral body fracture.

AHF, including 36 males and 10 females, and the average age was 46.5 years (range, 15–74 years). The causes of injuries were falls (27 cases), motor vehicle accidents (10 cases), and others (9 cases). The patient demographic and baseline characteristics are illustrated in Table 1. Associated injuries were reported in 31 (67.4%, 31/46) cases. Combined injuries included head injury (10 cases, 8 with minor and 2 with major head injuries), atlas injury (1 case), subaxial cervical spine injuries (6 cases), thoracolumbar spine fractures (5 cases), multiple rib fractures

(3 cases), pelvic fractures (2 cases), clavicle fracture (1 case), scapular fractures (2 cases), manubrium fracture (1 case), and fractures of the extremities (3 cases). Specifically, of the 8 cases with minor head injuries, 3 cases had scalp lacerations or contusions on the right side, 2 cases on the left side, and 2 cases in the parietal region.

According to Levine–Edwards classification scheme, 29 patients were types I, 9 patients types II, 5 type Ila, and 3 type III. Neurological deficit directly associated with C2 injury were

**Table 2****New classification of AHF.**

Type	Fracture feature	Description
Type A1	Fracture line through the posterior aspect of the C2 body with contralateral pars fracture	The most common type (27 cases), and 5 of 27 cases with neurologic deficit
Type A2	Fracture line through the posterior aspect of the C2 body with contralateral lamina fracture	Common type (12 cases) with the highest incidence of neurologic deficit (5/12)
Type B1	Bilateral oblique fracture lines through the posterior aspect of the C2 body	Less common type (5 cases), and 1 case with neurologic compromise
Type B2	Bilateral fracture lines through the posterior aspect of the C2 body, one is oblique and another is vertical	The least common of the four types (2 cases)

AHF = atypical Hangman fractures.

found in 12 of 46 patients (26.1%), and the incidence rates were 17.2% (5/29) in type I, 33.3% (3/9) in type II, 40% (2/5) in type IIa, and 66.7% (2/3) type III fractures. According to American Spinal Injury Association scale (ASIA), 1 patient was with ASIA B, 2 with C, and 9 with D.<sup>[6]</sup> Besides, 2 patients with neurologic impairment not associated with C2 were found, including 1 patient with ASIA A caused by Lumbar 1st burst fracture and another with C caused by C6/7 traumatic fracture-dislocation.

## 2.2. New classification

We made a primary AHF classification based on the feature of fracture patterns, incidence, and their impact on neurologic status (Table 2). Type A1 means that the fracture pattern is 1 fracture involving of posterior cortex of C2 on 1 side obliquely and another through the pars interarticularis (n=27 cases) on the other side, which accounted for 59% of all AHF (Fig. 1A, B). Type A2 means that the fracture pattern is 1 fracture through 1 side of C2 body obliquely and another through the contralateral lamina (n=12 cases), which may demonstrate a more rotational injury force compared with type A1 fracture, with 6 cases (50%, 6/12) with neurologic deficit directly associated with C2 injury (Fig. 2A, B). Three of 5 cases with scalp lacerations or contusions on the right or left side were found in type A2 group, and only 1 in type A1 group. Type B1 means bilateral oblique fracture lines through the posterior cortex of C2 on different sides (n=5 cases, Fig. 3A, B).

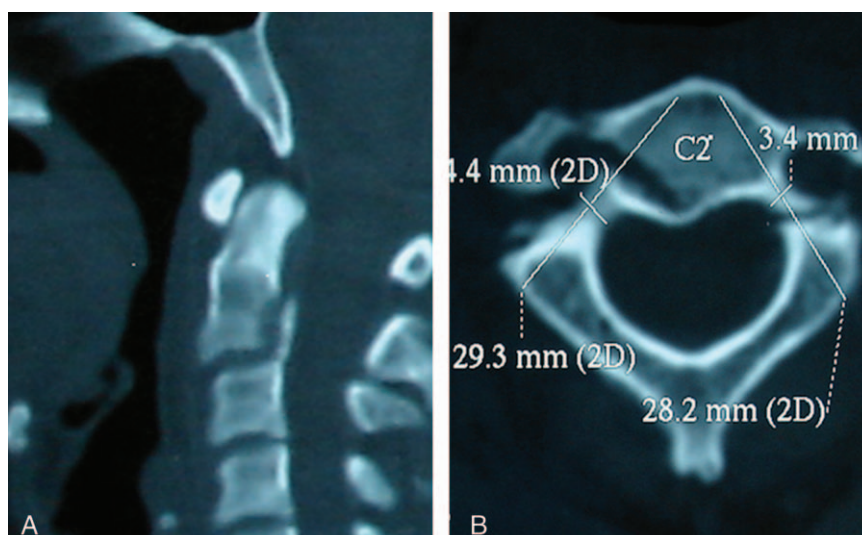
Type B2 means bilateral fracture lines with oblique 1 on 1 side and another vertical 1 on the other side (n=2 cases, Fig. 4A, B). One case with scalp contusion on the right side was found in type B2 group, and 1 case with scalp laceration or contusion in the parietal region was included in type B1 and type B2 group, respectively.

## 2.3. Treatment strategy

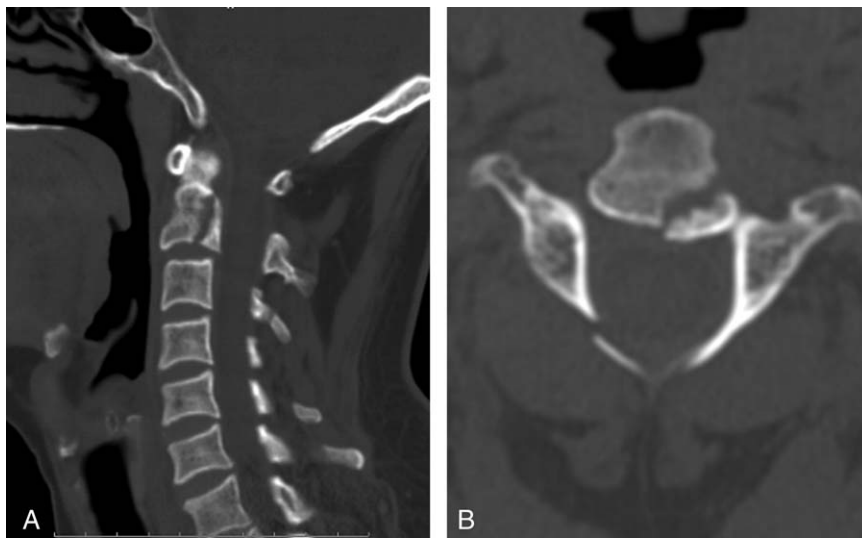
First, Levine-Edwards classification was applicable to AHF: unstable lesions (type II, IIa, and III) were treated surgically, and patients with type I fractures without C2-3 level instability were managed with collars. AHF of type I with neurologic deficit was considered as neurologic instability, and AHF of type I without neurologic compromise was evaluated using MRI, and if both the anterior longitudinal ligament and the disc at the C2 to 3 level were ruptured, it was recognized as instability. Second, when patients were treated surgically, we performed 1 of 4 different operation: posterior C2 to C3 Lag Screw-Rod (LSR) fixation and fusion,<sup>[7]</sup> extensive arthrodesis from C1 to C3, anterior approach with C2 to C3 discectomy and fusion, or combined anterior and posterior approach.

## 2.4. Clinical and radiologic assessment

The clinical outcomes included management complications, neck pain, and neurological improvement. The radiologic outcomes were assessed on follow-up CT or plain radiographs. Bony fusion



**Figure 1.** (A, B) The sagittal (left) and axial (right) computed tomography (CT) scans of type A1 fracture in our new classification.



**Figure 2.** (A, B) The sagittal (left) and axial (right) computed tomography (CT) scans of type A2 fracture in our new classification.

was assessed according to Bridwell standard.<sup>[8]</sup> Two authors (QW and LG) evaluated each image independently and reached a consensus on interpretation, and 1 month after the 1st evaluation, this procedure was repeated again.

### 3. Results

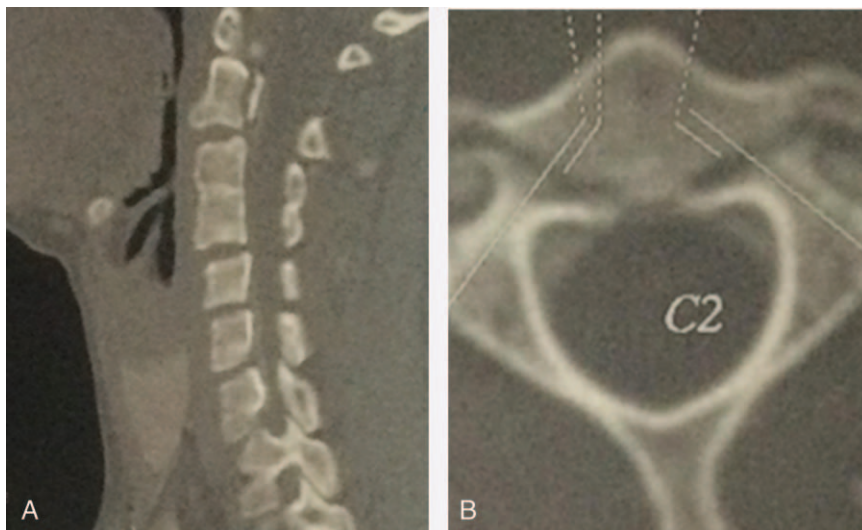
#### 3.1. Treatment choice

Of 46 AHF patients, 19 with Levine–Edwards I type without instability underwent nonoperative treatment using rigid collar for 2 to 3 months, and 27 patients underwent surgical treatment. Twenty-four patients underwent posterior approach, including 20 patients (11 cases type A1, 7 cases A2, 1 case B1, and 1 case B2 of our classification) with a normal course of vertebral artery and proper size of pedicle of C2 performed by posterior C2 to C3 LSR fixation and fusion, and 4 cases (3 cases A1 and 1 case B1) with extensive arthrodesis from C1 to C3 because of high riding of vertebral artery and tiny size of pedicle of C2. One patient with

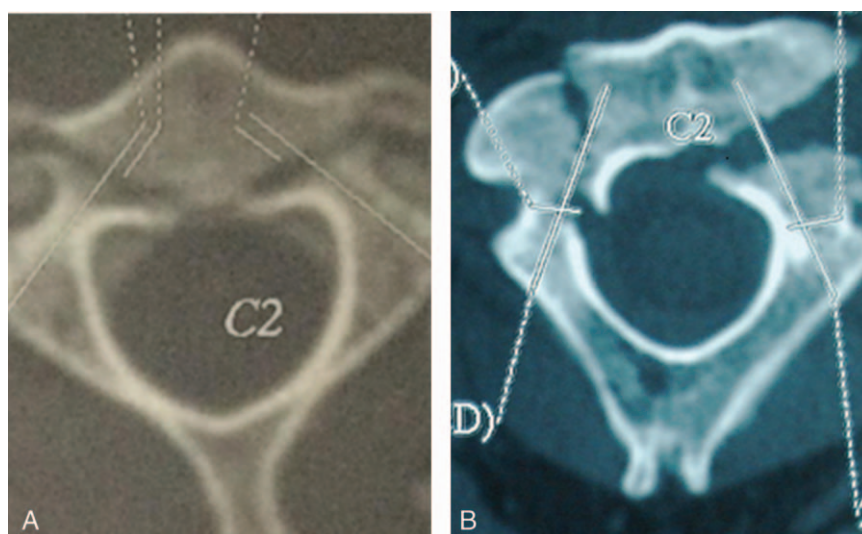
C2/3 disc herniation underwent anterior approach by C2/3 discectomy and fusion. Two cases underwent combined anterior and posterior approach (Table 1).

#### 3.2. Complications

For 1 patient (case no 26) with combined approach, esophageal perforation occurred during the exposure of the C2 to 3 vertebral bodies. With the help of thoracic surgeon repairing the lesion and tube-feeding for 10 days, the patient recovered and were discharged without sequelae. Two cases with posterior approach experienced severe bleeding in 1 side screw insertion trajectory due to the vessel damage when the C2 screw placement prepared, and the screws were placed to tamponade bleeding. After operation, 1 patient experienced transient cerebellar ataxia on postoperative 5 days which disappeared with the help of medicine. Both of them remained neurologically intact. One patient with lung infection and 1 patient with urinary infection were recovered by antibiotics treatment.



**Figure 3.** (A, B) The sagittal (left) and axial (right) computed tomography (CT) scans of type B1 fracture in our new classification.



**Figure 4.** (A, B) The sagittal (left) and axial (right) computed tomography (CT) scans of type B2 fracture in our new classification.

### 3.3. Clinical and radiologic outcomes

The mean follow-up time was 3.1 years (range, 6 months to 10 years). No patient complained severe neck pain at final follow-up. All patients revealed no evidence of neurological deterioration. Neurological evaluation showed there was 1 to 2 grade improvement in the 12 patients with neurologic deficit associated with C2 injuries. No incision infection or internal fixation failure was observed. All the patients achieved solid bony fusion. Twenty-six grade I fusions and 20 grade II fusions were observed within the follow-up period. One patient managed nonoperatively showed angulated healing of C2 fractures lines and local C2 to 3 kyphosis.

## 4. Discussion

### 4.1. AHF as a distinct fracture subtype

In 1985, Levine and Edwards modified the Effendi system and published the most widely accepted categorization for Hangman fractures, which not only affords a clear picture of the mechanism of injury, but also guides the proper treatment for each type lesion.<sup>[1,2,5]</sup> However, it usually aims at bilateral pars fractures of C2 and does not focus on whether fractures involving the posterior cortex of C2 on 1 or both sides. AHF was first formally reported in 1993, and the incidence was (32%, 6/19) and AHF with significant neurologic dysfunction were found in 33% of patients.<sup>[1]</sup> Burke and Harris<sup>[3]</sup> reported 11 (18%, 11/62) and Samaha et al<sup>[4]</sup> reported 13 (60%, 13/24) AHF in their series, respectively. However, both of them did not record the incidence of neurologic deficit in this kind of lesion. In AL-Mahfoudh et al<sup>[5]</sup> study, 68% (28/41) fractures were AHF and 18% (5/28) with neurologic deficit. In the current study, 74.2% (46/62) fractures were AHF, and 26% of 46 patients were accompanied with neurologic deficit. Meanwhile, some other authors acknowledge these fractures, but they classify these lesions within a broader context of miscellaneous axis fractures or axis body fractures.<sup>[9,10]</sup> In Effendi et al<sup>[9]</sup> series, even though the authors were aware that one of their cases was permanently quadriplegic, they still considered that Hangman fractures were usually benign, resulting in canal expansion, and were rarely

associated with severe neurologic deficit. Benzel<sup>[10]</sup> classified some AHF (part of his coronally oriented vertical fractures of C2 vertebral body) as axis body fractures.

We suggest that atypical fracture should be recognized as a distinct fracture subtype: first, AHF presents with a higher frequency and a higher incidence of neurologic compromise.<sup>[1,4,5]</sup> Second, the fracture patterns of AHF are diverse, and the details of dealing with them may be different. Third, the characteristic of AHF is that the intact ring of C2 vertebrae protecting spinal cord is destroyed.

### 4.2. New classification for AHF and its feature

In our study, all the 4 types of Levine–Edward were identified, and even more important, we found not just 4 different fracture patterns of AHF but also features of each type: pattern of type A fracture was featured with 1 fracture involving of posterior cortex of C2 on 1 side and another through either the pars (A1) or lamina (A2) on the other side, and the 1st fracture pattern (type A1) was associated with the highest incidence (59%, 27/46); the 2nd fracture pattern (type A2), which might demonstrate a more rotational injury force compared with type A1 fracture, was accompanied by a higher incidence of neurologic deficit. We assume that type A fractures are produced with the combined forces of traditional components that cause typical Hangman fractures and a rotational component, and the rotational injury force in type A2 fracture might be stronger compared with that in type A1.

The last 2 fracture patterns (type B1 and B2) involved with bilateral fracture lines through the posterior cortex of C2; although the location and extent of fracture lines were different, they usually caused damage to the integrity of spinal canal in the C2 level, which might produce canal compromise, resulting in neurologic deficit. We hypothesize that type B fractures are produced with the combined forces of components that cause typical Hangman fractures, a rotational component, and a vertical compression that impact the parietal region of the head, and with the vertical compression force blocked by C2/3 facet joints, the complex of forces cause fractures in front of neural arch of axis. Besides, and the rotational injury force in type B2

fracture should also be stronger compared with that in type B1. Therefore, our classification is based on the feature of fracture patterns, injury mechanism, incidence, and their impact on neurologic deficit to help to further the understanding of these fractures, and it may be used to establish guidelines for appropriate surgical treatment as we described our experience as above. We acknowledge the fact that the Levine–Edwards classification scheme for Hangman fractures is the most widely accepted, comprehensive, and consummate until now, and it is also applicable to AHF. Therefore, our AHF classification should be considered to be complementary one. We carefully suggest that patients with Hangman fractures should be classified as Levine–Edward different types (I, II, IIa, and III) basically; second, CT scans of the cervical spine should be used to determine whether the lesions are typical or atypical (AHF); finally, if the injury was AHF, it should also be divided into 1 of 4 types (type A1, A2, B1, and B2) devised by us to clarify this lesion further.

AL-Mahfoudh et al<sup>[5]</sup> conducted a similar study, but there were no Levine–Edward type III fractures. In their study, 68% (28/41) fractures were AHF, with 12 fractures (43% of 28 cases) involved the C2 body on 1 side and a fracture of the contralateral posterior element (pars or lamina) and 16 fractures showed a coronally orientated fracture through the body of C2 anterior to the pars interarticularis. Based on these fracture patterns, the authors also made a classification for AHF, which had some obvious drawbacks: it was just based on different fracture patterns, without all the 4 types of Levine–Edward; some of coronally orientated fractures should be recognized as axis body fractures not as Hangman fractures, because these fractures just caused spinal canal intact in the C2 level.

#### 4.3. Treatment strategy for AHF

Just like management of Hangman fractures, the ideal strategy for AHF remains controversial.<sup>[1–5,11–14]</sup> Some literatures reported that these fractures treated with collar or halo instead of surgery demonstrated good outcome/high healing rate, but many of them neglected the drawbacks with conservative treatment, including residual pain, residual deformities (kyphosis or anterior translation of C2–C3), and long time of immobilization in a halo orthosis or traction devices, especially for unstable fractures.<sup>[11,13]</sup> To resolve the problem of conservative treatment for these unstable injuries, early surgical treatment for unstable fractures has been increasingly used and reported in many countries.<sup>[7,14–18]</sup>

Our experience are listed as follows: first, Levine–Edwards classification is also applicable to AHF, and type II, IIa, and III lesions usually are unstable, and these injuries are better to be treated with surgical fixation; second, AHF of type I with neurologic deficit should be considered as neurologic instability and should be treated with surgical fixation; third, AHF of type I without neurologic compromise should be evaluated using MRI whether these lesions are stability or not, and if both the anterior longitudinal ligament and the disc at the C2 to 3 level ruptured, it is recognized as C2 to 3 level instability. Finally, for our patients who need rigid immobilization, we prefer surgical fixation because it can provide a short treatment duration.

Various operations for unstable Hangman fractures are available, including anterior, posterior, and both anterior and posterior approach.<sup>[7,13–18]</sup> We carefully suggest that posterior C2 to C3 LSR technique may be an effective and reliable option for these unique injuries, because C2 lag screws with different length of partial thread (C2 lag screws is partial thread screw in the anterior

part, and the length of partial thread is different adapting to variable conditions) can do the best to deal with these asymmetric injuries.<sup>[7]</sup> Although, theoretically, posterior C2 to C3 LSR is an ideal choice, if the attempt failed, we recommend individual strategy, such as extensive arthrodesis from C1 to C3, or anterior surgery to avoid and decrease the operation risks.<sup>[13–15,19]</sup>

#### 4.4. Limitations

Some limitations of our study should be mentioned. First, although it includes a prospectively maintained database of 10 years and the largest sample focusing on AHF until now, the present study is still a retrospective, small sample size, and nonmulticenter study. Another limitation of the current study is that we did not find AHF with odontoid fracture or with severe comminuted fractures of C2 body or some more complex injuries.<sup>[20]</sup> Finally, we believe that the injury mechanism of AHF is more complex than we discussed and we previous thought; however, the complex thing itself makes it is necessary to further explore the issue. This is a preliminary study, and we look forward to more studies focusing on this issue by other authors. Meanwhile, we expect that prospective, large sample size, and multicenter studies are conducted to confirm and modify our finding.

#### 5. Conclusion

AHF should be recognized as a distinct fracture subtype. The new classification for AHF is based on the feature of fracture patterns, injury mechanism, incidence, and their impact on neurologic deficit. And the new classification is complementary to Levine–Edwards.

#### References

- [1] Starr JK, Eismont FJ. Atypical Hangman's fracture. *Spine* 1993;18:1954–7.
- [2] Levine AM, Edwards CC. The management of traumatic spondylolisthesis of the axis. *J Bone Joint Surg Am* 1985;67:217–26.
- [3] Burke JT, Harris JH Jr. Acute injuries of the axis vertebra. *Skeletal Radiol* 1989;18:335–46.
- [4] Samaha C, Lazennec JY, Laporte C, et al. Hangman's fracture: the relationship between asymmetry and instability. *J Bone Joint Surg Br* 1989;82:1046–52.
- [5] AL-Mahfoudh R, Beagrie C, Woolley E, et al. Management of typical and atypical Hangman's fractures. *Global Spine J* 2015;6:248–56.
- [6] EI Masry WS, Tsubo M, Katoh S, et al. Validation of the American Spinal Injury Association (ASIA) motor score and the National Acute Spinal Cord Injury Study (NASCIS) motor score. *Spine* 1996;21:614–9.
- [7] Wang S, Wang Q, Yang H, et al. A novel technique for unstable Hangman's fracture: lag screw-rod (LSR) technique. *Eur Spine J* 2017;26:1284–90.
- [8] Bridwell KH, Lenke LG, McEnery KW, et al. Anterior fresh frozen structural allografts in the thoracic and lumbar spine. Do they work if combined with posterior fusion and instrumentation in adult patients with kyphosis or anterior column defects? *Spine* 1995;20:1410–8.
- [9] Effendi B, Roy D, Cornish B, et al. Fractures of the ring of the axis: a classification based on the analysis of 131 cases. *J Bone Joint Surg Br* 1981;63:319–27.
- [10] Benzel EC. Conservative treatment of neural arch fractures of the axis: computed tomography scan and X-ray study on consolidation time. *World Neurosurg* 2011;75:229–30.
- [11] Vaccaro AR, Madigan L, Bauerle WB, et al. Early halo immobilization of displaced traumatic spondylolisthesis of the axis. *Spine* 2002;27:2229–33.
- [12] Shin JJ, Kim SH, Cho YE, et al. Primary surgical management by reduction and fixation of unstable Hangman's fractures with discoligamentous instability or combined fractures: clinical article. *J Neurosurg Spine* 2013;19:569–75.

- [13] Li XF, Dai LY, Lu H, et al. A systematic review of the management of hangman's fractures. *Eur Spine J* 2006;15:257–69.
- [14] Xie N, Khoo LT, Yuan W, et al. Combined anterior C2-C3 fusion and C2 pedicle screw fixation for the treatment of unstable Hangman's fracture: a contrast to anterior approach only. *Spine* 2010;35:613–9.
- [15] Ying Z, Wen Y, Xinwei W, et al. Anterior cervical discectomy and fusion for unstable traumatic spondylolisthesis of the axis. *Spine* 2008;33:255–8.
- [16] Ma W, Xu R, Liu J, et al. Posterior short-segment fixation and fusion in unstable Hangman's fractures. *Spine* 2011;36:529–33.
- [17] Bristol R, Henn JS, Dickman CA. Pars screw fixation of a hangman's fracture: technical case report. *Neurosurgery* 2005;56:E204.
- [18] Liu J, Li Y, Wu Y. One-stage posterior C2 and C3 pedicle screw fixation or combined anterior C2-C3 fusion for the treatment of unstable hangman's fracture. *Exp Ther Med* 2013;5:667–72.
- [19] Li G, Wang Q, Liu H. CT analysis of anatomical variation and injury affecting posterior pedicle screw fixation for unstable Hangman fractures. *Medicine (Baltimore)* 2017;96:e6847.
- [20] Chaudhary SB, Martinez M, Shah NP, et al. Traumatic atlantoaxial dislocation with Hangman fracture. *Spine J* 2015;15:e15–8.