

Autosomal dominant polycystic kidney disease complicating renal ectopia and managed with renal transplantation

Andrew Connor¹, Charles E. Weston¹, Craig Dick² and Joanne E. Taylor¹

¹Department of Renal Medicine and ²Department of Radiology, Dorset County Hospital, Dorchester, UK

Correspondence and offprint requests to: Andrew Connor; E-mail: andrewconnor1974@hotmail.co.uk

Keywords: ADPKD; polycystic; renal ectopia

A 65-year-old lady developed fever and right-sided abdominal pain. Her medical history included renal transplantation for end-stage renal disease (ESRD) secondary to autosomal dominant polycystic kidney disease (ADPKD). Infection of a cyst within her native right kidney or liver was suspected. Computed tomography of her abdomen and pelvis showed both native kidneys to be grossly enlarged and polycystic. The left native kidney arose from within the pelvis. The transplanted kidney was visible in the right iliac fossa (Figure 1).

ADPKD is the fourth most common cause of ESRD [1], affecting ~1 in 1000 live births [2]. It is characterized by the accumulation of fluid-filled cysts in the kidney and other organs.

Renal ectopy and fusion are relatively common congenital anomalies. Renal ectopy results from the disruption of the normal embryological migration of the kidneys from the pelvis to the retroperitoneal renal fossa (at the level of the second lumbar vertebra). It may result from abnormalities of the ureteral bud and metanephric blastema, genetic anomalies, teratogenic influences or from anomalous vasculature acting as a barrier to ascent [3]. The incidence of pelvic kidney is 1 in 5000 [4]. Most cases are asymptomatic.

Renal fusion occurs when a portion of one kidney is fused with the other. The most common fusion anomaly is the horseshoe kidney. Approximately 20 cases of polycystic kidney disease complicating a horseshoe kidney have previously been reported [5]. However, to our knowledge, this is the first reported case of ADPKD complicating a pelvic kidney.

Nephrectomy may be considered prior to renal transplantation in patients with ADPKD in the presence of recurrent infection, suspected malignancy or extension of the native polycystic kidney into the potential pelvic surgical site. In cases complicated by a pelvic kidney, the notoriously variable vasculature of anomalous kidneys may complicate this procedure.

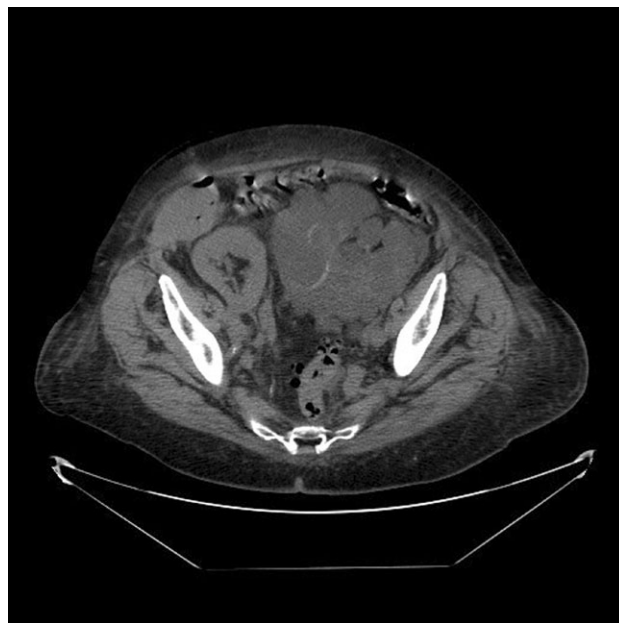


Fig. 1. Computed tomography showing a renal transplant lying in the right iliac fossa and a polycystic left native kidney arising from within the patient's pelvis.

References

1. Hateboer N, van Dijk MA, Bogdanova N *et al.* European PKD1-PKD2 Study Group. Comparison of phenotypes of polycystic kidney disease types 1 and 2. *Lancet* 1999; 353: 103–107
2. Bear JC, McManamon P, Morgan J *et al.* Age at clinical onset and at ultrasonographic detection of polycystic kidney disease: data for genetic counselling. *Am J Med Genet* 1984; 18: 45–53
3. Malek RS, Kelalis PP, Burke EC. Ectopic kidney tissue in children and frequency of association with other malformations. *Mayo Clin Proc* 1971; 46: 461
4. Sheih CP, Liu MB, Hung CS *et al.* Renal abnormalities in schoolchildren. *Pediatrics* 1989; 84: 1086
5. Batista Peres LA, Leonel Ferreira JR, Alvares Delfino VD. Polycystic horseshoe kidney. *Nephrol Dial Transplant* 2007; 22: 652–653

Conflict of interest statement. None declared.

Received for publication: 2.6.09; Accepted in revised form: 4.6.09