

## Case Report

# A case of successful kidney transplantation after an extremely long-term maintenance haemodialysis of 38 years

Masahiko Okamoto<sup>1</sup>, Tomoyuki Suzuki<sup>2</sup>, Shuji Nobori<sup>2</sup>, Hidetaka Ushigome<sup>2</sup> and Norio Yoshimura<sup>1,2</sup>

<sup>1</sup>Department of Organ Interaction Research Medicine and <sup>2</sup>Department of Transplantation and Regenerative Surgery, Graduate School of Medical Science, Kyoto Prefectural University of Medicine, Kyoto, Japan

Correspondence and offprint requests to: Masahiko Okamoto; E-mail: amoto@koto.kpu-m.ac.jp

### Abstract

We describe herein a case of kidney transplantation after extremely long-term haemodialysis. A 66-year-old male received a kidney transplant from a deceased donor after maintenance haemodialysis for 38 years and 2 months. In spite of long-term haemodialysis, he showed minimal calcification of the iliac vessels, and transplantation was carried out successfully. Other than some difficulties in vesical rehabilitation, his postoperative course was favourable and he was finally discharged from the hospital on the 84th postoperative day. On a review of the literature, this case might represent the longest period of haemodialysis ever prior to kidney transplantation in the world.

**Keywords:** haemodialysis; kidney transplantation; long term; vesical atrophy

### Introduction

Because of advances in the management of end-stage renal disease (ESRD) and the shortage of deceased donor kidneys, the number of patients undergoing a long-term continuation of haemodialysis is increasing in Japan. Herein, we report a case of successful kidney transplantation after an extremely long-term haemodialysis of 38 years, which might be the longest period of time a patient has ever been on haemodialysis prior to kidney transplantation in the world.

### Case report

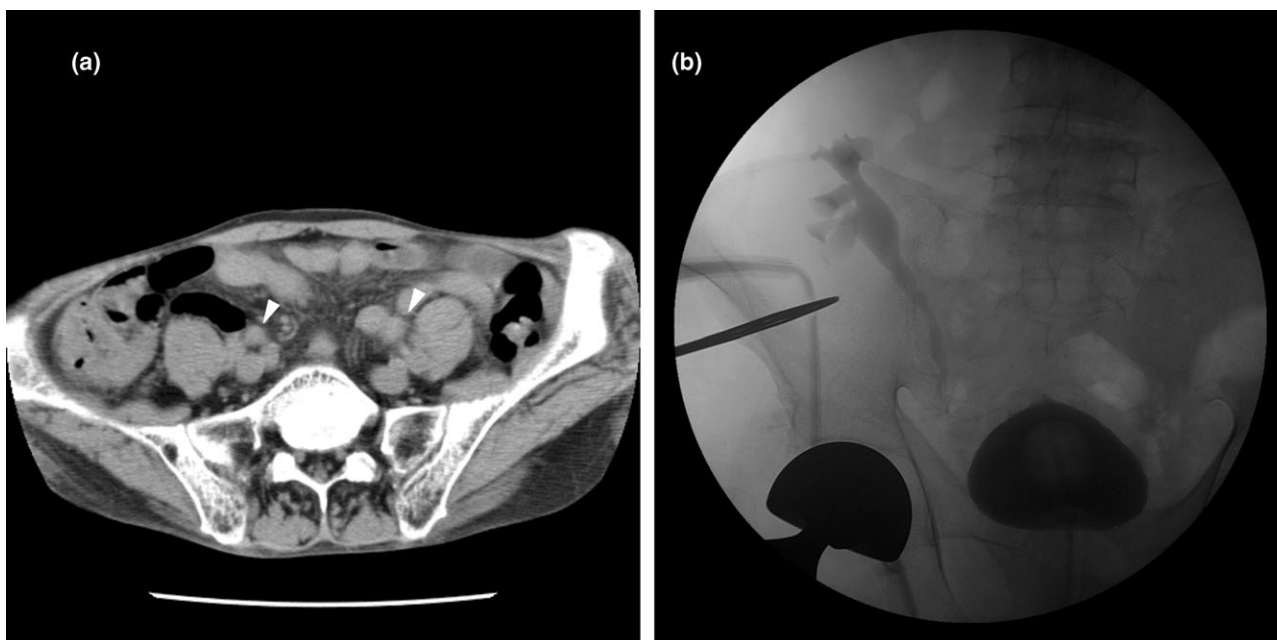
The patient was a 66-year-old male with ESRD due to chronic glomerulonephritis. Chronic haemodialysis was initiated in 1970 when the patient was 28 years of age and this modality was still rare in Japan. For the first 26 years, he received nocturnal haemodialysis for 12 h twice a week. After that he had received haemodiafiltration (HDF) for

4.5 h three times a week until transplantation. He had surgery for aseptic necrosis of the right femoral head at the age of 58 and suffered from cerebral infarction but recovered without any neurological defect. He was noted to have atrial fibrillation at the age of 63, and has since then been treated with an anticoagulant.

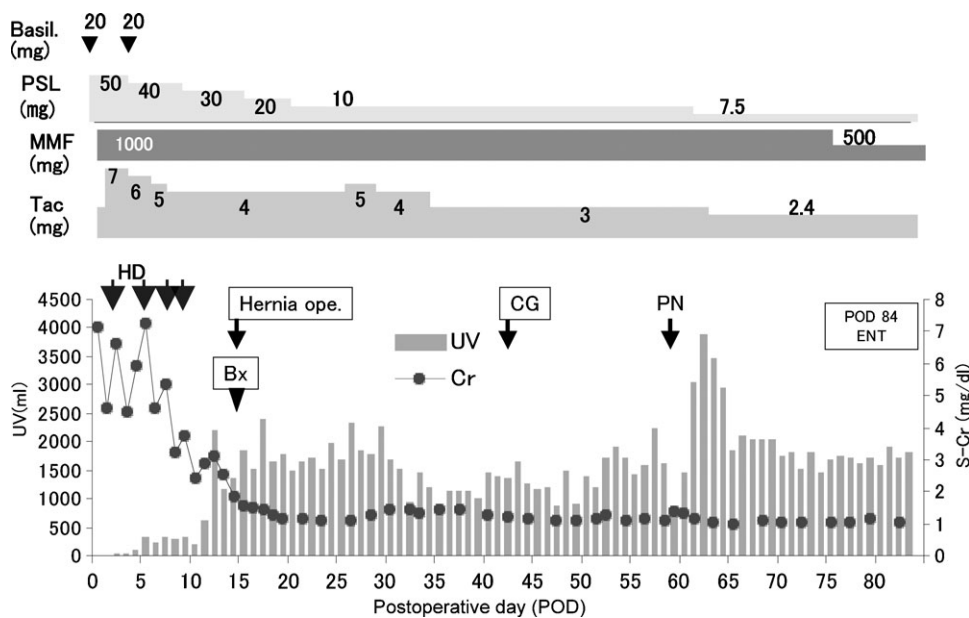
After maintenance haemodialysis for 38 years and 2 months, he received a kidney transplant from a 54-year-old female who had been diagnosed as brain dead due to traumatic subarachnoid haemorrhage. At the time of emergent admission, screening was performed to evaluate the risk of transplantation. There was no critical problem regarding the cardiovascular system except for the anticoagulant treatment. Computed tomography (Figure 1a) showed minimal calcification of his iliac vessels in spite of the long-term haemodialysis.

The kidney was harvested after cardiac arrest and preserved in University of Wisconsin solution, with a total ischaemic time of 6 h and 48 min. The graft ureter was anastomosed to his bladder intravesically. A percutaneous transvesical ureteral catheter was inserted because of the small volume of his bladder (<50 ml).

The graft functioned slowly, and four sessions of haemodialysis were needed after transplantation (Figure 2). Thereafter, the serum creatinine level gradually decreased to as low as 1.0 mg/dl. However, another operation was necessary on postoperative Day (POD) 13 due to bursting of the surgical wound caused by incisional hernia. Due to occlusion of the ureteral catheter for vesical rehabilitation starting on POD 20, he required frequent urination and was fatigued. On POD 35, the ureteral catheter was removed, and a transurethral Foley catheter was inserted. Cystography on POD 42 showed that the contrast medium infused via the Foley catheter went to the transplanted graft easily because of disuse atrophy of the bladder (Figure 1b). Although the Foley catheter was removed on POD 55, it was inserted again on POD 59 because of a rise in fever and mild elevation of the serum creatinine level, attributed to graft pyelonephritis caused by vesico-ureteral reflux. After reinsertion of the Foley catheter, he showed a very favourable



**Fig. 1.** (a) Computed tomography findings just before deceased donor kidney transplantation after 38 years and 2 months of haemodialysis. Arteriosclerosis was absent in the iliac vessels (arrow). (b) Retrograde cystography on POD 42 after deceased donor kidney transplantation. Contrast medium infused via the Foley catheter easily went to the transplanted graft because of disuse atrophy of the bladder.



**Fig. 2.** The postoperative course following deceased donor kidney transplantation. Bx: biopsy, CG: cystography, PN: pyelonephritis, HD: haemodialysis, Basil: basiliximab, PSL: prednisolone, MMF: mycophenolate mofetil, Tac: tacrolimus, UV: urine volume.

course, and serum creatinine remained as low as 1.0 mg/dl. After the continuous rehabilitation of his native bladder by transient occlusion of the Foley catheter, the catheter was removed on POD 75. He was finally discharged from the hospital without difficulty in urination on POD 84. Now, he is free from haemodialysis with an improving vesical function.

**Discussion**

Chronic haemodialysis was first reported in 1960 when Scribner *et al.* initiated a chronic haemodialysis programme [1]. Long-term haemodialysis first became a reasonable possibility in 1966, when the arteriovenous fistula was described [2], and there is now a small group of extremely

long-term haemodialysis survivors. Unfortunately, much of the information on these individuals is often anecdotal and does not usually appear in scientific reports. Kurkus *et al.* [3] reported two patients who were on haemodialysis for 35 years, and they described these patients as two of the longest known survivors on haemodialysis worldwide.

To achieve long-term survival on haemodialysis, various strategies have been described. Intensified haemodialysis is one of them. A large number of reports have demonstrated that increasing the dialysis time facilitates improved blood pressure control, the need for fewer antihypertensive drugs or none at all, and increased survival [4–6]. In our case, long-term nocturnal haemodialysis was thought to play a role in the extremely long-term survival on haemodialysis.

According to the *Annual Report of The Japanese Society for Dialysis Therapy*, the longest known period of haemodialysis in Japan by a surviving patient was 39 years and 8 months. Among renal transplant recipients in Japan, the present case showed the longest period of haemodialysis prior to kidney transplantation according to the data registered in the Japan Organ Transplant Network, which has collected all deceased donor transplant data since 1995 (personal communication). On review of a large number of studies, no report of a longer period of haemodialysis before kidney transplantation than in the present case was found. This is supported by the fact that, for unknown reasons, the mortality rate among haemodialysis patients in Japan is markedly lower than that of Western Europe and the United States [7].

It has been widely reported that the length of time on dialysis prior to transplantation affects a patient's survival. Our series of results also suggest that dialysis treatment for more than 10 years has negative effects on post-transplantation patient and graft survival [8]. Another important problem in kidney transplantation in long-term dialysis patients is an increasing risk of urologic complications because of an atrophic bladder caused by an extended anuric period. Wu *et al.* [9] reported that renal transplant recipients who have been anuric for a prolonged period show higher rates of complicated urinary tract infections, but the long-term risks

of urological complications are not significantly different. In our case, although the anuric period was extremely long, more than 35 years, the vesical function recovered in a rather short period of rehabilitation, with only one episode of urinary tract infection.

In conclusion, we encountered a case of renal transplantation after extremely long-term haemodialysis. Because of sophisticated dialysis management, arteriosclerosis was minimal and vascular complications could be avoided. Although a complication was caused by atrophic bladder and poor wound healing, renal transplantation after extremely long-term haemodialysis could eventually be performed successfully.

*Conflict of interest statement.* None declared.

## References

1. Scribner BH, Buri R, Caner JEZ *et al.* The treatment of chronic uremia by means of intermittent hemodialysis: a preliminary report. *Tr Am Soc Artif Intern Organs* 1960; 6: 114–122
2. Brescia MJ, Cimino JE, Appel K *et al.* Chronic hemodialysis using venipuncture and a surgically created arteriovenous fistula. *N Engl J Med* 1966; 275: 1089–1092
3. Kurkus J, Nykvist M, Lindergård B *et al.* Thirty-five years of hemodialysis: two case reports as a tribute to Nils Alwall. *Am J Kidney Dis* 2007; 49: 471–476
4. Troidle L, Hotchkiss M, Finkelstein F. A thrice weekly in-center nocturnal hemodialysis program. *Adv Chronic Kidney Dis* 2007; 14: 244–248
5. Haag-Weber M. Treatment options to intensify hemodialysis. *Kidney Blood Press Res* 2003; 26: 90–95
6. Locatelli F, Buoncristiani U, Canaud B *et al.* Dialysis dose and frequency. *Nephrol Dial Transplant* 2005; 20: 285–296
7. Goodkin DA, Young EW, Kurokawa K *et al.* Mortality among hemodialysis patients in Europe, Japan, and the United States: case-mix effects. *Am J Kidney Dis* 2004; 44(Suppl 2): S16–S21
8. Ushigome H, Sakai K, Suzuki T *et al.* Kidney transplantation for patients on long-term hemodialysis. *Transplant Proc* 2008; 40: 2297–2298
9. Wu YJ, Veale JL, Gritsch HA. Urological complications of renal transplant in patients with prolonged anuria. *Transplantation* 2008; 86: 1196–1198

*Received for publication: 20.6.09; Accepted in revised form: 24.6.09*