

Erector Spinae Plane Block using Clonidine as an Adjuvant for Excision of Chest Wall Tumor in a Pediatric Patient

Abstract

Erector spinae plane block has been described to manage post-thoracotomy pain. It is a simple block and shown to provide effective analgesia. In single shot blocks opioid supplementation may be required to manage pain after the effect of local anesthetic wears off. In this case, we describe a case of chest wall tumor excision in a child who received clonidine in addition to local anesthetic for the erector spinae plane block. This provided long lasting and effective postoperative analgesia and may be considered to prolong the analgesia achieved with erector spinae plane block.

Keywords: Chest wall tumor, clonidine, ESP, pediatric patient

Introduction

Regional anesthesia has seen a major upsurge in pediatric population ever since the introduction of ultrasound. Use of regional anesthesia as a part of multimodal analgesic strategy for post-thoracotomy pain and is associated with improved postoperative outcomes. Central neuraxial or paravertebral blocks have been the main regional anesthetic techniques utilized in children for this purpose.^[1] These techniques result in effective analgesia in majority of patients but are quite invasive and challenging to perform in this group of patients. The erector spinae plane block (ESPB) is a novel regional anesthesia technique which has shown promising results for the treatment of post-thoracotomy pain and is being increasingly utilized for this purpose.^[2,3] The main advantage appears to be its lesser invasiveness and complexity compared to the conventional techniques. Both single shot and continuous blocks have been used in adults and children effectively. We report a case of chest wall tumor excision (along with resection of two ribs) in a 2.5-year-old child where use of clonidine as an adjuvant with bupivacaine for ESPB resulted in prolonged postoperative analgesia and no requirement of rescue analgesics for the first 24 hours.

This is an open access journal, and articles are distributed under the terms of the Creative Commons Attribution-NonCommercial-ShareAlike 4.0 License, which allows others to remix, tweak, and build upon the work non-commercially, as long as appropriate credit is given and the new creations are licensed under the identical terms.

For reprints contact: reprints@medknow.com

Case Report

A 30-month-old, ASA I, female child weighing 14 kg presented with a mass on her back. On investigations, it was diagnosed to be a malignant peripheral nerve sheath tumor (9 × 5 × 2.5 cm) of the left upper posterior thoracic wall below the scapula lying deep to the subscapularis muscle and involving the third and the fourth rib along with the third intercostal space. She was posted for the tumor resection along with segmental resection of underlying two ribs. There was no significant history of any systemic illness in the past. She had received seven cycles of chemotherapy (vincristine, actinomycin-D, and cyclophosphamide based) and had received her last cycle 3 weeks back. Her blood counts and other investigations including echocardiography were normal. On the morning of surgery, the child was premedicated with syrup pediclorol 100 mg. She was shifted to the operating room and standard monitoring was attached. A 22-G IV cannula was secured and anesthesia was induced with propofol and fentanyl. The trachea was intubated with a 4-mm ID uncuffed endotracheal tube 3 minutes after giving vecuronium. Patient was then positioned lateral with operative side dependent. Under aseptic precautions, a linear high frequency (8–13 MHz; L38) ultrasound probe (Imagic Agile, Kontron medical,

How to cite this article: Gupta A, Gupta N, Choudhury A, Agrawal N. Erector spinae plane block using clonidine as an adjuvant for excision of chest wall tumor in a pediatric patient. *Ann Card Anaesth* 2020;23:221-3.

Anju Gupta,
Nishkarsh Gupta¹,
Arindam
Choudhury²,
Nidhi Agrawal

Department of Anaesthesiology,
VMMC and Safdarjung
Hospital, Departments of ¹Oncology
Anesthesiology and ²Cardiac
Anesthesiology, AIIMS,
New Delhi, India

Submitted: 30-Sep-2018
Revised: 24-Nov-2018
Accepted: 07-Jan-2019
Published: 07-Apr-2020

Address for correspondence:

Dr. Nishkarsh Gupta,
Oncology
Anesthesiology
and Palliative Medicine,
DRBRAIRCH, AIIMS,
New Delhi - 110 029, India.
E-mail: drnishkarsh@rediffmail.
com

Access this article online

Website: www.annals.in

DOI: 10.4103/aca.ACA_188_18

Quick Response Code:



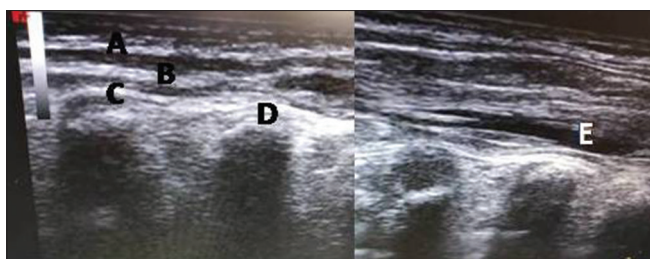


Figure 1: US images of a patient with ESP block; trapezius muscle (A), rhomboid major muscle (B), erector spinae muscle (C), T5 transverse process (D), and LA spread (E)

Peachtree city, Georgia) was placed parasagittal to the T5 spine.

T5 transverse process was visualized along with the three overlying muscles (i.e., from superficial to deep: trapezius, rhomboid major, and erector spinae), and a 5 cm blunt tipped echogenic needle was inserted in-plane from caudad to cephalad direction to lie above the tip of the transverse process and deep to the erector spinae muscle. Eight milliliter of ropivacaine 0.375% with 10 mcg clonidine was injected and spread of LA was seen [Figure 1]. Paracetamol 150 mg was administered as intravenous infusion. Anesthesia was maintained with isoflurane, nitrous oxide, and vecuronium boluses as per requirement. Surgery lasted 2 h with stable vital parameters and no further doses of opioids were required intraoperatively. After reversal of neuromuscular blockade, the trachea was extubated. In the post anesthesia care unit (PACU), the child remained comfortable with a Face, Legs, Activity, Cry, Consolability (FLACC) score of 0–1 and was discharged to the ward after 2 h with a FLACC score of 0. She received scheduled doses of paracetamol 150 mg intravenously every 8 hours postoperatively. The child was reassessed at 4 h, 6 h, 8 h, 16 h, and 24 h postoperatively, and FLACC was found to be 0–2 at all intervals. No further demand of analgesics was made, and on second postoperative day she was allowed orally and switched over to oral paracetamol. Parents reported to be extremely satisfied with the perioperative experience.

Discussion

The present case demonstrates effective and prolonged perioperative analgesia with ESPB using clonidine as an adjuvant to ropivacaine in a child with thoracic wall tumor. The ESPB is a newly described myofascial plane block where local anaesthetic is injected in the myofascial plane under the erector spinae muscle and posterior to the tip of the transverse process.^[4] The postulated mechanism of analgesic action is that the LA injected above the transverse process diffuses into the paravertebral space through the costotransverse foramina, cranially as well as caudally and blocks the thoracic spinal nerves running through it, thereby providing sensory blockade of the posterior as well as anterolateral chest wall.^[4]

Erector spinae muscle runs along the whole length of the thoracolumbar spine, and thus LA injected under it can provide extensive unilateral sensory coverage. Studies in fresh cadavers have found that dye/contrast injected at T5 level to spread from C7-T2 transverse process cranially to T8-L3 levels caudally.^[4,5] Hence, ESPB can be an effective and safer alternative to the deeper blocks such as PVB and epidural blocks.

ESPB has mainly been described in relation to treatment of adult chronic or acute pain management.^[2-4] More recently, anecdotal reports of its application in management of pediatric acute postoperative pain have shown promising results. A case report of thoracotomy for resection of rib tumor in a 7-year-old child described the successful use of single-shot ESPB at the end of the procedure at the level of the T8 transverse process using 14 mL of bupivacaine 0.5% with epinephrine 5 µg/mL.^[6] Postoperatively, multimodal analgesia was maintained using combination of intravenous tramadol 2 mg/kg, oral acetaminophen 15 mg/kg and intravenous metamizole 20 mg/kg. On this regimen, analgesia was effectively maintained until 32 h when morphine supplementation was required. In our case, there was no requirement of any rescue analgesics other than the scheduled acetaminophen doses during the postoperative stay despite the big tumor size and resection of 5 cm segments of two ribs.

Recently, use of continuous ESPB was described in a 3-year-old child for postoperative pain after open thoracotomy.^[7] ESP was performed at the end of the surgery at T9 level with 8 mL of 0.25% levo-bupivacaine bolus and continuous infusion of 0.1% levo-bupivacaine 3 mL/h was started. During the initial 4 postoperative days, only twice was a rescue bolus dose of 1.5 ml levobupivacaine 0.1% required and no other analgesics were required.

In our patient, the preoperative administration of the block with possible pre-emptive analgesia along with administration of clonidine as an adjuvant to local anaesthetic provided long lasting and effective postoperative analgesia. Hence, we propose the use of clonidine as an effective alternative to use of continuous ESPB in patients where use of continuous infusion techniques are not feasible or contraindicated. However, well-designed, randomized controlled trials are desirable to support or refute this claim.

Conclusion

ESPB can be an effective block for providing postoperative analgesia following thoracic surgeries in children. The use of clonidine as an adjuvant to local anaesthetics for ESPB may be effective in prolonging the duration of analgesia and improving the quality of block, thereby optimizing the benefits of the technique.

Declaration of patient consent

The authors certify that they have obtained all appropriate patient consent forms. In the form the patient(s) has/have given his/her/their consent for his/her/their images and other clinical information to be reported in the journal. The patients understand that their names and initials will not be published and due efforts will be made to conceal their identity, but anonymity cannot be guaranteed.

Financial support and sponsorship

Nil.

Conflicts of interest

There are no conflicts of interest.

References

1. Joshi GP, Bonnet F, Shah R, Wilkinson RC, Camu F, Fischer B, *et al.* A systematic review of randomized trials evaluating regional techniques for post thoracotomy analgesia. *Anesth Analg* 2008;107:1026-40.
2. Ueshima H, Otake H. Clinical experiences of ultrasound-guided erector spinae plane block for thoracic vertebra surgery. *J Clin Anesth* 2017;38:137.
3. Forero M, Rajarathinam M, Adhikary S, Chin KJ. Continuous erector spinae plane block for rescue analgesia in thoracotomy after epidural failure. A case report. *A A Case Rep* 2017;8:254-6.
4. Forero M, Adhikary SD, Lopez H, Tsui C, Chin KJ. The erector spinae plane block: A novel analgesic technique in thoracic neuropathic pain. *Reg Anesth Pain Med* 2016;41:621-7.
5. Adhikary SD, Pruet A, Forero M, Thiruvenkatarajan V. Erector spinae plane block as an alternative to epidural analgesia for post-operative analgesia following video-assisted thoracoscopic surgery: A case study and a literature review on the spread of local anaesthetic in the erector spinae plane. *Indian J Anaesth* 2018;62:75-8.
6. Muñoz F, Cubillos J, Bonilla AJ, Chin KJ. Erector spinae plane block for postoperative analgesia in pediatric oncological thoracic surgery. *Can J Anaesth* 2017;64:880-2.
7. De la Cuadra-Fontaine JC, Concha M, Vuletin F, Arancibia H. Continuous erector spinae plane block for thoracic surgery in a pediatric patient. *Paediatr Anaesth* 2018;28:74-5.